

Meningoencephalitis in Two Stranded California Sea Lions (*Zalophus californianus*) Caused by Aberrant Trematode Migration

Authors: Fauquier, Deborah, Gulland, Frances, Haulena, Martin, Dailey, Murray, Rietcheck, Randall L., et al.

Source: Journal of Wildlife Diseases, 40(4) : 816-819

Published By: Wildlife Disease Association

URL: <https://doi.org/10.7589/0090-3558-40.4.816>

BioOne Complete (complete.BioOne.org) is a full-text database of 200 subscribed and open-access titles in the biological, ecological, and environmental sciences published by nonprofit societies, associations, museums, institutions, and presses.

Your use of this PDF, the BioOne Complete website, and all posted and associated content indicates your acceptance of BioOne's Terms of Use, available at www.bioone.org/terms-of-use.

Usage of BioOne Complete content is strictly limited to personal, educational, and non - commercial use. Commercial inquiries or rights and permissions requests should be directed to the individual publisher as copyright holder.

BioOne sees sustainable scholarly publishing as an inherently collaborative enterprise connecting authors, nonprofit publishers, academic institutions, research libraries, and research funders in the common goal of maximizing access to critical research.

Meningoencephalitis in Two Stranded California Sea Lions (*Zalophus californianus*) Caused by Aberrant Trematode Migration

Deborah Fauquier,¹ Frances Gulland,^{1,3} Martin Haulena,¹ Murray Dailey,¹ Randall L. Rietschek,² and Thomas P. Lipscomb² ¹ The Marine Mammal Center, Marin Headlands, 1065 Fort Cronkhite, Sausalito, California 94965, USA; ² Armed Forces Institute of Pathology, 14th St. and Alaska Ave., Washington, D.C. 20306, USA; ³ Corresponding author (email: gullandf@tmmc.org)

ABSTRACT: Meningoencephalitis caused by aberrant trematode migration is described in two California sea lions (*Zalophus californianus*) admitted to a rehabilitation hospital between May and August 2001. Both animals displayed seizure activity and were euthanized due to poor response to therapy. Gross abnormal findings included liver flukes (*Zalophotrema hepaticum*) in the bile ducts and areas of swelling and necrosis in the cerebrum, cerebellum, and brain stem. Histopathology revealed meningoencephalitis with necrosis, hemorrhage, and many trematode eggs within the brain. In one sea lion, an adult trematode was found on the surface of the cerebrum. These are believed to be the first reported cases of meningoencephalitis caused by aberrant trematode migration in pinnipeds.

Key words: California sea lion, liver fluke, meningoencephalitis, *Zalophotrema hepaticum*, *Zalophus californianus*.

Liver flukes (*Zalophotrema hepaticum*) are common parasites of California sea lions (*Zalophus californianus*) (Dailey, 2001). They normally inhabit the liver, gallbladder, and pancreas and can cause portal fibrosis with bile duct proliferation and dilatation (Sweeney, 1974). This report describes clinical and pathologic characteristics of aberrant liver fluke migration causing meningoencephalitis in two California sea lions.

On 6 May 2001, a yearling male California sea lion (4937) was admitted to a rehabilitation hospital (The Marine Mammal Center [TMMC], Sausalito, California, USA). The animal had stranded live in Monterey County, California, USA (36°48'N, 121°47'W) and was lethargic. Age was determined by morphologic characteristics and season, the animal was estimated to be 1 yr of age. On physical examination, sea lion 4937 had a swollen left eye and was dehydrated. Red cell, white

cell, and serum chemistry parameters were within reference limits for this species (Bossart et al., 2001). The animal was treated with antibiotics, anti-gastric ulcer medications, and supportive care.

Eight days after presentation, sea lion 4937 became lethargic and ataxic. The animal was treated with 5 mg of diazepam (Valium®, Abbott Laboratories, Abbott Park, North Chicago, Illinois, USA) by injection into the gluteal muscle. Blood parameters were still within reference limits except for hyponatremia (131 mmol/ml). The animal was treated by subcutaneous administration of 500 ml of 0.9% sodium chloride. An abdominal ultrasound and thoracic radiographs were taken and no abnormalities were found. The animal showed no improvement and it was sedated with 175 mg of a 1:1 solution of tiletamine and zolazepam (Telazol®, Fort Dodge Animal Health, Fort Dodge, Iowa, USA) intramuscularly and was euthanized with 2,730 mg of pentobarbital (Beuthanasia®, Schering-Plough Animal Health Corporation, Kenilworth, New Jersey, USA) by intracardiac injection.

On 10 May 2001, another yearling male California sea lion (4940) was admitted to TMMC. The animal had stranded live in San Luis Obispo County, California, USA (35°32'N, 121°04'W), was lethargic, and had been observed having seizures on the beach. On physical examination, sea lion 4940 had bilateral harsh lung sounds. Blood parameters were within reference limits. Fecal examination revealed anisakid eggs, liver fluke (*Z. hepaticum*) eggs, lungworm (*Paraflaroides decorus*) larvae, and one hookworm (*Uncinaria lucasi*) egg (Dailey and Gilmartin, 1980; Dailey,

2001). The animal was diagnosed with suspected domoic acid toxicity based on clinical signs (Gulland et al., 2002) and lung-worm pneumonia. The sea lion was treated with antihelmintics including one dose of 6.1 mg of ivermectin (Ivomec®, Merck and Company, Whitehouse Station, New Jersey, USA) subcutaneously and two doses of 153 mg of praziquantel (Droncit®, Bayer Corporation, Shawnee Mission, Kansas, USA) orally. Sea lion 4940 was also treated with antibiotics, corticosteroids, and supportive care, and was monitored for additional seizures. The animal did not have additional seizures and was released in Marin County, California, USA (37°59'N, 122°58'W) on 8 June 2001.

Sea lion 4940 reestranded two more times in July and August 2001. The last stranding occurred on 18 August 2001 in San Mateo County, California, USA (37°28'N, 122°26'W). On physical examination the animal was weak, ataxic, lethargic, had a corneal ulcer in the right eye, and had fishhooks in the mouth and left hind flipper. Blood parameters were within reference limits. The fish hooks were removed on 19 August 2001, and there were no skull, thoracic, and abdominal radiographic abnormalities except for a bullet near the 7th sternebra with moderate soft-tissue swelling. Cardiac ultrasound examination revealed no obvious abnormalities. The animal was treated with antibiotics, anti-inflammatories, and supportive care. Six days after presentation, the animal was lethargic and unresponsive. While receiving medical treatment, the animal had a seizure that progressed to status epilepticus. Based upon the history of re-stranding and suspected long-term effects of domoic acid toxicity, the animal was sedated with 100 mg of Telazol intramuscularly and was euthanized with 2,730 mg of pentobarbital intravenously.

Gross postmortem examination of sea lions 4937 and 4940 revealed moderate to heavy loads of tapeworms (*Diphylllobothrium* sp.) in the intestines, anisakids in the stomach, and liver flukes in the bile ducts.

The liver flukes in the bile ducts were examined microscopically (40×) and identified morphologically as *Z. hepaticum*, as described by Delyamure (1955). The brain of sea lion 4937 had a 1-cm-diameter focal, darkened, raised area on the ventral surface of the right lobe of the cerebellum. The ventral brain stem of sea lion 4940 had multiple brown, ovoid structures up to 1 mm in diameter on the surface, as well as areas of necrosis and hemorrhage associated with fistulous tracts in the cerebrum. The brown ovoid structures were subsequently placed in saline solution and examined as wet mounts for microscopic study. The ovoid structures examined microscopically (40×) contained multiple operculate eggs with a thickened posterior pole, the eggs were 68–79×43–52 µm wide, and the morphology was consistent with those of *Z. hepaticum* eggs as described by Delyamure (1955). Spinal cord was not examined from either animal.

Tissue samples from multiple organs were fixed in 10% neutral buffered formalin, routinely processed for paraffin embedding, sectioned at 4–5 µm, and stained with hematoxylin and eosin. Microscopic examination of multiple sections of cerebrum and cerebellum from both sea lions revealed regions of parenchymal necrosis, hemorrhage, and fibrosis that contained numerous gitter cells interspersed with many oval eggs, thickened at the posterior pole and circular in cross section. Within the surrounding neuropil, there were gemistocytic astrocytes, swollen, degenerate axons, and many, often perivascular, lymphocytes and plasma cells. Meninges and choroid plexi were expanded by numerous lymphocytes and plasma cells but no eosinophils were observed. At the surface of a cerebral gyrus of sea lion 4940, a single flat, reddish brown, leaflike parasite, 11–13 mm long was found surrounded by gitter cells (Fig. 1). This parasite was morphologically identical to the specimens of *Z. hepaticum* found in the liver. Also egg and tegumental spine measurements were the same for the fluke found in the brain

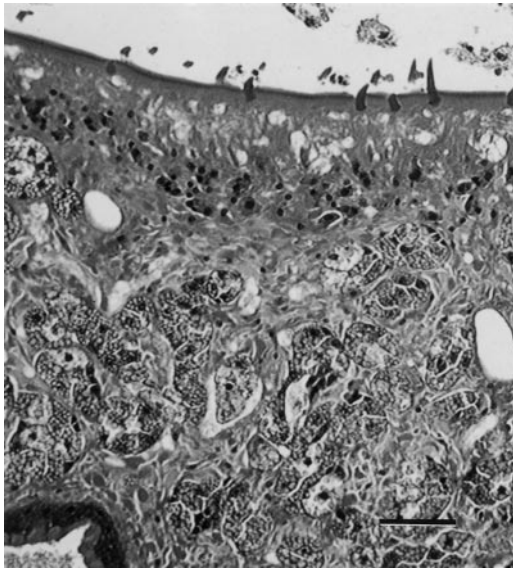


FIGURE 1. Portion of trematode from the brain of a California sea lion. Inflammatory gutter cells and debris are at the top. Note tegumental spines, vitellaria (with microvacuolated cytoplasm), and portion of cecum at lower left. Bar=60 μ m.

and the flukes found in the liver. Other histologic lesions in this sea lion included ulcerative gastritis associated with anisakid nematodes, pneumonia associated with degenerated nematodes, and focal granulomatous and eosinophilic hepatitis; however, no flukes or fluke eggs were seen in histologic sections of the liver. In sea lion 4937, atrophy of adipose tissue, interstitial nephritis, a trematode egg within the lumen of the common bile duct, an adult cestode within the lumen of the small intestine, and bronchiolitis associated with nematodes also were found. Based on light microscopy, sea lions 4937 and 4940 both were diagnosed with aberrant migration of one or more adult trematodes through the brain. Although the flukes were morphologically identified as *Z. hepaticum*, molecular techniques would be needed for positive species identification, which has not been performed in these cases.

At TMMC, more than 500 California sea lions have had gross and histopathologic examinations of the brain and these two animals are the first cases of menin-

goencephalitis caused by aberrant trematode migration observed in this species. Few reports of brain lesions associated with parasitic helminths have been described in marine mammals. In pinnipeds, larvae and adult worms of *Contracaecum osculatum* were found in the brains of four California sea lions from Baja California (Mexico) (Barroeta et al., 1961). In cetaceans, Ridgway and Dailey (1972) reported necrosis due to numerous trematode ova in the brain tissue of stranded common dolphins (*Delphinus delphis*) in California. The fluke species in these cases were originally identified as *Campula* sp. and *Zalophotrema* sp. Subsequent reports have determined that adult trematodes of the genus *Nasitrema* can be the causative agent of brain tissue necrosis in dolphins (Parker et al., 1977; Dailey and Walker, 1978).

In other nonmarine mammal species, digestive tract trematodes have been found to migrate to the brain. Fatal trematodiasis due to *Spirorchis* sp. has been reported in freshwater turtles (*Trachemys scripta elegans* and *Chrysemys picta*) (Johnson et al., 1998) and *Prouterina* sp. were found in the brain of a black bear (*Ursus americanus*) (Foreyt et al., 1996). In experimentally infected rodents, metacercariae of *Pharyngostomum cordatum* have been found to migrate to the brain (Shin et al., 2001). Lung flukes (*Paragonimus westermanni*) also have been found in brains of humans (Kang et al., 2000).

Liver flukes were present in sea lion 4940 at postmortem examination, despite treatment with praziquantel; however, the premortem worm burden was unknown. Also, the animal was returned to the wild subsequent to praziquantel treatment, so reinfection could have occurred before death. In sea lions 4937 and 4940, the liver fluke larvae may have migrated to the brain before reaching adult size; however, at this time the cause and route of the aberrant migration of liver flukes in these two California sea lions are unknown. Based upon these cases, abnormal parasit-

ic migration should be considered in the differential diagnosis of California sea lions displaying central nervous system abnormalities.

We thank the staff and volunteers of TMMC for care of these animals, and the Arthur and Elena Court Nature Conservancy and Page Evans Fellowship for their generous financial support.

LITERATURE CITED

- BARROETA, L. F., E. HIDALGO-ESCALANTE, AND R. OLEAC. 1961. Nematodes from birds and mammals IV. Erratic parasitosis in *Zalophus californianus* from Asuncion Island, Baja California, Mexico. *Helminthologia* 111: 112–116.
- BOSSART, G. D., T. H. REIDARSON, L. A. DIERAUF, AND D. A. DUFFIELD. 2001. Clinical pathology. In *CRC handbook of marine mammal medicine*, L. A. Dierauf and F. M. D. Gulland (eds.). CRC Press LLC, Boca Raton, Florida, pp. 383–436.
- DAILEY, M. 2001. Parasitic diseases. In *CRC handbook of marine mammal medicine*, L. A. Dierauf and F. M. D. Gulland (eds.). CRC Press LLC, Boca Raton, Florida, pp. 372.
- , AND W. G. GILMARTIN. 1980. Diagnostic key to the parasites of some marine mammals. Technical Document 295. Naval Ocean Systems Center, San Diego, California, 37 pp.
- , AND W. A. WALKER. 1978. Parasitism as a factor in single strandings of southern California cetaceans. *Journal of Parasitology* 64: 593–596.
- DELYAMURE, S. L. 1955. Helminthofauna of marine mammals (ecology and phylogeny). Academy of Sciences of the U.S.S.R. Laboratory of Helminthology, Moscow, USSR. [Translated by Israel Program for Scientific Translations, US Department of the Interior, Springfield, Virginia, TT67-51202, 522 pp.]
- FOREYT, W. J., S. C. SCHELL, AND J. C. BEYER. 1996. *Prouterina wescotti* n. gen., n. sp. (Trematoda: Prouterinidae n. fam.) from the brain, lungs and nasal sinuses of a black bear (*Ursus americanus*) from Idaho. *Journal of Wildlife Diseases* 32: 225–233.
- GULLAND, F. M. D., M. HAULENA, D. FAUQUIER, M. E. LANDER, T. ZABKA, AND R. S. DUERR. 2002. Domoic acid toxicity in Californian sea lions (*Zalophus californianus*): Clinical signs, treatment and survival. *The Veterinary Record* 150: 475–480.
- JOHNSON, C. A., J. W. GRIFFITH, P. TENORIO, S. HYTREK, AND C. M. LANG. 1998. Fatal trematodiasis in research turtles. *Laboratory Animal Science* 48: 340–343.
- KANG, S. Y., T. K. KIM, T. Y. KIM, Y. I. HA, S. W. CHOI, AND S. J. HONG. 2000. A case of chronic cerebral paragonimiasis *westerni*. *Korean Journal of Parasitology* 38: 167–171.
- PARKER, G. A., G. MIGAKI, AND W. A. WALKER. 1977. Case for diagnosis. *Military Medicine* 142: 869–871.
- RIDGWAY, S. H., AND M. D. DAILEY. 1972. Cerebral and cerebellar involvement of trematode parasites in dolphins and their possible role in stranding. *Journal of Wildlife Diseases* 8: 33–43.
- SHIN, E. H., J. Y. CHAI, AND S. H. LEE. 2001. Extraintestinal migration of *Pharyngostomum cordatum* metacercariae in experimental rodents. *Journal of Helminthology* 75: 285–290.
- SWEENEY, J. 1974. Common diseases of pinnipeds. *Journal of the Veterinary Medical Association* 165: 805–810.

Received for publication 30 July 2003.