

**INFECTIONS CAUSED BY MYCOBACTERIUM AVIUM
SUBSPECIES AVIUM, HOMINISSUIS, AND
PARATUBERCULOSIS IN FREE-RANGING RED DEER
(CERVUS ELAPHUS HIPPELAPHUS) IN AUSTRIA, 2001–
2004**

Authors: Glawischnig, Walter, Steineck, Theodora, and Spergser, Joachim

Source: Journal of Wildlife Diseases, 42(4) : 724-731

Published By: Wildlife Disease Association

URL: <https://doi.org/10.7589/0090-3558-42.4.724>

BioOne Complete (complete.BioOne.org) is a full-text database of 200 subscribed and open-access titles in the biological, ecological, and environmental sciences published by nonprofit societies, associations, museums, institutions, and presses.

Your use of this PDF, the BioOne Complete website, and all posted and associated content indicates your acceptance of BioOne's Terms of Use, available at www.bioone.org/terms-of-use.

Usage of BioOne Complete content is strictly limited to personal, educational, and non - commercial use. Commercial inquiries or rights and permissions requests should be directed to the individual publisher as copyright holder.

BioOne sees sustainable scholarly publishing as an inherently collaborative enterprise connecting authors, nonprofit publishers, academic institutions, research libraries, and research funders in the common goal of maximizing access to critical research.

INFECTIONS CAUSED BY *MYCOBACTERIUM AVIUM* SUBSPECIES *AVIUM*, *HOMINISSUIS*, AND *PARATUBERCULOSIS* IN FREE-RANGING RED DEER (*CERVUS ELAPHUS HIPPELAPHUS*) IN AUSTRIA, 2001–2004

Walter Glawischnig,^{1,4} Theodora Steineck,² and Joachim Spergser³

¹ Institute of Veterinary Medicine, Austrian Agency for Health and Food Safety, A-6020 Innsbruck, Austria

² Research Institute of Wildlife Ecology, University of Veterinary Medicine, A-1210 Vienna, Austria

³ Institute of Bacteriology, Mycology and Hygiene, Department of Pathobiology, University of Veterinary Medicine, A-1210 Vienna, Austria

⁴ Corresponding author (email: walter.glawischnig@ages.at)

ABSTRACT: Between 2001 and 2004, 14 Austrian free-ranging red deer (*Cervus elaphus hippelaphus*) infected by *Mycobacterium avium* species were observed. Eight of the cases were from different geographical regions, and six originated from the same hunting area. The affected animals had signs of diarrhea, severe weight loss, and emaciation. On post-mortem examination, lymphadenitis associated with grossly enlarged mesenteric lymph nodes as well as multiple caseous or purulent nodular lesions in the thickened wall of the intestines were present in all animals. In 10 cases *M. avium* subsp. *avium* and in four cases *M. a. hominissuis* were isolated. In three red deer, a mixed infection with *M. a. hominissuis* and *M. a. paratuberculosis* was evident. Typing of *M. a. avium* and *M. a. hominissuis* isolates was performed by polymerase chain reaction (PCR) detection of insertion sequence IS901 and the virulence-associated macrophage-induced gene (*mig*), inverted repeat (IR) typing (IS1245/IS1311), and random amplified polymorph DNA (RAPD) analysis. While all *M. a. avium* and *M. a. hominissuis* contained the *mig* gene, IS901 was detected only in *M. a. avium*. The prevalence of IS901-positive isolates correlated well with the geographic location of affected animals. The IS901-containing isolates were shown to be genotypically closely related, as they exhibit similar patterns in IR-typing and in RAPD analysis. In contrast, IS901-negative isolates (*M. a. hominissuis*) displayed distinct profiles in both molecular systems.

Key words: *Cervus elaphus hippelaphus*, DNA fingerprinting, mycobacteriosis, *Mycobacterium avium* subsp. *avium*, *Mycobacterium avium* subsp. *hominissuis*, *Mycobacterium avium* subsp. *paratuberculosis*, pathology, red deer.

INTRODUCTION

The *Mycobacterium avium* complex (MAC) comprises a group of related mycobacteria (*Mycobacterium avium*, *M. intracellulare*, and *M. species X*) that have been recognized as opportunistic and obligate pathogens of animals and humans. Within the MAC, *M. avium* are considered a major human and veterinary pathogen causing a variety of diseases including avian tuberculosis and mycobacteriosis, tuberculosis-like disease in humans, disseminated infections in immunocompromised patients such as those with HIV, lymphadenitis in humans and mammals, and paratuberculosis in ruminants. *Mycobacterium avium* has been recovered from different host species and body sites as well as from the environment, including

soil, water, dust, and air (Picardeau and Vincent, 1996). Based on differences in genotypic and growth characteristics, pathogenicity, and host range, *M. avium* species is subdivided into four subspecies, namely, *M. a. avium*, *M. a. hominissuis*, *M. a. silvaticum*, and *M. a. paratuberculosis* (Thorel, 1990; Mijls et al., 2002).

Several conventional and novel techniques for identification and typing of *M. avium* isolates are available for epidemiologic studies. Serotyping was the first method developed (Wolinsky and Schaeffer, 1973) followed by analyses of insertion sequences (IS901, IS1245, IS1311) (Kunze et al., 1992; Guerrero et al., 1995; Whittington et al., 1998). In addition, molecular approaches such as restriction fragment length polymorphism (RFLP) analysis with IS1245 (van Soolingen et

al., 1998) and IS901 (Dvorska et al., 2003) were standardized. Inverted repeat (IR) typing (Picardeau and Vincent, 1996) and randomly amplified polymorphic DNA (RAPD) analysis (Matsiota-Bernard et al., 1997; Pillai et al., 2001) appear to be suitable epidemiologic tools for studying *M. avium* infection.

In red deer (*Cervus elaphus hippelaphus*), *M. avium* species infection occurs only sporadically and is rarely transmissible (Thorel et al., 2001). Most reports refer to wild ruminants kept in captivity (Hime et al., 1971; De Lisle and Havill, 1985; Wards et al., 1991; Otter et al., 1995; Rohonczy et al., 1996; Quigley et al., 1997; Machackova et al., 2004; Machackova-Kopečna et al., 2005); only a few cases are reported in free-ranging red deer (Hopkins and McDiarmid, 1964; Matthews et al., 1981; Clifton-Hadley and Wilesmith, 1991; Pavlik et al., 2000a; Machackova et al., 2004). In contrast to infections with *M. bovis*, *M. avium* transmission is thought to occur only via the oral pathway (De Lisle et al., 1995). Therefore, the most common pathologic and clinical findings of *M. a. paratuberculosis* infection in red deer involve the gastrointestinal tract and associated lymph nodes and are characterized by persistent diarrhea and weight loss (Matthews et al., 1981). Lesions caused by *M. a. avium* and *M. a. hominissius* may be purulent, caseous, or granulomatous; although systemic disease is usually uncommon (Thorel et al., 2001), hematogenous spread to the liver and lungs may occur to produce miliary lesions and a terminal septicemia (Griffin, 1988). However, the isolation of *M. avium* from organs, lymph nodes, and fecal samples from deer without any clinical symptoms has been reported (Matthews et al., 1981; De Lisle and Havill, 1985; Quigley et al., 1997; Machackova-Kopečna et al., 2005).

The aim of this study was to analyze mycobacterial isolates and case and pathologic data from *M. avium*-infected red deer from Austria during 2001–2004.

MATERIALS AND METHODS

Between 2001 and 2004, 14 cases of mycobacteriosis in free-ranging red deer were observed. The affected animals, 13 adults of different ages (five hinds, eight stags) and one female fawn, had been shot by local hunters because of poor physical condition and clinical signs of diarrhea and severe weight loss. Eight of the 14 were single cases originating from different geographic regions in Austria. Six of the cases originated from two hunting areas with a high density of red deer. These two hunting areas are located in adjacent mountain valleys where animals share common feeding places in winter (Fig. 1).

Carcasses (without head) or various organs or tissue samples with gross lesions were submitted for post-mortem examination to Austrian veterinary laboratories. For the histopathologic evaluation, formalin-fixed tissues (from tuberculous lesions) were embedded in paraffin, sectioned at 3–5 μm , and stained with either hematoxylin and eosin or by the Ziehl-Neelsen method for light microscopic examination.

Mycobacterium a. avium and *M. a. hominissius* were isolated from gross lesions by cultivation on Middlebrook 7H11 plates supplemented with OADC enrichment. *Mycobacterium a. paratuberculosis* was isolated on Harrod's egg yolk medium with or without 2 g/ml Mycobactin. Isolates were phenotypically identified by biochemical tests and growth characteristics as described (Wayne and Kubica, 1986; Thorel et al., 1990; Mijs et al., 2002). Growth of *M. a. paratuberculosis* was confirmed by polymerase chain reaction (PCR) amplification of IS900 (Vary et al., 1990; Cousins et al., 1999). *Mycobacterium a. avium* and *M. a. hominissius* isolates were stored in Middlebrook 7H9 broth at -80°C until used in further studies.

For DNA extraction, single colonies of *M. a. avium* and *M. a. hominissius* were picked up from agar plates and cultivated in 10 ml Middlebrook 7H9 broth containing 1 mg D-cycloserine per ml. After overnight incubation at 37°C , cells were harvested by centrifugation ($14,000 \times G$, 20 min), washed twice with sterile phosphate buffered saline (PBS), and resuspended in 385 μl lysis buffer containing 20 mM Tris-HCl (pH 8.0), 1 mM ethylene diamine tetraacetate (EDTA), 30 mM dithiothreitol, 0.5% sodium dodecyl sulfate (SDS), and 0.4 mg proteinase K/ml. The mixture was incubated with agitation overnight at 55°C . DNA was isolated by cetyltrimethylammo-

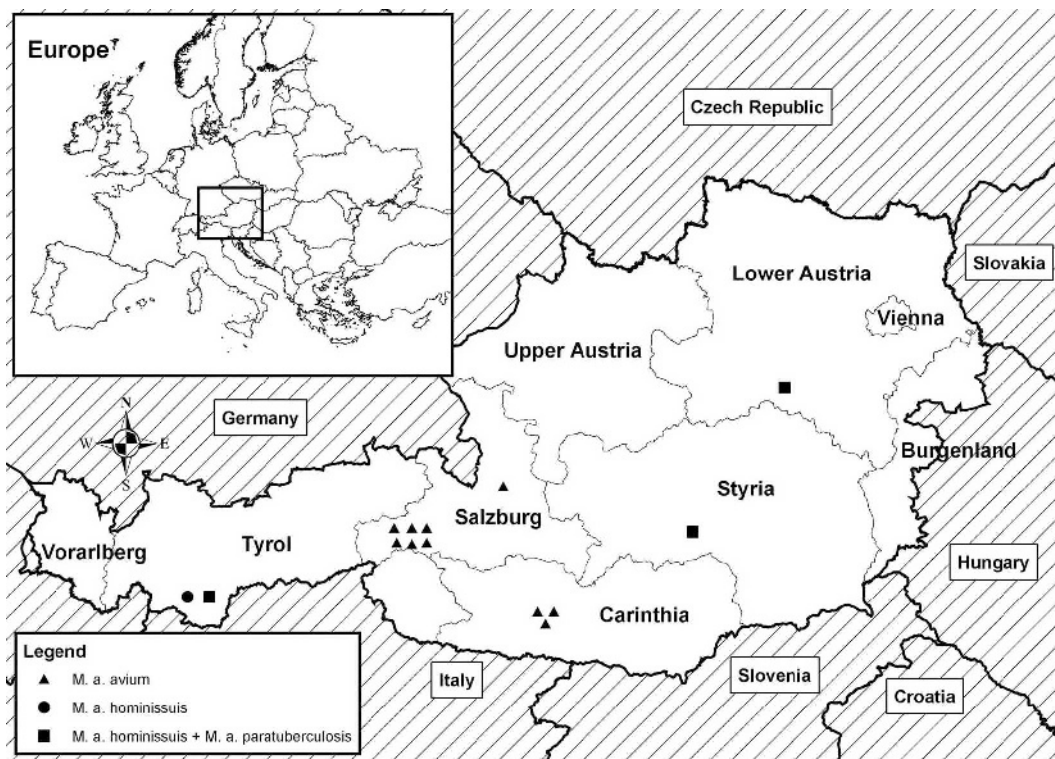


FIGURE 1. Geographic distribution of free-ranging red deer with *M. avium* mycobacteriosis in Austria.

nium bromide (CTAB) extraction as previously described (Kaltenböck et al., 1997). Phenol-chloroform extraction was followed by precipitation with 3 M sodium acetate and 96% ethanol. The DNA was pelleted, washed with 70% ethanol, and resuspended in 50 µl of distilled water.

DNA amplifications were performed with a GeneAmp PCR system 2400 (Perkin-Elmer Applied Biosystems, Branchburg, New Jersey, USA) in a 50 µl reaction mixture containing 1 mM MgCl₂, 1 mM of each dNTP, 5 µl of 10x PCR buffer, 1 Unit of Taq DNA polymerase (Promega, Mannheim, Germany), 20 pmol of each primer, and 5 µl of template.

Primers and amplification conditions for IS901 and macrophage-induced gene (*mig*) PCR were used as reported (Kunze et al., 1992; Beggs et al., 2000). For inverted repeat (IR) typing, PCR conditions and selected primers consisting of consensus sequences of the imperfect inverted repeats of IS1245 and IS1311 were used as described previously (Picardeau and Vincent, 1996). Amplified PCR products (10 µl) were analyzed by 2% agarose gel electrophoresis and ethidium bromide staining (Sigma, Vienna, Austria) and visualized by UV transillumination.

Random amplified polymorphic DNA (RAPD) analyses were performed by using RAPD primers 1–6 of the RAPD Analysis Primer Set and Ready-to-Go PCR beads (Amersham Pharmacia Biotech, Piscataway, New Jersey, USA) according to the manufacturer's instructions. In addition, RAPD primers IS1245A (Matsiota-Bernard et al., 1997) and OPE20 (Pillai et al., 2001) were included in the analysis. The cycling conditions were as follows: initial denaturation at 95 C for 5 min and 40 cycles of 1 min at 94 C, 1 min at 36 C, and 2 min at 72 C followed by a single 5-min extension at 72 C. Visualization of amplicons were performed as described above. To assess the reproducibility of the method, all RAPD experiments were performed twice. Results from RAPD were analyzed for the presence or absence of DNA bands, but band-staining intensity was not considered as a discriminatory factor.

RESULTS

Pathologic findings

At necropsy, all 14 carcasses had signs of diarrhea, severe weight loss, and

emaciation. Lymphadenitis associated with enlarged intestinal lymph nodes was present in all animals. In 11 cases, numerous purulent, caseous, or granulomatous lesions of different sizes were found in and on the thickened intestinal wall, mainly of the ileum, cecum, and anterior part of the colon. Lesions within the mesenteric lymph nodes were variable in size, ranging from 1 to 2 mm to large space-occupying lesions up to 12 cm in diameter that totally replaced the lymphoid tissue with an encapsulated necrotic mass. In three individuals, lesions were restricted to the intestinal tract, while all other cases had multiple lesions in both body cavities mainly affecting the lungs, pleura, liver, and mediastinal lymph nodes. Subcutaneous tuberculous abscesses were found in two of these cases, and a clinically apparent, tuberculous polyarthritis was seen in one case; all were infected by *M. a. avium*. One male animal infected by *M. a. avium* showed multiple tuberculous abscesses in the reproductive organs, and the scrotum was thickened.

The microscopic lesions in the intestinal wall were multifocal granulomatous inflammatory lesions composed of central areas of caseo-calcified necrosis surrounded by epithelioid cells, Langhans-type multinucleated giant cells, and lymphocytes. Large numbers of acid-fast bacilli were demonstrated, especially in these macrophage-like cells. In some individuals, numerous giant cells could be found, whereas only a few were present in the tuberculous lesions of other animals.

Molecular typing

Results obtained by molecular typing of MAC isolates are summarized in Table 1. *Mycobacterium a. avium* and *M. a. hominissuis* were recovered from affected lymph nodes of 10 and four animals, respectively. Three animals with *M. a. hominissuis* infection also were infected with *M. a. paratuberculosis*, as determined by growth characteristics and IS900 PCR. Although all *M. a. avium* and *M. a. hominissuis* isolates contained the *mig*

TABLE 1. Phenotypic and genotypic characteristics of *Mycobacterium avium avium* and *Mycobacterium avium hominissuis* isolated from free-ranging red deer.

No.	Year	Sex/age	Species	Location	Phenotype	IS901 ^a	<i>mig</i> ^b	IR/RAPD ^c
185	2001	Female/12a	Red deer	Salzburg	<i>M. a. avium</i>	+	+	A1
268	2001	Male/8a	Red deer	Salzburg	<i>M. a. avium</i>	+	+	A2
277	2001	Female/2a	Red deer	Salzburg	<i>M. a. avium</i>	+	+	A3
50,511	2001	Female/1a	Red deer	Salzburg	<i>M. a. avium</i>	+	+	A3
58,264	2001	Male/12a	Red deer	Salzburg	<i>M. a. avium</i>	+	+	A1
58,763	2001	Female/4a	Red deer	Salzburg	<i>M. a. avium</i>	+	+	A1
2,534	2004	Female/2a	Red deer	Salzburg	<i>M. a. avium</i>	+	+	A1
5,325	2001	Male/11a	Red deer	Carinthia	<i>M. a. avium</i>	+	+	A3
9,992	2001	Male/2a	Red deer	Carinthia	<i>M. a. avium</i>	+	+	A3
127	2003	Male/5a	Red deer	Carinthia	<i>M. a. avium</i>	+	+	A3
8,464	2001	Female/7a	Red deer	Tyrol	<i>M. a. hominissuis</i>	—	+	B
438	2002	Female/3a	Red deer	Tyrol	<i>M. a. hominissuis</i>	—	+	C
					<i>M. a. paratuberculosis</i>	ND ^d	ND	ND
18	2002	Male/1a	Red deer	Lower Austria	<i>M. a. hominissuis</i>	—	+	D
					<i>M. a. paratuberculosis</i>	ND	ND	ND
126	2002	Male/3a	Red deer	Styria	<i>M. a. hominissuis</i>	—	+	E
					<i>M. a. paratuberculosis</i>	ND	ND	ND

^a IS901 = Insertion sequence 901.

^b *mig* = macrophage-induced gene.

^c IR/RAPD = Inverted repeat/Random amplified polymorphic DNA analysis.

^d ND = not determined.

gene, IS901 was detected only in *M. a. avium* isolates. Fingerprint (RAPD) patterns of *M. a. avium* and *M. a. hominissuis* isolates were evaluated using the criteria established by Gillespie et al. (1997). In our study only primer 1245A consistently provided a set of unique and well-defined polymorphic DNA fragments. *Mycobacterium a. avium* isolates were shown to be genotypically closely related (cluster A), as they exhibit similar but not identical banding patterns in RAPD analysis. Cluster A was composed of three groups (A1, A2, A3). In contrast, *M. a. hominissuis* isolates displayed distinct profiles in RAPD analysis (B-E) (Table 1). Molecular typing of *M. a. avium* and *M. a. hominissuis* isolates by RAPD was confirmed by IR typing, although the latter method was shown to be less discriminating and did not show any grouping (A1, A2, and A3) within cluster A.

DISCUSSION

The pathologic findings in our report are similar to those described by Griffin (1988) and Hime et al. (1971). Special attention should be drawn to the enlarged intestinal lymph nodes, which supports the hypothesis of oral infection (De Lisle et al., 1995). Quigly et al. (1997) observed that *M. a. avium* is predominantly isolated from lesions in the retropharyngeal lymph nodes, but in our study heads from infected animals were not available for post-mortem examination. In a majority of our cases, we observed generalized mycobacteriosis with caseonecrotic granulomatous lesions in multiple lymph nodes and organs. These pathologic findings differ from those reported in red deer infected with *M. bovis*, which primarily involved putrid abscesses in lymph nodes (Lugton et al., 1998), and *M. a. paratuberculosis*, where pathognomic lesions were associated with the intestine. *Mycobacterium a. hominissuis* and *M. a. paratuberculosis* were concurrently isolated from lymph nodes of three animals (Table 1), prevent-

ing a clear association of pathologic findings. However, mixed infections with *M. a. avium* and *M. a. paratuberculosis* in red deer without pathognomic lesions of either have been reported recently from the Czech Republic (Machackova-Kopecná et al., 2005).

A variety of molecular methods were used to characterize and analyze the relatedness of *M. a. avium* and *M. a. hominissuis* isolates. Detection of *mig* was performed because it is the only well-characterized virulence factor currently identified in *M. a. avium*. The specific role of this gene has not been elucidated, but it has been associated with enhanced growth of organisms residing inside macrophages (Plum et al., 1997). The *mig* gene also has been reported to be specific for *M. a. avium*, which suggests that its detection may provide a simple and useful way of differentiating *M. a. avium* from other mycobacteria (Beggs et al., 2000). However, the *mig* gene can also be detected in *M. a. hominissuis* isolates.

Relatedness of *M. a. avium* and *M. a. hominissuis* isolates was established by IR typing and RAPD analysis. For IR typing, it has been shown that the selection of primers for the repetitive elements IS1245 and IS1311, which display high-level homologies, increased the number of potential priming sites. Consequently, banding patterns varied, as there were differences in the copy number of IS between strains (Picardeau and Vincent, 1996). In our study, IR typing was shown to be less discriminating compared to RAPD analysis, which suggests a low number of IS present in tested *M. a. avium* isolates. This is in agreement with previous studies proposing the reservation of the designation *M. a. avium* for bird-type strains with characteristic three-band IS1245 RFLP patterns (Mijls et al., 2002). Infection of free-ranging red deer by bird-type strains (*M. a. avium*) is supported by the occurrence of the IS901 element in all tested *M. a. avium* isolates. Previous studies have indicated that IS901-positive

strains are most frequently isolated from birds and that IS901 is present in only a low percentage of environmental and human/porcine strains (*M. hominissuis*; Pavlik et al., 2000b).

Despite the obvious low copy number of IS1245 in *M. a. avium* isolates, only primer IS1245A originating from a primer set amplifying IS1245 in high-stringency conditions provided well-defined polymorphic DNA fragments. This might be explained by amplification of interinsertional regions, but given the low annealing temperature, it may have resulted from nonspecific hybridization. *Mycobacterium a. hominissuis* isolated from red deer exhibited polymorphic banding patterns in RAPD, which suggests that infections were not clonal in origin. In contrast, some of the *M. a. avium* isolates displayed identical patterns, indicating that these isolates possibly originate from the same environmental or host reservoir, or from the same infected individual. This is supported by the fact that isolates with identical or similar profiles were isolated from individuals originating from the same or contiguous geographic areas. In these areas, transmission and infection may occur during winter when high deer concentrations exist on few feeding sites. Although most reports on *M. a. avium* mycobacteriosis refer to red deer held in captivity (De Lisle et al., 1995; Quigley et al., 1997; Machackova-Kopečna et al., 2005), high level of crowding at feeding sites might also produce ideal conditions for transmission and maintenance of the disease.

In our cases, we have not identified a specific infectious source, but fecal contamination of feeding sites by birds should be considered (Nie et al., 1982; Hejlíček et al., 1994). *Mycobacterium a. avium* infections in red deer have not been reported previously in Austria; the reasons for the occurrence of these recent clinical cases are unknown. As *M. a. avium* has been isolated from tuberculosis lesions and lymph nodes of red deer without any

gross lesions (Machackova-Kopečna et al., 2005), it is likely that *M. a. avium* infections in free-ranging Austrian red deer might be underdiagnosed. Hunters in the affected areas as well as in regions supposed to be free from tuberculosis should be trained to recognize suspicious lesions.

ACKNOWLEDGMENTS

The authors thank B. Fidler, W. Parsch, K. Sick, and A. Deutz for collecting and submitting samples.

LITERATURE CITED

- BEGGS, M. L., R. STEVANOVA, AND K. D. EISENACH. 2000. Species identification of *Mycobacterium avium* complex isolates by a variety of molecular techniques. *Journal of Clinical Microbiology* 38: 508–512.
- CLIFTON-HADLEY, R. S., AND J. W. WILESMITH. 1991. Tuberculosis in deer: A review. *Veterinary Record* 129: 5–12.
- COUSINS, D. V., R. WITTINGTON, I. MARSH, A. MASTERS, R. J. EVANS, AND P. KLUVER. 1999. *Mycobacteria* distinct from *Mycobacterium avium* subsp. *paratuberculosis* isolated from the faeces of ruminants possess IS900-like sequences detectable by IS900 polymerase chain reaction: Implications for diagnosis. *Molecular and Cellular Probes* 13: 431–442.
- DE LISLE, G. W., AND P. F. HAVILL. 1985. *Mycobacteria* isolated from deer in New Zealand from 1970–1983. *New Zealand Veterinary Journal* 33: 138–140.
- , M. A. JOYCE, G. F. YATES, B. J. WARDS, AND F. P. HOYLE. 1995. *Mycobacterium avium* infection in a farmed deer herd. *New Zealand Veterinary Journal* 43: 1–3.
- DVORSKA, L., T. J. BULL, M. BARTOS, L. MATLOVA, P. SVASTOVA, R. T. WESTON, J. KINTR, I. PARMOVA, D. VAN SOOLINGEN, AND I. PAVLIK. 2003. A standardised restriction fragment length polymorphism (RFLP) method for typing *Mycobacterium avium* isolates links IS901 with virulence for birds. *Journal of Microbiological Methods* 55: 11–27.
- GILLESPIE, B. E., B. M. JAYARAO, AND S. P. OLIVER. 1997. Identification of *Streptococcus* species by randomly amplified polymorphic deoxyribonucleic acid fingerprinting. *Journal of Dairy Science* 80: 471–476.
- GRIFFIN, J. F. T. 1988. The aetiology of tuberculosis and mycobacterial diseases in farmed deer. *Irish Veterinary Journal* 42: 23–26.
- GUERRERO, C., C. BERNASCONI, D. BURKI, T. BODMER, AND A. TELENTI. 1995. A novel insertion element

- from *Mycobacterium avium*, IS1245, is a specific target for analysis of strain relatedness. *Journal of Clinical Microbiology* 33: 304–307.
- HEJLICEK, K., F. TREML, AND L. CERNY. 1994. Epidemiology and pathogenesis of avian mycobacteriosis in rooks (*Corvus frugileus*). *Veterinarni Medicina* 39: 337–344 [In Czech].
- HIME, J. M., I. F. KEYMER, E. BOUGHTON, AND K. J. BIRN. 1971. Tuberculosis in a deer (*Cervus elaphus*) due to an atypical *Mycobacterium*. *Veterinary Record* 88: 616–617.
- HOPKINSON, F., AND A. MCDIARMID. 1964. Tuberculosis in a free-ranging red deer, *Cervus elaphus* in Scotland. *Veterinary Record* 76: 1521–1522.
- KALTENBÖCK, B., N. SCHMEER, AND R. SCHNEIDER. 1997. Evidence for numerous *omp1* alleles of porcine *Chlamydia trachomatis* and novel chlamydial species obtained by PCR. *Journal of Clinical Microbiology* 35: 1835–1841.
- KUNZE, Z. M., F. PORTAELS, AND J. J. MCFADDEN. 1992. Biologically distinct subtypes of *Mycobacterium avium* differ in possession of insertion sequence IS901. *Journal of Clinical Microbiology* 30: 2366–2372.
- LUGTON, I. W., P. R. WILSON, R. S. MORRIS, AND G. NUGENT. 1998. Epidemiology and pathogenesis of *Mycobacterium bovis* infection of red deer (*Cervus elaphus*) in New Zealand. *New Zealand Veterinary Journal* 46: 147–156.
- MACHACKOVA, M., P. SVASTOVA, J. LAMKA, I. PARMOVA, V. LISKA, J. SMOLIK, O. FISCHER, AND I. PAVLIK. 2004. Paratuberculosis in farmed and free-living wild ruminants in the Czech Republic (1999–2001). *Veterinary Microbiology* 101: 225–234.
- MACHACKOVA-KOPECNA, M., M. BARTOS, M. STRAKA, V. LUDVIK, P. SVASTOVA, J. ALVAREZ, J. LAMKA, I. TRCKA, F. TREML, I. PARMOVA, AND I. PAVLIK. 2005. Paratuberculosis and avian tuberculosis infections in one red deer farm studied by IS900 and IS901 RFLP analysis. *Veterinary Microbiology* 25: 261–268.
- MATSIOTA-BERNARD, P., S. WASER, P. T. TASSIOS, A. KYRIAKOPOULOS, AND N. J. LEGAKIS. 1997. Rapid discrimination of *Mycobacterium avium* strains from AIDS patients by randomly amplified polymorphic DNA analysis. *Journal of Clinical Microbiology* 35: 1585–1588.
- MATTHEWS, P. R. J., MCDIARMID, AND P. COLLINS. 1981. Mycobacterial infections in various species of deer in the United Kingdom. *British Veterinary Journal* 137: 60–66.
- Mijs, W., P. DE HAAS, R. ROSSAU, T. VAN DER LAAN, L. RIGOUTS, F. PORTAELS, AND D. VAN SOOLINGEN. 2002. Molecular evidence to support a proposal to reserve the designation *Mycobacterium avium* subsp. *avium* for bird-type isolates and “*M. avium* subsp. *Hominissuis*” for the human/porcine type of *M. avium*. *International Journal of Systematic and Evolutionary Microbiology* 52: 1505–1518.
- NIE, G. J., J. T. LUMEIJ, G. M. DORRESTEIN, W. T. C. WOLVEKAMP, P. ZWART, AND J. W. E. STAM. 1982. Tuberculosis in raptor birds. I. Clinical cases and different diagnosis. *Tijdschrift voor Diergeneeskunde* 107: 563–572 [In Dutch].
- OTTER, A., R. MUNRO, AND N. PALMER. 1995. Mycobacterial meningitis as a cause of ataxia and weight loss in a deer. *Veterinary Record* 18: 180.
- PAVLIK, I., J. BARTL, L. DVORSKA, P. SVASTOVA, R. DU MAINE, M. MACHACKOVA, W. Y. AYELE, AND A. HORVATHOVA. 2000a. Epidemiology of paratuberculosis in wild ruminants studied by restriction fragment length polymorphism in the Czech Republic during the period 1995–1998. *Veterinary Microbiology* 77: 231–251.
- , P. SVASTOVA, J. BARTL, L. DVORSKA, AND I. RYCHLIK. 2000b. Relationship between IS901 in the *Mycobacterium avium* complex strains isolated from birds, animals, humans, and the environment and virulence for poultry. *Clinical and Diagnostic Laboratory Immunology* 7: 212–217.
- PICARDEAU, M., AND V. VINCENT. 1996. Typing of *Mycobacterium avium* isolates by PCR. *Journal of Clinical Microbiology* 34: 389–392.
- PILLAI, S. R., B. M. JAYARO, J. D. GUMMO, E. C. HUE, JR., D. TIWARI, J. R. STABEL, AND R. W. WHITLOCK. 2001. Identification and sub-typing of *Mycobacterium avium* subsp. *paratuberculosis* and *Mycobacterium avium* subsp. *avium* by randomly amplified polymorphic DNA. *Veterinary Microbiology* 79: 275–284.
- PLUM, G., M. BRENDEN, J. E. CLARK-CURTIS, AND G. PULVERER. 1997. Cloning, sequencing, and expression of the *mig* gene of *Mycobacterium avium*, which codes from a secreted macrophage-induced protein. *Infection and Immunity* 65: 4548–4557.
- QUIGLEY, F. C., E. COSTELLO, O. FLYNN, A. GOGARTY, J. MCGUIRK, A. MURPHY, AND J. EGAN. 1997. Isolation of mycobacteria from lymph node lesions in deer. *Veterinary Record* 141: 516–518.
- ROHONCZY, E. B., A. V. BALACHANDRAN, T. D. DUKES, J. B. PAYEUR, J. C. RHYAN, D. A. SAARI, T. L. WHITING, S. H. WILSON, AND J. L. JARNAGIN. 1996. A comparison of gross pathology, histopathology, and mycobacterial culture for the diagnosis of tuberculosis in elk (*Cervus elaphus*). *Canadian Journal of Veterinary Research* 60: 108–114.
- THOREL, M. F., M. KRICHEVSKY, AND V. V. LEVY-FREBAULT. 1990. Numerical taxonomy of mycobactin-dependent mycobacteria, emended description of *Mycobacterium avium*, and description of *Mycobacterium avium* subsp. *avium* subsp. *nov.*, *Mycobacterium avium* subsp. *paratuberculosis* subsp. *nov.*, and *Mycobacterium avium* subsp. *silvaticum* subsp. *nov.* *International*

- al Journal of Systematic Bacteriology 40: 254–260.
- , H. F. HUCHZERMAYER, AND A. L. MICHEL. 2001. *Mycobacterium avium* and *Mycobacterium intracellulare* infection in mammals. Scientific and Technical Review of the Office International des Epizooties 20: 204–218.
- VAN SOOLINGEN, D., J. BAUER, V. RITACCO, S. C. LEO, I. PAVLIK, V. VINCENT, N. RASTOGI, A. GORI, T. BODMER, C. GARZELLI, AND M. J. GARCIAND. 1998. IS1245 restriction fragment length polymorphism typing of *Mycobacterium avium* isolates: Proposal for standardization. Journal of Clinical Microbiology 36: 3051–3054.
- VARY, P. H., P. R. ANDERSEN, E. GREEN, J. HERMONTAYLER, AND J. MCFADDEN. 1990. Use of highly specific DNA probes and the PCR reaction to detect *Mycobacterium paratuberculosis* in Johne's disease. Journal of Clinical Microbiology 28: 933–937.
- WARDS, B. J., G. W. DE LISLE, G. F. YATES, AND D. J. DAWSON. 1991. Characterization by restriction endonuclease analysis and seroagglutination of strains of *Mycobacterium avium* and *Mycobacterium intracellulare* obtained from farmed deer. American Journal of Veterinary Research 52: 197–201.
- WAYNE, L. G., AND G. P. KUBICA. 1986. Genus *Mycobacterium* Lehmann and Neumann 1896, 363AL. In Bergey's manual of systematic bacteriology, 2, P. H. A. Sneath, N. S. Mair, M. E. Sharpe and J. G. Holt (eds.). Williams & Wilkins, Baltimore, Maryland, pp. 1436–1457.
- WHITTINGTON, R., I. MARSH, E. CHOY, AND D. COUSINS. 1998. Polymorphism in IS1311, an insertion sequence common to *Mycobacterium avium* and *M. avium* subsp. *paratuberculosis*, can be used to distinguish between and within these species. Molecular and Cellular Probes 12: 349–358.
- WOLINSKY, E., AND W. B. SCHAEFFER. 1973. Proposed numbering scheme for mycobacterial serotypes by agglutination. International Journal of Systematic Bacteriology 23: 182–183.

Received for publication 11 October 2005.