

## **EFFECTS OF PROTOSTRONGYLUS SP. AND PNEUMOCYSTIS SP. ON THE PULMONARY TISSUE AND THE CONDITION OF MOUNTAIN AND BROWN HARES FROM FINLAND**

Authors: Laakkonen, Juha, Nyysönen, Tuomo, Hiltunen, Matti, Kauhala, Kaarina, Nikander, Sven, et al.

Source: Journal of Wildlife Diseases, 42(4) : 780-787

Published By: Wildlife Disease Association

URL: <https://doi.org/10.7589/0090-3558-42.4.780>

---

BioOne Complete ([complete.BioOne.org](https://complete.BioOne.org)) is a full-text database of 200 subscribed and open-access titles in the biological, ecological, and environmental sciences published by nonprofit societies, associations, museums, institutions, and presses.

Your use of this PDF, the BioOne Complete website, and all posted and associated content indicates your acceptance of BioOne's Terms of Use, available at [www.bioone.org/terms-of-use](https://www.bioone.org/terms-of-use).

Usage of BioOne Complete content is strictly limited to personal, educational, and non - commercial use. Commercial inquiries or rights and permissions requests should be directed to the individual publisher as copyright holder.

---

BioOne sees sustainable scholarly publishing as an inherently collaborative enterprise connecting authors, nonprofit publishers, academic institutions, research libraries, and research funders in the common goal of maximizing access to critical research.

# EFFECTS OF *PROTOSTRONGYLUS* SP. AND *PNEUMOCYSTIS* SP. ON THE PULMONARY TISSUE AND THE CONDITION OF MOUNTAIN AND BROWN HARES FROM FINLAND

Juha Laakkonen,<sup>1,7</sup> Tuomo Nyyssönen,<sup>2</sup> Matti Hiltunen,<sup>3</sup> Kaarina Kauhala,<sup>4</sup> Sven Nikander,<sup>5</sup> and Timo Soveri<sup>6</sup>

<sup>1</sup> Haartman Institute, Department of Virology, University of Helsinki, Helsinki, Finland

<sup>2</sup> Oulu Regional Unit, National Veterinary and Food Research Institute, Oulu, Finland

<sup>3</sup> Joensuu Game and Fisheries Research, Finnish Game and Fisheries Research Institute, Joensuu, Finland

<sup>4</sup> Turku Game and Fisheries Research, Finnish Game and Fisheries Research Institute, Turku, Finland

<sup>5</sup> Department of Basic Veterinary Sciences, University of Helsinki, Helsinki, Finland

<sup>6</sup> Saari Unit, Department of Clinical Veterinary Sciences, University of Helsinki, Saarentaus, Finland

<sup>7</sup> Corresponding author (email: juha.laakkonen@helsinki.fi)

**ABSTRACT:** Mountain hares (*Lepus timidus*) and brown hares (*Lepus europaeus*) shot by hunters in several game management districts in southern and central Finland during the hunting season from September to the end of February 1998–2001 were examined for *Protostrongylus* sp. and *Pneumocystis* sp. Of the mountain hares, 96.5% (194/201) were infected with the lungworm *Protostrongylus* sp. and 16.9% (32/189) had cyst forms of the fungus *Pneumocystis* sp. in the lungs. The prevalence of the lungworm and fungus in brown hares was 60% (18/30) and 20.0% (6/30), respectively. The tissue changes associated with the lungworms were macroscopically and microscopically well demarcated. The majority and most severe histopathologic changes were seen at the distal part of the caudal lobes. Inflammatory cells, mainly eosinophils and macrophages, and in lesser degree neutrophils, lymphocytes, and plasma cells were typical findings in the worm-infected tissue. The condition and weight of the hare did not show any significant association with the intensity of the lungworm infection. All *Pneumocystis*-infected mountain hares were young, and their condition and weight correlated negatively with the intensity of the infection. The intensity of the *Pneumocystis* infection did not correlate with that of the lungworm infection. Within a tissue section, a slight but significant positive correlation was observed between presence of cysts and inflammatory cells.

**Key words:** Hares, histopathology, lungworm, nematode.

## INTRODUCTION

The mountain hare (*Lepus timidus*) is one of the most common medium-sized mammals in Finland, and it is distributed throughout the country (Kauhala et al., 2005). Although it is an important game animal in Finland, we know relatively little about the factors contributing to the population dynamics of this species. Our recent study (Kauhala et al., 2005) showed that the population density and productivity of hares is low in southern Finland. The reproductive rate is highest in central Finland, but in the northern part of the country survival rates are low. As part of our studies on the ecology of mountain hares in Finland, we examined by histopathology lungs of mountain hares and brown hares (*Lepus europaeus*) shot by hunters

for *Protostrongylus* sp. and *Pneumocystis* sp. These organisms were chosen because lung nematodes, which have an indirect life cycle with snails as intermediate hosts, are known to be prevalent in Finnish mountain hares (Soveri and Valtonen, 1983), and their effect on the host condition has been suggested to be most severe in high density populations (Soveri et al., 1992). The lungs were specifically examined for *Pneumocystis* because these organisms appear to be prevalent in many wild and laboratory lagomorph species (Laakkonen, 1998) but wild mountain hares had not previously been examined for this fungus. Our aim was to study the effect of *Protostrongylus* sp. and *Pneumocystis* sp. on the two hosts, and gain information on the possible differences in the intensity of infections in different sites.

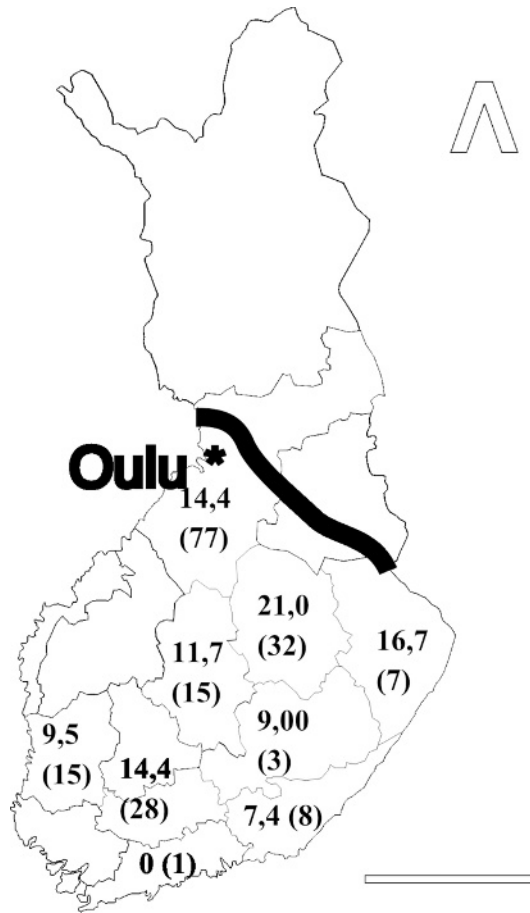


FIGURE 1. Map of Finland showing the game management districts. The numbers describe the mean intensity of the infection in mountain hares within the game animal district (sample size in parentheses). The northern and southern Häme districts were treated as one (the combined sample size 28). The mountain hare is found throughout the country but the brown hare occurs only south of the thick line. Scale bar=200 km.

## MATERIAL AND METHODS

Samples were collected from 201 mountain hares and 30 brown hares shot by hunters in several game management districts in southern and central Finland as far north as the game management district of Oulu (Fig. 1). Hares were shot during the hunting season from September to the end of February 1998–2001. The animals were divided into two age groups, young (under 10 mo) and old (over 1 yr) by palpation of the growing cartilage of the ulna (Kauhala and Soveri, 2001). The relationship between the body weight and length of the hind foot was used as a measure of condition (Iason, 1990; Kauhala et al., 2005).

The lung samples were stored frozen (−20 C), and thawed overnight before examination. Macroscopically, demarcated green

and brown areas were visible. Abnormalities in tissues caused by the lungworms were recorded as changes (in percentage) in the parenchyma for each lobe, separately. Six tissue samples were taken for histologic examination. Samples were taken from the distal parts of both caudal lobes, in the middle of both cranial lobes, from the distal part of the left cranial lobe, and from the middle of the accessory lobe. The tissue specimens were fixed in 10% neutral buffered formalin, dehydrated, and embedded in paraffin. Then, 5 µm sections were cut and stained with hematoxylin and eosin (H&E) and Gomori's methenamine silver (GMS) stains (Grocott, 1955) for light microscopy. The area of the sections was 45–65 mm<sup>2</sup>.

The cyst forms of *Pneumocystis* visible in the GMS stained sections were counted, and

the intensity of the infection for each section separately was categorized as follows: 0 = <5 cysts; 1 = 5–20 cysts; 2 = 21–80 cysts and 3 = >80 cysts. Individual *Pneumocystis* organisms are often difficult to identify if only a few cyst forms are visible. Thus, findings of less than 5 cysts were grouped together with the no cysts found category. The other intensity categories were chosen based on cyst findings from other wild mammals (Laakkonen and Soveri, 1995). The sum of the intensity estimates from the six histological slides (maximum 18) was the estimate used to describe the intensity of *Pneumocystis* infection in an individual hare.

The intensity of the lungworm infection was determined separately for eggs, larvae, and adult worms for each section. The four intensity classes were as follows: 0 = no eggs, larvae, or adult worms were visible in the section; 1 = 1–20 eggs/larvae or 1 adult; 2 = 21–100 eggs/larvae or 2–5 adults; 3 = >100 eggs/larvae, or >5 adults. The intensity parameter for each hare was the sum of the intensity estimates of the three organism stages. With six sections examined from each hare, the maximum intensity score for an individual was 54.

The extent of histopathologic changes (necrosis and presence of inflammatory cells) in relation to *Pneumocystis* and lungworms was also estimated on a scale from zero to three (no, few, relatively extensive, and extensive changes).

The one-way analysis of variance was used to test differences in the intensity of the lungworm and *Pneumocystis* infections between different game management districts, and the effects of winter feeding and predation (see Kauhala et al., 2005) on the lungworm intensities in hares. The relationship between sex and age on lungworm intensities was analyzed with the *t*-test. The interactions between these host parameters, winter feeding, and different districts were not analyzed due to the low sample size in some districts. The Pearson correlation test was used to test the effect of body weight and condition of the hare on the lungworm and *Pneumocystis* intensities. Variance analyses with repeated measures were used to analyze differences in infection intensities of these two organism groups and the extent of pathologic changes between the various lung lobes. The association of lungworm infection with the necrotic tissue, and presence of inflammatory cells was analyzed with logistic regression. Chi-square test was used to study the relation between *Pneumocystis* infection, necrotic tissue, and the inflammatory cells within each lobe. In all

tests,  $P < 0.05$  was considered statistically significant.

## RESULTS

The prevalence of cyst forms of *Pneumocystis* sp. in the GMS-stained sections in mountain hares was 16.9% (32/189). All infected mountain hares were young, but there was no sex-related difference in prevalence. The condition ( $P = 0.02$ ) and weight ( $P = 0.004$ ) of the hare correlated negatively with the intensity of the *Pneumocystis* infection, but there was no significant correlation between the lungworm and *Pneumocystis* intensities. The intensity of the *Pneumocystis* infection was highest in the sections taken from the middle part of the lobes. Within a tissue section, a significant positive correlation was observed between cysts and inflammatory cells ( $P = 0.002$ ). A significant negative correlation ( $P = 0.05$ ) was observed between cysts and the necrotic tissue in sections taken from the distal part of the caudal lobes. There was no significant difference in the intensity of the *Pneumocystis* infection in hares between the game management districts ( $P = 0.06$ ).

The overall prevalence of *Pneumocystis* sp. in brown hares was 20.0% (6/30). Only one young brown hare was infected.

The overall prevalence of the nematode *Protostrongylus* sp. in mountain hares estimated by histopathology was 96.5% (194/201). The highest intensity of infection score in an individual hare was 37. None of the host variables examined (sex, age, weight, and condition) correlated significantly with the intensity of infection. The intensity of infection varied significantly ( $P < 0.001$ ) among the game management districts (Fig. 1).

The prevalence of *Protostrongylus* sp. in brown hares was 60.0% (18/30). Adult brown hares (15/21) were not significantly ( $P = 0.12$ ) more often infected than the young ones (3/9). The highest intensity of infection in an individual brown hare was

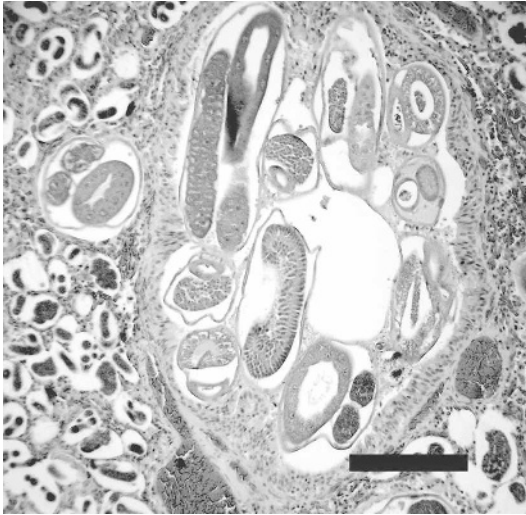


FIGURE 2. Adult lungworm in bronchiole. Eggs and first stage larvae in adjacent alveoli. Bar=200  $\mu$ m.

10. Due to the small sample size, the effects of other variables were not tested statistically.

Macroscopically, lungs with lungworms had well demarcated areas with a mixture of green and brown. Most of the pathologic changes were seen at the distal part of the caudal lobes. In the mildest case, macroscopic changes were visible only in one lobe. In the most severe cases, the edges of all lobes had visible changes covering approximately half of the lung surface. Most hares with mild changes were young individuals, and all hares with no infection detected macroscopically or microscopically were young individuals. Of the mountain hares, 29 had no macroscopic changes typical for lungworm infection in their lungs, but in 22 of these, the infection was visible in histologic examination of lung tissues (six adult, 12 young, and one of unknown age).

The tissue changes caused by the lungworms were also microscopically demarcated. Eggs and stage 1 larvae (L1) were visible in alveoli, as well as adult worms in bronchioles (Fig. 2). In some cases, the entire affected tissue was full of different developmental stages. The bronchioles were often blocked by worms, inflamma-

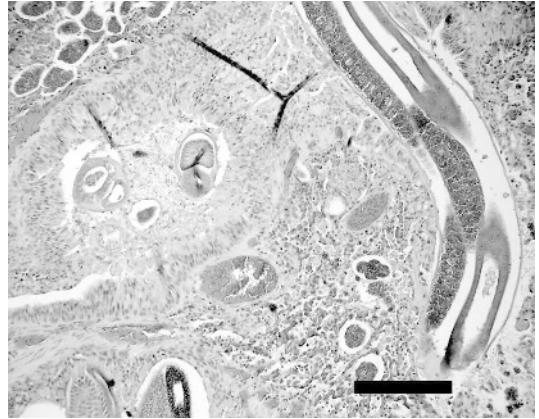

FIGURE 3. Bronchiole blocked by adult lungworm, inflammatory cells, and hypertrophic bronchial epithelium. Bar=200  $\mu$ m.

tory cells, and hypertrophic epithelium (Fig 3). In such sites, the lung tissue was airless and necrotic. In necrotic areas, no clear cell or tissue structures could be seen and they were poorly stained. The amount of worms and necrotic tissue was significantly higher in the distal part of the caudal lobes than that of the cranial lobe, and these findings were positively correlated in samples taken from the apex of the lung lobes.

Adult worms and larvae were also seen outside the areas where tissue changes were observed. In these areas, a common finding was aggregation of inflammatory cells around bronchioles and blood vessels. Alveolar egg aggregations did not normally cause any inflammatory changes but the adult worms and larvae in bronchioles were in some cases surrounded by inflammatory cells. The inflammatory cells were mainly eosinophils and macrophages, and in lesser degree neutrophils, lymphocytes, and plasma cells. Occasionally, a granulomatous inflammatory reaction consisting of eosinophils, macrophages and giant cells, was seen around a developmental stage of the worm. In few infection sites, findings included extensive aggregations of lymphoid cells. There was a positive correlation ( $P<0.001$ ) between presence of in-

TABLE 1. The parasite and fungal organisms found in mountain and European hares from Finland in 1998–2001.

Organism	<i>Lepus timidus</i> <sup>a</sup>		<i>Lepus europaeus</i>	
	+/ <i>n</i> (%) <sup>b</sup>		+/ <i>n</i> (%)	
	Adult	Young	Adult	Young
<i>Protostrongylus</i> sp.	95/95 (100)	80/87 (91.5)	15/21 (71.4)	3/9 (33.3)
<i>Pneumocystis</i> sp. <sup>a</sup>	0/87 (—)	32/81 (36.8)	5/21 (23.8)	1/9 (11)

<sup>a</sup> The total number of *L. timidus* examined for *Pneumocystis* sp. was 189. The age of 21 *L. timidus* that were negative for *Pneumocystis* sp. was not known.

<sup>b</sup> + = number of positive hares; *n* = number of hares examined; % = prevalence.

flammatory cells and the worm infection in the sections taken from the middle part of the lobes, but the correlation was negative ( $P<0.001$ ) in the sections taken from the distal part of the lobes.

DISCUSSION

To our knowledge, this is the first study of *Pneumocystis* sp. in mountain hares. The positive correlation observed between cysts and the presence of inflammatory cells within a tissue section, as well as a negative correlation between cysts and the weight and condition of the host, indicates that *Pneumocystis* infection has adverse effects on wild mountain hares. The relation between low body weight, condition index, and intensity of *Pneumocystis* infection has previously been reported mainly in debilitated adult brown hares and in young brown hares suffering from intestinal coccidiosis (Poelma and Broekhuizen, 1972). Settnes et al. (1986) reported that *Pneumocystis*-infected brown hares had died of coccidiosis or hemorrhagic gastritis, but one also had a substantial number of *Pneumocystis* organisms in the lung without any macroscopic lesions. Brown hare is one of the few wild animal species in which pneumonia caused by *Pneumocystis* sp. has been reported to be the cause of death (Blažek, 1960).

In this study, *Pneumocystis* was found to be more common in young mountain hares whereas only one young brown hare

was infected (Table 1). The contribution of age on *Pneumocystis* infection in wild animals appears to vary (Laakkonen, 1998), indicating that hosts immunocompromised due to very young or old age and/or primary infection are susceptible to *Pneumocystis* infection. There was no significant relation between the lungworms and *Pneumocystis* cysts in the present study, however, and the site of the most intense infections differed between the two pathogen groups. The significant changes in the host tissue caused by worms might have hindered the detection of *Pneumocystis* cysts.

*Pneumocystis* infection appears to be a relatively common finding in many lagomorph species. In this study, the prevalence in mountain hares was 16.9%. In brown hares, the prevalence has varied from 10.7% to 20.0% (Poelma and Broekhuizen, 1972; Settnes et al., 1986; this study). Spontaneous (without immunosuppression) *Pneumocystis* infections also are common in laboratory rabbits (Soulez et al., 1989).

Recent studies have shown antigenic and genetic diversity among *Pneumocystis* organisms infecting different mammal species (Cushion, 2004). *Pneumocystis carinii* is the name previously used for all organisms of this genus, but this species has only been found in rats. Further studies are warranted to characterize the *Pneumocystis* organisms found in hares, and to determine whether the same species occurs in the mountain and brown hares.

The high prevalence and wide distribution of lungworm infections has also been demonstrated in previous studies of hares from Finland. Soveri and Valtonen (1983) reported that the prevalence of *P. pulmonalis* in mountain hares was 87% and in brown hares 33%. High prevalence in hares has also been found elsewhere, especially in northern Sweden and Russia (Burgaz, 1969; Koghteva and Morozov, 1969). In contrast, all lung samples ( $n=116$ ) of brown hares from Germany were negative for lungworms (Frölich et al., 2003). Because of the histologic examination method, we did not try to identify the lung worm species. However, only *Protostrongylus pulmonalis* has been reported from Finland and Sweden (Burgaz, 1969; Soveri and Valtonen, 1983).

Compared to the results of previous studies (Soveri and Valtonen, 1983; Keith et al., 1986), the age or body weight of the hare had no significant effect on the intensity of the lungworm infection in hares in this study. This is at least partly explained by the fact that in the present study, intensity of the infection was determined histologically by the presence of different developmental stages of the worm. In our previous study (Soveri and Valtonen, 1983), intensity was estimated as the extent of macroscopic changes in the lungs, which seemed to increase with age. The sex of the hare had no effect on the intensity of infection in this, or in most other studies done in mountain or brown hares (Burgaz, 1969; Soveri and Valtonen, 1983; Keith et al., 1986).

The macroscopic and histologic changes caused by the lungworms were similar to those found in previous studies in mountain hares in Finland and Italy (Soveri and Valtonen, 1983; Battisti et al., 2000). An association between the necrosis and heavy worm infection speaks to harmful effects of these nematodes on the tissue. The damaged lung tissue is unlikely to heal into properly functioning lung tissue. The negative correlation between presence of inflammatory cells and the worm

infection intensity in the sections taken from the distal part of the lobes results from the presence of necrotic tissue in these sites. In the necrotic tissue sites, only the damaged tissue and worms are histologically visible. Apparently the worms can stay and reproduce also in necrotic areas. The alveolar egg groups usually do not cause an inflammatory reaction, which is thought to ensure the development of the eggs before hatching of the larvae (Pajersky et al., 1992).

Lung worm infection has only rarely been studied in areas where both mountain and brown hares occur (Burgaz, 1969; Soveri and Valtonen, 1983). In the present study, the prevalence of lungworm infection was lower in brown hares than those in mountain hares but only in a relatively few cases the two species were caught in the same area. The two hare species differ in their habitat and food requirements, which could lead to different exposure of brown hares to infected snails (Frölich et al., 2003). Spatial differences in the distribution of the snail intermediate host also might explain some of the differences in the intensity of the lungworm infection in mountain hares. The pathology of the infection also differs between the two host species. Extensive macroscopic changes are relatively rare in brown hares compared to mountain hares. Whether the lower prevalence and intensity of lungworm infection in brown hares is associated with the species-specific differences in immunity and/or with the relatively recent introduction of brown hares to the Finnish fauna is not known. In contrast to the findings of Pajersky et al. (1992), adult worms were found in all the parts of the lung where samples were collected.

Based on the histopathologic findings, most infected hares had both adults and larvae in the lungs. Adult worms were found throughout the hunting season from September to the end of February, at which time the ground has been covered by snow for several months. The intensity

of lungworm infection in snowshoe hares has been reported to increase during winter months due to the decrease in food quality (Kralka and Samuel, 1990). In this study, the effect of season on the lung worm infection in hares could not be assessed because all samples were collected during the hunting season from September to February.

Intense infections of lung tissue can compromise pulmonary function, which can affect the hare's ability to escape predators, especially in malnourished animals and during bad weather conditions. Also, lungworm infections can harmfully affect the lung tissue and its gas exchange capabilities, making hares susceptible to secondary bacterial infections and predation (Keith et al., 1986; Pajersky et al., 1992; Frölich et al., 2003). However, infection with *P. pulmonalis* or other lungworms are thought to be relatively benign in hares (see Muroma, 1954; Keith et al., 1986); they are not known to associate negatively with mountain hare population dynamics (Iason and Boag, 1988) unless there is also a lack of food leading to poor condition of the hares (Soveri et al., 1992). The relatively low sample size in some sites and years did not allow quantitative analyses on the effect of the lungworm or *Pneumocystis* infection on hare population dynamics, but relatively high mean worm intensities were found both in increasing and declining hare populations. The adverse effects of *Pneumocystis* infection on both the host tissue and the host condition indicate that these pulmonary pathogens could negatively impact mountain hare populations.

#### ACKNOWLEDGMENTS

We are grateful for all hunters providing lung samples, and Heikki and R. Koivunen for technical assistance. This study was financially supported by the Academy of Finland.

#### LITERATURE CITED

- BATTISTI, A., M. DI PAOLO, AND G. DI GUARDO. 2000. Pulmonary protostrongyliasis in a mountain hare from Italy. *Journal of Wildlife Diseases* 36: 367–369.
- BLÁŽEK, K. 1960. Die *Pneumocystis*—pneumonia beim feldhasen (*Lepus europeus* Pallas, 1778). *Zentralblatt Allgemeine Pathologie Anatomie* 101: 484–489.
- BURGAZ, I. 1969. A report on the presence of endoparasites in *Lepus timidus* and *Lepus europaeus* in Sweden. *Transactions IX International Congress of Game Biology*, Moscow, Russia, pp. 628–635.
- CUSHION, M. T. 2004. *Pneumocystis*: Unraveling the cloak of obscurity. *Trends in Microbiology* 12: 243–249.
- FRÖLICH, K., J. WISSER, H. SCHMÜSER, U. FEHLBERG, H. NEUBAUER, R. GRUNOW, K. NIKOLAU, J. PRIEMER, S. THIEDE, W. J. STREICH, AND S. SPECK. 2003. Epizootiologic investigations of European brown hares (*Lepus europaeus*) in selected populations from Schleswig–Holstein, Germany. *Journal of Wildlife Diseases* 39: 751–761.
- GROCOTT, R. G. 1955. A stain for fungi in tissue sections and smears. *American Journal of Clinical Pathology* 25: 975–979.
- IASON, G. R. 1990. The effects of size, age and a cost of early breeding on reproduction in female mountain hares. *Holarctic Ecology* 13: 81–89.
- , AND B. BOAG. 1988. Do intestinal helminths affect condition and fecundity of adult mountain hares? *Journal of Wildlife Diseases* 24: 599–605.
- KAUHALA, K., AND T. SOVERI. 2001. An evaluation of methods for distinguishing between juvenile and adult mountain hares *Lepus timidus*. *Wildlife Biology* 7: 295–300.
- , P. HELLE, AND M. HILTUNEN. 2005. Population dynamics of mountain hare *Lepus timidus* populations in Finland. *Wildlife Biology* 11: 299–307.
- KEITH, I. M., L. B. KEITH, AND J. R. GARY. 1986. Parasitism in a declining population of snowshoe hares. *Journal of Wildlife Diseases* 22: 349–363.
- KOGHTEVA, E. Z., AND V. F. MOROZOV. 1969. The influence of helminthiases on the populations of arctic hare (*Lepus timidus*) in the northwestern part of USSR. *Transactions IX International Congress Game Biology*, Moscow, Russia, p. 694.
- KRALKA, R. A., AND W. M. SAMUEL. 1990. The lungworm *Protostrongylus boughtoni* (Nematoda, Metastrongyloidea) in gastropod intermediate host and the snowshoe hare (*Lepus americanus*). *Canadian Journal of Zoology* 68: 2567–2575.
- LAAKKONEN, J. 1998. *Pneumocystis carinii* in wildlife. *International Journal for Parasitology* 28: 241–252.
- , AND T. SOVERI. 1995. Characterization of *Pneumocystis carinii* infection in *Sorex araneus* from southern Finland. *Journal of Wildlife Diseases* 31: 228–232.

- MUROMA, E. 1954. Metsäjäniksen tautisuus talvella 1953–1954. Suomen Riista 9: 81–84 (In Finnish).
- PAJERSKY, A., R. SVARC, AND M. MEDVEDOVA. 1992. Vital manifestations of the helminth *Protostrongylus communatus* (Diesing, 1851) in the lungs of hare and rabbit. Biologia (Bratislava) 47: 411–416.
- POELMA, F. G., AND S. BROEKHUIZEN. 1972. *Pneumocystis carinii* in hares, *Lepus europeus* Pallas in the Netherlands. Zeitung der Parasitenkunde 40: 195–202.
- SETTNES, O. P., K. ELVESTAD, AND B. CLAUSEN. 1986. *Pneumocystis carinii* Delanoe & Delanoe, 1912 found in lungs of freelifving animals in Denmark at autopsy. Nordisk Veterinaermedicin 38: 11–15.
- SOULEZ, B., E. DEI-CAS, P. CHARETT, G. MOUGEOT, M. CAILLAUX, AND D. CAMUS. 1989. The young rabbit: A nonimmunosuppressed model for *Pneumocystis carinii* pneumonia. Journal of Infectious Diseases 160: 355–356.
- SOVERI, T., AND M. VALTONEN. 1983. Endoparasites of hares (*Lepus timidus* L. and *L. europeus* Pallas) in Finland. Journal of Wildlife Diseases 19: 337–341.
- , M. AARNIO, S. SANKARI, AND V. HAUKISALMI. 1992. Blood chemistry and endoparasites of the mountain hare (*Lepus timidus* L.) in high and low density populations. Journal of Wildlife Diseases 28: 242–249.

Received for publication 9 June 2005.