

PATHOLOGY AND EPIDEMIOLOGY OF NATURAL WEST NILE VIRAL INFECTION OF RAPTORS IN GEORGIA

Authors: Ellis, Angela E., Mead, Daniel G., Allison, Andrew B., Stallknecht, David E., and Howerth, Elizabeth W.

Source: Journal of Wildlife Diseases, 43(2) : 214-223

Published By: Wildlife Disease Association

URL: <https://doi.org/10.7589/0090-3558-43.2.214>

BioOne Complete (complete.BioOne.org) is a full-text database of 200 subscribed and open-access titles in the biological, ecological, and environmental sciences published by nonprofit societies, associations, museums, institutions, and presses.

Your use of this PDF, the BioOne Complete website, and all posted and associated content indicates your acceptance of BioOne's Terms of Use, available at www.bioone.org/terms-of-use.

Usage of BioOne Complete content is strictly limited to personal, educational, and non - commercial use. Commercial inquiries or rights and permissions requests should be directed to the individual publisher as copyright holder.

BioOne sees sustainable scholarly publishing as an inherently collaborative enterprise connecting authors, nonprofit publishers, academic institutions, research libraries, and research funders in the common goal of maximizing access to critical research.

PATHOLOGY AND EPIDEMIOLOGY OF NATURAL WEST NILE VIRAL INFECTION OF RAPTORS IN GEORGIA

Angela E. Ellis,^{1,4} Daniel G. Mead,² Andrew B. Allison,² David E. Stallknecht,² and Elizabeth W. Howerth³

¹ Athens Veterinary Diagnostic Laboratory, College of Veterinary Medicine, The University of Georgia, Athens, Georgia 30602, USA

² Southeastern Cooperative Wildlife Disease Study, Department of Population Health, College of Veterinary Medicine, The University of Georgia, Athens, Georgia 30602, USA

³ Department of Pathology, College of Veterinary Medicine, The University of Georgia, Athens, Georgia 30602, USA

⁴ Corresponding author (email: aellis@vet.uga.edu)

ABSTRACT: Carcasses from 346 raptors found between August 2001 and December 2004 were tested for West Nile virus (WNV) using virus isolation and immunohistochemistry; 40 were positive for WNV by one or both methods. Of these 40 birds, 35 had histologic lesions compatible with WNV infection, one had lesions possibly attributable to WNV, and four had no histologic evidence of WNV. The most common histologic lesions associated with WNV infection were myocardial inflammation, necrosis, and fibrosis; skeletal muscle degeneration, inflammation, and fibrosis; and lymphoplasmacytic encephalitis. Other lesions included hepatitis, lymphoid depletion in spleen and bursa, splenic and hepatic hemosiderosis, pancreatitis, and ganglioneuritis. Gross lesions included calvarial and leptomeningeal hemorrhage, myocardial pallor, and splenomegaly. Red-tailed hawks (*Buteo jamaicensis*) (10/56), sharp-shinned hawks (*Accipiter striatus*) (8/40), and Cooper's hawks (*Accipiter cooperii*) (10/103) were most commonly affected. Also affected were red-shouldered hawks (*Buteo lineatus*) (2/43), an osprey (*Pandion haliaetus*) (1/5), barred owls (*Strix varia*) (4/27), a great horned owl (*Bubo virginianus*) (1/18), and eastern screech owls (*Megascops asio*) (4/42). Although birds were examined throughout the year, positive cases occurred only during the summer and late fall (June–December). Yearly WNV mortality rates ranged from 7–15% over the four years of the study. This study indicates trends in infection rates of WNV in raptorial species over a significant time period and supports the available information regarding pathology of WNV infection in Strigiformes and Falconiformes. Although many species tested were positive for WNV infection, severity of lesions varied among species.

Key words: Avian, immunohistochemistry, pathology, raptors, West Nile virus, WNV.

INTRODUCTION

West Nile virus (WNV) was first documented in the United States in 1999 when it was associated with an outbreak in New York that resulted in the death of hundreds of wild birds (Steele et al., 2000). Since that time, WNV has spread across the United States, causing the deaths of thousands of wild birds, as well as some captive species (Steele et al., 2000; Kramer and Bernard, 2001; Ludwig et al., 2002). Although the majority of these birds have been passerines, especially corvids, many other taxonomic groups of birds have been affected, including several species of hawks and owls (Steele et al., 2000; Ellis et al., 2005; CDC, 2006). In addition to a few individual reports of WNV in raptors (Anderson et al., 1999; Garmendia et al., 2000), pathologic

findings from natural infections have been previously described in 13 owls from Michigan (Fitzgerald et al., 2003), as well as 11 Cooper's hawks (*Accipiter cooperii*), 11 red-tailed hawks (*Buteo jamaicensis*), 25 great-horned owls (*Bubo virginianus*), and 12 goshawks (*Accipiter gentilis*) from Minnesota (Wunschmann et al., 2004, 2005). Clinical disease has been described in 40 raptors from Virginia representing nine species (Joyner et al., 2006). A final study described pathologic findings in both naturally and experimentally infected raptors including American kestrels (*Falco sparverius*), golden eagles (*Aquila chrysaetos*), red-tailed hawks, barn owls (*Tyto alba*), and great-horned owls (Nemeth et al., 2006a).

This study describes the gross pathology and histopathological and immunohisto-

chemical findings associated with WNV infection in eight species of raptors. Results are compared over four years to identify trends in WNV infection rates in these species in Georgia.

MATERIALS AND METHODS

State and local health departments in Georgia voluntarily submitted dead raptors for WNV testing to the Southeastern Cooperative Wildlife Disease Study, College of Veterinary Medicine, The University of Georgia. Between August 2001 and December 2004, 346 raptors were examined. Age and sex were recorded if known, and body condition was assessed. Age was recorded as juvenile or adult and was based on presence of a bursa and/or morphologic characteristics (eye color, feather color). Complete necropsies were performed on all birds. Except in cases where scavenging, trauma, or decomposition prevented collection of one or more samples, brain, heart, and cloacal swab samples from each bird were placed in BA-1 media for virus isolation (Gibbs et al., 2005). Samples of heart, liver, kidney, lung, spleen, gonad, adrenal, trachea, crop, ventriculus, proventriculus, intestine, pancreas, bursa of Fabricius, skeletal muscle, and brain were placed in 10% formalin for routine histopathology and immunohistochemistry. Additional tissues such as skin, eyes, and bone marrow were collected as deemed necessary.

Histopathology

Formalin-fixed tissues were processed and embedded in paraffin within 48 hours. Hematoxylin and eosin (HE) stained slides were examined and all histologic changes were noted, including those considered incidental.

Immunohistochemistry

Immunohistochemistry (IHC) was performed as previously described (Gottdenker et al., 2003). Briefly, a streptavidin-biotin alkaline phosphatase staining system was used. The primary antibody was a rabbit polyclonal used at a 1:500 dilution (BioReliance, Rockville, Maryland, USA). Fast red chromagen was used for labeling.

Virus isolation and identification of virus

A cloacal swab and 3 mm³ samples of brain stem and heart were aseptically obtained and placed in separate 1.5 ml microcentrifuge tubes containing 0.5 ml BA-1 medium. Tissues

were stored at 4 C prior to testing (<24 hr). Tissues were macerated with a plastic tissue grinder in BA-1 and centrifuged at 7,200 × G for 5 min. Virus isolation and RT-PCR for identification were performed as previously described (Gottdenker et al., 2003).

RESULTS

Forty of the 346 (11.5%) birds examined were WNV positive; five of these were positive by virus isolation, eleven by IHC, and 24 were positive by both methods. In 2001 (August through December), 7% (5/72) of the submitted raptors were WNV positive, and in 2002, 2003, and 2004 (January through December), 15% (21/138), 11% (10/94), and 10% (4/42) were positive, respectively. Although birds were submitted throughout the year (Fig. 1), WNV positive birds were identified only during the months of June (1), July (3), August (17), September (9), October (8), November (1), and December (1).

Regarding sex and age, 24/192 females (12.5%), 12/116 males (10.3%), and 4/38 birds of unknown sex (11%) were positive for WNV, as were 28/202 juveniles (13.9%), 8/64 adults (13%), and 4/80 birds of unknown age (5%). Both Strigiformes and Falconiformes were represented with 10/56 red-tailed hawks (18%), 8/40 sharp-shinned hawks (*Accipiter striatus*) (20%), 10/103 Cooper's hawks (9.7%), 2/43 red-shouldered hawks (*Buteo lineatus*) (5%), 1/5 ospreys (*Pandion haliaetus*) (20%), 4/27 barred owls (*Strix varia*) (15%), 4/42 eastern screech owls (*Megascops asio*) (10%), and 1/18 great-horned owls (6%) testing positive for WNV. Six barns owls, four broad-winged hawks (*Buteo platyterus*), one American kestrel, and one Mississippi kite (*Ictinia mississippiensis*) were negative for WNV.

Gross pathology

Eighteen of the 40 birds with WNV infection were emaciated, 12 were thin, and 10 were in good body condition. Nine had calvarial hemorrhages, four had lep-

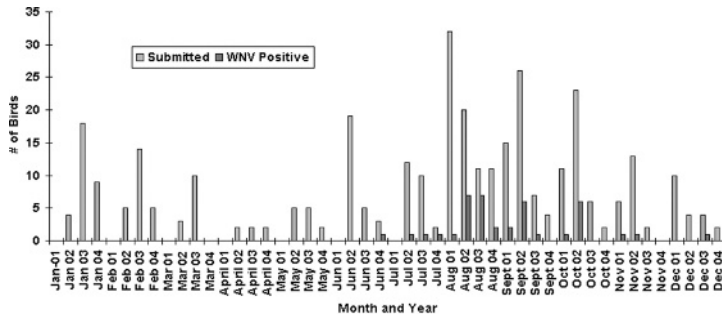


FIGURE 1. Number of WNV positive birds vs. number of birds submitted by month and year.

tomeningeal hemorrhage or congestion, 10 had multifocal to coalescing areas of myocardial pallor, four had enlarged spleens, and two had diffusely mottled kidneys. Of the 10 birds with gross cardiac lesions, only one of nine owls had visible lesions, whereas nine of 31 hawks had lesions.

Several birds had traumatic injuries, including bruises, fractures, hemorrhage, and penetrating wounds. Many birds also had gastrointestinal parasites, although this was considered incidental.

Histopathology

A variety of histologic lesions consistent with WNV infection were identified (Table 1, Fig. 2). Myocardial lesions, which included inflammation, necrosis, and fibrosis, were highly variable in severity. Inflammatory lesions ranged from scattered mononuclear cells in the myocardial interstitium to multiple foci of lymphoplasmacytic cells infiltrating the myocardium and sometimes pericardium, to almost complete replacement of the myocardium by mononuclear cells. Myocardial necrosis and fibrosis also ranged from focal to widespread.

Although histologic lesions ($n=7$) were more prevalent than gross lesions ($n=1$) in the hearts of the WNV-positive owls, lesions were mild in all seven birds. Hawks tended to have more extensive lesions with severe inflammation or fibrosis in 13/31 birds.

Within skeletal muscle, myofiber de-

generation was a consistent finding with varying degrees of concurrent lymphoplasmacytic inflammation and fibrosis. Changes in skeletal muscle were not as severe as those observed in cardiac muscle.

Encephalitic lesions typically consisted of lymphoplasmacytic perivascular cuffing. Gliosis and neuronal necrosis were often present but were rarely prominent. Lesions were highly variable, both among and between species, ranging from focal and/or very mild to severe and diffuse. All areas of the brain were affected, although not in every bird. Lymphoplasmacytic meningitis was commonly noted, although it was typically mild, even in birds with severe encephalitis. Similar to the findings in heart, only two of nine owls had histologic lesions in brain, and lesions were very mild in both birds. Ganglioneuritis occurred in about a third of the infected birds. In most birds, lesions involved ganglia and nerves in the proventriculus and ventriculus, but in one bird inflammation was mild, focal, and confined to the cervical ganglion.

Splenic changes were generally more subtle than in other organs and consisted of multiple small foci of necrotic or apoptotic lymphoid cells. Hemosiderin commonly was seen in splenic macrophages, and smudging of sheathed arterioles was rarely noted. Bursal changes were consistent with atrophy, which could have been physiologic or pathologic.

Pancreatic lesions were mild and con-

TABLE 1. Histologic lesions observed in West Nile virus-positive raptors.^a

Organ affected/lesion (<i>n</i> =number affected/number examined)	Description	Number affected
Heart (<i>n</i> =37/40)		
Myocarditis	Lymphoplasmacytic to histiocytic	30
Pericarditis		5
Necrosis		16
Fibrosis		9
Brain (<i>n</i> =25/38)		
Encephalitis	Lymphoplasmacytic	25
Meningitis		17
Spleen (<i>n</i> =20/35)		
Hemosiderosis		13
Atrophy		1
Necrosis/Apoptosis	Lymphoid cells	10
Liver (<i>n</i> =34/40)		
Hepatitis	Lymphoplasmacytic	23
	Lymphoplasmacytic to granulomatous	9
	Lymphoplasmacytic, some heterophils	10
	Hepatocytes and Kupffer cells	10
Hemosiderosis		
Bursa (<i>n</i> =17/24)		
Atrophy		5
Apoptosis	Lymphoid cells and epithelium	2
Skeletal muscle (<i>n</i> =32/37)		
Myositis	Lymphoplasmacytic	13
Degeneration/necrosis		27
Autonomic nerves (<i>n</i> =13/40)		
Ganglioneuritis	Proventriculus, ventriculus, cervical ganglion	11
Necrotic neurons	Same as above	7
Pancreas (<i>n</i> =9/25)		
Pancreatitis	Lymphoplasmacytic	8
Fibrosis		2
Apoptosis	Lymphoid cells	2
Kidney (<i>n</i> =16/40)		
Acute tubular necrosis		7
Urates		2
Nephritis		9

^a WNV positive species: Cooper's hawk, red-shouldered hawk, red-tailed hawk, sharp-shinned hawk, barred owl, eastern screech owl, and great-horned owl.

sisted of small, focal to multifocal aggregates of lymphocytes with or without plasma cells between exocrine glands. Liver lesions tended to be periportal to multifocal and were most often lymphoplasmacytic. Granulomatous and heterophilic lesions were also noted but were considered background as they were often associated with intralesional larvae. Dilated sinusoids and hepatocellular vacuolation were sometimes noted, and hemosiderin was not an uncommon finding with

deposits in both Kupffer cells and macrophages.

Lung lesions were identified in some birds and typically consisted of mild increases in the numbers of lymphocytes and plasma cells, often around bronchioles. Multifocal areas of necrosis were present in the lungs from one bird.

Immunohistochemistry

Of the 29 positive birds for WNV by virus isolation, 24 were also positive by

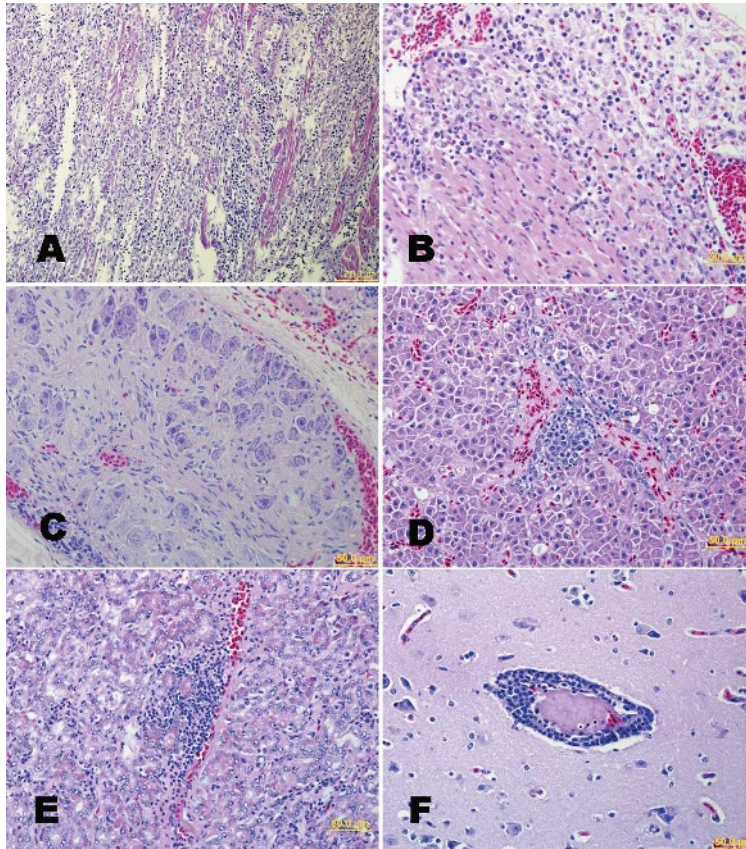


FIGURE 2. A. Heart, Red-tailed hawk. Large numbers of lymphocytes, plasma cells, and macrophages replace and separate myocardial fibers. HE. B. Heart, Sharp-shinned hawk. Numerous lymphocytes, plasma cells, and macrophages replace and infiltrate myocardial fibers and extend into the pericardium. HE. C. Ganglion, perirenal, Red-tailed hawk. Lymphocytes and plasma cells infiltrate this ganglion. HE. D. Liver, Cooper's hawk. Lymphocytes and plasma cells surround a portal vein. HE. E. Pancreas, Red-tailed hawk. Lymphocytes dissect between pancreatic exocrine glands. HE. F. Cerebrum, Red-tailed hawk. Thick lymphoplasmacytic cuffs surround vessels, and there are increased numbers of glial cells. HE.

IHC. Eleven birds were positive by IHC alone. Immunohistochemistry identified viral antigen in heart, kidney, liver, lung, spleen, ventriculus, proventriculus, intestine, bursa, adrenal, a large blood vessel, cerebrum, cerebellum, brain stem, and meninges (Table 2). Within these tissues, viral antigen was identified in myocardial fibers, cerebellar Purkinje cells and axonal fibers, neurons of the cerebrum and brain stem nuclei, various epithelial cells, fibroblasts, and phagocytic cells including macrophages, microglia, and Kupffer cells (Fig. 3). Viral antigen was not identified in

brain in any of the owls, although two birds had encephalitic lesions.

DISCUSSION

Our study suggests that WNV infection peaked in raptors in Georgia in 2002 followed by slight decreases in 2003 and 2004. Based on these four years of data, it does not appear that WNV is or will become a major cause of mortality in raptors in Georgia. Ten percent is well within previously published ranges (3–30%) of mortality in raptors due to

TABLE 2. Immunohistochemistry results by tissue for West Nile virus-positive raptors.

Species ^a	Tissue ^b												Virus isolation ^c
	Ht	Li	Lu	Kd	Sp	CR	CB	BS	PV	V	In	SM	
COH	4/10	6/10	3/10	2/10	1/8	3/10	2/9	3/8	2/8	0/8	3/9	3/6	6/10
RSH	2/2	0/2	0/2	0/2	0/2	2/2	1/2	1/1	1/2	0/2	0/2	0/0	2/2
RTH	6/10	2/10	4/10	7/10	2/7	5/9	7/9	2/6	5/8	3/8	3/7	3/7	10/10
SSH	6/8	4/8	4/8	5/8	1/8	1/7	1/7	1/7	2/7	1/6	0/7	3/4	6/8
Osprey	0/1	0/1	0/1	0/1	0/1	0/1	0/1	0/1	0/1	1/1	0/1	0/1	1/1
BO	1/4	1/4	1/4	1/4	1/4	0/4	0/2	0/2	1/2	1/2	0/3	0/1	3/4
ESO	2/4	0/4	1/4	2/4	3/4	0/4	0/3	0/4	0/2	0/2	1/2	0/1	0/4
GHO	0/1	0/1	0/1	0/1	0/1	0/1	0/1	0/1	1/1	1/1	0/1	0/1	1/1
Total	21/40	13/40	13/40	17/40	8/35	11/38	11/34	7/30	12/31	7/30	7/32	9/21	29/40

^a COH = Cooper's hawk, RSH = red-shouldered hawk, RTH = red-tailed hawk, SSH = sharp-shinned hawk, BO = barred owl, ESO = eastern screech owl, GHO = great-horned owl.

^b Ht = heart, Li = liver, Lu = lung, Kd = kidney, Sp = spleen, CR = cerebrum, CB = cerebellum, BS = brainstem, PV = proventriculus, V = ventriculus, In = intestine, SM = skeletal muscle; total positive/total tested.

^c Tissues positive: brain, heart, and/or cloacal swab.

infectious diseases (Fix and Barrows, 1990; Work and Hale, 1996; Deem et al., 1998; Morishita et al., 1998). However, true population effects are difficult to assess because accurate population numbers are rarely available, and there is an inherent sampling bias in any study such as this one, that rely on submissions from

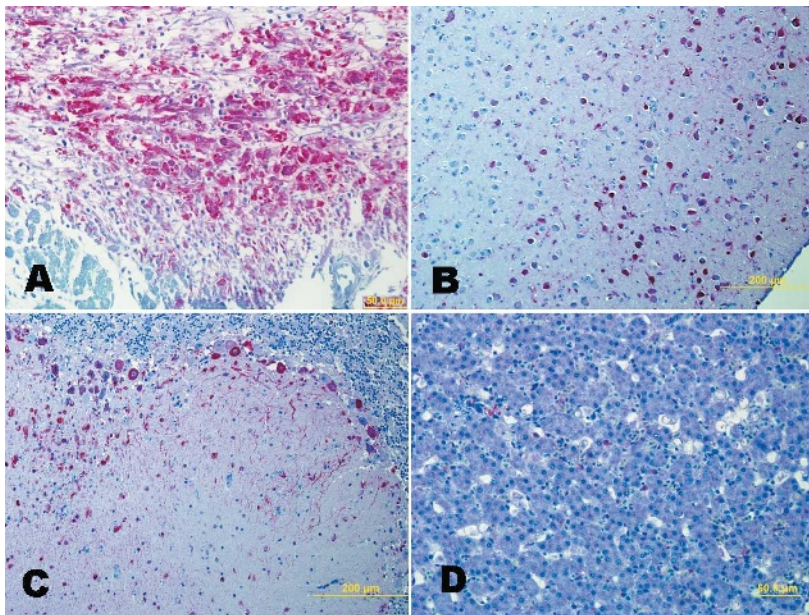


FIGURE 3. A. Heart, Red-tailed hawk. Immunostaining demonstrates viral antigen in myocardial fibers and infiltrating monocytes. Fast red chromagen, hematoxylin counterstain. B. Cerebrum, Red-tailed hawk. Immunostaining demonstrates abundant viral antigen in neurons and glial cells. Fast red chromagen, hematoxylin counterstain. C. Cerebellum, Red-tailed hawk. Purkinje cells, axonal/dendritic fibers, and glial cells contain viral antigen. Fast red chromagen, hematoxylin counterstain. D. Liver, Red-tailed hawk. Viral-laden Kupffer cells are scattered throughout the liver. Fast red chromagen, hematoxylin counterstain.

the public. One important point is that many WNV positive raptors also had concurrent lesions. Six birds had significant gross lesions that were not attributable to WNV infection, and in four birds, trauma appeared to be the immediate cause of death. Therefore, it is important from a public health standpoint to realize that birds with traumatic injuries or other diseases might also have concurrent WNV infection that could have contributed to death, either directly or indirectly, or simply might have been an incidental finding.

The detection of WNV infection in raptors consistently paralleled the mosquito transmission season (D. Mead, pers. comm.), with the majority of raptor cases occurring August through October. This timeline also parallels reports of clinical cases of WNV in raptors in Virginia (Joyner et al., 2006). Although previous reports have occasionally identified WNV-positive raptors during the winter (Anderson et al., 1999; Garmendia et al., 2000), no WNV-positive raptors were identified in this study during the winter or early spring.

Of the four raptor species in which WNV was not detected, all birds were submitted during the WNV transmission season. Barn owls were submitted in July, August, September, and October; broad-winged hawks in July, August, and September, and the Mississippi kite and American kestrel in August. However, because these bird species were not well represented in our study (barn owls [$n=6$], broad-winged hawks [$n=4$], American kestrel [$n=1$], and Mississippi kite [$n=1$]), it is difficult to draw conclusions about their susceptibility to WNV. All four of these species are included in the Centers for Disease Control's WNV avian mortality database (CDC, 2006); however, this database does not provide information on numbers of birds tested or found to be WNV positive for each species. Barn owls were included in a study of an outbreak of WNV in Ontario, Canada. Although 10

barn owls were present in the susceptible population, none of these owls died and eight of 10 had antibodies to WNV following the outbreak (Gancz et al., 2004). In addition, experimental infection of two barn owls failed to elicit clinical signs and resulted in relatively low viremia and shedding levels in combination with a relative lack of gross and histopathologic lesions compared to other raptor species (Nemeth et al., 2006a). This information in combination with the data in this study suggest that barn owls might be relatively resistant to WNV-associated mortality, although serologic data indicate that they are susceptible to infection. American kestrels experimentally inoculated with WNV via needle or mosquito developed lesions typical of WNV infection, including myocarditis and encephalitis (Nemeth et al., 2006a), indicating that this species is susceptible to infection. Eastern screech owls have not been reported as a susceptible species, and the Ontario study included 36 susceptible birds with no observed mortality and 72% seroconversion following the outbreak (Gancz et al., 2004). A pathologic study of WNV in owls included a single eastern screech owl out of 82 owls that died (Gancz et al., 2006). Interestingly, all four of the WNV-positive eastern screech owls in this study were very young birds. Two were fledglings and the remaining two had minimal evidence of involution in the bursa of Fabricius, indicating that they were young juveniles. Most previous studies have not indicated age-related differences in susceptibility to or mortality associated with WNV infection; this is likely due to the difficulty of determining age in wild birds. However, for some domestic bird species, birds of younger age appear to be more severely affected by WNV infection (Turell et al., 2000; Langevin et al., 2001; Turell et al., 2001, 2002; Austin et al., 2004). Although previous evidence has not indicated high susceptibility of eastern screech owls, experimental infection of juvenile eastern screech owls resulted in viremia in all

subcutaneously inoculated birds, and two of five birds developed clinical signs (Nemeth et al., 2006b). Adult birds were not included in the study. Two other studies include age information for affected owls, although not specifically for screech owls. The Ontario study found that although age was not a significant risk factor for exposure to WNV, birds older than one year of age were more likely to experience mortality due to WNV infection (Gancz et al., 2004). A second study also found that of 25 great-horned owls positive for WNV, the majority were greater than one year of age (Wunschmann et al., 2005). However, the effects of bias must again be considered here because WNV-infected fledglings and adults might have different probability of detection due to behavior differences.

Previous reports have demonstrated that lesions and severity of lesions are variable among species of raptors with WNV infection (Anderson et al., 1999; Garmendia et al., 2000; Steele et al., 2000; Wunschmann et al., 2004, 2005; Gancz et al., 2006; Nemeth et al., 2006a). This study supports and expands the findings from previous reports. As previously reported (Wunschmann et al., 2005), owls in this study tended to be less severely affected by WNV than hawks. Owls had fewer and milder gross and histologic lesions, and viral antigen was less prevalent than in affected hawks. Among owl species, gross and histopathologic lesions have also been shown to vary considerably (Gancz et al., 2006), but species that had the most severe lesions (northern species such as the snowy owl) were not included in the present study.

Among the hawks, red-tailed hawks, red-shouldered hawks, and sharp-shinned hawks were severely affected by WNV infection. Hearts from the majority of birds of these species had grossly visible lesions, moderate to severe histologic lesions, and viral antigen detectable by IHC. Although a relatively large number of Cooper's hawks were affected, lesions

in these birds were generally milder than in the three previously described species.

Although antigen distribution was generalized in most hawk species, the red-shouldered hawks rarely had viral antigen in tissues other than heart or brain. However, because only two WNV-positive birds of this species were examined, it is uncertain whether this is a real trend. With the exception of red-shouldered hawks, kidney, liver, and lung were useful for detecting WNV antigen in hawks. Heart was the best tissue for IHC in all species, and brain was relatively insensitive except in red-tailed, red-shouldered, and Cooper's hawks.

Gross lesions were far less common than histologic lesions, with the most common gross lesion being calvarial hemorrhage. Myocardial necrosis was highly variable, with most birds having either no grossly visible necrosis or severe necrosis involving most of the heart. Splenomegaly was noted occasionally but was not a consistent finding. Many birds were emaciated, but the significance of this is not known. Birds could either be emaciated as a result of disease, or emaciation could have made these birds more susceptible to disease. In at least one case, there was extensive fibrosis within the heart, indicating a more chronic disease process which would support the idea of emaciation secondary to disease. On the other hand, the majority of WNV-positive raptors (and the majority of raptors submitted) were juveniles, and previous studies have indicated that starvation is a common cause of morbidity/mortality in raptors, especially within the first year of life, probably due to poor hunting skills (Cooper, 1973; Morishita et al., 1998). Therefore, it is possible that body condition and WNV infection are simply concurrent findings. Although the majority of birds affected with WNV in this study were juveniles, juveniles were also submitted far more commonly than adults.

This study indicates that WNV is primarily myocardiotropic and neurotrop-

ic in raptors with the most common histologic lesions being myocarditis/myocardial necrosis and nonsuppurative meningoencephalitis. Within brain lesions, WNV antigen was detected by IHC in neurons of the cerebrum and brainstem nuclei, cerebellar Purkinje cells, and glial cells as well as within infiltrating lymphocytes and gitter cells. In cardiac lesions, WNV antigen was detected by IHC in myocardial fibers and infiltrating lymphocytes and histiocytes. Other histologic lesions that were consistent with WNV infection in our study but occurred less frequently were pancreatitis, meningitis, ganglioneuritis, pericarditis, hepatitis (primarily lymphoplasmacytic but sometimes containing macrophages and/or heterophils), and lymphoid depletion in the spleen and bursa, often with apoptotic cells. Splenic and/or hepatic hemosiderosis was commonly seen, but this is a non-specific finding that is common in sick birds.

Antigen to WNV was detected by IHC in virtually all tissues. However, a prominent finding was the detection of antigen within macrophage-type cells in many organs. This finding is consistent with results in nonraptorial species and might be suggestive of pathogenesis. Macrophages produce a variety of inflammatory mediators such as tumor necrosis factor and interleukin 1 that can cause tissue damage. Macrophages might also serve to transport viruses to other tissues. The finding of apoptotic cells in multiple organs might also provide some clue to pathogenesis, and is consistent with in vivo findings in mice where the WNV capsid induced inflammation and apoptosis via the caspase-9 pathway (Yang et al., 2002).

Although these results are generally consistent with those in other studies (Steele et al., 2000; Swayne et al., 2000) and provide some basic information, many questions remain regarding pathogenesis, species susceptibility, host-related factors of disease, and potential population impacts of WNV on raptors.

ACKNOWLEDGMENTS

This study was primarily supported by the Georgia Department of Human Resources through the Centers for Disease Control and Prevention's "Epidemiology and Laboratory Capacity for Infectious Diseases" grant program, contract 427-93-25328. Additional support was provided by the Federal Aid to Wildlife Restoration Act (50 Stat. 917) and through sponsorship from fish and wildlife agencies in Alabama, Arkansas, Florida, Georgia, Kansas, Kentucky, Louisiana, Maryland, Mississippi, Missouri, North Carolina, Oklahoma, Puerto Rico, South Carolina, Tennessee, Virginia, and West Virginia. The authors wish to thank N. Gottdenker and R. Gerhold for necropsy assistance.

LITERATURE CITED

- ANDERSON, J. F., T. G. ANDREADIS, C. R. VOSSBRINCK, S. TIRRELL, E. M. WAKEM, R. A. FRENCH, A. E. GARMENDIA, AND H. J. VAN KRUININGEN. 1999. Isolation of West Nile virus from mosquitoes, crows, and a Cooper's hawk in Connecticut. *Science* 286: 2331–2333.
- AUSTIN, R. J., T. L. WHITING, R. A. ANDERSON, AND M. A. DREBOT. 2004. An outbreak of West Nile virus-associated disease in domestic geese (*Anser anser domesticus*) upon initial introduction to a geographic region, with evidence of bird to bird transmission. *Canadian Veterinary Journal* 45: 117–123.
- CDC. 2006. West Nile Virus avian mortality database. <http://www.cdc.gov/ncidod/dvbid/westnile/birdspecies.htm>. Accessed 14 February 2006.
- COOPER, J. E. 1973. Post-mortem findings in East African birds of prey. *Journal of Wildlife Diseases* 9: 368–375.
- DEEM, S. L., S. P. TERRELL, AND D. J. FORRESTER. 1998. A retrospective study of morbidity and mortality of raptors in Florida: 1988–1994. *Journal of Zoo and Wildlife Medicine* 29: 160–164.
- ELLIS, A. E., D. G. MEAD, A. B. ALLISON, S. E. GIBBS, N. L. GOTTDENKER, D. E. STALLKNECHT, AND E. W. HOWERTH. 2005. Comparison of immunohistochemistry and virus isolation for diagnosis of West Nile virus. *Journal of Clinical Microbiology* 43: 2904–2908.
- FITZGERALD, S. D., J. S. PATTERSON, M. KIUEP, H. A. SIMMONS, S. D. GRIMES, C. F. SARVER, R. M. FULTON, B. A. STEFICEK, T. M. COOLEY, J. P. MASSEY, AND J. G. SIKARSKIE. 2003. Clinical and pathologic features of West Nile virus infection in native North American owls (Family Strigidae). *Avian Diseases* 47: 602–610.
- FIX, A. S., AND S. Z. BARROWS. 1990. Raptors rehabilitated in Iowa during 1986 and 1987: A

- retrospective study. *Journal of Wildlife Diseases* 26: 18–21.
- GANCZ, A. Y., I. K. BARKER, R. LINDSAY, A. DIBERNARDO, K. MCKEEVER, AND B. HUNTER. 2004. West Nile virus outbreak in North American owls, Ontario, 2002. *Emerging Infectious Diseases* 10: 2135–2142.
- , D. A. SMITH, I. K. BARKER, R. LINDSAY, AND B. HUNTER. 2006. Pathology and tissue distribution of West Nile virus in North American owls (family: Strigidae). *Avian Pathology* 35: 17–29.
- GARMENDIA, A. E., H. J. VAN KRUININGEN, R. A. FRENCH, J. F. ANDERSON, T. G. ANDREADIS, A. KUMAR, AND A. B. WEST. 2000. Recovery and identification of West Nile virus from a hawk in winter. *Journal of Clinical Microbiology* 38: 3110–3111.
- GIBBS, S., A. ELLIS, D. MEAD, A. ALLISON, E. HOWERTH, AND D. STALLKNECHT. 2005. West Nile virus detection in the organs of naturally infected Blue Jays (*Cyanocitta cristata*). *Journal of Wildlife Diseases* 41: 354–362.
- GOTTDENKER, N. L., E. W. HOWERTH, AND D. G. MEAD. 2003. Natural infection of a great egret (*Casmerodius albus*) with eastern equine encephalitis virus. *Journal of Wildlife Diseases* 39: 702–706.
- JOYNER, P. H., S. KELLY, A. A. SHREVE, S. E. SNEAD, J. M. SLEEMAN, AND D. A. PETTIT. 2006. West Nile virus in raptors from Virginia during 2003: Clinical, diagnostic, and epidemiologic findings. *Journal of Wildlife Diseases* 42: 335–344.
- KRAMER, L. D., AND K. A. BERNARD. 2001. West Nile virus infection in birds and mammals. *Annals of the New York Academy of Sciences* 951: 84–93.
- LANGVIN, S. A., M. BUNNING, B. DAVIS, AND N. KOMAR. 2001. Experimental infection of chickens as candidate sentinels for West Nile virus. *Emerging Infectious Diseases* 7: 726–729.
- LUDWIG, G. V., P. P. CALLE, J. A. MANGIAFICO, B. L. RAPHAEL, D. K. DANNER, J. A. HILE, T. L. CLIPPINGER, J. F. SMITH, R. A. COOK, AND T. MCNAMARA. 2002. An outbreak of West Nile virus in a New York City captive wildlife population. *American Journal of Tropical Medicine and Hygiene* 67: 67–75.
- MORISHITA, T., A. FULLERTON, L. LOWENSTINE, I. GARDNER, AND D. BROOKS. 1998. Morbidity and mortality in free-living raptorial birds of northern California: A retrospective study, 1983–1994. *Journal of Avian Medicine and Surgery* 12: 78–81.
- NEMETH, N., D. GOULD, R. BOWEN, AND N. KOMAR. 2006a. Natural and experimental West Nile virus infection in five raptor species. *Journal of Wildlife Diseases* 42: 1–13.
- , D. C. HAHN, D. H. GOULD, AND R. A. BOWEN. 2006b. Experimental West Nile virus infection in Eastern Screech Owls (*Megascops asio*). *Avian Diseases* 50: 252–258.
- STEELE, K. E., M. J. LINN, R. J. SCHOEPP, N. KOMAR, T. W. GEISBERT, R. M. MANDUCA, P. P. CALLE, B. L. RAPHAEL, T. L. CLIPPINGER, T. LARSEN, J. SMITH, R. S. LANCIOTTI, N. A. PANELLA, AND T. S. MCNAMARA. 2000. Pathology of fatal West Nile virus infections in native and exotic birds during the 1999 outbreak in New York City, New York. *Veterinary Pathology* 37: 208–224.
- SWAYNE, D. E., J. R. BECK, AND S. ZAKI. 2000. Pathogenicity of West Nile virus for turkeys. *Avian Diseases* 44: 932–937.
- TURELL, M. J., M. O'GUINN, AND J. OLIVER. 2000. Potential for New York mosquitoes to transmit West Nile virus. *American Journal of Tropical Medicine and Hygiene* 62: 413–414.
- , M. L. O'GUINN, D. J. DOHM, AND J. W. JONES. 2001. Vector competence of North American mosquitoes (Diptera: Culicidae) for West Nile virus. *Journal of Medical Entomology* 38: 130–134.
- , ———, ———, J. P. WEBB, JR., AND M. R. SARDELIS. 2002. Vector competence of *Culex tarsalis* from Orange County, California, for West Nile virus. *Vector Borne and Zoonotic Diseases* 2: 193–196.
- WORK, T. M., AND J. HALE. 1996. Causes of owl mortality in Hawaii, 1992 to 1994. *Journal of Wildlife Diseases* 32: 266–273.
- WUNSCHMANN, A., J. SHIVERS, J. BENDER, L. CARROLL, S. FULLER, M. SAGGESE, A. VAN WETTERE, AND P. REDIG. 2004. Pathologic findings in red-tailed hawks (*Buteo jamaicensis*) and Cooper's hawks (*Accipiter cooper*) naturally infected with West Nile virus. *Avian Diseases* 48: 570–580.
- , ———, ———, ———, ———, ———, ———, AND ———. 2005. Pathologic and immunohistochemical findings in goshawks (*Accipiter gentilis*) and great horned owls (*Bubo virginianus*) naturally infected with West Nile virus. *Avian Diseases* 49: 252–259.
- YANG, J. S., M. P. RAMANATHAN, K. MUTHUMANI, A. Y. CHOO, S. H. JIN, Q. C. YU, D. S. HWANG, D. K. CHOO, M. D. LEE, K. DANG, W. TANG, J. J. KIM, AND D. B. WEINER. 2002. Induction of inflammation by West Nile virus capsid through the caspase-9 apoptotic pathway. *Emerging Infectious Diseases* 8: 1379–1384.

Received for publication 19 June 2006.