

A Case of Pulmonary Cryptococcosis in a Free-living Toad (*Bufo bufo*)

Authors: Seixas, Fernanda, da Luz Martins, Maria, de Lurdes Pinto, Maria, Travassos, Paulo Jorge, Miranda, Manuela, et al.

Source: Journal of Wildlife Diseases, 44(2) : 460-463

Published By: Wildlife Disease Association

URL: <https://doi.org/10.7589/0090-3558-44.2.460>

BioOne Complete (complete.BioOne.org) is a full-text database of 200 subscribed and open-access titles in the biological, ecological, and environmental sciences published by nonprofit societies, associations, museums, institutions, and presses.

Your use of this PDF, the BioOne Complete website, and all posted and associated content indicates your acceptance of BioOne's Terms of Use, available at www.bioone.org/terms-of-use.

Usage of BioOne Complete content is strictly limited to personal, educational, and non - commercial use. Commercial inquiries or rights and permissions requests should be directed to the individual publisher as copyright holder.

BioOne sees sustainable scholarly publishing as an inherently collaborative enterprise connecting authors, nonprofit publishers, academic institutions, research libraries, and research funders in the common goal of maximizing access to critical research.

A Case of Pulmonary Cryptococcosis in a Free-living Toad (*Bufo bufo*)

Fernanda Seixas,^{1,2} Maria da Luz Martins,³ Maria de Lurdes Pinto,^{1,2} Paulo Jorge Travassos,^{4,5} Manuela Miranda,⁶ and Maria dos Anjos Pires^{1,2,7} ¹ Laboratório de Histologia e Anatomia Patológica, Clínicas Veterinárias, Universidade de Trás-os-Montes e Alto Douro, 5001-801 Vila Real, Portugal; ² Centro de Estudos em Ciência Animal e Veterinária, Universidade de Trás-os-Montes e Alto Douro, 5001-801 Vila Real, Portugal; ³ Instituto de Higiene e Medicina Tropical/Centro de Recursos Microbiológicos, Universidade Nova de Lisboa, R. Junqueira, 96, 1349-008 Lisboa, Portugal; ⁴ Laboratório de Ecologia Aplicada, Departamento de Engenharia Biológica e Ambiental, Universidade de Trás-os-Montes e Alto Douro, 5001-801 Vila Real, Portugal; ⁵ Centro de Estudos em Tecnologia do Ambiente e Vida, Universidade de Trás-os-Montes e Alto Douro, 5001-801 Vila Real, Portugal; ⁶ Av. da Cocanha 110, Lugar de Casinhas, 5400-674 Chaves, Portugal; ⁷ Corresponding author (email: apires@utad.pt)

ABSTRACT: Pulmonary cryptococcosis was observed in a free-living adult female common toad (*Bufo bufo*) that was killed by a vehicle. Both lungs had various eosinophilic, monomorphic, and spherical to elliptical organisms identified as *Cryptococcus* spp. The yeasts were demonstrated by Grocott's silver method and the periodic acid-Schiff reaction and the capsule was positive for mucin with a mucicarmine stain. The agent was confirmed by immunohistochemistry, using the monoclonal antibody anti-*Cryptococcus neoformans*, and by a polymerase chain reaction-based method using a *C. neoformans*-specific primer. This report, to the best of our knowledge, represents the first case of cryptococcosis in a common toad.

Key words: *Bufo bufo*, cryptococcosis, *Cryptococcus neoformans*, fungal diseases, toad.

Since 1993, many amphibian populations have been listed as declining or of conservation concern. Because most amphibians are exposed to terrestrial and aquatic habitats, it is often difficult to determine the factors that affect the ecology and the dynamics of these populations. Many potential disease agents are present in healthy animals and disease can occur when immune systems are compromised (Alford and Richards, 1999).

Cryptococcosis is an important mycosis that occurs worldwide in temperate and tropical climates, and it affects domestic animals and a variety of wild species (Jones et al., 1997). The disease is caused by a soil-inhabiting, yeast-like basidiomycetous fungus, *Cryptococcus neoformans* (Levitz, 1994; Burek, 2001; Travis et al., 2002),

which apparently affects immunocompetent and immunocompromised individuals (Buchanan and Murphy, 1998). The disease occurs sporadically and it is not contagious (Burek, 2001), but it has emerged as a major cause of morbidity and mortality in immunosuppressed humans (Buchanan and Murphy, 1998; Travis et al., 2002).

Genetic and biochemical studies have established two varieties of *C. neoformans*: *C. neoformans* var. *gatti* and *C. neoformans* var. *neoformans* (Krockenberger et al., 2003). Most infections in animals are due to the variety *neoformans* (Travis et al., 2002); it is found worldwide, especially in habitats heavily contaminated by bird droppings from rock pigeons (*Columba livia*) or other species (Burek, 2001; Travis et al., 2002). *Cryptococcus neoformans* var. *gatti* has a restricted geographical distribution, mainly subtropical and tropical areas (Jones et al., 1997; Burek, 2001; Krockenberger et al., 2003).

In this article, we report a case of pulmonary cryptococcosis in a free-living adult female toad (*Bufo bufo*) that was killed by a vehicle in northern Portugal. The amphibian was submitted for post-mortem examination at the Histopathology Laboratory of the University of Trás-os-Montes e Alto Douro (Vila Real, Portugal). Necropsy examination revealed multiple organ fractures and internal hemorrhages. The lungs had occasional whitish small round soft lesions. No other significant lesions were observed.

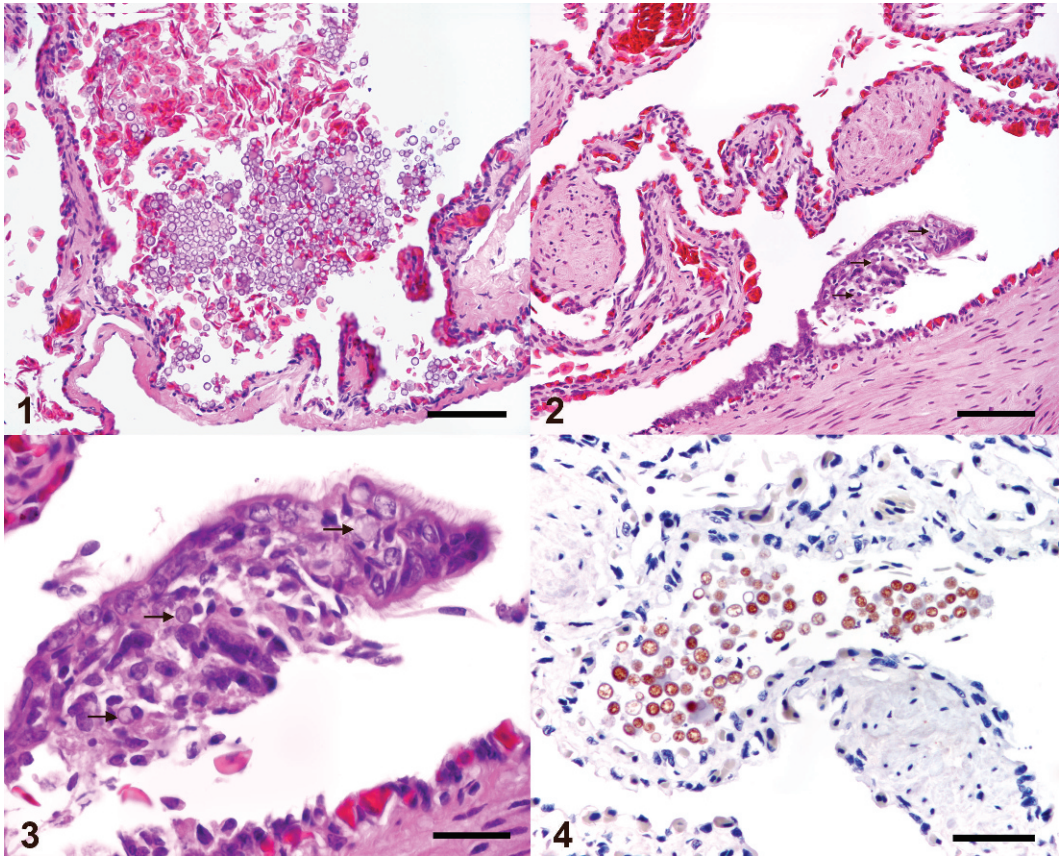


FIGURE 1. Lung. Fungal organisms in the respiratory space, with no inflammatory reaction (PAS). Bar=100 μ m. FIGURE 2. Lung. Inflammatory reaction to the fungal organisms (arrows). H&E stain. Bar=100 μ m. FIGURE 3. Lung. High-power magnification of Figure 2. Arrows show the fungal organisms. H&E stain. Bar=50 μ m. FIGURE 4. Lung. Immunoreactivity of the yeasts to anti-*Cryptococcus* antibody. Streptavidin-biotin-peroxidase, counterstained with hematoxylin. Bar=50 μ m.

Organ and tissue samples were fixed in a 10% buffered formalin solution and processed for light microscopy using standard methods. Organ and tissue samples were sectioned at 2 μ m and stained with hematoxylin and eosin (H&E), periodic acid-Schiff reaction (PAS), Grocott's methenamine silver stain, and mucicarmine stain. For immunohistochemical characterization, the monoclonal antibody anti-*C. neoformans* was used (clone CSFi, at 1:200; kindly donated by a Neomarkers®, Lab Vision, England, and Inopat, Portugal) and was visualized by a streptavidin and biotin peroxidase technique. This antibody binds to 50 kDa and 90 kDa glycoproteins found on the surface of the

yeast wall, and it recognizes encapsulated and acapsular strains of *C. neoformans*.

A polymerase chain reaction (PCR)-based method using a *C. neoformans* species-specific primer was used to confirm the presence of this yeast in tissues. DNA was extracted from the H&E- and PAS-stained sections as described previously (Banaschak et al., 2000; Man et al., 2001), with some modifications. A single multiplex PCR reaction was done using three primers, two universal primers used to identify the presence of any fungal DNA and one *C. neoformans* species-specific primer that allows the detection of this yeast's DNA in clinical samples. This technique has been used at the Medical

Mycology Laboratory at the Institute of Hygiene and Tropical Medicine, Lisbon, Portugal, since 2003 to diagnose cryptococcosis in human patients with infection (Martins, 2001).

Microscopically, both lungs had hemorrhages and various eosinophilic, monomorphic, and spherical to elliptical organisms, measuring 4–27 μm , identified as *Cryptococcus* spp. disseminated in the reticulate infoldings of pulmonic tissue; the yeasts were strongly positive to Grocott's and PAS stains (Fig. 1), but positivity to mucicarmine stain was scarce, because most yeasts were acapsular. The inflammatory response to the agent was minimal, except for an area where the organisms were surrounded by some macrophages and lymphocytes (Figs. 2, 3). The animal also had fatty liver, renal congestion, and ciliated protozoa in the colonic mucosa. Other organs did not have significant alterations.

The identity of the organism was confirmed by immunohistochemistry, using the antibody anti-*C. neoformans* (Fig. 4), and by a PCR-based method (Fig. 5).

Pulmonary cryptococcosis is caused by inhalation of spores of *C. neoformans* (Jones et al., 1997; Burek, 2001; Travis et al., 2002). It has a marked propensity for the respiratory system, specially the nasal cavity (Jones et al., 1997; Burek, 2001). The time delay between exposure and clinical disease is highly variable, but there are some reports of acute infection shortly after exposure. Patients with primary pulmonary cryptococcosis rarely have symptoms, or they present nonspecific pulmonary symptoms (Travis et al., 2002).

Diagnosis is based on identification of the organisms by cytology or in tissues, antigen detection assays, and isolation of fungus in culture (Burek, 2001). Although culture is needed for definitive identification, a confident diagnosis can be made by identification of the capsule microscopically (Burek, 2001). Microscopically, the findings are diagnostic, consisting of masses of organisms proliferating with little or

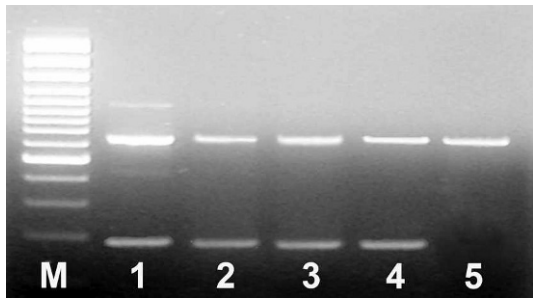


FIGURE 5. Agarose gel electrophoresis of polymerase chain reaction (PCR) products resulting from PCR amplification with three primers: two rDNA Universal delimiting primers led the amplification of a 600-base pair (bp) fragment, and a internal primer specific to *Cryptococcus neoformans* allowed an amplification of a species-specific fragment of 200 bp. M = Marker. 1 = DNA from a pure culture of *C. neoformans*. 2 = DNA from the free-living toad stained tissues. 3 = DNA from blood from a human patient with cryptococcosis. 4 = DNA from cerebrospinal fluid from a human patient with cryptococcosis. 5 = DNA from a pure culture of *Candida* sp.

no restriction. In H&E sections, the yeast cells are eosinophilic, uninucleate, thin-walled, and spherical to oval (Chandler and Watts, 1988; Jones et al., 1997), measuring 2–20 μm in diameter (mean 4–6 μm). The cells seem to have a faintly stained zone or “halo” that represents a capsule (Levitz, 1994; Burek, 2001; Travis et al., 2002), which stains selectively with mucin stains, such as mucicarmine, PAS, and colloidal iron (Burek, 2001; Travis et al., 2002).

The tissue response to cryptococcal infection depends on the immune status of the patient and whether the organisms have a capsule. When the tissue reaction to the organisms is minimal, as in this case, the air spaces seem filled with myriads of organisms (Travis et al., 2002) and only few macrophages and lymphocytes (López, 2001). A fibrohistiocytic infiltrate may accompany densely packed organisms (Burek, 2001; Travis et al., 2002). Alternatively, organisms may form nodular granulomas similar to other fungal pulmonary infections (Travis et al., 2002).

In conclusion, we describe an appar-

ently healthy animal in which both lungs had organisms, similar in shape and dimensions, to *Cryptococcus* spp., with minimal inflammatory reaction. *C. neoformans* was confirmed by immunohistochemistry and a PCR-based technique. As far as we know, this is the first report of pulmonary cryptococcosis in a free-living common toad.

The authors thank Neomarkers and Inopat for donating the antibody anti-*Cryptococcus* and L. Bento for expert technical assistance.

LITERATURE CITED

- ALFORD, R. A., AND S. J. RICHARDS. 1999. Global amphibian declines: A problem in applied ecology. *Annual Review of Ecology and Systematics* 30: 133–165.
- BANASCHAK, S., B. ROLF, AND B. BRINKMANN. 2000. Influence of different staining techniques on the DNA analysis of histological sections. *International Journal of Legal Medicine* 113: 114–116.
- BUCHANAN, K. L., AND J. W. MURPHY. 1998. What makes *Cryptococcus neoformans* a pathogen? *Emerging Infectious Diseases* 4: 71–83.
- BUREK, K. 2001. Mycotic diseases. In *Infectious Diseases of Wild Mammals*, E. S. Williams and I. K. Barker (eds.), 3rd Edition. Manson Publishing, London, UK, pp. 522–523.
- CHANDLER, F. W., AND J. C. WATTS. 1988. Fungal infections. In *Pulmonary Pathology*, D. H. Dail and S. P. Hammar (eds.). Springer-Verlag, New York, pp. 190–192 and 206–211.
- JONES, T. C., R. D. HUNT, AND N. W. KING. 1997. Diseases caused by fungi. In *Veterinary pathology*. 6th Edition. T. C. Jones, R. D. Hunt, and N. W. King (eds.). Lippincott Williams & Wilkins, Baltimore, Maryland, pp. 516–517.
- KROCKENBERGER, M. B., P. J. CANFIELD, AND R. MALIK. 2003. *Cryptococcus neoformans* var. *gatti* in the koala (*Phascolarctos cinereus*): A review of 43 cases of cryptococcosis. *Medical Mycology* 41: 225–234.
- LEVITZ, S. M. 1994. Macrophage-*Cryptococcus* interactions. In *Macrophage-pathogen interactions*. Immunology Series, Vol. 60. B. S. Zwilling and T. K. Eisenstein (eds.). Marcel Dekker Inc., New York, pp. 533–540.
- LÓPEZ, A. 2001. Respiratory system. In *Thomson's special veterinary pathology*, 3rd Edition. W. W. Carlton, M. D. McGavin, and J. F. Zachary (eds.). Mosby-Year Book Inc., Saint Louis, Missouri, pp. 175 and 187.
- MAN, Y. G., F. MAINFAR, G. L. BRATTHAUER, E. A. KUHLS, AND F. TAVASSOLI. 2001. An improved method for DNA extraction from paraffin sections. *Pathology Research and Practice* 197: 635–642.
- MARTINS, M. L. 2001. Polimorfismos fenéticos e diagnóstico molecular de *Cryptococcus neoformans*. PhD Thesis, Instituto de Higiene e Medicina Tropical, Universidade Nova de Lisbon, Lisbon.
- TRAVIS, W. D., T. V. COLBY, M. N. KOSS, M. L. ROSADO-DE-CHRISTENSON, N. L. MULLER, AND T. E. KING, JR. 2002. Lung infections. In *Atlas of nontumour pathology: Non-neoplastic disorders of the lower respiratory tract*, 1st series, Fasc. 2. American Registry of Pathology and Armed Forces Institute of Pathology, Washington, DC, pp. 600–605.

Received for publication 14 June 2006.