

## **COLUMBID HERPESVIRUS-1 IN TWO COOPER'S HAWKS (ACCIPITER COOPERII) WITH FATAL INCLUSION BODY DISEASE**

Authors: Pinkerton, Marie E., Wellehan, James F. X., Johnson, April J., Childress, April J., Fitzgerald, Scott D., et al.

Source: Journal of Wildlife Diseases, 44(3) : 622-628

Published By: Wildlife Disease Association

URL: <https://doi.org/10.7589/0090-3558-44.3.622>

---

BioOne Complete ([complete.BioOne.org](https://complete.BioOne.org)) is a full-text database of 200 subscribed and open-access titles in the biological, ecological, and environmental sciences published by nonprofit societies, associations, museums, institutions, and presses.

Your use of this PDF, the BioOne Complete website, and all posted and associated content indicates your acceptance of BioOne's Terms of Use, available at [www.bioone.org/terms-of-use](https://www.bioone.org/terms-of-use).

Usage of BioOne Complete content is strictly limited to personal, educational, and non - commercial use. Commercial inquiries or rights and permissions requests should be directed to the individual publisher as copyright holder.

---

BioOne sees sustainable scholarly publishing as an inherently collaborative enterprise connecting authors, nonprofit publishers, academic institutions, research libraries, and research funders in the common goal of maximizing access to critical research.

## COLUMBID HERPESVIRUS-1 IN TWO COOPER'S HAWKS (*ACCIPITER COOPERII*) WITH FATAL INCLUSION BODY DISEASE

Marie E. Pinkerton,<sup>1,6</sup> James F. X. Wellehan, Jr.,<sup>2</sup> April J. Johnson,<sup>2,3</sup> April L. Childress,<sup>2</sup> Scott D. Fitzgerald,<sup>4</sup> and Michael J. Kinsel<sup>5</sup>

<sup>1</sup> Veterinary Diagnostic Laboratory and Department of Pathobiology, College of Veterinary Medicine, University of Illinois, 2001 South Lincoln Avenue, Urbana, IL 61802, USA

<sup>2</sup> Department of Small Animal Clinical Sciences, College of Veterinary Medicine, University of Florida, Gainesville, FL 32610, USA

<sup>3</sup> Current Address: Division of Viral and Rickettsial Diseases, Centers for Disease Control and Prevention, Atlanta, GA 30333, USA

<sup>4</sup> Diagnostic Center for Population and Animal Health, Department of Pathobiology and Diagnostic Investigation, Michigan State University, Lansing, MI, 48910, USA

<sup>5</sup> University of Illinois Zoological Pathology Program, Building 101, Room 0745, 2160 South First Avenue, Maywood, IL 60163, USA

<sup>6</sup> Corresponding author (email: pinkerton@svm.vetmed.wisc.edu)

**ABSTRACT:** We report two separate naturally occurring cases of fatal herpesviral disease in Cooper's Hawks (*Accipiter cooperii*). Gross lesions included splenomegaly and hepatomegaly, with diffuse pale mottling or scattered small white foci. Histologic lesions included splenic and hepatic necrosis associated with eosinophilic intranuclear inclusion bodies characteristic of herpesvirus. In one case, necrosis and inclusions were also noted in bone marrow, thymus, bursa of Fabricius, thyroid gland, parathyroid gland, ceca, and the enteric system. Transmission electron microscopy demonstrated viral particles typical of herpesvirus within hepatocyte nuclei and budding from the nuclear membrane. Herpesviral DNA was amplified via polymerase chain reaction (PCR) of paraffin-embedded liver and spleen, and sequence data were consistent with columbid herpesvirus-1, an alphaherpesvirus of Rock Pigeons (*Columba livia*). PCR results provide evidence that this disease is transmitted to raptors via Rock Pigeons, most likely through ingestion of Rock Pigeons as prey.

**Key words:** *Accipiter cooperii*, columbid herpesvirus, Cooper's Hawk, falcon herpesvirus, inclusion body disease, polymerase chain reaction.

### INTRODUCTION

Naturally occurring herpesvirus infection manifesting as fatal inclusion body disease has been previously reported in a variety of falcon and owl species (Ritchie, 1995), with infection historically attributed to "falconid herpesvirus-1" and "strigid herpesvirus-1," respectively. Within the family Accipitridae, herpesviral disease has only been reported once in Booted Eagles (*Hieraetus pennatus*) and Common Buzzards (*Buteo buteo*; Ramis et al., 1994). In these cases, virus identification was done by electron microscopy, which cannot identify herpesviruses beyond the family level. Similar naturally occurring disease in accipiters (genus *Accipiter*) has not been reported. Experimental induction of fatal inclusion body disease has been demonstrated after intramuscular injection with falconid herpesvirus-1 in a

Cooper's Hawk (*Accipiter cooperii*), a Sharp-shinned Hawk (*Accipiter striatus*), and a Swainson's Hawk (*Buteo swainsoni*; Maré and Graham, 1976), with lesions described as typical for the disease. While the present manuscript was under review, the virus associated with this disease in falcons and owls was shown to be columbid herpesvirus-1 (Gailbreath and Oaks, 2008).

Gross lesions of inclusion body disease of falcons typically include hepatomegaly, splenomegaly, and punctate to approximately 3-mm-diameter pale tan foci in the liver, spleen, bone marrow, and intestine (Graham et al., 1975). Histologic lesions include degeneration and necrosis, with associated intranuclear inclusion bodies in the liver, spleen, bone marrow, intestine, and cecal-associated lymphoid tissue ("cecal tonsils"; Graham et al., 1975). In experimentally induced cases, necrosis

was also noted microscopically in other tissues, including the thymus, bursa of Fabricius, thyroid gland, choroid plexus, kidney, pancreas, and gonads (Graham and Maré, 1976).

Herpesvirus infection often causes subclinical or mild disease in the natural host species and fatal disease in aberrant species. It has been speculated that a separate avian species serves as the natural host for falconid herpesvirus-1 and that falcons acquire the disease through ingestion of infected prey species, most likely pigeons/Rock Pigeons (*Columba livia*; Ritchie, 1995). Disease has been observed in falcons after ingestion of pigeons (Ward et al., 1971; Kocan et al., 1977), and falcons with a known history of ingesting pigeons have developed disease due to columbid herpesvirus-1 (Gailbreath and Oaks, 2008). Serologic evidence has shown cross-reaction between herpesvirus isolated from falcons with inclusion body disease and herpesvirus isolates from falcons, pigeons, and owls (Kaleta, 1990). A single previous report demonstrated similar DNA cleavage patterns with restriction endonuclease digestion between falcon and pigeon herpesvirus isolates (Aini et al., 1993). Recent work by Gailbreath and Oaks (2008) correlates inclusion body disease in falcons and owls with infection by columbid herpesvirus-1. This paper describes gross, histologic, and electron microscopic findings consistent with inclusion body disease in two Cooper's Hawks, with polymerase chain reaction (PCR) detection of columbid herpesvirus-1 genetic material in both hawks.

## MATERIALS AND METHODS

### Case histories

**Hawk 1:** A free-ranging juvenile female Cooper's Hawk was found moribund inside a warehouse in Chicago, Illinois, USA (41°51'N, 87°39'W) and died during examination. The carcass was submitted through the Cook County Forest Preserve District Wildlife Field Office for examination. A complete necropsy was performed by the University of Illinois

Zoological Pathology Program in Maywood, Illinois, USA.

**Hawk 2:** A free-ranging adult female Cooper's Hawk found near Lansing, Michigan, USA (42°43'N, 84°3'W) was submitted to the Michigan State University Veterinary Teaching Hospital with clinical signs of ataxia, difficulty standing, and left wing droop. No history previous to admission was available, and head trauma was suspected. The hawk was given supportive care but died on the sixth day of hospitalization. A complete necropsy was performed at the Michigan State University Animal Health Diagnostic Laboratory.

### Light microscopy

For both cases, representative tissues from all body systems were collected and fixed in 10% neutral buffered formalin. After fixation, tissues were routinely processed, embedded in paraffin, sectioned, and 5- $\mu$ m-thick sections were stained with hematoxylin and eosin. For PCR, several 50- $\mu$ m sections of paraffin block containing liver and spleen were submitted to the University of Florida, Gainesville, Florida, USA.

### Electron microscopy

Samples were processed for transmission electron microscopy by postfixation in 3% glutaraldehyde and embedding in Epon-Araldite resin (Polysciences, Warrington, Pennsylvania, USA). Less than 1- $\mu$ m-thick sections of the samples were stained with uranyl acetate and lead citrate. Sections were examined using a transmission electron microscope (Philips 301, Philips Electronic Instruments, Mahwah, New Jersey, USA).

### Polymerase chain reaction

DNA was extracted from paraffin-embedded tissue using the DNeasy DNA tissue kit (QIAGEN, Valencia, California, USA). Nested PCR amplification of a portion of the herpesvirus DNA-dependent DNA polymerase gene was performed using previously described methods (VanDevanter et al., 1996). The PCR product was resolved in a 1% agarose gel. The band was excised and purified using the QIAquick gel extraction kit (QIAGEN). The purified product was directly sequenced using the Big-Dye Terminator kit (Perkin-Elmer, Branchburg, New Jersey, USA), and it was analyzed using an automated sequencer (ABI377, PerkinElmer). The product was edited, and the primer sequences were removed; the resulting sequence was compared with those in GenBank (National Center

for Biotechnology Information, Bethesda, Maryland, USA), European Molecular Biology Laboratory (Cambridge, UK), and Data Bank of Japan (Mishima, Shizuoka, Japan) databases using TBLASTX and BLASTN (Altschul et al., 1997).

## RESULTS

On gross examination, hawk 1 had adequate skeletal musculing but scant adipose stores, and it was deemed to be in adequate nutritional status. The spleen was markedly enlarged, soft, and red mottled yellow. The liver was mottled pale brown to dark red, and it had rare randomly distributed pinpoint to 1-mm white foci on section. Thymus and bursa of Fabricius were grossly within normal limits as were remaining organ systems. Hawk 2 had marked atrophy of pectoral muscles. The liver and the spleen were mildly enlarged and mottled. Remaining organ systems were grossly normal.

Histologically, the splenic parenchyma of hawk 1 was diffusely necrotic, with loss of approximately 95% of the lymphoid tissue and replacement of most parenchyma with abundant fibrin and cellular debris. Few remaining lymphocytes contained eosinophilic intranuclear inclusion bodies with margination of chromatin. The liver had few random multifocal regions of necrosis making up approximately 5–10% of the hepatic parenchyma. Few hepatocytes in the areas surrounding regions of necrosis contained eosinophilic intranuclear inclusions with margination of chromatin and often a distinct clear zone (halo) surrounding the inclusion (Fig. 1). Occasionally, regions of hepatic necrosis were surrounded by thin bands of immature hypercellular fibrous connective tissue. Additional hepatic lesions included moderate intracellular and extracellular cholestasis and mild biliary reduplication. Foci of necrosis with surrounding cells containing intranuclear inclusion bodies were also noted in the bone marrow, thymus, bursa of Fabricius, parathyroid gland, thyroid gland, pancreas, cecal lymphoid tissue,

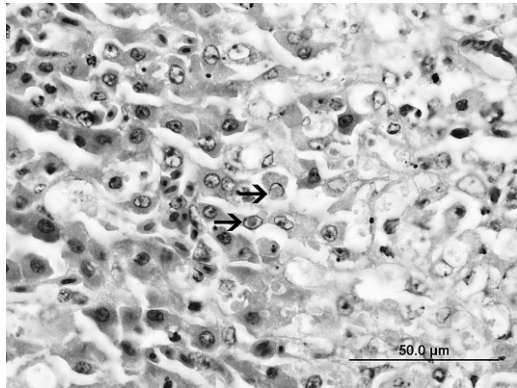


FIGURE 1. Liver, Cooper's Hawk (*Accipiter cooperii*) (hawk 1). Hepatic tissue on the right side of the image is necrotic. Occasional hepatocytes at the border between necrotic and viable tissue contain eosinophilic intranuclear inclusions (arrows). H&E stain. Bar=50 μm.

and intestinal lymphoid tissue. In hawk 2, histologic findings included few small foci of hepatic necrosis and multifocal zones of splenic necrosis with accumulations of fibrinoid material. Numerous scattered hepatocytes and splenic histiocytes contained eosinophilic intranuclear inclusions.

Transmission electron microscopy demonstrated enlarged hepatocyte nuclei containing variable numbers of 100–110-nm nucleocapsids, with margination of chromatin and nucleoli (Fig. 2a, c). Budding of virions from the nuclear membrane was evident, and 180-nm enveloped virions were noted in the cytoplasm adjacent to the nucleus (Fig. 2b).

Aerobic bacterial culture of the spleen of hawk 1 yielded heavy *Bacillus* sp. and *Escherichia coli*, both considered contaminants. Virus isolation was not attempted in hawk 1; in hawk 2 virus isolation attempts using chicken embryo fibroblast cell culture (Schat and Purchase, 1989) were unsuccessful.

Amplification resulted in a 181-base pair product. BLASTN results for the sequence showed 100% nucleotide homology with columbid herpesvirus-1 DNA polymerase gene (GenBank accession no.

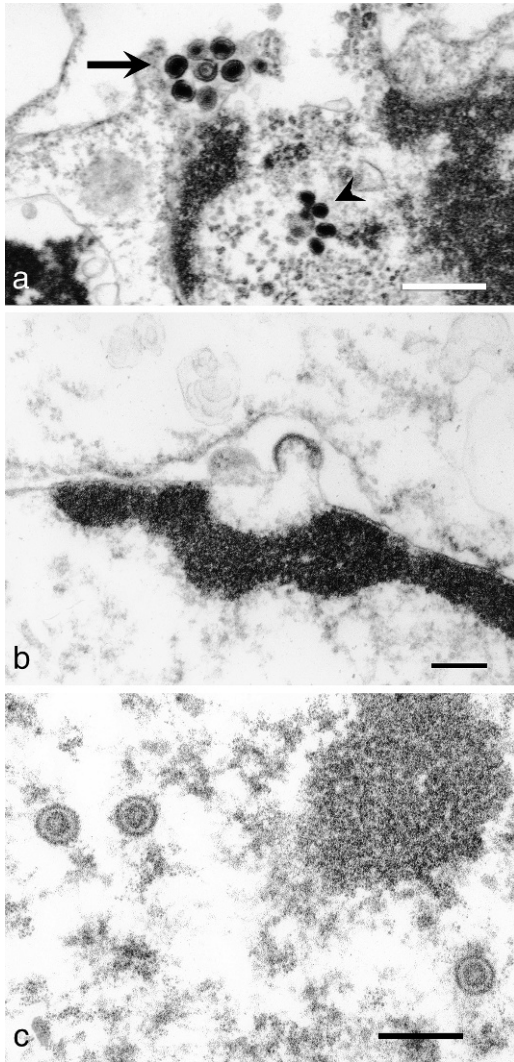


FIGURE 2. Liver, Cooper's Hawk (*Accipiter cooperii*) (hawk 2). Transmission electron microscopy. a. Herpesvirus nucleocapsids within the nucleus (arrowhead) and enveloped virions in the cytoplasm (arrow). Bar=500 nm. b. Virions budding from the nuclear membrane. Bar=200 nm. c. Nucleocapsids within the nucleus. Bar=200 nm.

AF141890), a member of the subfamily *Alphaherpesvirinae*, genus *Mardivirus*. Sequence data were submitted to GenBank under accession number EF623994.

#### DISCUSSION

The herpesviruses of mammals, birds, and reptiles are divided into the subfam-

ilies *Alphaherpesvirinae*, *Betaherpesvirinae*, and *Gammapherpesvirinae*, which are further subdivided by genus and species. Sequence data have shown that all herpesviruses of birds, characterized to date, are in the subfamily *Alphaherpesvirinae*. Initial taxonomy schemes were based on properties of infection, host range, and behavior in culture. Currently, phylogenetic relationships of herpesviruses are formally based on genetic content, as defined by homology of nucleic acid sequences and identification of particular genes unique to a virus subset (Minson et al., 2000), which has resulted in some virus reclassification (Ehlers et al., 1999; Wellahan et al., 2003). In falcons and owls, herpesvirus disease can be due to columbid herpesvirus-1, based on DNA polymerase gene sequences (Gailbreath and Oaks, 2008). The sequence results in these two cases are homologous to the sequence for columbid herpesvirus-1 DNA polymerase gene found in Rock Pigeons (Ehlers et al., 1999). Sequences from this region have been found to be unique to each herpesvirus species (VanDevanter et al., 1996). A previous study of 22 herpesvirus species analyzed multiple variants of three species. Only single base pair variations that did not result in alteration of the amino acid sequence were seen within species (VanDevanter et al., 1996).

Most previous methods of identification and classification of herpesviruses isolated from raptors have been imprecise. Herpesviruses isolated from falcons in the genus *Falco* with inclusion body hepatitis cross-react serologically with herpesvirus isolates from falcons, pigeons, and owls (Maré and Graham, 1973; Potgieter et al., 1979; Tantawi et al., 1983; Kaleta, 1990). Serologic detection of falconid herpesvirus-1 in Accipitridae is rare (Schettler et al., 2001; Zsivanovits et al., 2004). Serum neutralization tests found that a herpesvirus isolate from an apparently healthy Bald Eagle (*Haliaeetus leucocephalus*) nestling was distinct from a disease-

associated falcon isolate (Docherty et al., 1983). The degree of cross-reactivity of antibodies to different species of nondomestic avian herpesviruses is unknown in the absence of sequence data. Experimental infection studies have been inconclusive. In one study, experimental infection with isolates from owls and falcons but not pigeons caused disease in American Kestrels (*Falco sparverius*; Maré and Graham, 1973). A Red-tailed Hawk (*Buteo jamaicensis*) inoculated with a falcon herpesvirus isolate did not develop clinical disease (Maré, 1975). In one study of the nucleic acid of herpesviruses of birds of prey, falcon and pigeon herpesvirus isolates were found to have similar DNA cleavage patterns after restriction endonuclease digestion (Aini et al., 1993). However, this method is less capable of differentiating herpesviruses than sequencing the DNA polymerase gene. Virus isolation has also been used; however, this is most often followed by immunologic identification, which is complicated by the close antigenic relatedness of many herpesviruses (Tantawi et al., 1983). In contrast, application of PCR and sequencing for detection and identification of herpesviruses provides a rapid, sensitive, and specific alternative for diagnosing herpesviral disease (VanDevanter et al., 1996). Falconid herpesvirus-1 and strigid herpesvirus-1 have been shown to be identical to columbid herpesvirus-1 based on partial sequences of the DNA polymerase gene (Gailbreath and Oaks, 2008). In the two cases presented in this paper, PCR testing resulted in the definitive identification of columbid herpesvirus-1 in accipiters with fatal inclusion body disease.

Previous phylogenetic analyses of herpesviruses suggest that many elements in the branching patterns of *Herpesviridae* are congruent with branching patterns for the corresponding host species (McGeoch and Davison, 1999) implying host-virus coevolution is common. In hosts for which they are adapted, herpesviruses often cause lesser disease than is seen in

aberrant hosts. There are numerous examples of herpesviruses causing more severe disease in aberrant hosts (Ostrowski et al., 1998; Dunowska et al., 2001; Landolfi et al., 2005). Like falcons in the genus *Falco*, hawks in the genus *Accipiter* primarily prey on birds, and it is likely that these Cooper's Hawks acquired the virus through preying on Rock Pigeons. Disease has been seen in other raptors after ingestion of Rock Pigeons (Ward et al., 1971; Kocan et al., 1977; Gailbreath and Oaks, 2008). Studies suggest that the prevalence of columbid herpesvirus infection in Rock Pigeons is very high (Vindevogel et al., 1981; Kaleta, 1990), whereas the seroprevalence in birds of prey is significantly lower (Schettler et al., 2001; Zsivanovits et al., 2004). Rock Pigeons are not a native North American species (Shorger, 1952), and in the absence of host-virus coevolution, Cooper's Hawks and other North American species are likely not adapted to columbid herpesvirus-1, and infection may result in fatal disease in these aberrant hosts. Alternatively, this virus may also be found to cause fatal disease in European raptors. Maintaining a virus of relatively low pathogenicity for the host that is highly pathogenic in predator species may provide a selective advantage for columbid herpesvirus-1-infected Rock Pigeon populations. PCR results implicate columbid herpesvirus-1 as the cause of inclusion body disease in these Cooper's Hawks, which correlate with PCR results for other raptors and expand the known range of potentially affected birds to include the Accipitridae.

#### ACKNOWLEDGMENTS

The authors appreciate the excellent technical assistance of J. Chladny and the histology laboratory of the University of Illinois Veterinary Diagnostic Laboratory, and Chris Anchor and the Forest Preserve District of Cook County Wildlife Field Office. Partial support for this study was obtained from the Cook County Department of Animal and Rabies Control Environmental Impact Program.

## LITERATURE CITED

- AINI, I., L. M. SHIH, A. E. CASTRO, AND Y. C. ZEE. 1993. Comparison of herpesvirus isolates from falcons, pigeons and psittacines by restriction endonuclease analysis. *Journal of Wildlife Diseases* 29: 196–202.
- ALTSCHUL, S. F., T. L. MADDEN, A. A. SCHÄFFER, J. ZHANG, Z. ZHANG, W. MILLER, AND D. J. LIPMAN. 1997. Gapped BLAST and PSI-BLAST: A new generation of protein database search programs. *Nucleic Acids Research* 25: 3389–3402.
- DOCHERTY, D. E., R. I. ROMAINE, AND R. L. KNIGHT. 1983. Isolation of a herpesvirus from a bald eagle nestling. *Avian Diseases* 27: 1162–1165.
- DUNOWSKA, M., G. J. LETCHWORTH, J. K. COLLINS, AND J. C. DEMARTINI. 2001. Ovine herpesvirus-2 glycoprotein B sequences from tissues of ruminant malignant catarrhal fever cases and healthy sheep are highly conserved. *Journal of General Virology* 82: 2785–2790.
- EHLERS, B., K. BORCHERS, C. GRUND, K. FROLICH, H. LUDWIG, AND H. J. BUHK. 1999. Detection of new DNA polymerase genes of known and potentially novel herpesviruses by PCR with degenerate and deoxynosine-substituted primers. *Virus Genes* 18: 211–220.
- GAILBREATH, K. L., AND J. L. OAKS. 2008. Herpesviral inclusion body disease in owls and falcons is caused by the pigeon herpesvirus (columbid herpesvirus 1). *Journal of Wildlife Diseases* 44: 427–433.
- GRAHAM, D. L., AND C. J. MARÉ. 1976. Clinical and pathological aspects of inclusion body disease (herpesvirus infection) of falcons (IBDF). In *Wildlife diseases*, L. A. Page (ed.). Plenum Press, New York, pp. 465–470.
- , F. P. WARD, AND M. C. PACKHAM. 1975. Inclusion body disease (herpesvirus infection) of falcons (IBDF). *Journal of Wildlife Diseases* 11: 83–91.
- KALETA, E. F. 1990. Herpesviruses of birds: A review. *Avian Pathology* 19: 193–211.
- KOCAN, A. A., L. N. POTGIETER, AND K. M. KOCAN. 1977. Inclusion body disease of falcons (Herpesvirus infection) in an American kestrel. *Journal of Wildlife Diseases* 13: 199–201.
- LANDOLFI, J. A., J. F. X. WELLEHAN, A. J. JOHNSON, AND M. KINSEL. 2005. Fatal human herpesvirus type 1 infection in a white-handed gibbon (*Hylobates lar*). *Journal of Veterinary Diagnostic Investigation* 17: 369–371.
- MARÉ, C. J. 1975. Herpesviruses of birds of prey. *Journal of Zoo Animal Medicine* 6: 6–11.
- , AND D. L. GRAHAM. 1973. Falcon Herpesvirus, the etiologic agent of inclusion body disease of falcons. *Infection Immunity* 8: 118–125.
- , AND ———. 1976. Pathogenicity and host range of the falcon herpesviruses. In *Wildlife diseases*, L. A. Page (ed.). Plenum Press, New York, pp. 471–482.
- MCGEOCH, D. J., AND A. J. DAVISON. 1999. The molecular evolutionary history of the herpesviruses. In *Origin and evolution of viruses*, E. Domingo, R. Webster and J. Holland (eds.). Academic Press, San Diego, pp. 441–465.
- MINSON, A. C., A. DAVISON, R. EBERLE, R. C. DESROSIERS, B. FLECKENSTEIN, P. E. PELLETT, B. ROIZMAN, AND M. J. STUDDERT. 2000. Family Herpesviridae. In *Virus taxonomy: Classification and nomenclature of viruses*. Seventh Report of the International Committee on the Taxonomy of Viruses, M. H. V. Van Regenmortel, C. M. Fauquet, D. H. L. Bishop, E. B. Carstens, M. K. Estes, S. M. Lemon, J. Maniloff, M. A. Mayo, D. J. McGeoch, C. R. Pringle and R. B. Wickner (eds.). Virology Division, International Union of Microbiological Societies, Academic Press, San Diego, California, pp. 203–225.
- OSTROWSKI, S. R., M. J. LESLIE, T. PARROTT, S. ABELT, AND P. E. PIERCY. 1998. B-virus from pet macaque monkeys: An emerging threat in the United States? *Emerging Infectious Diseases* 4: 117–121.
- POTGIETER, L. N., A. A. KOCAN, AND K. M. KOCAN. 1979. Isolation of a herpesvirus from an American kestrel with inclusion body disease. *Journal of Wildlife Diseases* 15: 143–149.
- RAMIS, A., N. MAJÓ, M. PUMAROLA, D. FONDEVILA, AND L. FERRER. 1994. Herpesvirus hepatitis in two eagles in Spain. *Avian Diseases* 38: 197–200.
- RITCHIE, B. W. 1995. Herpesviridae. In *Avian viruses: Function and control*, B. W. Ritchie (ed.). Wingers Publishing, Lake Worth, Florida, pp. 171–222.
- SCHAT, K. A., AND H. G. PURCHASE. 1989. Cell culture methods. In *A laboratory manual for the isolation and identification of avian pathogens*. 3rd Edition. H. G. Purchase, L. H. Arp, C. H. Domermuth and J. E. Pearsen (eds.). American Association of Avian Pathologists, Athens, Georgia, pp. 167–175.
- SCHETTLER, E., T. LANGGEMACH, P. SOMMER, J. STREICH, AND K. FROLICH. 2001. Seroepizootiology of selected infectious disease agents in free-living birds of prey in Germany. *Journal of Wildlife Diseases* 37: 145–152.
- SCHORGER, A. W. 1952. Introduction of the domestic pigeon. *Auk* 69: 462–463.
- TANTAWI, H. H., Z. I. IMAN, C. J. MARE, R. EL-KARAMANY, M. A. SHALABY, AND F. TAYEB. 1983. Antigenic relatedness of pigeon herpes encephalomyelitis virus to other avian herpesviruses. *Avian Diseases* 27: 563–568.
- VANDEVANter, D. R., P. WARRENER, L. BENNETT, E. R. SCHULTZ, S. COULTER, R. L. GARBER, AND T. M. ROSE. 1996. Detection and analysis of diverse herpesviral species by consensus primer PCR. *Journal of Clinical Microbiology* 34: 1666–1671.

- VINDEVOGEL, H. U., L. DAGENAI, B. LANSIVAL, AND P. P. PASTORET. 1981. Incidence of rotavirus, adenovirus and herpesvirus infection in pigeons. *Veterinary Record* 109: 285–286.
- WARD, F. P., D. G. FAIRCHILD, AND J. V. VUICICH. 1971. Inclusion body hepatitis in a prairie falcon. *Journal of Wildlife Diseases* 7: 120–124.
- WELLEHAN, J. F. X., M. GAGEA, D. A. SMITH, W. M. TAYLOR, Y. BERHANE, AND D. BIENZLE. 2003. Characterization of a herpesvirus associated with tracheitis in Gouldian finches (*Erythrura [Chloebia] gouldiae*). *Journal of Clinical Microbiology* 41: 4054–4057.
- ZSIVANOVITS, P., N. A. FORBES, L. T. ZVONAR, M. R. WILLIAMS, M. LIERZ, C. PRUSAS, AND M. M. HAFEZ. 2004. Investigation into the seroprevalence of falcon herpesvirus antibodies in raptors in the UK using virus neutralization tests and different herpesvirus isolates. *Avian Pathology* 33: 599–604.

*Received for publication 5 June 2007.*