

Isolation of *Mycobacterium mageritense* from the Lung of a Harbor Porpoise (*Phocoena phocoena*) with Severe Granulomatous Lesions

Authors: Morick, D., Kik, M., de Beer, J., van der Zanden, A. G. M., and Houwers, D. J.

Source: Journal of Wildlife Diseases, 44(4) : 999-1001

Published By: Wildlife Disease Association

URL: <https://doi.org/10.7589/0090-3558-44.4.999>

BioOne Complete (complete.BioOne.org) is a full-text database of 200 subscribed and open-access titles in the biological, ecological, and environmental sciences published by nonprofit societies, associations, museums, institutions, and presses.

Your use of this PDF, the BioOne Complete website, and all posted and associated content indicates your acceptance of BioOne's Terms of Use, available at www.bioone.org/terms-of-use.

Usage of BioOne Complete content is strictly limited to personal, educational, and non - commercial use. Commercial inquiries or rights and permissions requests should be directed to the individual publisher as copyright holder.

BioOne sees sustainable scholarly publishing as an inherently collaborative enterprise connecting authors, nonprofit publishers, academic institutions, research libraries, and research funders in the common goal of maximizing access to critical research.

Isolation of *Mycobacterium mageritense* from the Lung of a Harbor Porpoise (*Phocoena phocoena*) with Severe Granulomatous Lesions

D. Morick,^{1,4} M. Kik,² J. de Beer,³ A. G. M. van der Zanden,³ and D. J. Houwers² ¹Seal Rehabilitation and Research Center (SRRC), 9968 AG Pieterburen, The Netherlands; ²Veterinary Pathological & Microbiological Diagnostic Centres, Veterinary Faculty, Utrecht University, 3548 CL Utrecht, The Netherlands; ³Medical Microbiology & Infection Control, Gelre Hospitals, 7334 DZ Apeldoorn, The Netherlands; ⁴Corresponding author (email: dannymorick@hotmail.com)

ABSTRACT: Post-mortem investigation of a harbor porpoise (*Phocoena phocoena*) found dead on the beach of the island of Vlieland, The Netherlands, revealed severe granulomatous changes in the right lung lobe. Ziehl Neelsen staining demonstrated relatively large acid-fast rods. Mycobacterial culture yielded a fast-growing mycobacterium, which was identified by molecular biological methods as *Mycobacterium mageritense*. Autolysis prevented histopathology. It was tentatively concluded that the granulomatous changes were the cause of porpoise's death and that *M. mageritense* was the causative agent. This is the first report of the isolation and molecular identification of this mycobacterium in a nonhuman animal species and the first association with the marine environment.

Key words: Granulomatous lesions, lung, *Mycobacterium mageritense*, *Phocoena phocoena*.

A subadult (1–4-yr-old) female harbor porpoise (*Phocoena phocoena*) was found dead on 31 July 2006 on the beach of the island of Vlieland, The Netherlands. The animal had probably been dead for a few weeks. It was refrigerated for 4 days until the necropsy was performed at the Seal Rehabilitation and Research Center (SRRC), Pieterburen, The Netherlands. The animal weighed 39.08 kg and was 148 cm in length (head to tail). The carcass was in moderate state of autolysis and poor nutritional condition (blubber thickness at sternum, 6 mm). On external examination, parts of the skin were found to be peeling off, there was mild scavenger damage probably by birds on the dorsal area of the body and a small amount (approximately 10 g) of sand and five small (10-mm-diameter) shells were found in the oral cavity.

The thoracic cavity contained 700 ml of dark red fluid. Approximately 50 lungworms

(*Pseudalius inflexus*) were found at the bifurcation of the trachea. Two lungworms were also present in the right ventricle of the heart. The most pronounced pathologic change was the enlarged right lung, with multifocal, protruding granulomas. These firm, gray-colored nodules ranged from 2 mm to 17 mm in diameter. They were also found on the thoracic wall, diaphragm, pericardium, and aorta (Fig. 1a, b). No similar lesions were found in other organs. Furthermore, the stomach contained about 1,000 stomach worms (*Anisakis simplex*), and 700 ml of dark red to brown fluid was found in the abdominal cavity. Tissue samples were taken for histopathology, but meaningful examination was not possible due to a massive degree of autolysis.

Because the gross pathology raised suspicion of mycobacterial involvement, smears of granulomatous tissues were made. Ziehl-Neelsen stains revealed few, relatively large, acid-fast rods. For further investigation, tissue samples were decontaminated and liquefied by standard procedure (Isenberg, 2004). Polymerase chain reaction (PCR) assays directly on this material targeting the IS6110 (Savelkoul et al., 2005) and 16S rRNA genes were negative. Löwenstein-Jensen (L-J) slants with and without pyruvate and liquid *Mycobacterium* media from the MB Bact system (BioMérieux, Boxtel, The Netherlands) were inoculated and subsequently incubated. The latter media revealed substantial growth after 5 days; DNA was extracted using QIAamp DNA mini elute kit (QIAGEN, Benelux, The Netherlands). Real-time PCR for IS6110, which is specific for members of the *Mycobacterium tuberculosis* complex, was negative,

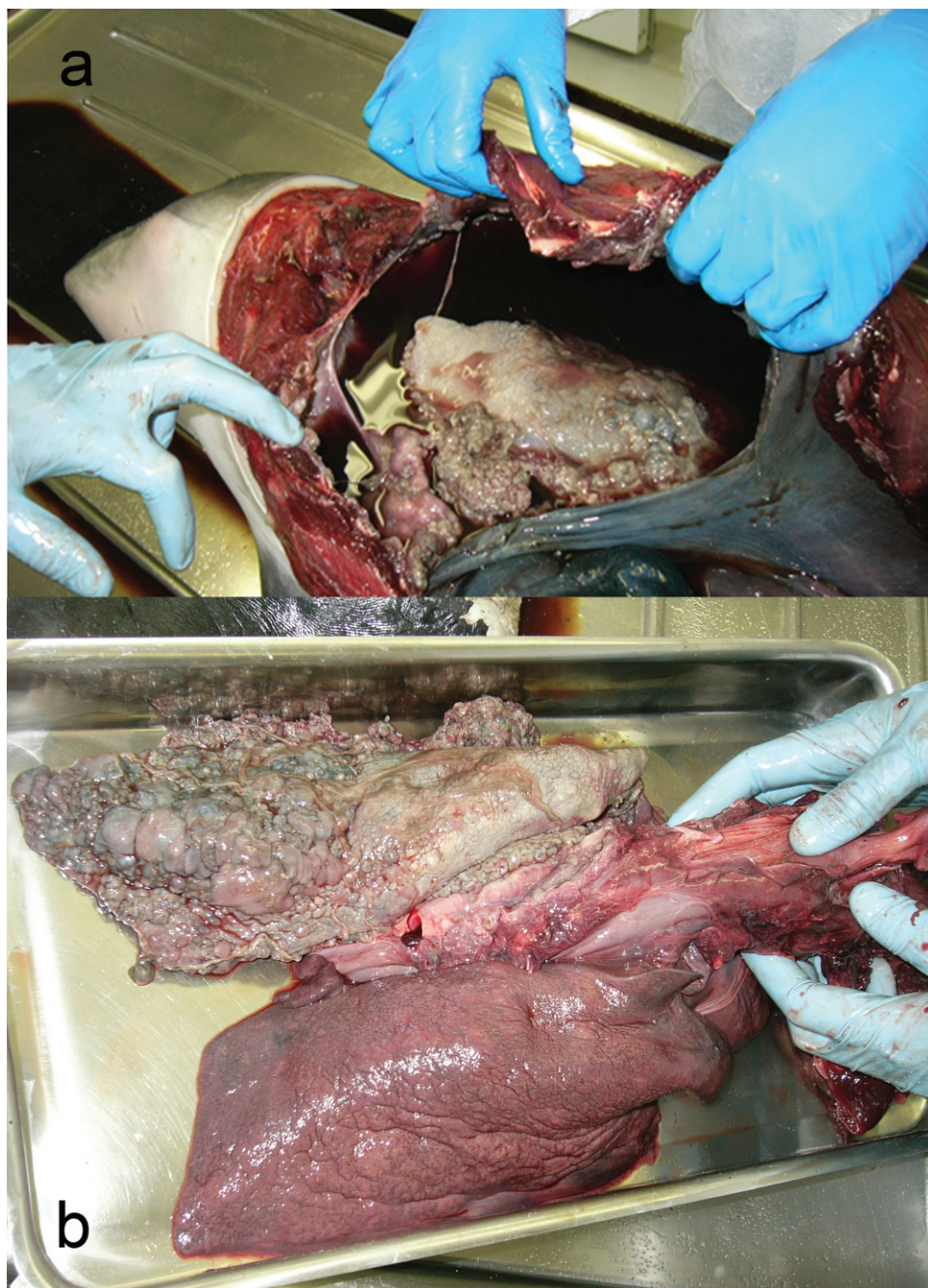


FIGURE 1. *Mycobacterium mageritense* in a harbor porpoise (*Phocoena phocoena*): (a) Thoracic cavity viewed from the left; dark red fluid is present in the thoracic cavity and there are multiple granulomas in the lung and on the diaphragm, and pericardium. (b) Overview of lungs; one lung is enlarged and has multiple granulomas.

but the real-time assay for 16S rDNA was positive. The 16S rRNA gene amplification product from the cultured strain was subjected to sequence analysis using a

3100-Avant sequencer (Applied Biosystems, Foster City, California, USA). The nucleotide sequence obtained was assembled, edited, and analyzed with Lasergene

software (DNASar, Inc., Madison, Wisconsin, USA), deposited in GenBank, and compared with known 16S rDNA sequences using BLAST. The 16S rDNA (434-base pair) sequence proved to have a 100% homology with *M. mageritense*.

Mycobacteria are aerobic, nonmotile bacteria that occur widely in nature and range from soil-dwelling saprophytes to pathogens of humans and animals. *Mycobacterium mageritense* is a relatively new species in the group of rapidly growing nonpigmented mycobacteria. It was initially isolated from five human sputa in Spain during 1987–1989 (Domenech et al., 1997), without apparent clinical relevance. Wallace et al. (2002) described six more human isolates of *M. mageritense* infection in the United States between 1999 and 2002, some of which were associated with clinical disease, i.e., infected wounds. More recently, two cases of furunculosis associated with a footbath at a nail salon (Gira et al., 2004), a catheter-related bloodstream infection (Ali et al., 2007), and a spontaneously resolving pulmonary infection (Miki et al., 2007) by *M. mageritense* were reported. The clinical presentations are similar to *M. fortuitum*-associated lesions, and it has been suggested that *M. mageritense* isolates have been mistaken in the past for *M. fortuitum* because they are not easily distinguished in the laboratory. It should be noted that finding only a few acid-fast rods in the affected tissue is common in these atypical mycobacterial infections.

Since 1982, 210 necropsies of stranded harbor porpoise were performed at SRRC, in addition to the necropsies of numerous other marine mammals. To the best of our knowledge, this is the first report of isolation of this organism from a marine mammal and even from a nonhuman animal species.

The autolytic state of the carcass and its organs prevented proper histologic examination that could have confirmed the mycobacterial nature of the lesions. Howev-

er, their typical granulomatous character upon gross pathology was suggestive. The parasitic infestation found in this case is a common finding in harbor porpoises that apparently died of other causes. This animal demonstrated severe, typical granulomatous lesions in the lung in association with the isolation from those tissues of *M. mageritense*, which suggests that the infection with this agent was the cause of death of this harbor porpoise. The source of infection was most probably the marine biotope.

LITERATURE CITED

- ALI, S., F. A. KHAN, AND M. FISHER. 2007. Catheter-related bloodstream infection caused by *Mycobacterium mageritense*. *Journal of Clinical Microbiology* 45: 273.
- DOMENECH, P., M. S. JIMENEZ, M. C. MENENDEZ, T. J. BULL, S. SAMPER, A. MANRIQUE, AND M. J. GARCIA. 1997. *Mycobacterium mageritense* sp. nov. *International Journal of Systematic Bacteriology* 47: 535–540.
- GIRA, A. K., A. H. REISENAUER, L. HAMMOCK, U. NADIMINTI, J. T. MACY, A. REEVES, C. BURNETT, M. A. YAKRUS, S. TONEY, B. J. JENSEN, H. M. BLUMBERG, S. W. CAUGHMAN, AND F. S. NOLTE. 2004. Furunculosis due to *Mycobacterium mageritense* associated with footbaths at a nail salon. *Journal of Clinical Microbiology* 42: 1813–1817.
- ISENBERG, H. D. 2004. Clinical microbiology procedures handbook, Chapter 7.1.2.1, 2nd Edition. American Society for Microbiology, Washington, D.C.
- MIKI, M., M. SHIMIZUKAWA, H. OKAYAMA, AND Y. KAZUMI. 2007. A case of pulmonary *Mycobacterium mageritense* infection: The difficulty of differential diagnosis of granulomatous lung diseases. *Kekkaku* 82: 189–194.
- SAVELKOU, P. H. M., A. CATSBURG, S. MULDER, L. OOSTENDORP, J. SCHIRM, H. WILKE, A. G. M. VAN DER ZANDEN, AND G. T. NOORDHOEK. 2005. Detection of *Mycobacterium tuberculosis* complex with real time PCR: Comparison of different primer-probe sets based on the IS6110 element. *Journal of Microbiological Methods* 66: 177–180.
- WALLACE, R. J. JR., B. A. BROWN-ELLIOTT, L. HALL, G. ROBERTS, R. W. WILSON, L. B. MANN, C. J. CRIST, S. H. CHIU, R. DUNLAP, M. J. GARCIA, J. TODD BAGWELL, AND K. C. JOST, JR. 2002. Clinical and laboratory features of *Mycobacterium mageritense*. *Journal of Clinical Microbiology* 40: 2930–2935.

Received for publication 3 September 2007.