

Pulmonary Infection due to *Mycobacterium bovis* in a Black Rhinoceros (*Diceros bicornis minor*) in South Africa

Authors: Espie, Ian W., Hlokwe, Tiny M., van Pittius, Nicolaas C. Gey, Lane, Emily, Tordiffe, Adrian S. W., et al.

Source: Journal of Wildlife Diseases, 45(4) : 1187-1193

Published By: Wildlife Disease Association

URL: <https://doi.org/10.7589/0090-3558-45.4.1187>

BioOne Complete (complete.BioOne.org) is a full-text database of 200 subscribed and open-access titles in the biological, ecological, and environmental sciences published by nonprofit societies, associations, museums, institutions, and presses.

Your use of this PDF, the BioOne Complete website, and all posted and associated content indicates your acceptance of BioOne's Terms of Use, available at www.bioone.org/terms-of-use.

Usage of BioOne Complete content is strictly limited to personal, educational, and non - commercial use. Commercial inquiries or rights and permissions requests should be directed to the individual publisher as copyright holder.

BioOne sees sustainable scholarly publishing as an inherently collaborative enterprise connecting authors, nonprofit publishers, academic institutions, research libraries, and research funders in the common goal of maximizing access to critical research.

Pulmonary Infection due to *Mycobacterium bovis* in a Black Rhinoceros (*Diceros bicornis minor*) in South Africa

Ian W. Espie,¹ Tiny M. Hlokwe,² Nicolaas C. Gey van Pittius,³ Emily Lane,¹ Adrian S. W. Tordiffe,¹ Anita L. Michel,² Annéle Müller,³ Antoinette Kotze,^{1,4} and Paul D. van Helden^{3,5} ¹National Zoological Gardens of South Africa, PO Box 754, Pretoria 0001, South Africa; ²Bacteriology Section, ARC-Onderstepoort Veterinary Institute, Private Bag X05, Onderstepoort 0110, South Africa; ³DST/NRF Centre of Excellence for Biomedical TB Research, US/MRC Centre for Molecular and Cellular Biology, Division of Molecular Biology and Human Genetics, Department of Biomedical Sciences, Faculty of Health Sciences, Stellenbosch University, PO Box 19063, Tygerberg 7505, South Africa; ⁴Genetics Department, University of the Free State, PO Box 339, Bloemfontein 9300, South Africa; ⁵Corresponding author (email: pvh@sun.ac.za)

ABSTRACT: We report a case of tuberculosis due to infection with *Mycobacterium bovis* in an elderly male black rhinoceros (*Diceros bicornis minor*) from the Limpopo Province in South Africa. The animal was euthanized due to very poor condition, old age, and dental attrition. Necropsy examination revealed two small nonencapsulated granulomas (~40-mm diameter) in the dorsocaudal lobe of the left lung. Sequencing of isolated crude lung tissue PCR product and boiled lung culture samples confirmed that the causative organism was *M. bovis*. Genotyping revealed limited similarities with *M. bovis* strains isolated thus far from South African cattle or wildlife. The source of the infection could not be determined. This case illustrates that *M. bovis* could impact conservation of free-ranging rare and endangered species. Effective diagnostics are urgently needed for different animal species, such as white or black rhinoceroses, to certify with a reasonable degree of certainty that these animals are free of tuberculosis in natural habitats.

Key words: Black rhinoceros, *Diceros bicornis minor*, genetic typing, *Mycobacterium bovis*, pulmonary granuloma.

Mycobacterium bovis is a common pathogenic mycobacterium, and it has a very broad host species range, although it is arguably found mostly in bovidae with cattle as the maintenance hosts (Cousins et al., 2004). In areas where *M. bovis* is found at high prevalence, it can cross the species and ecologic niche barrier and pose a threat to rare and endangered mammals by infecting them. It is known that African buffalo (*Syncerus caffer*) in some game parks have become infected

with bovine tuberculosis (bTB) (Bengis et al., 1996; De Vos et al., 2001; Rodwell et al., 2001; Cousins et al., 2004; Michel et al., 2006), and buffalo in herds have become new maintenance species for bTB (De Vos et al., 2001). A variety of “spill-over” species in the Kruger National Park have been found to be infected with bTB, such as chacma baboon (*Papio ursinus*), lion (*Panthera leo*), cheetah (*Acinonyx jubatus*), kudu (*Tragelaphus strepsiceros*), and leopard (*Panthera pardus*), as a result of the spreading infection of bTB in the buffalo herds in the park (Keet et al., 1996, 2001; De Vos et al., 2001; Michel et al., 2009).

There are no published reports on bovine tuberculosis in free-ranging black or white rhinoceroses, although several cases in captive rhinoceros have been documented (Mann et al., 1981; Stetter et al., 1995). At the National Zoological Gardens (NZG) of South Africa, Gauteng, Pretoria, a black rhinoceros died in 1956 from suspected generalized tuberculosis, but this remains unconfirmed by culture (Hofmeyr, 1956). In the Hluhluwe-iMfolozi Park (HiP), histopathologic examination of a pelvic lymph node taken from a free-ranging black rhinoceros revealed lesions consistent with tuberculosis (D. Cooper, KwaZulu Natal, pers. comm., 2008 and N. Kriek, Faculty of Veterinary Science, University of Pretoria, pers. comm., 2008), but no culture result is available. The antemortem diagnosis of

tuberculosis in rhinoceros remains problematic because the intradermal tuberculin test yields inconclusive results in most cases (Bengis, State Veterinarian, Kruger National Park, pers. comm., 2008), and a survey conducted on captive rhinoceroses in North America confirms this (Godfrey et al., 1990). This report describes a case of *M. bovis* infection in a black rhinoceros and discusses potential implications of this finding for wildlife conservation.

In June 2002, the National Zoological Gardens received an elderly black rhinoceros bull (estimated age 35–40 yr at the time) from the Mkuzi Game Reserve, KwaZulu Natal. The translocation was done because he was territorially displaced by a dominant bull earlier that same year. He was captured outside the Mkuzi Game Reserve and transported to the animal-holding facilities in the Hluhluwe-iMfolozi Park. From there, he was translocated to the NZG's Mokopane Biodiversity Conservation Centre, Mokopane, Limpopo Province (24°10'14.1"S, 29°1'10.9"E), South Africa, where he was kept in a fenced camp of ~1.5 ha in size, with vegetation representing mixed-sour bushveld.

The animal experienced several constraints, such as a missing left eye, assumed to have been caused by previous trauma before the translocation. He was also hard of hearing in contrast to other black rhinoceroses. The natural vegetation in the enclosure was supplemented daily with lucerne hay and "Boskos" cubes (Wes Enterprises, Thabazimbi Roller Mills, Thabazimbi, Limpopo Province). The "Boskos" cubes are manufactured as a by-product from bush clearing, and *Acacia* spp. and *Dycrostachus* trees are the main components. Access was provided to fresh drinking water, and a mud wallow was available, which was used frequently. Other free-ranging animals such as Helmeted Guineafowl (*Numida meleagris*), bush buck (*Tragelaphus scriptus*), nyala (*Tragelaphus angasii*), chacma baboon (*Papio ursinus*), bushpig (*Potamochoerus*

porcus), and warthog (*Phacochoerus aethiopicus*), opportunistically shared his camp and food on a regular basis. Adjoining the one side of the enclosure, there was a breeding herd of five African buffalo (*Syncerus caffer*). The rhinoceros was also accessible for close viewing by the visiting public through a cable fence.

In 2004, the rhinoceros developed a corneal ulcer on his right eye, which was successfully treated with antibiotics injected into the subconjunctiva, and the third eyelid flap was sutured over the cornea and kept in position for 10 days. In June 2005, his condition started to deteriorate when he developed chronic intermittent diarrhea, the cause of which could not be determined after numerous negative fecal cultures to identify pathogenic bacteria. In November 2007, the rhinoceros was euthanized.

A full necropsy examination was performed and indicated, aside from abundant *Amblyomma* ticks in the axilla and inguinal areas, severe weight loss and organ atrophy, marked adrenocortical hyperplasia, scattered minor cutaneous lacerations, moderate right otitis externa, a rubbery gray urolith in the left kidney (50×30×17 mm), and two firm discrete mottled tan to cream foci (40-mm diameter) in the left caudodorsal lung lobe (Fig. 1). No affected thoracic or mesenteric lymph nodes were found.

No acid-fast organisms were seen in a Ziehl-Neelsen stained impression smear of the lung lesion. On routine histology, the lung lesions consisted of necrogranulomatous pneumonia characterized by discrete and coalescing unencapsulated foci of central variably mineralized necrotic debris surrounded by loose aggregates of epithelioid macrophages, Langerhans-type multinucleate giant cells, lymphocytes, and plasma cells (Fig. 2). Smaller similar granulomas occurred in adjacent macroscopically unaffected lung parenchyma. Additional histologic findings were incidental and included tissue hemosiderosis (liver, spleen, small intestine), axillary skin

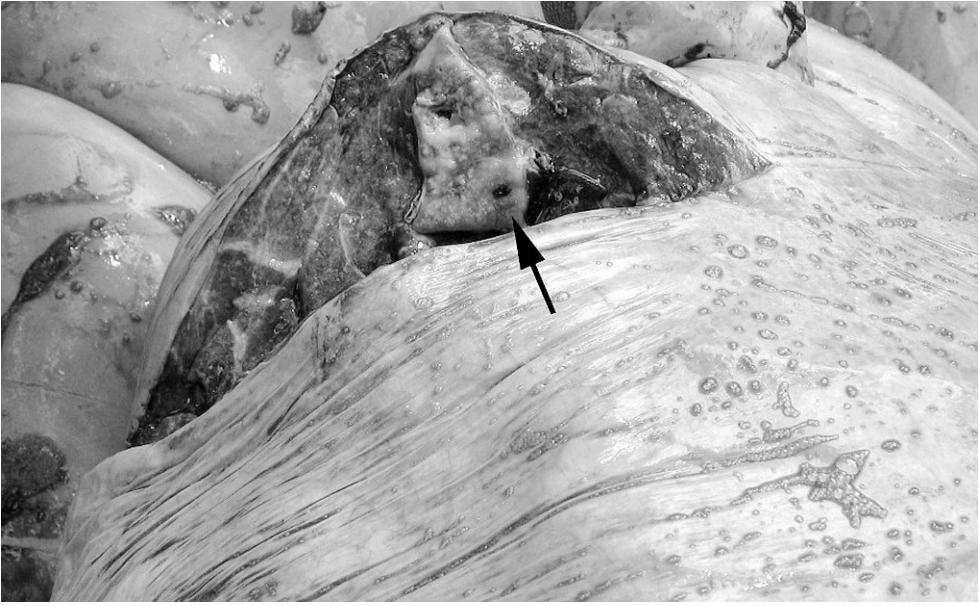

FIGURE 1. A transverse cut through an unencapsulated tuberculosis granuloma in the dorsocaudal lobe of the left lung, ~40 mm in diameter. Bar=1.5 cm.

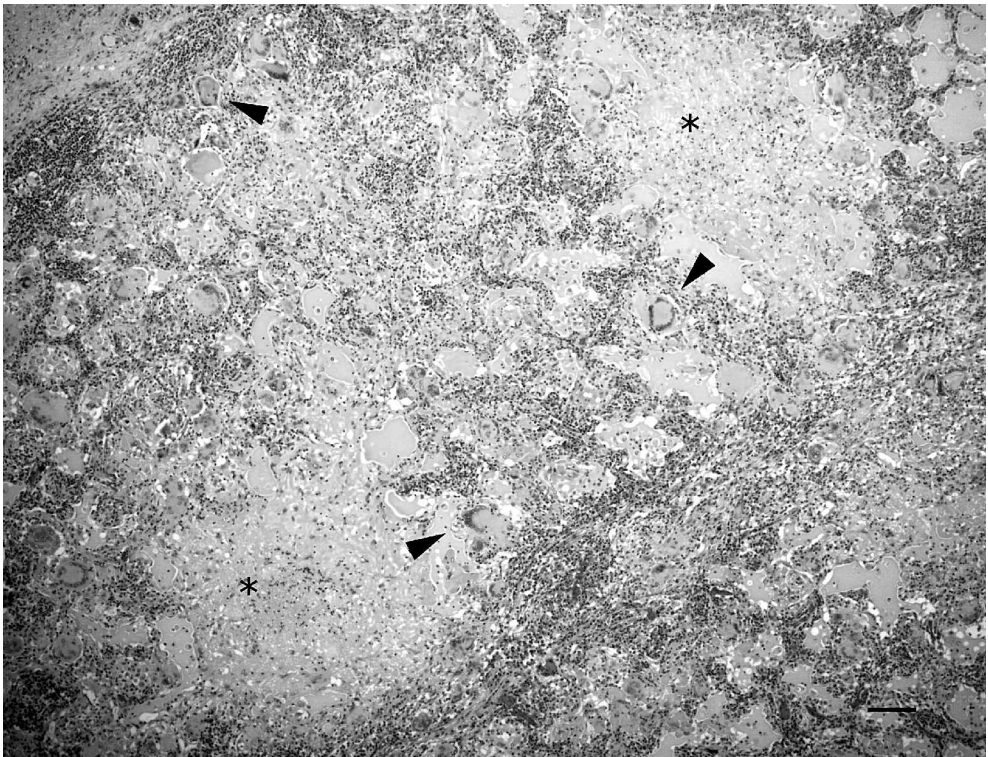


FIGURE 2. Necrogranulomatous pneumonia found in this black rhinoceros. Note the central areas of necrosis (*) and multinucleate giant cells (arrowheads). H&E stain. Bar=100 μ m.

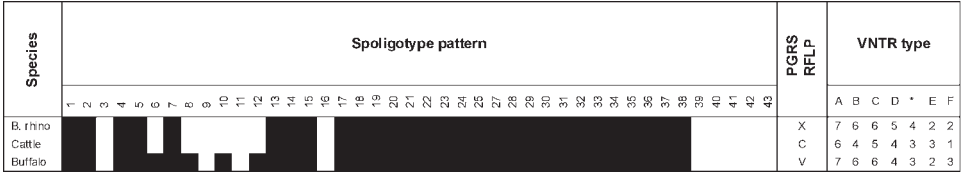


FIGURE 3. Spoligotype, VNTR, and PGRS-RFLP profiles for the SP8-type *M. bovis* isolated from the black rhinoceros compared to isolates from buffalo and cattle.

hyperkeratosis, inguinal lymph node an-thrasilicosis and medullary plasmacytosis, minor membranoproliferative glomerulo-nephritis and renal medullary interstitial fibrosis and amyloidosis, and mild cor-onary arteriosclerosis. Sera collected 62 days prior to and on the day of euthanasia tested negative for antibodies to *M. bovis* using the BovidTB STAT-PAK (Chem-bio Diagnostic Systems, Inc., Medford, New York, USA). This test outcome may either indicate that the rhino did not mount an antibody response due to early infection, or, alternatively, the test system may be unsuitable for black rhinoceros.

Fresh granulomatous tissue samples were processed according to standard methods (Michel et al., 2009), and the acid-fast growth obtained was subjected to DNA extraction, followed by 16S rDNA polymerase chain reaction (PCR) se-quencing and multiplex-PCR amplifica-tion to identify members of the *Mycobac-terium tuberculosis* complex (Warren et al., 2006). The sample tested positive for *M. bovis*. Genetic typing of the strain using spoligotyping (Kamerbeek et al., 1997) revealed a pattern consistent with *M. bovis* type SP8, which had been previously isolated from cattle in the Western and Eastern Cape, and also in Swaziland. The spacers that are deleted in the SP8 type are 3, 6, 8–12, 16, 39–43.

For restriction fragment length poly-morphism (RFLP) typing, the IS6110 and PGRS genetic markers were used for their high discriminatory power among South African *M. bovis* isolates (Michel et al., 2008, 2009). The *M. bovis* isolated from the black rhino revealed a unique banding pattern when hybridized with the PGRS

probe, despite some similarities with bovine isolates of the spoligotype SP8 from the Eastern Cape and the dominant *M. bovis* strain in the Hluhluwe-iMfolozi Park (HIP), respectively (Michel et al., 2008, 2009) (data not shown). The IS6110 RFLP produced a banding pattern con-sistent with the C1 profile, which is one of the two most common and less discrimi-natory IS6110 profiles in cattle. Buffalo in HiP as well as the cattle isolate shown in Figure 3 were classified as C2 strains (Michel et al., 2008, 2009). The same set of strains was subjected to an analysis of variable numbers of tandem repeat (VNTR) sequences, which again identified a unique genetic profile for the *M. bovis* from the black rhinoceros (Fig. 3).

It is currently unknown when the animal contracted the infection, and the source of the *M. bovis* infection remains unclear. Following the diagnosis of *M. bovis*, the five African buffalo in the adjoining enclosure of the black rhinoc-eros were tested using the comparative intradermal tuberculin and gamma inter-feron tests, and they showed negative results. Cattle are regarded as a potential source, since bTB had been diagnosed in cattle herds in this region of the Limpopo Province previously. Several cattle herds in the vicinity and surrounding farmland were tuberculin skin tested. The bTB infection status of a suspect dairy herd (located within about 10 km of the center) could not be confirmed, and quarantine measures were lifted. Following the diag-nosis in the rhinoceros, bTB testing of cattle herds in the vicinity of the center was intensified but still failed to identify a potential source of the infection (E.

Klemp, State Veterinarian, Mokopane, Limpopo Province, pers. comm., 2008). There was no evidence of contact between these animals and the rhinoceros. The potential role of humans in the transmission of *M. bovis* between cattle and the rhinoceros cannot be excluded with certainty. The rhinoceros did have close contact with caretakers, sputum cultures from whom tested negative for mycobacteria. Alternatively, wildlife ranging freely in the vicinity of the NZG center as well as in the reserve of origin, where the rhinoceros spent the majority of his life, may have carried the infection, and it is of critical importance that future epidemiologic investigations include postmortem examinations of wildlife shot or found dead in these areas.

The animal collections of the NZG are located at four centers 1) the National Zoological Gardens (25°44'20.3"S, 28°11'27.6"E), Pretoria, Gauteng, 2) the Lichtenburg Biodiversity Conservation Centre (26°7'57.7"S, 26°10'8.4"E), Lichtenburg, North West Province, 250 km to the southwest of Pretoria, 3) the Mokopane Biodiversity Conservation Centre (24°10'14.1"S, 29°1'10.9"E), Mokopane, Limpopo Province, 210 km north of Pretoria, and 4) the Emerald Animal World (26°43'33.9"S, 27°52'36.7"E), Vanderbijlpark, Gauteng, 150 km south of Pretoria. All the confirmed cases of tuberculosis infection in the collection of the NZG, apart from this one, have been at the Pretoria center, where all the cases thus far have been *M. tuberculosis* infections in mammals (Michel et al., 2003) and *M. avium* infections in birds (Espie, unpubl.), and one recent case of dassie bacillus in a tortoise (Gey van Pittius et al., pers. com.). As far as we can ascertain, this is the first confirmed case of *M. bovis* infection in a rhinoceros in South Africa and also the first case of bTB infection in the four centers of the NZG. We also think that this was an incidental finding in this particular rhinoceros because the lesions were relatively small and localized. In our

opinion, his poor condition was attributed to other causes, such as old age, dental attrition, and environmental stress due to poor browsing availability, especially during the winter months.

Our finding further shows that rhinoceroses have the potential of becoming infected with bTB. This is highly significant to the management of the populations of white and black rhinoceroses in other reserves and parks in South Africa, especially the Kruger National Park (KNP) and HiP complex, where a high risk of spill-over infections has been demonstrated (Michel et al., 2006). The pathology observed in our case study may be indicative of a largely localized and self-limiting *M. bovis* infection in rhinoceros and would classify these animals as true spill-over species with no or very limited potential to transmit and maintain the infection.

Currently, there are no reliable and validated laboratory tests for pachyderms. However, preliminary studies toward the development of an IFN-gamma assay for rhinoceroses (Morar et al., 2007) and new rapid antibody assays have been reported to be useful in the diagnosis of tuberculosis in various species, including elephant (Lyashchenko et al., 2006; Wernery et al., 2007). Further research is needed to develop sensitive and specific tools for the detection of *M. bovis* infections in pachyderms, and also other mammalian species, to safeguard conservation and translocation of these species to uninfected areas.

This study shows that *M. bovis* has the potential to cross over into the Rhinocerotidae (family)/Perissodactyla (odd-toed ungulates). If such cross-over can occur in free-ranging animals, then this pathogen has the potential to affect the conservation status of these rare and endangered animals, not simply as an agent of morbidity and mortality, but also by limiting sales and translocation. This effect would be felt by conservation authorities and agencies as well as institu-

tions such as private reserves and zoos. It is therefore important for diagnostic methodologies for mycobacterial infection in these animals to be developed and made available.

The authors thank Ms. M. de Kock for technical assistance, Mark Howitt, head of the Mokopane Biodiversity Conservation Centre, and Bongani Dlamini, Veterinary Pathology Laboratory Assistant, NZG, for their assistance with the necropsy examination; and the Histology Laboratory of the National Health Laboratory Service, Pretoria.

LITERATURE CITED

- BENGIS, R. G., N. P. KRIEK, D. F. KEET, J. P. RAATH, V. DE VOS, AND H. F. HUCHZERMAYER. 1996. An outbreak of bovine tuberculosis in a free-living African buffalo (*Syncerus caffer*—Sparrman) population in the Kruger National Park: A preliminary report. *Onderstepoort Journal of Veterinary Research* 63: 15–18.
- COUSINS, D. V., H. F. K. A. HUCHZERMAYER, J. F. T. GRIFFIN, G. K. BRÜCKNER, I. B. J. VAN RENSBURG, AND N. P. J. KRIEK. 2004. Tuberculosis. In *Infectious diseases of livestock*, Volume III, J. A. W. Coetzer and R. C. Tustin (eds.). Oxford University Press, Oxford, UK, pp. 1973–1993.
- DE VOS, V., R. G. BENGIS, N. P. KRIEK, A. MICHEL, D. F. KEET, J. P. RAATH, AND H. F. HUCHZERMAYER. 2001. The epidemiology of tuberculosis in free-ranging African buffalo (*Syncerus caffer*) in the Kruger National Park, South Africa. *Onderstepoort Journal of Veterinary Research* 68: 119–130.
- GODFREY, R. W., B. L. DRESSER, AND B. J. CAMPBELL. 1990. Tuberculosis testing of captive rhinoceros. In *Proceedings of the American Association of Zoo Veterinarians*, San Padre Island, Texas, 21–26 October, p. 312.
- HOFMEYR, C. B. F. 1956. Two hundred and eighty autopsies at the National Zoological Gardens, Pretoria. *Journal of the South African Veterinary Association* 27: 263–282.
- KAMERBEEK, J., L. SCHOOLS, A. KOLK, M. VAN AGTERVELD, D. VAN SOOLINGEN, S. KUIJPER, A. BUNSCHOTEN, H. MOLHUIZEN, R. SHAW, M. GOYAL, AND J. VAN EMBDEN. 1997. Simultaneous detection and strain differentiation of *Mycobacterium tuberculosis* for diagnosis and epidemiology. *Journal of Clinical Microbiology* 35: 907–914.
- KEET, D. F., N. P. KRIEK, M. L. PENRITH, A. MICHEL, AND H. HUCHZERMAYER. 1996. Tuberculosis in buffaloes (*Syncerus caffer*) in the Kruger National Park: Spread of the disease to other species. *Onderstepoort Journal of Veterinary Research* 63: 239–244.
- , R. G. BENGIS, AND A. L. MICHEL. 2001. Tuberculosis in kudus (*Tragelaphus strepsiceros*) in the Kruger National Park. *Onderstepoort Journal of Veterinary Research* 68: 225–230.
- LYASHCHENKO, K. P., R. GREENWALD, J. ESFANDIARI, J. H. OLSEN, R. BALL, G. DUMONCEAUX, F. DUNKER, C. BUCKLEY, M. RICHARD, S. MURRAY, J. B. PAYEUR, P. ANDERSEN, J. M. POLLOCK, S. MIKOTA, M. MILLER, D. SOFRANKO, AND W. R. WATERS. 2006. Tuberculosis in elephants: Antibody responses to defined antigens of *Mycobacterium tuberculosis*, potential for early diagnosis, and monitoring of treatment. *Clinical Vaccine Immunology* 13: 722–732.
- MANN, P. C., M. BUSH, D. L. JANSSEN, E. S. FRANK, AND R. J. MONTALI. 1981. Clinicopathologic correlations of tuberculosis in large zoo mammals. *Journal of the American Veterinary Medical Association* 179: 1123–1129.
- MICHEL, A. L., L. VENTER, I. W. ESPIE, AND M. L. COETZEE. 2003. *Mycobacterium tuberculosis* infections in eight species at the National Zoological Gardens of South Africa, 1991–2001. *Journal of Wildlife Diseases* 34: 364–370.
- , R. G. BENGIS, D. F. KEET, M. HOFMEYR, L. M. KLERK, P. C. CROSS, A. E. JOLLES, D. COOPER, I. J. WHYTE, P. BUSS, AND J. GODFROID. 2006. Wildlife tuberculosis in South African conservation areas: Implications and challenges. *Veterinary Microbiology* 112: 91–100.
- , T. M. HLOKWE, M. L. COETZEE, L. MARE, L. CONNOWAY, V. P. RUTTEN, AND K. KREMER. 2008. High *Mycobacterium bovis* genetic diversity in a low prevalence setting. *Veterinary Microbiology* 126: 151–159.
- , M. L. COETZEE, D. F. KEET, L. MARÉ, R. M. WARREN, D. COOPER, R. G. BENGIS, K. KREMER, AND P. D. VAN HELDEN. 2009. Molecular epidemiology of *Mycobacterium bovis* isolates from free-ranging wildlife in South African game reserves. *Veterinary Microbiology* 133: 335–343.
- MORAR, D., E. TIJHAAR, A. NEGREA, J. HENDRIKS, D. VAN HAARLEM, J. GODFROID, A. L. MICHEL, AND V. P. RUTTEN. 2007. Cloning, sequencing and expression of white rhinoceros (*Ceratotherium simum*) interferon-gamma (IFN-gamma) and the production of rhinoceros IFN-gamma specific antibodies. *Veterinary Immunology and Immunopathology* 115: 146–154.
- RODWELL, T. C., N. P. KRIEK, R. G. BENGIS, I. J. WHYTE, P. C. VILJOEN, V. DE VOS, AND W. M. BOYCE. 2001. Prevalence of bovine tuberculosis in African buffalo at Kruger National Park. *Journal of Wildlife Diseases* 37: 258–264.
- STETTER, M. D., S. K. MIKOTA, A. F. GUTTER, E. R. MONTERROSO, J. R. DALOVISIO, C. DEGRAW, AND

- T. FARLEY. 1995. Epizootic of *Mycobacterium bovis* in a zoologic park. *Journal of the American Veterinary Medical Association* 207: 1618–1621.
- WARREN, R. M., N. C. GEY VAN PITTIUS, M. BARNARD, A. HESSELING, E. ENGELKE, K. M. DE, M. C. GUTIERREZ, G. K. CHEGE, T. C. VICTOR, E. G. HOAL, AND P. D. VAN HELDEN. 2006. Differentiation of *Mycobacterium tuberculosis* complex by PCR amplification of genomic regions of difference. *International Journal of Tuberculosis and Lung Disease* 10: 818–822.
- WERNERY, U., J. KINNE, K. L. JAHANS, H. M. VORDERMEIER, J. ESFANDIARI, R. GREENWALD, B. JOHNSON, A. UL-HAQ, AND K. P. LYASHCHENKO. 2007. Tuberculosis outbreak in a dromedary racing herd and rapid serological detection of infected camels. *Veterinary Microbiology* 122: 108–115.

Received for publication 3 December 2008.