

DERMATOPHILUS INFECTION IN COLUMBIAN GROUND SQUIRRELS (*Citellus columbianus columbianus*)

Authors: WOBESER, G., and GORDON, M. A.

Source: Bulletin of the Wildlife Disease Association, 5(1) : 31-32

Published By: Wildlife Disease Association

URL: <https://doi.org/10.7589/0090-3558-5.1.31>

BioOne Complete (complete.BioOne.org) is a full-text database of 200 subscribed and open-access titles in the biological, ecological, and environmental sciences published by nonprofit societies, associations, museums, institutions, and presses.

Your use of this PDF, the BioOne Complete website, and all posted and associated content indicates your acceptance of BioOne's Terms of Use, available at www.bioone.org/terms-of-use.

Usage of BioOne Complete content is strictly limited to personal, educational, and non - commercial use. Commercial inquiries or rights and permissions requests should be directed to the individual publisher as copyright holder.

BioOne sees sustainable scholarly publishing as an inherently collaborative enterprise connecting authors, nonprofit publishers, academic institutions, research libraries, and research funders in the common goal of maximizing access to critical research.

DERMATOPHILUS INFECTION IN COLUMBIAN GROUND SQUIRRELS
(*Citellus columbianus columbianus*)

Dermatophilus infection causes dermatitis in various herbivorous animals including cattle, sheep, goats, horses, elands (*Taurotragus* sp.) (Ainsworth and Austwick, 1959, Fungal diseases of animals, Commonwealth Agricultural Bureaux, Farnham Royal, England), and white-tailed deer (*Odocoileus virginianus*) (Dean *et al*, 1961, N.Y. State J. Med. 61:1283). Infection has been produced experimentally in laboratory animals including the rabbit, guinea pig, and mouse. Natural infection in wild rodents does not appear to have been described previously.

Case Report

In July, 1966, a group of 24 Columbian ground squirrels was captured in the Kelowna region of British Columbia and forwarded to the Department of Zoology, University of Guelph. The animals were maintained in separate cages at a temperature of 40 F as part of a hibernation study.

In July, 1967, one of the squirrels was presented at the Ontario Veterinary College because of skin lesions which had been noted approximately two weeks earlier. The animal was euthanized and examined. Thick crusts of material which appeared to be keratinized skin were found on the nose and cheeks (Fig. 1). The scabs were tightly adherent and the underlying tissue was moist and hyperemic. There was erythema and alopecia of the hind legs and perineal region; the tail was a naked stump approximately 2 cm long (Fig. 2). Smears made from the serous exudate beneath the scabs were stained with Giemsa. Numerous long filaments which appeared to be dividing transversely and longitudinally to form coccoid bodies were observed (Fig. 3). This type of growth is considered to be diagnostic for *Dermatophilus* (Roberts, 1967, Vet. Bull. 37 (8): 513). In stained tissue sections the organisms appeared to be restricted to the epidermis, in which there were areas of hyperkeratosis and micro-



FIGURE 1. Thick crusted material on nose of squirrel.

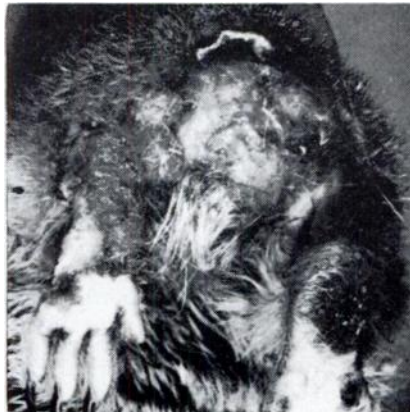

FIGURE 2. Tail region of squirrel showing serous exudate present after removal of scabs.

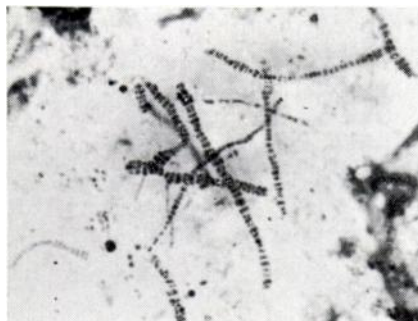


FIGURE 3. *Dermatophilus* organisms in skin smear, Giemsa stain.

abscessation, similar to that described by Searcy and Hulland (1968, Can. Vet. J. 9 (1): 16) in bovine *Dermatophilus* infection. *Dermatophilus* was not isolated from this case.

Subsequently the remainder of the ground squirrels were examined for skin lesions. One animal had gross lesions similar to those of the first case. Typical *Dermatophilus* organisms were observed on Giemsa-stained smears. Portions of the scabs from the nose and tail were removed, soaked in sterile distilled water, ground in a tissue grinder and diluted by serial tenfold dilution to 1×10^{-8} . A 0.1 ml amount of each dilution was cultured on agar plates containing 10% bovine blood. After 24 hours' incubation at 37 C small elevated matt colonies producing beta hemolysis were formed. A culture of the organism was forwarded to the Division of Laboratories and Research, New York State Department of Health, Albany, New York, where it was identified as a strongly proteolytic strain of *Dermatophilus congolensis* (Gordon, 1964, J. Bact. 88 (2): 509). Inoculation of scarified skin of rabbits resulted in infection and host tissue reaction similar to that induced by strains of *D. congolensis* isolated from naturally-infected cattle and deer.

Discussion

It is interesting to speculate on the source of infection in this case. Lesions were not noted until the squirrels had been in captivity for one year during which domestic rabbits and ground hogs (*Marmota monax*) were sometimes kept in the same room. No lesions were seen in the other species. Roberts (1967, Vet. Bull. 37 (8): 513) states that in domestic animals chronically infected individuals are the likely reservoir of the microorganism, and the main source of infection in outbreaks. If this was the case in this instance, infection in wild ground squirrels may provide a new approach to the epizootiology of *Dermatophilus* infection.

Acknowledgements

The authors wish to thank Dr. K. Ronald, Department of Zoology, University of Guelph, and his staff for their cooperation.

G. WOBESER

Section of Zoonoses and Diseases
of Wildlife
Ontario Veterinary College
Guelph, Ontario

M. A. GORDON

Division of Laboratories and Research
State of New York Department
of Health
Albany, New York

October 1, 1968