

## **NOTES ON A NODULAR DISEASE OF THE INTESTINE OF THE OPEN-BILLED STORK — (*Anastomus oscitans*) CAUSED BY *Chaunocephalus ferox***

Authors: PATNAIK, M. M., RAO, A. T., ACHARJYO, L. N., and  
MOHANTY, D. N.

Source: Journal of Wildlife Diseases, 6(1) : 64-66

Published By: Wildlife Disease Association

URL: <https://doi.org/10.7589/0090-3558-6.1.64>

---

BioOne Complete ([complete.BioOne.org](https://complete.BioOne.org)) is a full-text database of 200 subscribed and open-access titles in the biological, ecological, and environmental sciences published by nonprofit societies, associations, museums, institutions, and presses.

Your use of this PDF, the BioOne Complete website, and all posted and associated content indicates your acceptance of BioOne's Terms of Use, available at [www.bioone.org/terms-of-use](https://www.bioone.org/terms-of-use).

Usage of BioOne Complete content is strictly limited to personal, educational, and non - commercial use. Commercial inquiries or rights and permissions requests should be directed to the individual publisher as copyright holder.

---

BioOne sees sustainable scholarly publishing as an inherently collaborative enterprise connecting authors, nonprofit publishers, academic institutions, research libraries, and research funders in the common goal of maximizing access to critical research.

**NOTES ON A NODULAR DISEASE OF THE INTESTINE OF  
THE OPEN-BILLED STORK — (*Anastomus oscitans*)  
CAUSED BY *Chaunocephalus ferox***

Although the occurrence of *Chaunocephalus ferox* (Rudolphi, 1795) Dietz, 1909, in crypts in the intestines of the Indian open-billed stork (*Anastomus oscitans*) was known (Rai, 1963, Ind. J. Helminth., 15: 6-13), detailed information on the pathology of the parasite in this host was not available. During investigation of an epizootic disease among open-billed storks, maintained on a snail diet (*Vivipara* sp.) at Nandankanan zoo, nodular lesions caused by *C. ferox* were

encountered in the post-duodenal part of the small intestine of seven of ten storks examined post-mortem by one of the authors (MMP). In the foregut, concurrent infections with *Synhimantus laticeps* Rudolphi, 1819 also were observed in four of them. All birds infected with *C. ferox* had signs of diarrhoea, listlessness, loss of appetite and convulsion before death. This presentation gives the relevant descriptions of the trematode and histopathology of the parasitized nodule.

**Materials and Methods**

Nodular lesions of the intestines were collected during post-mortem examinations of the birds. The trematode parasites recovered from the nodules were flattened and fixed in Bouin's fluid, stained with Borax-carmin and mount-

ed. The intestinal nodules were fixed in 10% formol-saline. The sections prepared from the paraffin embedded nodular lesions were stained with hematoxylin and eosin.

**Observations**

The nodules were globular, circumscribed and prominent on both the serosal (Fig. 1) and mucosal surfaces. A perforation was noticed on the summit of the protuberance on the mucosal surface through which trematode ova and cellular exudate oozed out. On squeezing the nodules, one or more viable pink trematodes were recovered. The smaller nodules invariably contained immature parasites and the larger ones contained ovigerous, adult forms.

All the parasitic trematodes were *C. ferox*. The adult mounted specimens measured 3.5-6.5 mm in length, 1.25-3.25 mm in width at the preacetabular part and 0.6-0.75 mm at the postacetabular part. There was little difference in size of the postacetabular part between the juveniles and adults in comparison with their preacetabular parts. Of the 46 specimens examined, 29 had 27 collar spines, arranged in two rows with 4 corner spines without any interruption. Only seven had 26 spines. The oral sucker of the adult was 0.14 mm and the

prepharynx was 0.25 mm in diameter. The esophagus was simple, 1.8-2.00 mm long and bifurcated into two lateral caeca in front of the ventral sucker, which ran laterally to the posterior end and opened into the excretory bladder. The ventral sucker was 0.49 mm in diameter. The sucker ratio varied from 1:2.25 - 1:2.5. The pretesticular oval ovary, situated near the right caeca, measured 0.3 x 0.22 mm. The two globular testes were almost equal in size and measured 0.25 x 0.22 mm. (Fig. 2). The eggs measured 0.035 x 0.075 mm.

The sections revealed the parasites in a coiled position inside the nodule. The spinous head collar and fasciculated preacetabular part of the parasite lay in close apposition with the inner wall of the nodule and the aspinous postacetabular slim part was relatively free in a cavity, filled with fibrino-necrotic exudate. In early nodules, at the site of trematode penetration through the mucosa and submucosa, there was traumatic destruction of tissues with haemorrhage

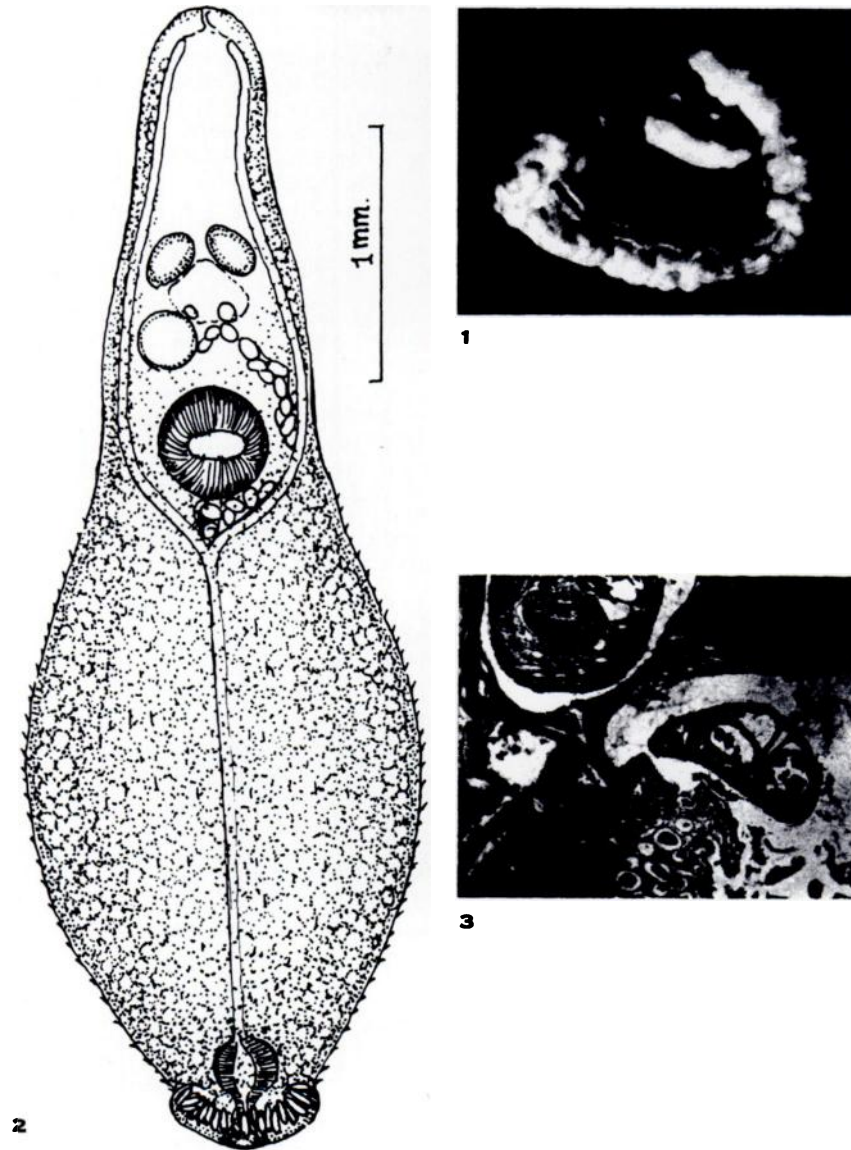


FIGURE 1. Nodular lesions on the intestine of heavily infected open-billed stork caused by the echinostome, *C. ferox*.

FIGURE 2. Camera-lucida drawing of a smaller ovigerous *C. ferox* specimen recovered from an intestinal nodule of medium size.

FIGURE 3. Section of a small nodule containing the early stages of one parasite (*C. ferox*) and migration of another into the nodule. H.E. x 60.

and denudation of the epithelium and subepithelium. Further, the parasite left a trail of such destruction (Fig. 3) in submucosal tissues to where it settled in deeper locations, near or beyond the muscularis mucosa. There was marked thickening due to edema and excessive infiltration of granulocytes and lymphocytes. Fibroblasts and connective tissue fibres were seen at the periphery of the

circumscribed lesions. The muscle fibres adjacent to early small nodules had increased granularity. The sarcoplasm was eosinophilic and had degenerative changes in the nuclei. In more advanced larger nodules the muscle fibres were necrotic. The intergrading nodules had a variable degree of fibrosis around the parasites. The serosa in all cases was thickened.

### Discussion

The *C. ferox* specimens dealt with in this study were much smaller than those described by Dawes (1956, *The Trematoda*, Cambridge Univ. Press, London, 360 pp.) and closely corresponded with the given descriptions of *C. odhneri* Vrat, and *C. kirati* Vrat (1947, Proc. Nat. Acad. Sci. 17B:95-116) recorded from this host. Rai (1963, Ind. J. Helminth., 15:6-13) had considered *C. odhneri* as a possible synonym of *C. ferox*, now studied, except for the sacculated esophagus and unequal testes. It is evident from the figures given by Vrat, the trematodes were recovered from such nodular lesions

but were described as being from crypts of the intestine. These findings suggest that *C. kirati* also is a possible synonym.

From the uniform distribution of the parasitic nodules, it is believed that this parasite becomes established in nodules at the predilectory site in the intestinal wall and continues histiozoic life even after attaining maturity in this host. The growth patterns of the preacetabular spinous parts of parasites of different sizes, which were proportional to the size of the nodules, also suggest that the larger adult parasites were relatively more pathogenic.

### Summary

An account is given of the pathology of nodular lesions in the small intestine of open-billed storks, *Anastomus oscitans*, caused by *Chaunocephalus ferox*. It is suggested that the parasitic trematodes lead an entirely histiozoic life in this host.

### Acknowledgements

Grateful acknowledgements are due to the Director of Animal Husbandry and Veterinary Services, Orissa, and Wildlife Conservation Officer, Orissa for use of the facilities.

M. M. PATNAIK,  
A. T. RAO,  
L. N. ACHARJYO  
and D. N. MOHANTY.

State Veterinary Laboratory,  
Bhubaneswar, India.

April 10, 1969.