



POLYDACTYLISM IN A WHITE-TAILED DEER FROM EASTERN ONTARIO

Authors: MILLER, F. L., and CAWLEY, A. J.

Source: Journal of Wildlife Diseases, 6(2) : 101-103

Published By: Wildlife Disease Association

URL: <https://doi.org/10.7589/0090-3558-6.2.101>

BioOne Complete (complete.BioOne.org) is a full-text database of 200 subscribed and open-access titles in the biological, ecological, and environmental sciences published by nonprofit societies, associations, museums, institutions, and presses.

Your use of this PDF, the BioOne Complete website, and all posted and associated content indicates your acceptance of BioOne's Terms of Use, available at www.bioone.org/terms-of-use.

Usage of BioOne Complete content is strictly limited to personal, educational, and non - commercial use. Commercial inquiries or rights and permissions requests should be directed to the individual publisher as copyright holder.

BioOne sees sustainable scholarly publishing as an inherently collaborative enterprise connecting authors, nonprofit publishers, academic institutions, research libraries, and research funders in the common goal of maximizing access to critical research.

POLYDACTYLISM IN A WHITE-TAILED DEER FROM EASTERN ONTARIO

Polydactylism has not been reported in any species of deer in North America. Polydactylous front feet were found in a single German roe buck (*Capreolus capreolus*) by Nobs (1954, Deutsche Tierärztliche Wochenschrift, Hanover, 61: 407), and in about 90 red deer

(*Cervus elaphus*) in New Zealand by Daniel (1965, Säugetierk. Mitt., 15: 149-155) who suggested that the character probably originated in New Zealand from one stag and two hinds from the Royal deer herd at Windsor Park, England, liberated there in 1863.

Methods

The polydactylous right front foot was collected from a white-tailed deer fawn shot near Calabogie, Ontario, November 4, 1967, in Renfrew County at 76°46'N, 45°16'W. The senior author was in the hunting party and detected the anomaly while handling the deer. Linear measure-

ments of the supernumerary hoof and the normal 2nd and 5th digits were recorded after visual examination of the foot. The foot was then photographed and radiographed for detailed interpretation of the polydactylous condition.

Results

The polydactylous right front foot had an extra digit of three phalanges and an extra metacarpal on the inside of the foot (Fig. 1) in the position of the ancestral first digit. The extra metacarpal bone was not fused along its length to the cannon bone. The hoof of the extra digit curved upward in a crescent, tapered sharply, and appeared by its slightly exaggerated size and shape to be non-functional (Figs. 2 and 3).

The supernumerary hoof had a maximum lower surface length of 81% more than its upper surface length (47 mm. to 26 mm.) and exceeded the lower surface

lengths of the 2nd and 5th digits (normal "dew claws", 28 mm. and 29 mm.) by 62 and 68%. The upper surface length of the supernumerary hoof, however, was only 96 and 93% of the upper surface lengths of the 2nd and 5th digits (27 mm. and 28 mm.).

Further external and internal examinations revealed no other abnormalities. The fawn was estimated to be about 5 months old by the erupted but not fully rotated 1st incisors. It appeared in excellent condition with deep fat deposits in all fat depository areas.

Discussion

Nobs attributed the polydactylous front feet to embryonic duplication of the tissues of the limb buds. Daniel stated that polydactylism "is probably caused by a dominant gene with incomplete penetrance and variable expressivity". He believed that the trait was aberrant rather than atavistic because there was no known ancestor of the deer with three functional digits on the forefeet and two on the hind. However, polydactylous

front feet have now been found on three species of deer from different parts of the world, whereas a polydactylous hind foot has never been found on any deer, not even in the 90 cases from New Zealand, and there thus appears to be some predisposition for the location of the anomaly. Possibly, then, ancestral deer lost the first digit of the forefoot later than that of the hind foot.

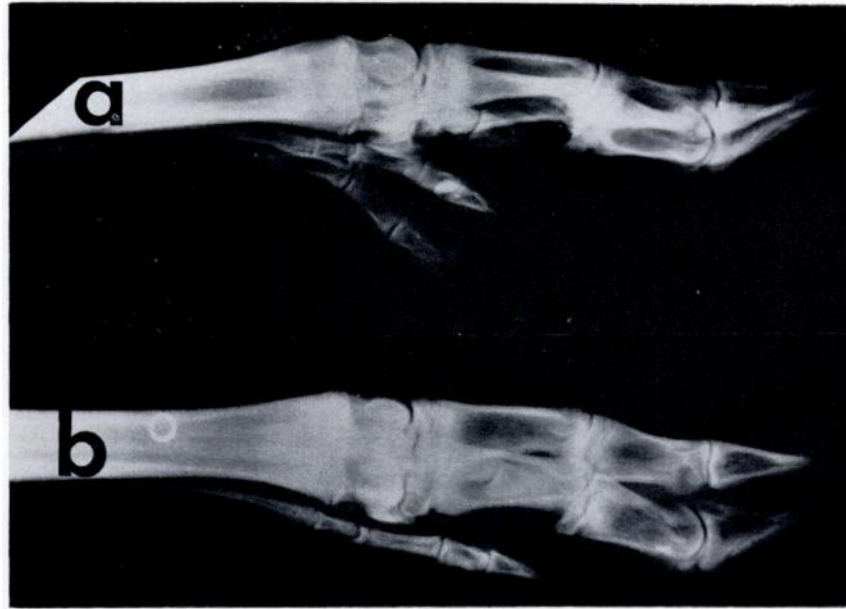


FIGURE 1. Radiograph of the right front foot from two female white-tailed deer fawns: (a) polydactylous foot with five complete digits, showing the phalanges of the supernumerary digit and the extra unfused metacarpal bone, Ontario, 1967; (b) normal foot with four digits, Ontario, 1968.

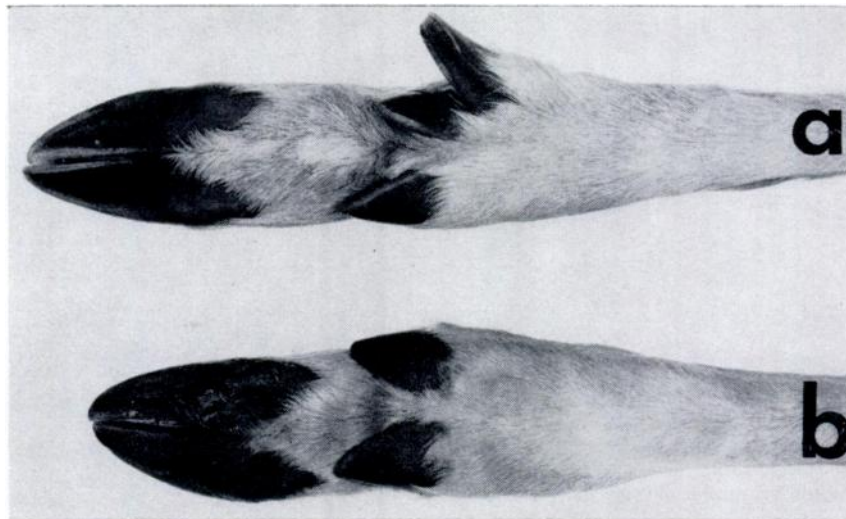


FIGURE 2. Posterior views of the right front foot from two female white-tailed deer fawns: (a) polydactylous foot showing hooves of the five complete digits (note curvature and projection of supernumerary hoof) Ontario, 1967; (b) normal foot with four digits, Ontario, 1968.

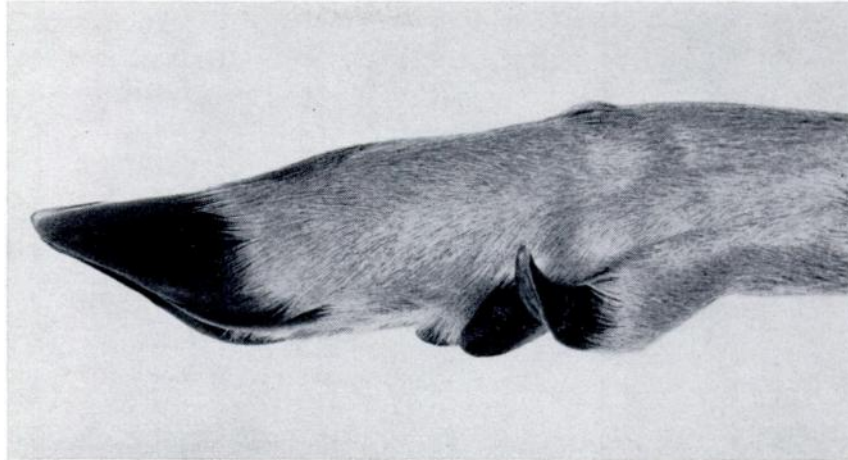


FIGURE 3. Lateral view of inside right front foot from polydactylous female white-tailed deer fawn from eastern Ontario, 1967, showing exaggerated curvature and projection of supernumerary digit.

Summary

A polydactylous right front foot was collected from a white-tailed deer (*Odocoileus virginianus*) fawn in eastern Ontario, Canada. We determined by gross visual and radiographic examinations that the polydactylous foot had a

complete extra digit in the position of the ancestral 1st digit. This is the first documented account of a perfect polydactylous condition in a North American cervid.

Acknowledgements

We are grateful to Mr. Gerald Lewis for kindly allowing us to take, for further examination, the polydactylous foot from the deer which he shot. We wish to thank Dr. E. Broughton, Canadian Wildlife Service, for his assistance in handling the material, Dr. A. H. Macpherson for a critical review of the manuscript, Mr. G. D. Tessier, Canadian Wildlife Service, for his technical assistance, and Mr. G. Ben, Department of Biology, University of Ottawa, for photographing Figures 1, 2 and 3.

F. L. MILLER
Canadian Wildlife Service
Eastern Region
Highway 31
Ottawa 1, Ontario, Canada

and

A. J. CAWLEY
Professor and Head
Small Animals Section
Ontario Veterinary College
University of Guelph
Guelph, Ontario, Canada