

**THE HARP SEAL, *Pagophilus groenlandicus*
(ERXLEBEN, 1777) XII. STAPHYLOCOCCAL
GRANULOMAS (BOTRYOMYCOSIS) IN HARP SEALS**

Authors: WILSON, T. M., and LONG, J. R.

Source: Journal of Wildlife Diseases, 6(3) : 155-159

Published By: Wildlife Disease Association

URL: <https://doi.org/10.7589/0090-3558-6.3.155>

BioOne Complete (complete.BioOne.org) is a full-text database of 200 subscribed and open-access titles in the biological, ecological, and environmental sciences published by nonprofit societies, associations, museums, institutions, and presses.

Your use of this PDF, the BioOne Complete website, and all posted and associated content indicates your acceptance of BioOne's Terms of Use, available at www.bioone.org/terms-of-use.

Usage of BioOne Complete content is strictly limited to personal, educational, and non - commercial use. Commercial inquiries or rights and permissions requests should be directed to the individual publisher as copyright holder.

BioOne sees sustainable scholarly publishing as an inherently collaborative enterprise connecting authors, nonprofit publishers, academic institutions, research libraries, and research funders in the common goal of maximizing access to critical research.

THE HARP SEAL, *Pagophilus groenlandicus* (ERXLEBEN, 1777)
XII. STAPHYLOCOCCAL GRANULOMAS (BOTRYOMYCOSIS)
IN HARP SEALS

Case History: seal 1

In March, 1969, a 2 year old female harp seal, captive for 23 months, was received for necropsy. Pertinent clinical history included the occurrence of multiple ulcers in the abdominal skin during October, 1968 and dysphagia commencing in January, 1969 and persisting until death. Hematology revealed leukocytosis and neutrophilia.

Pathological Findings

Externally the body, especially the abdomen, was covered with pale, focal areas of alopecia, 1-3 mm in size. A scirrhous, 5 cm yellow-grey mass was firmly attached in the region of the left thyroid gland, but did not penetrate the esophagus or trachea. A firm, white, 1 cm nodule was present in the dorsal diaphragmatic region of the right lung.

The peritoneal cavity contained approximately 200 ml of a sero-sanguinous fluid and a red, firm granular mass in the omental attachments of the stomach and spleen. This mass was elongated, approximately 50 cm in length and 15 cm in thickness and the cut surface was mottled red and white.

The intestinal mesentery was dark red and thickened with firm, white nodules less than 1 cm in diameter at the mesenteric-intestinal attachment.

Histological Findings

Similar granulomatous lesions were found in the thyroid mass, lung, abdominal mass and in all layers of the intestinal wall. These granulomatous foci were composed of central sulphur granules immediately surrounded by lymphocytes and further encircled by plasma cells, epithelioid cells and dense connective tissue capsules. There was considerable hemorrhage and vascularization in the abdominal mass, with immature connective tissue surrounding the foci.

The histological appearance of the sulphur granules was variable in all tissues examined but generally the granules were eosinophilic and hyaline, sometimes with rows of radiating clubs at the granule peripheries. Granules were round, elongate or irregular and varied from 50 to 250 microns (Fig. 1). With hematoxylin and eosin (H and E) stain, foci of basophilic cocci were seen in and around the granules.

No positive staining reactions were obtained with the periodic acid-Schiff and acid fast techniques on representative tissue sections, while Brown and Brenn (McManus and Mowry, 1960, *Staining Methods, Histologic and Histochemical*, Harper-Row, New York, N.Y., p. 362) staining of similar sections revealed masses of gram-positive cocci in and around the sulphur granules (Fig. 2).

Case History: seal 2

In June, 1969, a 27 month old female harp seal, in captivity for two years, was received for necropsy. Pertinent clinical history included the appearance of multiple small skin ulcers 5 months prior to death, chronic corneal ulceration and a chronic leukocytosis and neutrophilia.

Pathological Findings

Externally the carcass was covered with multiple, pale, 2-5 mm ulcers, most prevalent on the abdominal skin. Internal lesions were confined to the lymph nodes. All nodes examined, but especially the prescapular, axillary, submandibular and inguinal nodes, were approximately twice normal size, with purulent centers.

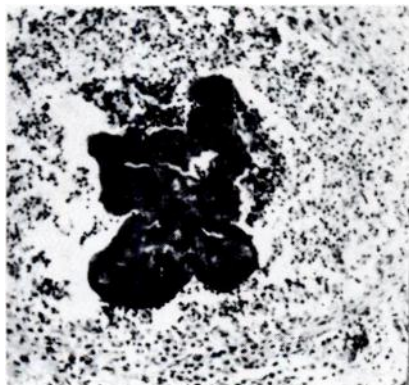


FIGURE 1. Sulphur granule in the center of a granulomatous lesion, lung, Case 1. H & E stain; x 100.

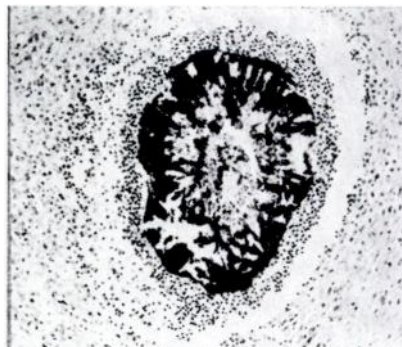


FIGURE 2. Masses of gram positive cocci in the center of a granulomatous lesion, intestine, Case 1. Brown and Brenn; x 100.

Histological Findings

All organs were examined histologically but lesions were found only in the skin and lymph nodes. There was ulceration of the epidermis, with focal infiltration of neutrophils and lymphoid cells into the dermis, particularly adjacent to the hair follicles and external root sheaths. Sulphur granules were present in areas of dermal inflammation.

Histological lesions were similar in all lymph nodes examined, including the prescapular, axillary, submandibular and inguinal nodes. There was disorganiza-

tion of the lymph node structure by focal granulomatous lesions. Several nodes had necrotic centers, infiltrated by masses of neutrophils and lymphoid cells. The histological structure of the focal granulomas present in the lymph nodes was similar to the granulomas described in Case 1, except for the occurrence of more neutrophils immediately surrounding the sulphur granules. The sulphur granules in this case were less numerous and distinct than in Case 1. The differential stains used in this case and the results obtained were similar to those in Case 1.

Case History: seal 3

A subcutaneous cervical mass was received from a male, 20 month old harp seal. The animal had been euthanized after a long undiagnosed illness. Experimentation on this animal had involved the placement of electrodes in and about the ears.

Pathological Findings

The mass was firm, pale and approximately 10 cm in diameter. Incisions exposed yellow, 1-2 mm foci surrounded by dense connective tissue. Histological examination revealed lesions similar to

those described in Case 1, except for the presence of more neutrophils immediately surrounding the granules. Periodic acid-Schiff and acid fast reactions were negative, while Brown and Brenn stain revealed gram-positive cocci in the centers of the granulomatous foci.

Housing

Seals 1 and 2 had been housed together in an outdoor tank for approximately 13 months prior to their deaths. Seal 3 also had been kept periodically in this outdoor tank.

Bacteriological Findings

The only bacteria seen in stained smears from the abdominal mass of seal 1 were gram-positive cocci. Culture on calf blood agar (CBA) yielded many colonies of hemolytic staphylococci in pure culture.

Smears from two tissue specimens from seal 2, a skin ulcer and a prescapular lymph node, contained gram-positive cocci. When cultured on CBA, moderate to large numbers of hemolytic staphylococci grew from the skin ulcer, the spleen, liver, and from the iliac, mesenteric, prescapular and mandibular lymph nodes. No bacteria were cultured from lung and kidney tissues and staphylococci were not isolated from the intestinal tract. Salmonellae were not cultured from the feces.

A single specimen from the cervical mass from seal 3 likewise yielded a pure culture of hemolytic staphylococci.

Isolates from the three cases were identified as *Staphylococcus aureus* (Baird-Parker, Methods for classifying Staphylococci and Micrococci, in: Gibbs and Skinner, 1966, *Identification Methods for Microbiologists*, Academic Press, New York, N.Y., pp 59-64). Some characteristics of these cultures are given in Table 1.

Using a basic international set of 23 phages, the isolates were phage typed by the Canadian Staphylococcus Phage Typing Reference Centre (Laboratory of Hygiene, Ottawa 3, Ontario). They possessed a similar phage pattern, as listed in Table 1. Antibiotic sensitivity tests, using sensitivity test discs, indicated that all isolates were sensitive to the six antibiotics used: Ampicillin (5 mcg), Chloramphenicol (5 mcg), Cloxacillin (5 mcg), Erythromycin (2 mcg), Penicillin (2u) and Tetracycline (5 mcg).

TABLE 1. *Cultural characteristics of Staphylococcus aureus from three harp seals.*

Seal	Source	Mannitol Salt Agar	Free Coagulase	Phage Pattern	Hemolysis on Blood Agar Horse	Calf
1	abdominal mass	+	+	83A/85	D	B, D*
2	skin ulcer	+	+	83A	D	D
	spleen	+	+	47/83A/85+	D	D
3	cervical mass	+	+	6/47/53/83A	D	weak B, D

*D = delta and B = beta hemolysis

Diagnosis

Bacteriological and histopathological results indicated a generalized staphylococcal granulomatous disease in seal 1, staphylococcal granulomatous lymphadenitis with bacteremia in seal 2, and a subcutaneous staphylococcal granuloma in seal 3.

denitis with bacteremia in seal 2, and a subcutaneous staphylococcal granuloma in seal 3.

Discussion

Staphylococcal granulomas have been reported in bovine mastitis (Albiston, 1930, Aust. Vet. J. 6: 2-22; Tanner, 1952, Nord. Vet. Med. 4: 655-673; Blackburn, 1959, Brit. Vet. J. 115: 311-316) swine mastitis (Davies and Torrance, 1930, J. Comp. Path. Therp. 43: 216-233) swine genital infections (Fennestad, et al., 1955, Nord. Vet. Med. 7: 929-947) and equine castration wounds (McFadyyeen, 1919, J. Comp. Path. Therp. 32: 73-89). Botryomycotic spondylitis and myelitis have been reported in a sow (Sullivan and Short, 1966, Cornell Vet. 56: 356-364) and a case of metastatic botryomycosis has been documented in a cat (Habermann and Williams, 1956, J.A.V.M.A. 129: 30-33).

The granuloma is the result of chronic infection with *Staphylococcus* species, usually *Staphylococcus aureus*. Generally the lesion is a firm, pale nodule made up of dense connective tissue, containing focal abscesses. With H and E stain, the foci of abscessation are seen to contain amorphous eosinophilic masses called sulphur granules. In acute cases, neutrophils immediately surround the granule, while lymphoid cells and larger mononuclear cells are evident in the later stages of infection. Encircling this are large mononuclear cells, epithelioid cells and connective tissue which form a dense capsule around the granule and its cellular component.

The frequency of staphylococcal granulomas in humans is much less than in animals and as indicated by Winslow (1959, Amer. J. Path. 35: 153-167) the disease takes two forms: integumentary and visceral, the former more common. Two cases of intra-abdominal staphylococcal granulomas in humans caused by fish bone foreign bodies have been reported (Kimmelstiel and Oden, 1939, Arch. Path. 27: 313-319).

No reports were found of staphylococcal granulomas in pinnipeds; however, one case of thoracic actinomycosis was reported in a mane seal (Schmitt, 1962, Nord Vet. Med. 14, Suppl. 1: 170-173). This case was not confirmed

bacteriologically nor by differential staining procedures.

While the etiologic agent, course of the disease and pathology of staphylococcal granulomas is similar in animals and in man, the nomenclature for this condition is chaotic. There is no accepted terminology and names used include botryomycosis, actinomycosis and staphylococcusactinophytosis. In many instances these terms are vague or incorrect. Confusion in nomenclature may be the result of inadequate or inaccurate diagnosis of bacterial and mycotic granulomas.

Schiefer (1964, Path. Vet. 1: 221-247) classified bacterial and mycotic granulomas into four groups: 1) bacterial, 2) actinomycotic, 3) fungal granuloma, obligate pathogenicity, 4) fungal granuloma, facultative pathogenicity. It is within the second group, which includes the diseases actinomycosis, actinobacillosis, nocardiosis, streptothricosis, and staphylococcal granulomas, where the differential diagnosis in our cases must be considered. A confirmed diagnosis of any of the above diseases can be made only after cultural isolation of the agent; however, an accurate diagnosis usually can be made after histological examination and differential staining of the lesions.

Sulphur granules can be seen histologically in lesions of actinomycosis, actinobacillosis and staphylococcal granulomas. The granules in actinobacillosis and actinomycosis are similar in appearance and are noted for their stellate contour. The granules in staphylococcal granulomas differ from the granules of actinobacillosis and actinomycosis in having smooth curved peripheries. Gram stains of the granules reveal gram-positive filamentous forms in actinomycosis; short, plump, gram-negative filamentous forms in actinobacillosis and gram-positive cocci in staphylococcal granulomas (Schiefer, 1964, Path. Vet. 1: 221-247).

In seal 2, *Staphylococcus aureus* was isolated from several tissues, including the spleen and skin ulcer and since the

phage pattern indicates that the isolates from these two tissues were not different, it is possible that the skin lesions afforded the portal of entry into the body. The skin ulcers present in seal 1 were not examined bacteriologically nor histologically but similarly, the skin lesions may have been the source of bacterial entry. From the history of experimental surgery about the head of seal 3, it seems most likely that these procedures resulted in infection.

Coagulase positive staphylococci can be isolated from the skin, nose and other mucous membranes of man and a number of animal species. No literature was found to indicate that the nasal and fecal bacterial flora of seals has been studied. *Staphylococcus aureus* is a constituent of the normal fecal flora of man, but Smith and Crabb (1961, J. Path. Bact. 82: 53-66) were unable to isolate this organism from the feces of ten animal species. In a study of the normal aerobic fecal flora of 18 captive harp seals, Humble

(Personal Communication, Ontario Veterinary College, University of Guelph, Guelph, Ontario, Canada) cultured hemolytic staphylococci only once from one seal and twice from another. Seal 2 of this report was sampled five times prior to death and fecal staphylococci were not found. Staphylococci were not cultured from sixteen water samples from various seal tanks.

In a ten year study, Danish workers (Jessen, et al., 1969, New Eng. J. Med. 281: 627-635) observed that staphylococcal strains with phage patterns similar to those of our harp seal isolates were becoming much more common in human hospital flora. Although epidemiological studies were not carried out in our cases, a human source cannot be excluded.

Lesions from which *Staphylococcus aureus* is isolated and in which histological examination reveal granulomatous reactions, including sulphur granules, should be diagnosed as staphylococcal granulomas.

Acknowledgements

The assistance of the personnel of the Marine Mammal Laboratory, Department of Zoology, University of Guelph, Guelph, Ontario, Canada, especially Heather Pederson and Diane Vander Pol, is acknowledged. The technical assistance of Mr. E. W. Eaton is appreciated.

T. M. WILSON ¹, ³

J. R. LONG ²

¹ Department of Pathology, Section of Zoonoses and Wildlife Diseases, Ontario Veterinary College, University of Guelph, Guelph, Ontario, Canada.

² Department of Veterinary Microbiology and Immunology, Ontario Veterinary College.

³ This investigation was supported by an A.V.M.A. Foundation Award.

March 2, 1970.