

SPONTANEOUS HERPES-LIKE VIRAL INFECTION IN A CHINCHILLA (*Chinchilla laniger*)

Author: GOUDAS, P.

Source: Journal of Wildlife Diseases, 6(3) : 175-179

Published By: Wildlife Disease Association

URL: <https://doi.org/10.7589/0090-3558-6.3.175>

BioOne Complete (complete.BioOne.org) is a full-text database of 200 subscribed and open-access titles in the biological, ecological, and environmental sciences published by nonprofit societies, associations, museums, institutions, and presses.

Your use of this PDF, the BioOne Complete website, and all posted and associated content indicates your acceptance of BioOne's Terms of Use, available at www.bioone.org/terms-of-use.

Usage of BioOne Complete content is strictly limited to personal, educational, and non - commercial use. Commercial inquiries or rights and permissions requests should be directed to the individual publisher as copyright holder.

BioOne sees sustainable scholarly publishing as an inherently collaborative enterprise connecting authors, nonprofit publishers, academic institutions, research libraries, and research funders in the common goal of maximizing access to critical research.

SPONTANEOUS HERPES-LIKE VIRAL INFECTION IN A CHINCHILLA (*Chinchilla laniger*)

An adult female chinchilla was submitted for necropsy with a history of sudden death. External examination of the carcass revealed slight discoloration of the fur in the perineal area. Gross

lesions included a friable, pale, almost white, liver and numerous white foci, 2 to 5 mm in diameter, scattered through the tissues of the adrenal glands.

Histopathology and Electronmicroscopy

Representative tissues from liver, spleen, kidneys, adrenals, small intestine, uterus, heart, lung and brain were fixed in buffered neutral 10% formalin, embedded in paraffin, sectioned and stained with hematoxylin and eosin (H and E). Special stains used included the periodic acid-Schiff (PAS) reaction and the Feulgen method for DNA.

Histological examination revealed multiple foci of necrosis in the zona fasciculata and to a lesser extent the other cell layers of the cortex of the adrenal glands. The centers of the foci were an eosinophilic amorphous material, sprinkled with chromatin debris and a few fragmented polymorphonuclear leukocytes. The cy-

toplasm of the cells adjacent to the dead tissue was vacuolated. Margination of chromatin and eosinophilic intranuclear inclusion bodies were found in a high percentage of these cells. The inclusions resembled "type A" as described by Cowdry (1934, Arch. Path. 18: 527-542) and others (Pereira, 1961, Advan. Virus Res. 8: 245-285) and were PAS and Feulgen negative (Fig. 1). Necrotic areas similar to the above were found in moderate numbers throughout the red pulp of the spleen. A large number of reticulo-endothelial cells had eosinophilic intranuclear inclusions. Most of the epithelioid parenchymatous cells of the pineal body had margined chromatin

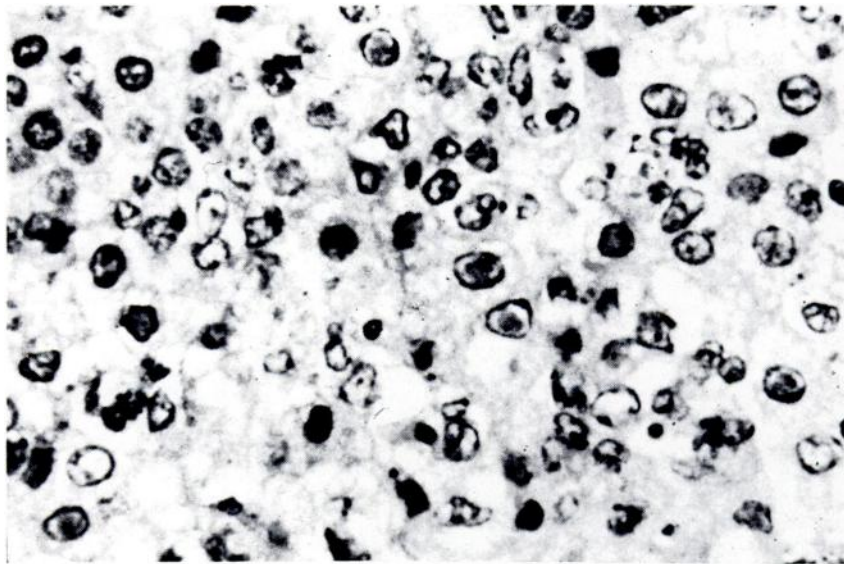


FIGURE 1. *Vacuolated degenerating cells of the zona fasciculata of the adrenal. Many of these contain eosinophilic intranuclear inclusion bodies. H and E stain.*

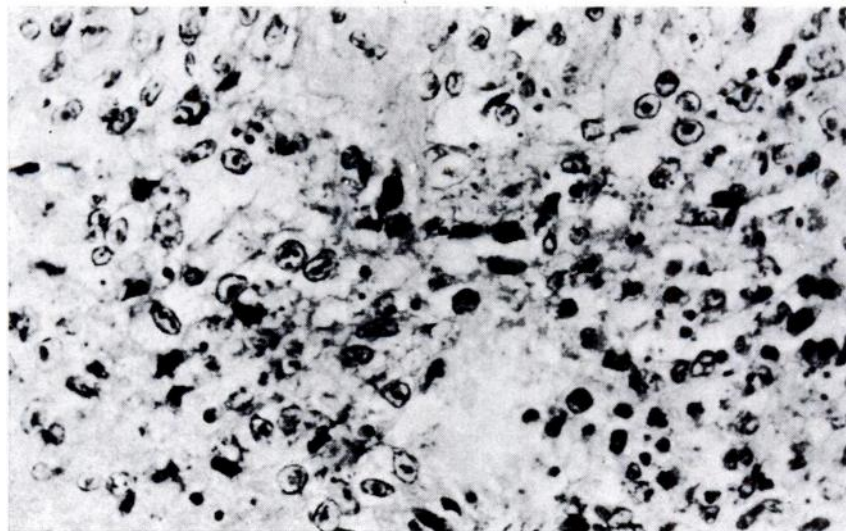


FIGURE 2. Pineal body, with many cells containing eosinophilic intranuclear inclusion bodies. H and E stain.

and contained "type A" inclusions (Fig. 2). A focus of cell destruction was observed as well. Similar inclusion bodies were found in a few astrocytes and glial cells of the medulla of the brain. Hepatic cells contained cytoplasmic vacuoles.

Following histologic examination, the formalin-fixed and paraffin-embedded adrenal tissues were used for electron microscopy employing the following methods:

The wax was removed from small cubes of tissue with two changes of xylene over a period of 2 hours at 57°C and then the tissue was cleared with two changes of carbon tetrachloride for 30 minutes. The tissue was immersed in 1% osmium tetroxide in carbon tetrachloride for 2 hours, followed by 1% uranyl acetate in methanol for one hour. The methanol was cleared with two changes of acetone for 30 minutes, also assuring complete dehydration. The tissue was then impregnated and embedded in maraglas by standard methods. Sections cut on a Reichert ultramicrotome were stained with lead citrate and examined with a Philips electron microscope, model 300 at 60 Kv.

Due to post-mortem changes and formalin fixation, we were unable to describe detailed cytological changes. Similar lack of preservation of details of fine structure have been reported by Harland et al. (1967, *Lancet* 2: 581-582) and Morecki and Becker (1968, *Arch. Path.* 86: 292-296) who demonstrated herpesvirus particles by electron microscopy of formalin-fixed and paraffin-embedded human tissues. Nevertheless, a coarse margination of chromatin was observed along the inner wall of the nuclear membrane. The central area of the nucleus was occupied by a granular matrix containing a number of particles of high density. These areas may correspond to the eosinophilic inclusions seen by light microscopy. A halo was apparent between the central parts of the nucleus and the margined chromatin. This was interrupted by dark foci, containing viral particles. The most significant finding was numerous viral particles, both in the cell cytoplasm adjacent to the nucleus and in the nucleus itself (Fig. 3). In the nucleus, capsids and central cores of relatively high density were visible, measuring approximately 80 m μ . The hexagonal profile of these par-

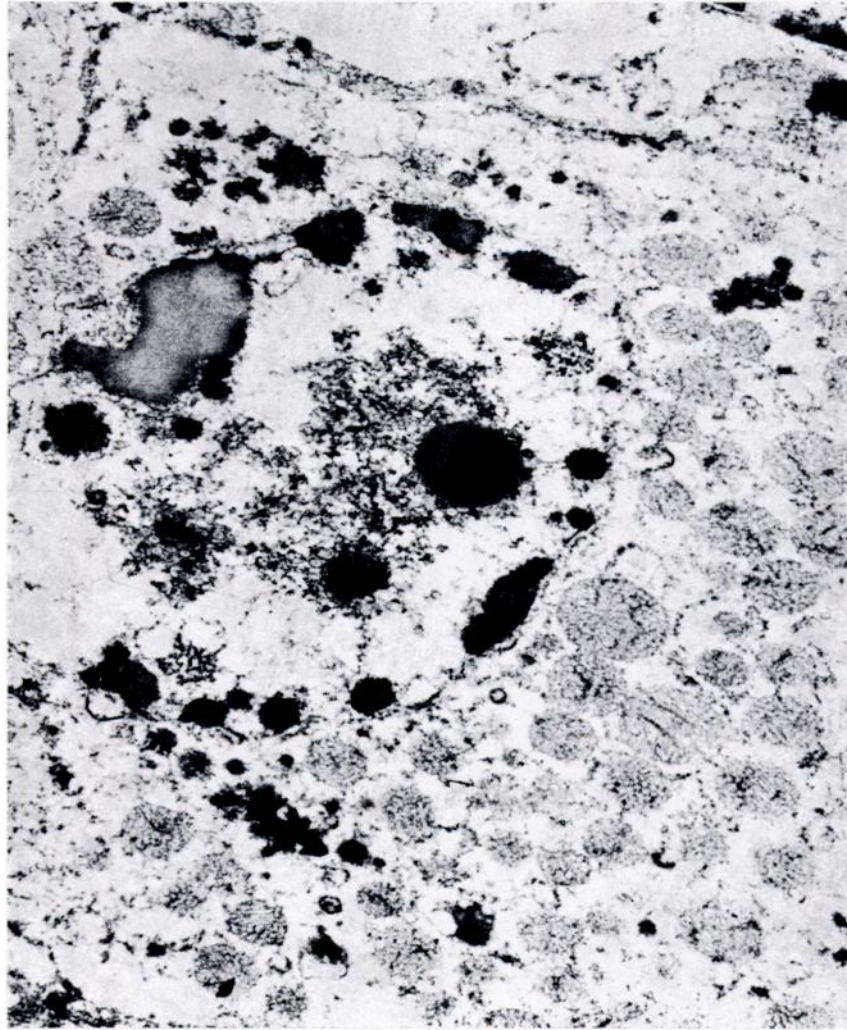


FIGURE 3. *Electronmicrograph of a cell of the zona fasciculata of the adrenal. Notice marginated chromatin along the inner wall of the nuclear membrane, viral particles in both nucleus and cytoplasm and the dense, granular inclusion body masses. X 20400.*

ticles was noticeable. In the cytoplasm, at higher magnification, enveloped capsids, approximately 140 m μ , with internal structures, were seen (Fig. 4). Furthermore, buds or ballooned portions of the nuclear membrane contained enveloped

viral particles (Fig. 5). This seemed to represent the last stages of envelopment and release of virus from the nucleus into the cytoplasm, as has been described by others (Darlington and Moss, 1969, *Progr. Med. Virol.* 11: 16-45).

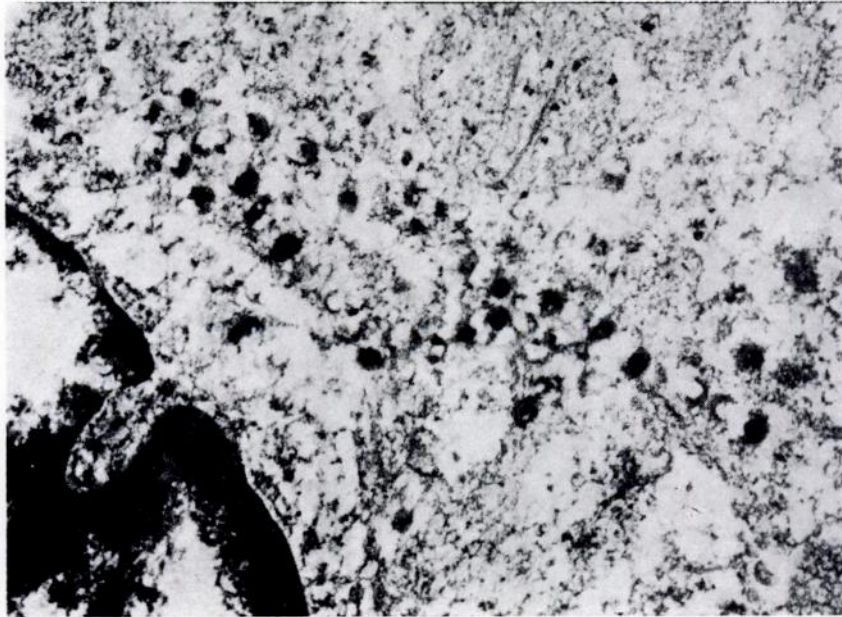

FIGURE 4. *Electronmicrograph of part of a cell of the zona fasciculata. Notice enveloped particles in the cytoplasm. X 52700.*

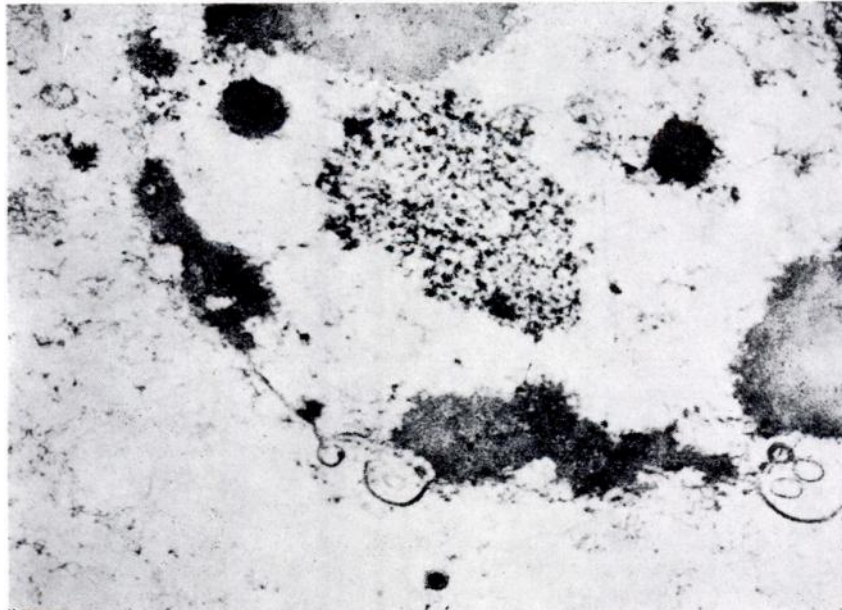


FIGURE 5. *Electronmicrograph of part of a cell of the zona fasciculata to show budding of the nuclear membrane. Notice enveloped "full" particles with intact core and "empty" particles. X 40100.*

Discussion

Inclusion bodies are a well-known histologic feature of many viral infections, and are often of diagnostic value. They may represent foci of developing virions, or sites of viral degradation (Rabin and Jenson, 1967, *Progr. Med. Virol.* 9: 392-450). On the other hand, non-viral inclusions have been found (Sobel, et al., 1969, *Arch. Path.* 87: 172-192). It is evident that the lesions in this instance were the result of the response to the viral infection. Unfortunately, material was not retained for animal inoculation and so verification of the condition by demonstration of the virus in other animals could not be made. The question concerning this case is whether this agent is a member of the herpesvirus group. Evidence supporting this concept is:

- (1) The morphologic similarities between the virus in question and members of the herpesvirus group, as revealed by the electron microscope (Nii, et al., 1968, *J. Virol.* 2:

517-536; Rhodes and Van Rooyen, 1968, *Textbook of Virology*, 5th edition. Williams and Wilkins Co., Baltimore; Wildy, et al., 1960, *Virology* 12: 204-222).

- (2) The distribution and pattern of the lesions by light microscopy. The individual lesions bear a close resemblance to those of pseudorabies, systemic herpes simplex and B virus infections (Gresham and Jennings, 1962, *An Introduction to Comparative Pathology*, pg. 61. Academic Press, N.Y.; Rhodes and Van Rooyen, op. cit.; Sabin and Hurst, 1935, *Brit. J. Exp. Path.* 16: 133-148; Trainer and Karstad, 1963, *Zoonoses Research* 2: 135-151; Wright and Symmers, 1966, *Systemic Pathology*, vol. II. pp. 1198, 1573. Longmans).

Histological changes of the pineal body such as we have described, have not, to our knowledge, been reported in other herpesvirus infections.

Acknowledgements

We wish to thank Dr. P. Lusi, Section of Zoonoses and Diseases of Wildlife, Ontario Veterinary College, for performing the gross post-mortem examination. Electron microscope facilities were supplied by the Ontario Science Center.

P. GOUDAS*

*Department of Pathology,
Section of
Zoonoses and Wildlife Diseases,
Ontario Veterinary College,
Guelph, Ontario*

and

J. S. GILROY

*Ontario Science Centre,
Don Mills, Ontario*

April 29, 1970

*Present address:

Connaught Medical Research Laboratories
1755 Steeles Avenue W.
Willowdale, Ontario.