



## **Hepatozoon sp. IN NORTHERN VOLES, *Microtus oeconomus*, ON ST. LAWRENCE ISLAND, ALASKA**

Author: OHBAYASHI, MASASHI

Source: Journal of Wildlife Diseases, 7(1) : 49-51

Published By: Wildlife Disease Association

URL: <https://doi.org/10.7589/0090-3558-7.1.49>

---

BioOne Complete ([complete.BioOne.org](https://complete.BioOne.org)) is a full-text database of 200 subscribed and open-access titles in the biological, ecological, and environmental sciences published by nonprofit societies, associations, museums, institutions, and presses.

Your use of this PDF, the BioOne Complete website, and all posted and associated content indicates your acceptance of BioOne's Terms of Use, available at [www.bioone.org/terms-of-use](https://www.bioone.org/terms-of-use).

Usage of BioOne Complete content is strictly limited to personal, educational, and non - commercial use. Commercial inquiries or rights and permissions requests should be directed to the individual publisher as copyright holder.

---

BioOne sees sustainable scholarly publishing as an inherently collaborative enterprise connecting authors, nonprofit publishers, academic institutions, research libraries, and research funders in the common goal of maximizing access to critical research.

## Hepatozoon sp. IN NORTHERN VOLES, *Microtus oeconomus*, ON ST. LAWRENCE ISLAND, ALASKA

During an investigation of the developmental characteristics of a larval cestode, *Echinococcus multilocularis* Leuckart, in northern voles, *Microtus oeconomus* Pallas, of St. Lawrence Island, Bering

Sea, I found *Hepatozoon* sp. in tissue sections from 11 of 77 cases studied. *Hepatozoon* has not been reported previously from rodents in Alaska.

### Materials and Methods

The voles were selected examples from large series collected over a 14-year period (1955-1968) by personnel of the Zoonotic Disease Section, Arctic Health Research Center. Serial sections of hepatic

tissues from these voles were prepared by the paraffin-embedding method and stained with hematoxylin-eosin. The protozoan was found in the schizogony stage in these sections.

### Results

Infection was light in all 11 cases, and no evidence of pathogenicity was noted. The schizonts were found within hepatic cells; in some cases cells of the sinusoidal endothelium had formed a minute focus around them. The mature schizont with micromerozoites, the X schizont (Mackerras, M. J., 1961, Aust. J. Zool. 9: 61-122), was subspherical, 20 to 30  $\mu$  in diameter, and contained usually 80 to 120 (rarely more than 200) micromerozoites (Fig. 1). The micromerozoites were slender, 8 to 10  $\mu$  long by 1.5 to 1.8  $\mu$  wide. The actual length of the merozoite and the position of the nucleus could not be determined because of the nature of the preparations. The cytoplasm took a homogeneous, acidophilic stain. The nucleus was ellipsoid, 1.8 to 2.5  $\mu$  by 1.2 to 1.5  $\mu$ , and contained coarse granules of chromatin. In the immature X schizont, the nuclei were arranged marginally and the cytoplasm was flocculated (Fig. 2). A few schizonts with 2 to 6 macromerozoites, the Y schizont (Mackerras, M. J., 1961, Aust. J. Zool. 9: 61-122), were found; these were 12 to 15  $\mu$  in diameter (Fig. 3). The macromerozoites were 9 to 10  $\mu$  long by 3.4 to

4  $\mu$  wide and were slightly arched with one end somewhat thicker than the other. The nucleus was chromatin-poor, with a thin nuclear membrane, and was 3 to 3.7  $\mu$  long by 2.5  $\mu$  wide; it was situated near the thicker end. The cytoplasm was acidophilic and contained several minute vacuoles.

In November, 1968, 13 northern voles were brought alive from St. Lawrence Island to the laboratory, and the liver, spleen, lungs, and blood were examined in detail. Blood smears, prepared by both the routine and concentration methods (Herman, C. M. and Price, D. L., 1955, J. Protozool. 2: 48-51), and spleen impressions gave negative results in all cases. Immature X schizonts were found in hepatic sections in three cases; in one of these, a few gametocytes were identified in monocytes of impression smears of liver and lung, stained by the Wright-Giemsa method (Figs. 4 & 5). The slightly arched gametocyte was 9 to 10  $\mu$  long by 2.5 to 4  $\mu$  wide. The homogeneously staining nucleus, 3 to 4.5  $\mu$  by 2 to 3  $\mu$ , was situated eccentrically. The cytoplasm contained basophilic granules.

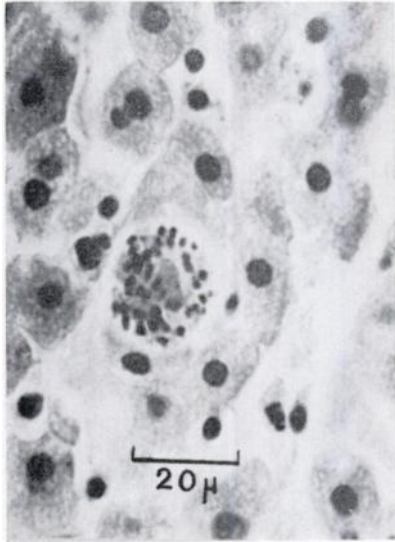


FIGURE 1

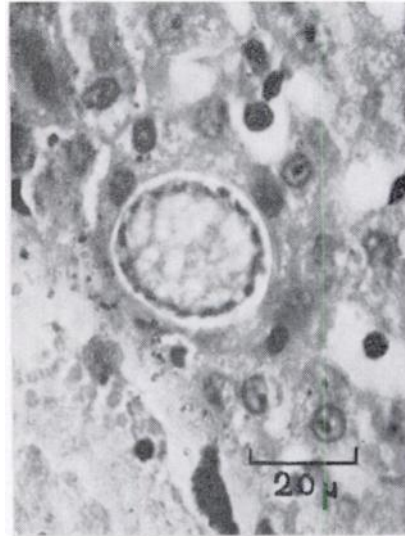


FIGURE 2

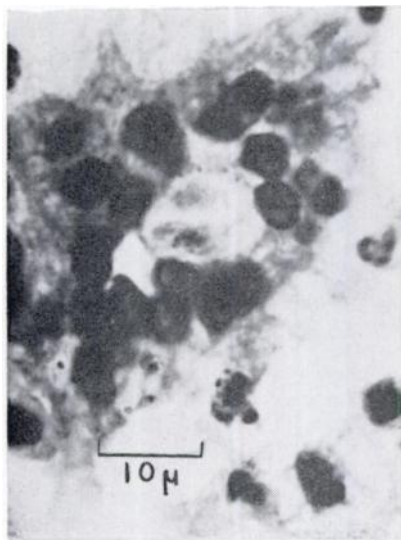


FIGURE 3

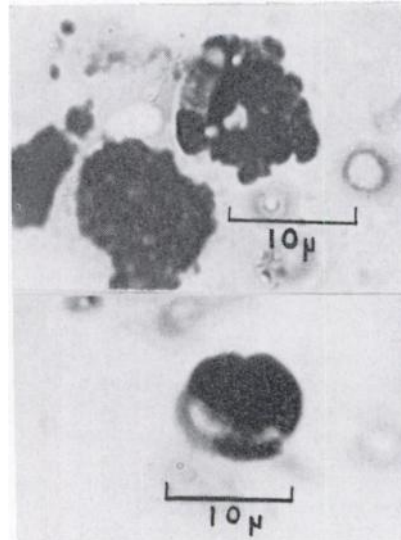


FIGURE 4 &amp; 5

FIGURE 1. Mature *X* schizont containing micromerozoites in the liver of a northern vole.

FIGURE 2. Immature *X* schizont with peripheral nuclei in the liver of a northern vole.

FIGURE 3. Mature *Y* schizont containing two macromerozoites in the liver of a northern vole.

FIGURES 4 and 5. Gametocytes in monocytes from impression smears of the lungs of a northern vole.

### Discussion

This species is characterized by a large number of micromerozoites in each schizont and by the presence of gametocytes and schizonts in monocytes and hepatic cells, respectively. Krampitz (1964, *Acta Trop.* 21: 115-154) investigated various species of *Hepatozoon* in rodents of southern Europe. His *Hepatozoon* sp. from *Microtus oeconomus* was also characterized by gametocytes in monocytes and schizonts in hepatic cells, but further details were lacking.

In North America, species of *Hepatozoon* have been reported from the gray squirrel, *Sciurus carolinensis* Gmelin (Clark, G. M., 1958, *J. Parasit.* 44: 52-63; Dorney, R. S., and Todd, A. C.,

1959, *J. Parasit.* 45: 309; Herman, C. M., and Price, D. L., 1955, *J. Protozool.* 2: 48-51; Weindanz, W. P., and Hyland, K. E., 1958, *J. Parasit.* 44: 97), the California ground squirrel, *Citellus beecheyi* (Richardson) (Wellman, C., and Wherry, W. H., 1910, *Parasitol.* 3: 417-422), and the brown rat, *Rattus norvegicus* (Berkenhout) (Andrews, J., and White, H. F., 1936, *Amer. J. Hyg.* 24: 184-206; Eyles, D. E., 1952, *J. Parasit.* 38: 222-225; Miller, W. W., 1908, *U.S. Publ. Hlth. Serv., Hyg. Lab. Bull.* No. 46; Price, E. W., and Chitwood, B. G. 1931, *J. Parasit.* 18: 55). Further investigation, including clarification of the life cycle, is required to determine the identity of the species reported here.

### Acknowledgements

The author expresses his appreciation to Drs. Robert L. Rausch and Francis H. Fay and to

Mr. Larry M. Shults for providing the specimens of voles collected by them.

MASASHI OHBAYASHI\*

*Zoonotic Disease Section  
Arctic Health Research Center  
U.S. Department of Health, Education,  
& Welfare  
College, Alaska*

June 10, 1970

\*Present address:

*Department of Parasitology  
Faculty of Veterinary Medicine  
Hokkaido University  
Sapporo, Japan*