

## **GRANULOMATOUS ENTERITIS IN *Catostomus commersoni* ASSOCIATED WITH DIATOMS**

Author: WOLKE, RICHARD E.

Source: Journal of Wildlife Diseases, 7(1) : 76-79

Published By: Wildlife Disease Association

URL: <https://doi.org/10.7589/0090-3558-7.1.76>

---

BioOne Complete ([complete.BioOne.org](https://complete.BioOne.org)) is a full-text database of 200 subscribed and open-access titles in the biological, ecological, and environmental sciences published by nonprofit societies, associations, museums, institutions, and presses.

Your use of this PDF, the BioOne Complete website, and all posted and associated content indicates your acceptance of BioOne's Terms of Use, available at [www.bioone.org/terms-of-use](https://www.bioone.org/terms-of-use).

Usage of BioOne Complete content is strictly limited to personal, educational, and non - commercial use. Commercial inquiries or rights and permissions requests should be directed to the individual publisher as copyright holder.

---

BioOne sees sustainable scholarly publishing as an inherently collaborative enterprise connecting authors, nonprofit publishers, academic institutions, research libraries, and research funders in the common goal of maximizing access to critical research.

## GRANULOMATOUS ENTERITIS IN *Catostomus commersoni* ASSOCIATED WITH DIATOMS

Algae are members of the plant kingdom of unsettled classification and, in some instances, of known pathogenicity to man and other animals (Schantz, *Properties and Products of Algae* (J. E. Zajic, ed.), p. 83, Plenum Press, New York, 1970). Pathogenicity is primarily related to the production of toxins by members of the Cyanophyta (blue-green algae) although a member of the Chlorellaceae, *Prototheca* sp., is an infectious pathogen *per se* (Van Kruiningen *et al.*, *Path. vet.*, 6: 345-354, 1969).

A division of the algae known as the Chrysophyta contains unicellular plants with cell walls of silica which are commonly referred to as diatoms. These photosynthetic organisms are of ubiquitous distribution in aquatic and soil environments but have not been reported as pathogens of vertebrates. The cell wall of the diatom is composed of hydrated amorphous silica (silicon dioxide) with small amounts of aluminum and iron oxides deposited in a probable pectin organic matrix (Smith, *The Freshwater*

*Algae of the United States*, 2nd ed., McGraw-Hill, New York, 1950; Patrick and Reimer, *The Diatoms of the United States*, Vol. 1, Monographs of the Academy of Natural Sciences of Philadelphia, No. 13, 1966; Lewin, *Canad. J. Microbiol.*, 3: 427-433, 1957).

Silicon dioxide is known to elicit severe granulomatous reactions in the lung and other organs of man and domestic animals (Gardner, *Am. J. Path.*, 13: 13-24, 1937). Furthermore, particulate matter (i.e., the exoskeleton of diatoms) which cannot be destroyed by normal body defenses may, in itself, elicit a granulomatous reaction. Hence, it appears that the diatom possesses two physical characteristics capable of bringing about a granulomatous lesion if these organisms find their way into tissues.

This paper describes a granulomatous enteritis in the white sucker (*C. commersoni*) in association with numerous phagocytized diatoms, some of which were positively identified as members of several genera.

### Materials and Methods

The white sucker was captured April 15, 1970 by seine in the Quinebaug River, Wauregan, Connecticut as part of a State Fish Disease Survey Project.

All tissues for histological examination were fixed in 10% formalin, embedded in paraffin, sectioned at 6 microns, and stained with hematoxylin and eosin,

Ziehl-Neelsen acid fast, periodic acid-Schiff, and Kossa stains.

Diatoms were isolated for identification by the following method: paraffin embedded sections were cut from 4 to 40 microns, placed on slides, washed with xylene, dried, ashed for a period of 30 to 60 minutes, and mounted in Permount.

### Results

The fish was a 4-year-old male, weighing 295 grams with a total length of 33 centimeters. There were no external gross lesions. Internal examination revealed the first 5 to 7 centimeters of the foregut to be thickened, rubbery in consistency, and empty. The rest of the intestine was normal and contained brownish detritus. There were no other internal gross lesions.

Histologically, the villi of the affected intestine were short, thick, and swollen. The crypts that normally exist between these structures were obliterated and their previous existence was discernible only by the persistence of the lining mucosa cells lying at right angles to the gut lumen. The submucosa of the villi were packed with uniform, acidophilic, poly-

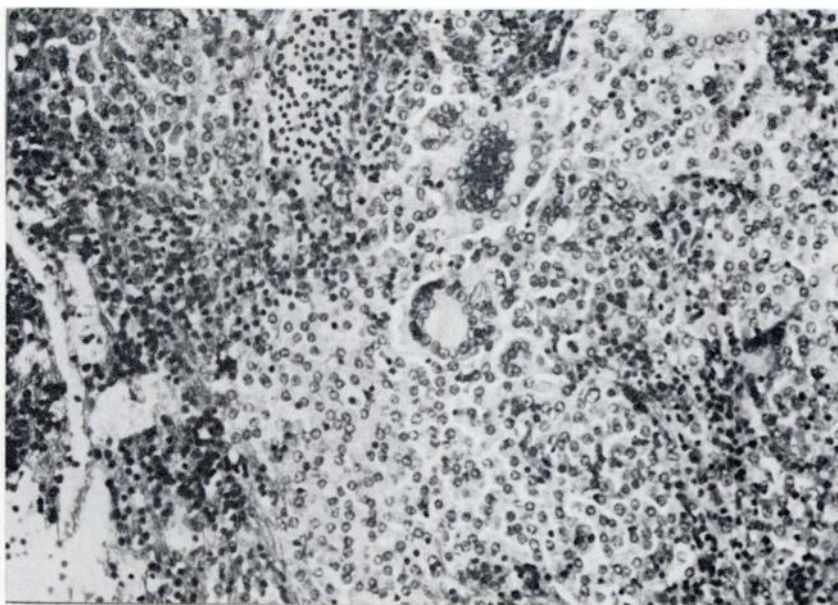


FIGURE 1. Severe granulomatous reaction with giant cells in lamina propria of anterior intestine. H & E; X400.

gonal histiocytic cells. In some instances these cells were in distinct islands outlined by congested vessels and thin connective tissue septae (Fig. 1). A diffuse scattering of lymphocytes was present immediately below the mucosa.

Giant cells of both the Langhans and foreign body type were dispersed among the histiocytes of the submucosa. Present within the cytoplasm of at least half of these cells were ovoid or rectangular striated refractile bodies varying in length from 5 to 10 microns. Occasionally these bodies and their fragments were found free between the histiocytic cells, but none were found free in the lumen of the gut. The morphology of these organisms was so characteristic that identification as diatoms (Chrysophyta) (*Cymbella*) was possible by light microscopy of hematoxylin and eosin stained sections (Fig. 2). Periodic acid-Schiff and Kossa stains for better differentiation of the organisms were negative. Phase microscopy was the

most efficient means for prompt location and identification of the diatoms in routinely stained preparations. Ziehl-Neelsen stains for acid fast organisms were negative in all sections examined. All other organs were microscopically normal.

In the incinerated preparations of the sectioned material several different diatom genera could be identified easily. Whole walls of the pennate diatoms *Eunotia* and *Cocconeis* were observed. In addition, almost complete skeletons of the centrate diatoms *Melosira* and *Cyclotella*, as well as the pennate *Cymbella*, were present in the tissue; the latter two genera were badly broken, possibly in sectioning of the material. We report probable presence of *Gomphonema* and *Fragilaria*. A fragment of a *Nitzschia* was positively identified and a portion of the wall of a *Synedra* was seen. Numerous other fragments of broken diatoms were scattered in the tissue. Some were

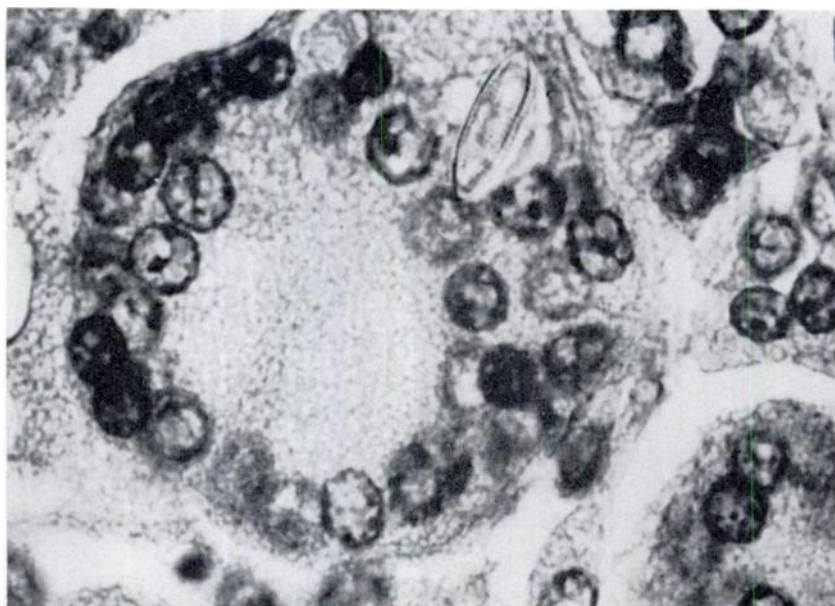


FIGURE 2. Valve view of diatom in giant cell. H & E; X 1,000.

probably broken at time of ingestion, but it appears that many of the fragments resulted from the preparation of the sections. Inasmuch as identification of the

diatoms is based on clear views of all aspects of ornamentation, several of the observed glass walls could not be positively identified.

#### Discussion

The most interesting facet of this case report is the question of the relationship between the granulomatous enteritis and the presence of the diatoms in the submucosal tissue of the foregut. One is certainly justified in questioning a direct cause and effect relationship. However, circumstantial evidence appears sufficient to incriminate the diatoms as a probable cause of the severe reaction present.

Granulomatous enteritis is a disease of multiple origin which has been reported in man and domestic animals (Jubb and Kennedy, *The Pathology of Domestic Animals*, Vol. II, Academic Press, New York, 1963; Van Kruiningen *et al.*, *Path. vet.*, 2: 521-544, 1965; Robbins, *Pathology*, Vol. II, W. B. Saunders Co., Philadelphia, Pennsylvania, 1967). Members

of the Mycobacteriaceae are one of the most common causes in man, other animals, and fish. Additional causes include fungi, higher bacteria, and foreign bodies (Refvem, *Acta Path. Microbiol. Scand.*, 25: 107-120, 1948; Robbins, *Pathology*, Vol. I, W. B. Saunders Co., Philadelphia, 1967). The lesion described in this report is similar, with the exception of giant cells, to the lesions of tuberculosis in fish (Nigrelli and Vogel, *Zoologica*, 48: 131-144, 1963). However, no acid fast organisms were present in this case and there is no other evidence that the reaction was due to a Mycobacterium.

As previously mentioned, granulomas of the gut may be elicited by the presence of foreign bodies both of a proteinaceous and mineral nature. The exoskeleton of

diatoms qualifies as a mineral foreign body and it seems logical to assume that it is capable of eliciting such a foreign body response.

In addition, it is of interest to note that the exoskeleton is composed of silicon dioxide (Lewin, *op. cit.*). The severe granulomatous reaction of silicon is well known and the condition of silicosis in man is a recognized occupational disease (Robins, *op cit.*).

One might, therefore, speculate that the silicon dioxide of the diatoms' exoskeleton is in part responsible for the granulomatous reaction seen in this fish's intestine. This is an especially attractive hypothesis since it is known that silicon will elicit this kind of lesion in fish and

other animals under experimental conditions and that the lesion of silicosis is identical to lesions seen in cases of tuberculosis of higher vertebrates (Gardner, *op. cit.*).

Diatoms have not previously been reported as pathogens of vertebrates and the authors do not wish to give the impression that they believe them to be invasive organisms. These plants commonly pass through the gut of fishes and do not result in lesions of any sort. In this case it seems probable that there was a pre-existing lesion which allowed entrance of the diatoms to the submucosa where they were able to elicit the observed reaction as foreign bodies due to their content of silicon.

RICHARD E. WOLKE\*

*Department of Animal Diseases*

and

F. R. TRAINOR

*Department of Biological Sciences*

*University of Connecticut*

*Storrs, Connecticut 06268*

July 27, 1970

\*Present address:

*School of Oceanography,  
University of Rhode Island,  
Narragansett, Rhode Island 02882.*