



GASTRIC ULCERS ASSOCIATED WITH *Contracaecum* SPP. (NEMATODA: ASCAROIDEA) IN A STELLER SEA LION AND A WHITE PELICAN 1

Authors: LIU, SI-KWANG, and EDWARD, ALFRED G.

Source: Journal of Wildlife Diseases, 7(4) : 266-271

Published By: Wildlife Disease Association

URL: <https://doi.org/10.7589/0090-3558-7.4.266>

BioOne Complete (complete.BioOne.org) is a full-text database of 200 subscribed and open-access titles in the biological, ecological, and environmental sciences published by nonprofit societies, associations, museums, institutions, and presses.

Your use of this PDF, the BioOne Complete website, and all posted and associated content indicates your acceptance of BioOne's Terms of Use, available at www.bioone.org/terms-of-use.

Usage of BioOne Complete content is strictly limited to personal, educational, and non - commercial use. Commercial inquiries or rights and permissions requests should be directed to the individual publisher as copyright holder.

BioOne sees sustainable scholarly publishing as an inherently collaborative enterprise connecting authors, nonprofit publishers, academic institutions, research libraries, and research funders in the common goal of maximizing access to critical research.

GASTRIC ULCERS ASSOCIATED WITH *Contracaecum* SPP. (NEMATODA: ASCAROIDEA) IN A STELLER SEA LION AND A WHITE PELICAN^[1]

SI-KWANG LIU,^[2] and ALFRED G. EDWARD

Abstract: *Contracaecum* spp. (Nematode: Ascaroidea) caused gastric ulcers in a Steller sea lion from the California coast and a white pelican from Tule Lake, California. The parasite penetrated deeply into the gastric wall, causing extensive inflammatory reaction. A hyaline material formed a mold surrounding the head of the nematode in the granulation tissue.

Contracaecum is a parasite of sea mammals,^{5,7,9,10,19,21,22} marine birds,²⁴ and marine fishes.⁶ In the cases reported here, adult and juvenile worms were found in ulcerative lesions of the stomach of a Steller sea lion and the proventriculus of a white pelican.

Gross Pathology

A piece of stomach 16.4 cm by 12.5 cm of a male Steller sea lion (*Eumetopias jubata*) captured on the California coast was submitted for pathologic and parasitologic studies. Grossly, two ulcers were observed in the specimen. The first ulcer was irregularly shaped, 3.5 cm long, 1.2 to 1.8 cm wide and 0.6 to 0.9 cm deep, and contained seven tightly attached worms. The second ulcer was round, 0.8 cm in diameter and 0.6 cm deep, and contained four worms. Some worms were free on the mucosa of the stomach.

The adult parasite had three lips and interlabia and had a cervical collar behind its head (Figure 2). The anterior cecum was larger than the posterior appendix. Spicules were equal, the gubernaculum was absent in the male, and the vulva was in the anterior part of the female body. The parasite corresponded closely to descriptions of *Contracaecum osculatum*.^{5,11,23,24}

The ulcers were dark gray, and their edges were sharp and distinct. Their surfaces were coated with mucus, and their bases with a layer of necrotic tissue in which the heads of the parasites were buried. The ulcers extended through the mucosa, submucosa, and into the musculature of the gastric wall. The tissue surrounding them was swollen and thickened, reddish-gray, and firm to the touch. The vessels in the serosa were congested.

A piece of proventriculus of a white pelican (*Pelecanus erythrorhynchos*) of unknown sex captured on Tule Lake, California, was submitted for pathologic and parasitologic examinations. Three irregular ulcers, 5 to 8 mm in diameter and 3 to 5 mm deep, and two or three worms tightly attached to each ulcer were observed in the specimen. The parasites were identified as *Contracaecum* sp.

Histopathology

In the piece of stomach from the Steller sea lion, the base of the ulcers was covered first by a rather thick layer of fibrinous necrotic material studded with bacterial clumps. Beneath this was a thin layer of nuclear debris and disintegrated granulocytes (Figure 1), which merged into a thick layer of granulation

[1] From the School of Veterinary Medicine, University of California, Davis, California 95616.

[2] Present Address: Department of Pathology, The Animal Medical Center, New York, New York 10021.

tissue consisting mainly of granulocytes, lymphocytes, plasma cells, macrophages, histiocytes, fibroblasts, and angioblasts. Beneath the granulation tissue was fibrous (scar) tissue — chiefly fibroblasts, angioblasts, histiocytes, collagen fibers with a whorl pattern, newly formed blood vessels, and a few lymphocytes and plasma cells. The fibrous tissue extended down between bundles of muscle. The glands adjacent to the ulcer were decreased in height, tortuous, and dilated. They were lined with undifferentiated, mucin-secreting cells resembling intestinal epithelial cells. Specific parietal cells and chief cells were absent. The adjacent mucosa and submucosa were infiltrated

with numerous lymphocytes and plasma cells.

The heads of the immature worms penetrated into the granulation tissue and even extended deeply into the immature fibrous tissue. The bodies of the parasites were bathed in the necrotic debris and masses of bacteria. A pink to bluish-pink hyaline material formed a mold around the head of the parasite deep in the granulation tissue (Figure 2). Immediately adjacent to this material was necrotic tissue consisting of pyknotic nuclei and eosinophilic cytoplasm. Masses of bacteria trailed behind the hyaline material. The hyaline image was mixed with streaks of basophilic nuclear fragments in the peri-

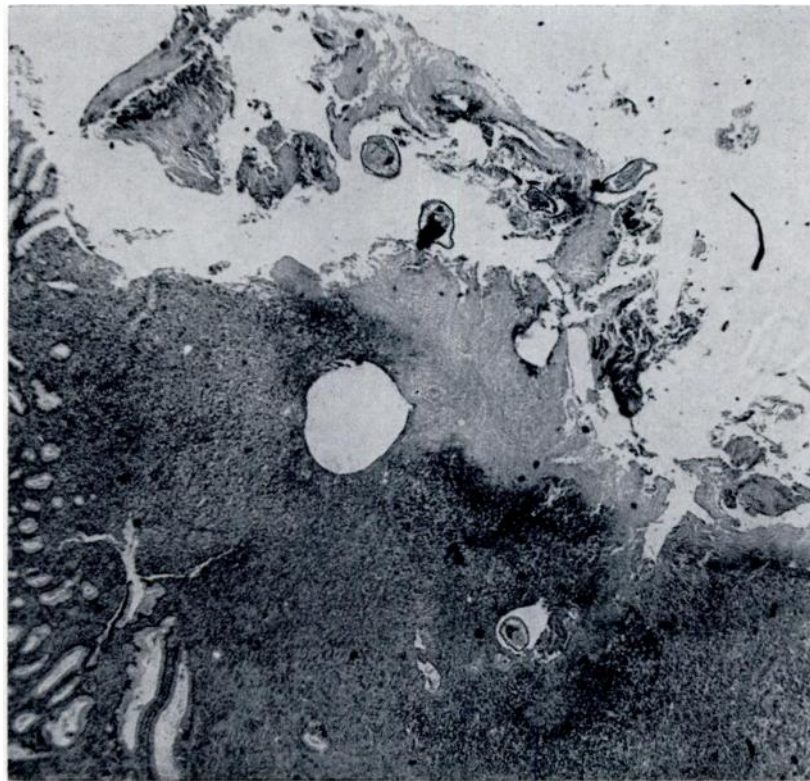


FIGURE 1. Stomach of a Steller sea lion; ulcerated surface is coated with necrotic material and fibrin. Mucosa has been replaced by granulation tissue. Sections of the nematode are seen on the surface as well as deep within the granulation tissue. H & E stain, $\times 25$.

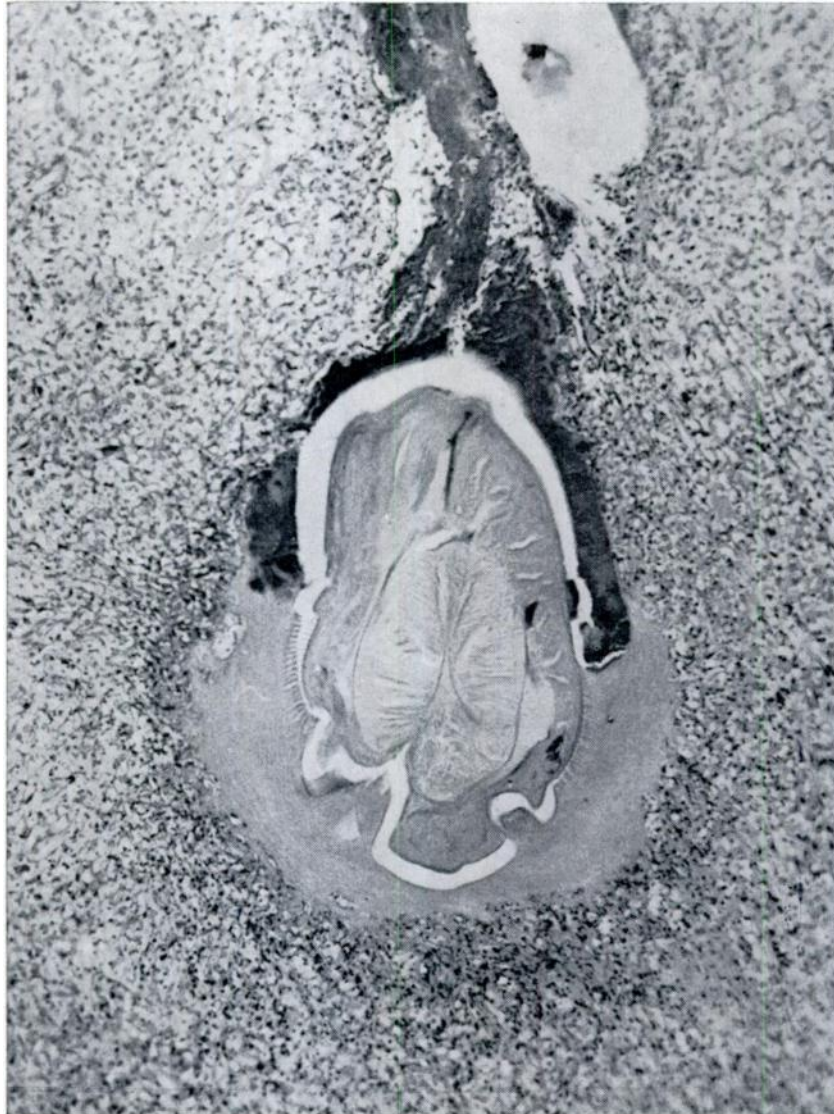


FIGURE 2. Section of the head of *Contracaecum* surrounded by hyaline material and immersed in the necrotic debris and granulation tissue. Bacterial masses trail behind the hyaline material. H & E stain, x 50.

phery. The hyaline mold, which had been vacated by the head of the worm, was occupied by numerous granulocytes and macrophages. The periphery of the hyaline substance had merged into the granulation tissue.

Similar lesions were observed in the proventriculus of the white pelican, except that the granulation tissue was minimal (Figure 3).

Histochemical reactions of the hyaline material were varied. With the periodic acid Schiff (PAS) reaction,² the internal

border was yellow, the periphery was light orange-pink, and the worm was a yellowish pink. With Mallory Crossman stain,² the hyaline material was dark red to red-orange, with some bluish staining material. In trichrome Pollak stain,¹⁷ it was greenish, similar to collagen and reticulum. It was negative for iron in Perls' stain.⁴ There was no reaction in Gram-Weigert stain.¹⁰ It was greenish in Gordon Sweet stain,¹⁰ negative for DNA in the inner portion in Feulgen stain,⁴ and negative for RNA and DNA in methyl green pyronine stain.⁴

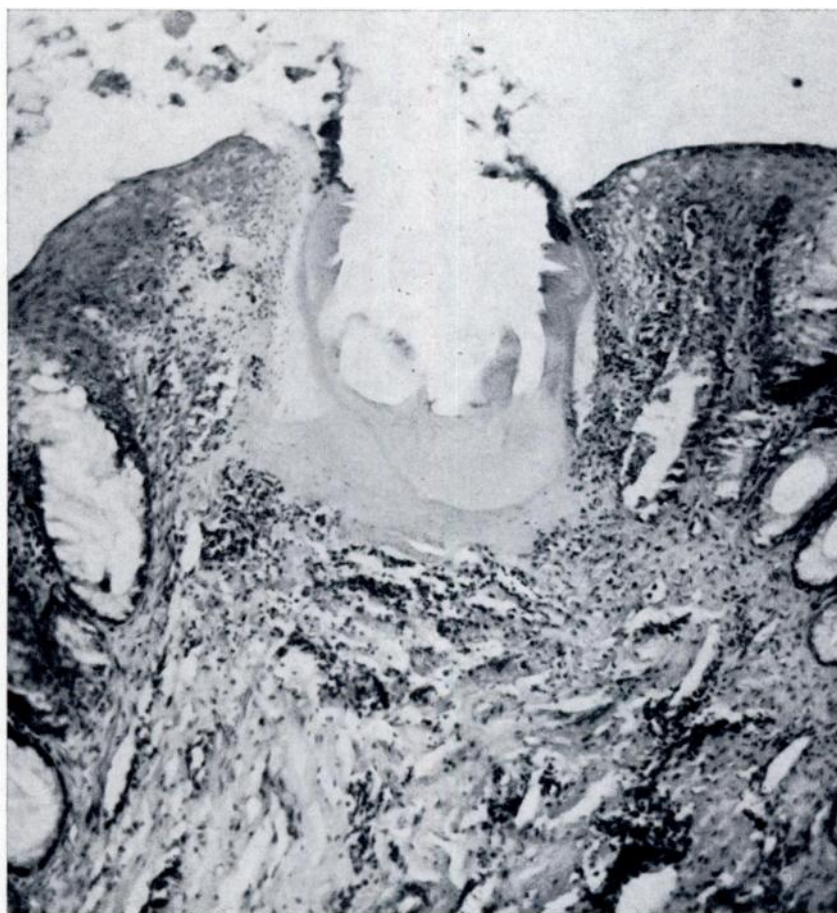

FIGURE 3. Proventriculus of a white pelican. Hyaline material formed around *Contracaecum* sp. has been surrounded by necrotic debris and inflammatory cells in the mucosa. H & E stain, x 50.

DISCUSSION

In the cases described here, the principal gastric lesions are probably due to penetration of the immature worms, their excretion or secretion causing local tissue destruction and inflammation. The nematode has been reported responsible for gastric ulcers in sea mammals.^{9,10,19,22}

The formation of the hyaline substance around the head of the immature nematodes in the stomach of the sea lion and proventriculus of the white pelican is not fully understood. Results of histochemical studies, however, suggest that the material consisted of secretions of the larva mixed with necrotizing tissue and cells from the host, indicated by the presence of pyknosis and karyorrhexis of cell nuclei in its periphery. The hyaline material was similar, but not identical, to that of cutaneous lesions in man,¹⁵ in mice experimentally infected with the larvae of *Trombicula akamushi*,¹ and in black ducks and mallards naturally infected with *Womersia strandmani*.⁸ It was different from the cuticle and cast skin of the nematode.^{3,12,13} We thought the material might be an antigen-antibody complex. Identical lesions were also seen in the stomach of a rabbit experimentally

infected with *Anisakis marina*.¹⁸ What role the hyaline substance played in the host-parasite relationship is unknown at the present time. It might have functioned as a glue to insure a stable position for development of the larva against the gastric peristalsis.

The life cycle of this nematode is still obscure. An intermediate host, normally an invertebrate (copepod), and a second intermediate (or transport) host, normally vertebrate (fishes) are required. The final host, such as a sea mammal, marine bird or marine fish, acquires the infection by ingesting the infected fish.⁶ More than 150 cases of the so-called herring worm disease in man were reported in the Netherlands from 1955 to 1968.^{18,20} The causal parasite was a larva of *Anisakis marina* from green herring, and consumption of lightly salted herring was the source of infection.¹⁸ Parasitic granuloma caused by *Contracaecum* sp. larva were reported in the stomachs of dogs living around the seashore of Hokkaido, Japan.¹¹ The dogs had eaten infected fish. Since the life cycle of the nematode could not be completed in an abnormal host, such as a dog, the larvae encysted in the gastric wall provoked granulomatous lesions.

LITERATURE CITED

1. AOKI, T. 1957. Histological studies on the so-called stylostome or hypopharynx in the tissues of the hosts parasitized by the Trombiculid mites. *Acta Med. Biol.* 5: 103-120.
2. ARMED FORCES INSTITUTE OF PATHOLOGY. 1960. *Manual of Histologic and Special Staining Techniques*. 2d ed. McGraw-Hill Book Co., New York.
3. ASH, L. R. 1962. Migration and development of *Gnathostoma procyonis* Chandler, 1942, in mammalian hosts. *J. Parasit.* 48: 306-313.
4. BARKA, T., and P. J. ANDERSON. 1963. *Histochemistry*. Harper & Row, Publishers, New York.
5. BAYLIS, H. A. 1937. On the ascarids parasitic in seals with special reference to the genus *Contracaecum*. *Parasitology* 29: 121-130.
6. BERLAND, B. 1961. Nematodes from some Norwegian marine fishes. *Sarsia* 2: 1-5.
7. BERLAND, B. 1963. *Phocascaris cystophorae* sp. nov. (Nematoda) from the hooded seal with an emendation of the genus. *Arbok for Universitetet i Bergen. Mat.-Naturv. Serie No. 17*. Norwegian Univ. Press, Bergen and Oslo.
8. CLARK, G. M., and V. D. STOTTS. 1960. Skin lesions on black ducks and mallards caused by chigger (*Womersia strandmani* Wharton 1947). *J. Wildl. Management* 24: 106-108.

9. JOHNSTON, D. G., and S. H. RIDGWAY. 1969. Parasitism in some marine mammals. J. Am. Vet. Med. Assoc. 155: 1064-1072.
10. KEYES, M. 1965. Pathology of the northern fur seal. J. Am. Vet. Med. Assoc. 147: 1090-1095.
11. KITAYAMA, H., M. OHBAYASHI, H. SATOH, and Y. KITAMURA. 1967. Studies on parasitic granuloma in the dog. Japanese J. Parasit. 16: 28-35.
12. LIU, S.-K. 1965. Pathology of *Nematospiroides dubius*. I. Primary infections in C-H and Webster mice. Exp. Parasit. 17: 123-135.
13. LIU, S.-K. 1965. Pathology of *Nematospiroides dubius*. II. Reinfections in Webster mice. Exp. Parasit. 17: 136-147.
14. LYSTER, L. L. 1940. Parasites of some Canadian sea mammals. Can. J. Res. 18: 395-409.
15. OBATA, Y., and T. AOKI. 1958. Human infesting experiments on the larva of *Trombicula akamushi*. Japanese J. Sanitary Zool. 9: 149-152.
16. PEARSE, A. G. E. 1960. *Histochemistry*, 2d ed. Little, Brown & Co., Boston, Massachusetts.
17. POLLAK, O. J. 1944. A rapid trichrome stain. Arch. Path. 37: 294.
18. RUITENBERG, E. J., J. M. BERKVEN, and M. J. M. DUYZINGS. 1971. Experimental *Anisakis marina* infections in rabbits. J. Comp. Path. 81: 157-163.
19. SCHROEDER, C. R., and H. WEGEFORTH. 1935. The occurrence of gastric ulcers in sea mammals of the California coast, their etiology and pathology. J. Am. Vet. Med. Assoc. 87: 333-342.
20. VAN THEIL, P. H., F. C. KUIPERS, and R. Th. ROSKAM. 1960. A nematode parasitic to herring, causing acute abdominal syndromes in man. Trop. Geogr. Med. 2: 97-113.
21. VIK, R. 1964. Penetration of stomach wall by anisakis-type larvae in porpoises. Can. J. Zool. 42: 513.
22. WILSON, T. M., and P. H. STOCKDALE. 1970. *Contracaecum* sp. infestation in a harp seal. J. Wildl. Dis. 6: 152-154.
23. YAMAGUTI, S. 1961. *Systema Helminthum. Vol. III. The Nematodes of Vertebrates*, part I., pp. 587-858. Interscience Publishers, New York.
24. YORKE, W., and P. A. MAPLESTONE. 1962 (1926). *The Nematode Parasites of Vertebrates*. Hafner Publishing Co., New York.

Received for publication April 29, 1971