

## **CRANIAL ASYMMETRY WITH MASSIVE INFECTION IN A BOX TURTLE**

Authors: JACKSON, CRAWFORD G., FULTON, MACDONALD, and JACKSON, MARGUERITE M.

Source: Journal of Wildlife Diseases, 8(3) : 275-277

Published By: Wildlife Disease Association

URL: <https://doi.org/10.7589/0090-3558-8.3.275>

---

BioOne Complete ([complete.BioOne.org](https://complete.BioOne.org)) is a full-text database of 200 subscribed and open-access titles in the biological, ecological, and environmental sciences published by nonprofit societies, associations, museums, institutions, and presses.

Your use of this PDF, the BioOne Complete website, and all posted and associated content indicates your acceptance of BioOne's Terms of Use, available at [www.bioone.org/terms-of-use](https://www.bioone.org/terms-of-use).

Usage of BioOne Complete content is strictly limited to personal, educational, and non - commercial use. Commercial inquiries or rights and permissions requests should be directed to the individual publisher as copyright holder.

---

BioOne sees sustainable scholarly publishing as an inherently collaborative enterprise connecting authors, nonprofit publishers, academic institutions, research libraries, and research funders in the common goal of maximizing access to critical research.

## CRANIAL ASYMMETRY WITH MASSIVE INFECTION IN A BOX TURTLE

CRAWFORD G. JACKSON, JR., MACDONALD FULTON, and MARGUERITE M. JACKSON,  
Department of Biological Sciences, Mississippi State College for Women,  
Columbus, Mississippi 39701, U.S.A.

**Abstract:** A captured box turtle, *Terrapene carolina*, was found to have a large swelling on the neck, the result of a massive, mixed bacterial infection of *Citrobacter*, *Enterobacter*, *Proteus morganii*, *Proteus rettgeri*, and a non-pigmented strain of *Pseudomonas*. A well-defined caseous mass between the superficial and deep cervical muscles was surrounded by purulent material. An eroded squamosal bone allowed purulent material to gain access to the pharynx. The skull was markedly asymmetrical, due primarily to left squamosal enlargement. Initial entry of the pathogens via pharyngeal trauma is suggested.

An adult male (carapace length: 123 mm) box turtle, *Terrapene carolina*, collected in Lowndes County, Mississippi, near Columbus in July, 1971, was found to have a massive swelling on the left aspect of the neck (Fig. 1A).

Superficial examination revealed the swelling to extend from the posterior border of the tympanum to the edge of the carapace, a distance of about 25 mm with the neck extended. Lateral protrusion of the swelling was about 10 mm. The unbroken skin was incised to determine the internal extent and nature of the swelling. A large, well-defined mass, yellow and caseous in composition, was located between the superficial and deep muscle layers of the neck. The mass extended from the left temporal fenestra (where it lay between and in contact with the squamosal and supraoccipital bones) posteriorly to the level of the carapace edge. It was surrounded by purulent, yellowish material having a distinctly foul odor. Weight of the cleanly excised mass was 6.0 g or 2.1 per cent of the body weight of the turtle.

During excision, it was noticed that the upper part of the anterolateral wall of the quadrate had been eroded away allowing purulent matter to enter the tympanic cavity. Because of this, the head was carefully skinned and skeletonized for osteological examination. The

prepared skull (Fig. 1B) has marked asymmetry as well as extensive additional osteomyelitis of the lateral wall of the left squamosal bone. Although extensive erosion had occurred, the remaining portion of the left squamosal is greatly enlarged dorsally, laterally, and posteriorly when compared to its counterpart. The left frontal bone is also noticeably larger than its counterpart. By contrast, asymmetrical reductions in the dimensions of epipterygoid bone, nasopalatine foramen, and carotico-pharyngeal foramen were noted for the left side.

During examination of the living animal, purulent, foul - smelling material which was observed to issue from the nostrils, was collected on sterile swabs for culturing. When the neck skin was found to be intact, it was incised with aseptic precautions, and swabs were taken from the purulent material surrounding the caseous mass. Swabs were immediately suspended in brain-heart infusion for incubation. Subsequent streaking was done on plates of desoxycholate and blood-milk agar. Both tube and plate cultures were incubated at 35 C and additional plates were streaked at 5 hours and again overnight. Growth was rapid in broth. Desoxycholate plates developed both red and colorless colonies, but no colonies on blood-milk agar exhibited the marked clearing charac-

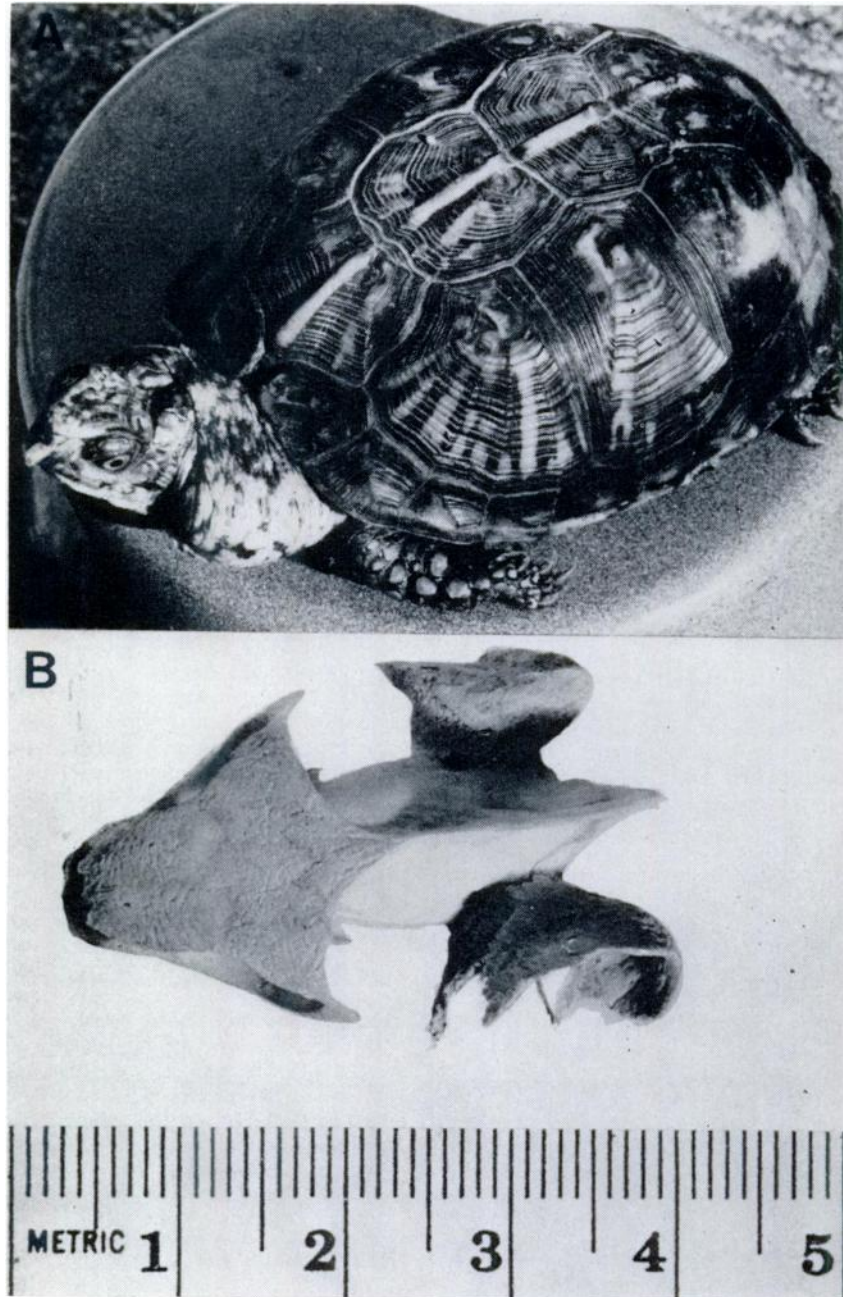


FIGURE 1. Massive bacterial infection of a box turtle. A. Living animal exhibiting large swelling on lateral aspect of neck. B. Dorsal view of skull showing greatly enlarged and eroded left squamosal bone.

teristic of *Aeromonas*. No gram-positive organisms were detected. Examples of all observed colony types derived from nasal drippings and purulent matter on both nutrient media were transferred again to brain-heart infusion, replated and then tested by conventional biochemical methods.

Five kinds of microorganisms were isolated and identified as follows: *Citrobacter*, *Enterobacter*, *Proteus morganii*, *Proteus rettgeri*, and a non-pigmented strain of *Pseudomonas*.

In their extensive monograph, Reichenbach-Klinke and Elkan<sup>4</sup> report no cases of massive, mixed bacterial infections in turtles, although documenting several cases of chelonian infections variously caused by *Aeromonas*, *Serratia*, *Mycobacterium*, and *Peptostreptococcus*. They considered turtles as being merely frequent carriers of the *Salmonella* group of bacteria. In a previous paper, Jackson and Fulton<sup>2</sup> reported the isolation of a mixed microflora (*Citrobacter*, *Escherichia*, *Proteus*, *Pseudomonas* and *Serratia*) from cutaneous lesions encountered on several species of aquatic turtles. From the same sample of turtles they further reported the isolation of *Aeromonas*, *Citrobacter*, *Enterobacter*, *Proteus* and *Serratia* from the heart blood of various individuals later at necropsy. Since the cloaca of several species of wild, apparently healthy turtles has previously been reported<sup>3</sup> to yield mixed floras containing *Aero-*

*bacter*, *Citrobacter*, *Escherichia*, *Proteus* and *Pseudomonas*, it appears that the massive infection described herein is simply a case of infiltration and subsequent pathogenesis by bacteria that seem to be part of the normal flora of cheionians. Boam *et al.*<sup>1</sup> reported subcutaneous abscesses developing on the head and neck of two common iguanas, *Iguana iguana*, kept in a laboratory colony. Bacteriologic cultures of the caseous material yielded *Micrococcus* organisms from one animal and a non-pigmented strain of *Serratia marcescens* from the other. Two spiny-tailed iguanas, *Ctenosaura acanthura*, also from the same colony developed subcutaneous abscesses on the neck and right forelimb. Cultures of caseous material yielded *Salmonella marina* from one lizard, and a non-pigmented strain of *Serratia marcescens* from the other.

No evidence for external entry was found, although it is possible that a puncture wound or similar external injury could have completely healed prior to our examination. We suggest that trauma to the eustachian meatus by a sharp object such as a mollusk shell fragment, may have initiated the infection.

Since no histological investigation was made, we cannot comment as to whether squamosal enlargement was a pre-existing condition or else a result of chronic infection.

#### Acknowledgements

The authors wish to express their appreciation to Mr. Louis O. Joyner of the Mississippi State College for Women Photographic Laboratory who kindly prepared the illustrations.

#### LITERATURE CITED

1. BOAM, G. W., V. L. SANGER, D. F. COWAN, and D. P. VAUGHAN. 1970. Subcutaneous abscesses in iguanid lizards. J. Amer. vet. med. Assoc. 157: 617-619.
2. JACKSON, C. G. JR., and M. FULTON. 1970. A turtle colony epizootic apparently of microbial origin. J. Wildlife Dis. 6: 466-468.
3. JACKSON, M. M., C. G. JACKSON, JR., and M. FULTON. 1969. Investigation of the enteric bacteria of the Testudinata—I: Occurrence of the genera *Arizona*, *Citrobacter*, *Edwardsiella* and *Salmonella*. Bull. Wildlife Dis. Assoc. 5: 328-329.
4. REICHENBACH-KLINKE, H., and E. ELKAN. 1965. *The Principal Diseases of Lower Vertebrates*. Academic Press, New York. 600 p.

Received for publication February 20, 1972