

## **Evidence for Haemosporidian Parasite Infections in Spectacled Eiders (*Somateria fischeri*) Sampled in Alaska, USA during the Breeding Season**

Authors: Reed, John A., Sexson, Matthew G., Smith, Matthew M., Schmutz, Joel A., and Ramey, Andrew M.

Source: Journal of Wildlife Diseases, 54(4) : 877-880

Published By: Wildlife Disease Association

URL: <https://doi.org/10.7589/2018-01-012>

---

BioOne Complete ([complete.BioOne.org](https://complete.BioOne.org)) is a full-text database of 200 subscribed and open-access titles in the biological, ecological, and environmental sciences published by nonprofit societies, associations, museums, institutions, and presses.

Your use of this PDF, the BioOne Complete website, and all posted and associated content indicates your acceptance of BioOne's Terms of Use, available at [www.bioone.org/terms-of-use](https://www.bioone.org/terms-of-use).

Usage of BioOne Complete content is strictly limited to personal, educational, and non - commercial use. Commercial inquiries or rights and permissions requests should be directed to the individual publisher as copyright holder.

---

BioOne sees sustainable scholarly publishing as an inherently collaborative enterprise connecting authors, nonprofit publishers, academic institutions, research libraries, and research funders in the common goal of maximizing access to critical research.

## Evidence for Haemosporidian Parasite Infections in Spectacled Eiders (*Somateria fischeri*) Sampled in Alaska, USA during the Breeding Season

John A. Reed,<sup>1,2</sup> Matthew G. Sexson,<sup>1</sup> Matthew M. Smith,<sup>1</sup> Joel A. Schmutz,<sup>1</sup> and Andrew M. Ramey<sup>1,2</sup> <sup>1</sup>US Geological Survey, Alaska Science Center, 4210 University Drive, Anchorage, Alaska 99508, USA; <sup>2</sup>Corresponding authors (emails: jareed@usgs.gov; aramey@usgs.gov)

**ABSTRACT:** We assessed hematozoa infection in Spectacled Eiders (*Somateria fischeri*) at two areas in Alaska, US. No *Haemoproteus* or *Plasmodium* species were detected. *Leucocytozoon* prevalence was 6.5% for adults across sites and 41.9% for juveniles sampled in the Arctic, providing evidence for local transmission. All *Leucocytozoon* haplotypes were previously detected in waterfowl.

Haemosporidian parasites, or hematozoa, have been associated with mortality events or population declines in songbirds, penguins, and waterfowl (Herman et al. 1975; van Riper et al. 1986; Hill et al. 2010). Hematozoa transmission is regulated by temperature and the presence of suitable vectors; it has been predicted that the prevalence and distribution of hematozoa may be affected by ecological change (Garamszegi 2011; Loiseau et al. 2012; Zamora-Vilchis et al. 2012), particularly in high-latitude areas. In Alaska, information on the distribution of hematozoa in wild birds has increased in recent years (Ramey et al. 2012; Reeves et al. 2015; Smith et al. 2016), yet the diversity of host taxa sampled remains limited. For example, molecular techniques have not been used to assess hematozoa infection in sea ducks (family: Anatidae; tribe: Mergini).

Spectacled Eiders (*Somateria fischeri*) are sea ducks inhabiting arctic and subarctic regions of eastern Siberia and Alaska and are listed as “threatened” under the Endangered Species Act by the US Fish and Wildlife Service. In Alaska, breeding populations inhabit the Yukon-Kuskokwim Delta (YKD) and Arctic Coastal Plain (ACP) on the western and northern coasts, respectively. Spectacled Eiders nest within wetlands adjacent to the Bering, Chukchi, Beaufort, and East Siberian seas and spend non-breeding seasons offshore

in the Arctic Ocean and Bering Sea (Petersen et al. 2000). Consequently, exposure of Spectacled Eiders to hematozoa via biting insects is presumably restricted to breeding areas.

We screened blood samples from Spectacled Eiders collected as part of a larger ecological study, to assess the prevalence and diversity of hematozoa infecting this species. Our objectives were to 1) estimate hematozoa prevalence in adult and juvenile Spectacled Eiders, 2) assess transmission on the ACP, and 3) characterize the genetic and morphologic diversity of parasites infecting Spectacled Eiders relative to other avian hosts. Our results provide a baseline for future assessments of health effects from parasite infections on Spectacled Eiders and changes in parasite prevalence in subarctic and arctic habitats.

We captured adult Spectacled Eiders on the YKD ( $n=46$ ) and ACP ( $n=77$ ) in May–June 2008 and June–August 2009–12, respectively, using methods described in Sexson et al. (2016). Additionally, we captured flightless ducklings ( $n=62$ ) 5 wk after peak hatch on the ACP in 2010–11. Jugular blood samples (1–2 mL) were collected from each individual and preserved in either 2-mL vials with 0.75 mL Longmire Buffer, or BD Vacutainer EDTA tubes (Franklin Lakes, New Jersey, USA). We made thin blood smears on glass slides from 110 ACP samples. We conducted all capture and field sampling protocols under authorizations granted by the US Geological Survey’s Animal Care and Use Committee (2008-04) and the US Fish and Wildlife Service (TE012158-0). Molecular methods for detecting and genetically characterizing hematozoa followed Ramey et al. (2013). Sparse age- and

TABLE 1. Number and percentage of Spectacled Eider (*Somateria fischeri*) blood samples from the Yukon-Kuskokwim Delta (YKD) and Arctic Coastal Plain (ACP), Alaska, USA, detected as positive for *Leucocytozoon* infection using molecular techniques by location in Alaska, year, age, and sex.<sup>a</sup>

Location	Year	Age	Sex	Leucocytozoon			Haplotypes detected
				Total <i>n</i>	Positive <i>n</i>	%	
YKD	2008	Ad	F	31	3	10	SPEI 02, SPEI 03, SPEI 05
			M	15	2	13	SPEI 03
ACP	2009	Ad	F	7	0	0	
			M	13	2	15	SPEI 02, SPEI 08
	2010	Ad	F	21	1	5	SPEI 06
			M	3	0	0	
		Juv	F	5	2	40	SPEI 06, SPEI 07
	2011	Ad	M	14	11	79	SPEI 01, SPEI 06, SPEI 07, SPEI 08
			F	24	0	0	
		Juv	F	22	8	36	SPEI 04, SPEI 07, SPEI 08
			M	21	5	24	SPEI 07, SPEI 08, SPEI 09
	2012	Ad	F	9	0	0	

<sup>a</sup> Ad = adult; Juv = juvenile; M = male; F = female.

sex-specific data, along with low infection rates, precluded incorporation of occupancy model estimates of detection probability and of potential false negatives in prevalence estimates. Blood smears were stained with Giemsa and examined at 400–1,000× magnification to identify the morphospecies of hematozoa in samples that tested positive for infection via molecular screening. All data related to this study are archived in Reed (2018).

Using molecular methods, we detected *Leucocytozoon* infections in 18.4% of samples (34/185; Table 1). Morphologic assessment of blood smears identified *Leucocytozoon simondi* as the parasite present in ACP samples (Fig. 1a; voucher specimens archived at the Smithsonian Institution, Museum of Natural History, USNM1486967–USNM1486972). *Leucocytozoon* prevalence in juveniles (41.9%; 26/62) was higher than in adults (6.5%; 8/123; Table 1), possibly because of downy ducklings having less physical protection from biting insects than fully feathered birds. Detection of *Leucocytozoon* infections in juvenile eiders provides evidence of transmission within the ACP, corroborating previous reports of *Leucocytozoon* transmission among geese in this region (Ramey et al. 2014).

We did not detect *Haemoproteus* or *Plasmodium* infections in Spectacled Eiders at either the YKD or ACP. Previous studies reported low prevalence of *Plasmodium* infections (4%) in Northern Pintails (*Anas acuta*) sampled farther inland on the YKD and *Haemoproteus* parasites in a variety of waterfowl species sampled at interior (14%) and coastal areas (1–3%) of the YKD and ACP (Ramey et al. 2012, 2014, 2015). Spectacled Eiders may be infected with *Haemoproteus* and *Plasmodium* at prevalences below the detection threshold of our methodology; alternatively, parasite development may be restricted by the relatively low temperatures along the narrow band of coastal habitat occupied by eiders sampled in this study. *Haemoproteus* and *Plasmodium* parasites previously detected in other waterfowl at the YKD and ACP may have been acquired in areas farther from the coast or other regions during non-breeding season.

We identified nine *Leucocytozoon* haplotypes (GenBank MG734969–MG734977) with nucleotide identity differing by 0.25–9.3% (1–37/400 base pairs; Fig. 1b). These nine haplotypes shared 100% identity with those previously detected in 16 avian species (predominately waterfowl) sampled at loca-

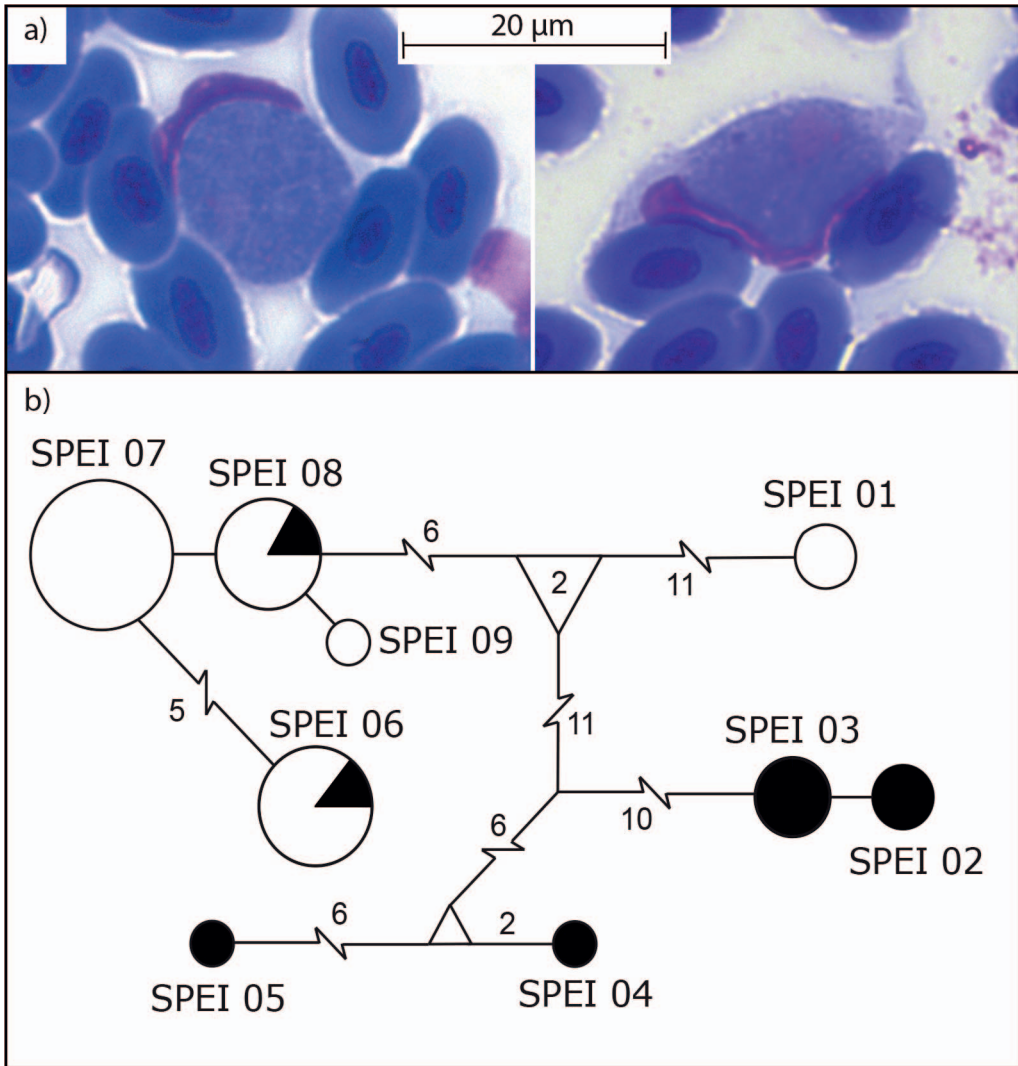


FIGURE 1. (a) *Leucocytozoon simondi* gametocytes in blood smears from Spectacled Eiders (*Somateria fischeri*) on the Arctic Coastal Plain of Alaska, USA (2010–11). (b) Minimum spanning network for *Leucocytozoon* mitochondrial DNA cytochrome *b* haplotypes identified by molecular techniques in blood sampled from Spectacled Eiders in Alaska (2008–12). Circle sizes are proportional to haplotype frequency. Host age class is represented by color (black: adult, white: juvenile). A single mutation separates nodes unless indicated by number. Lines separating nodes are drawn to scale unless indicated by a break.

tions in Alaska, elsewhere in North America, and in East Asia (see the Supplementary Table). These results are consistent with prior research, suggesting broad spatial distributions and genetic diversity for *Leucocytozoon* lineages infecting waterfowl (Reeves et al. 2015). Two *Leucocytozoon* haplotypes were identified in both juvenile and adult Spectacled Eiders (Fig. 1b), including one adult

female and her brood, indicating that parasites may be transmitted within and among family groups on the ACP during brood rearing. However, we observed most parasite haplotypes exclusively in either adult or juvenile birds (Fig. 1b). This suggests more complex spatiotemporal dynamics or the involvement of additional host species in *Leucocytozoon* transmission. Additional re-

search into transmission dynamics on the YKD and ACP, health consequences of hematozoa infections in Spectacled Eiders, and changes in parasite prevalence and distribution over time, would be helpful for refining the ecological context of our results.

We appreciate reviews of previous versions of this manuscript by J. Pearce, B. Meixell, and three anonymous reviewers. This work was funded by the US Geological Survey through the Wildlife Program of the Ecosystem Mission Area. Any use of trade, firm, or product names is for descriptive purposes only and does not imply endorsement by the US Government.

### SUPPLEMENTARY MATERIAL

Supplementary material for this article is online at <http://dx.doi.org/10.7589/2018-01-012>.

### LITERATURE CITED

- Garamszegi LZ. 2011. Climate change increases the risk of malaria in birds. *Glob Change Biol* 17:1751–1759.
- Herman CM, Barrow JH Jr, Tarshis IB. 1975. Leucocytozoonosis in Canada Geese at the Seney National Wildlife Refuge. *J Wildl Dis* 11:404–411.
- Hill AG, Howe L, Gartrell BD, Alley MR. 2010. Prevalence of *Leucocytozoon* spp. in the endangered yellow-eyed penguin *Megadyptes antipodes*. *Parasitology* 137:1477–1485.
- Loiseau C, Harrigan RJ, Cornel AJ, Guers SL, Dodge M, Marzec T, Carlson JS, Seppi B, Sehgal RNM. 2012. First evidence and predictions of *Plasmodium* transmission in Alaskan bird populations. *PLoS One* 7:0044729.
- Petersen MR, Grand JB, Dau CP. 2000. Spectacled Eider (*Somateria fischeri*). In: *The birds of North America*, Rodewald PG, editor. Cornell Lab of Ornithology, Ithaca, New York, pp. 2–45.
- Ramey AM, Ely CR, Schmutz JA, Pearce JM, Heard DJ. 2012. Molecular detection of hematozoa infections in tundra swans relative to migration patterns and ecological conditions at breeding grounds. *PLoS One* 7:e45789.
- Ramey AM, Fleskes JP, Schmutz JA, Yabsley MJ. 2013. Evaluation of blood and muscle tissues for molecular detection and characterization of hematozoa infections in northern pintails (*Anas acuta*) wintering in California. *Int J Parasitol* 2:102–109.
- Ramey AM, Reed JA, Schmutz JA, Fondell TF, Meixell BW, Hupp JW, Ward DH, Terenzi J, Ely CR. 2014. Prevalence, transmission, and genetic diversity of blood parasites infecting tundra-nesting geese in Alaska. *Can J Zool* 92:699–706.
- Ramey AM, Schmutz JA, Reed JA, Fujita G, Scotton BD, Casler B, Fleskes JP, Konishi K, Uchida K, Yabsley MJ. 2015. Evidence for intercontinental parasite exchange through molecular detection and characterization of haematozoa in northern pintails (*Anas acuta*) sampled throughout the North Pacific Basin. *Int J Parasitol* 4:11–21.
- Reed JA. 2018. Blood parasite infection data from Spectacled Eiders (*Somateria fischeri*), Alaska (USA), 2008–2012. *US Geological Survey data release*. US Geological Survey, Anchorage, Alaska. <https://doi.org/10.5066/P9CDBRDC>.
- Reeves AB, Smith MM, Meixell BW, Fleskes JP, Ramey AM. 2015. Genetic diversity and host specificity varies across three genera of blood parasites in ducks of the Pacific Americas Flyway. *PLoS One* 10: e0116661.
- Sexson MG, Petersen MR, Breed GA, Powell AN. 2016. Shifts in the distribution of molting Spectacled Eiders (*Somateria fischeri*) indicate ecosystem change in the Arctic. *Condor* 118:463–476.
- Smith MM, Van Hemert C, Merizon R. 2016. Haemosporidian parasite infections in grouse and ptarmigan: Prevalence and genetic diversity of blood parasites in resident Alaskan birds. *Int J Parasitol* 5:229–239.
- van Riper C, van Riper SG, Goff ML, Laird M. 1986. The epizootiology and ecological significance of malaria in Hawaiian land birds. *Ecol Monogr* 56:327–344.
- Zamora-Vilchis I, Williams SE, Johnson CN. 2012. Environmental temperature affects prevalence of blood parasites of birds on an elevation gradient: Implications for disease in a warming climate. *PLoS One* 7:e39208.

Submitted for publication 19 January 2018.

Accepted 17 April 2018.