

## **Causes of Mortality in a Population of Marine-Foraging River Otters (*Lontra canadensis*)**

Authors: Gaydos, Joseph K., Delaney, Martha A., and Raverty, Stephen

Source: Journal of Wildlife Diseases, 56(4) : 941-946

Published By: Wildlife Disease Association

URL: <https://doi.org/10.7589/JWD-D-20-00031>

---

BioOne Complete ([complete.BioOne.org](https://complete.BioOne.org)) is a full-text database of 200 subscribed and open-access titles in the biological, ecological, and environmental sciences published by nonprofit societies, associations, museums, institutions, and presses.

Your use of this PDF, the BioOne Complete website, and all posted and associated content indicates your acceptance of BioOne's Terms of Use, available at [www.bioone.org/terms-of-use](https://www.bioone.org/terms-of-use).

Usage of BioOne Complete content is strictly limited to personal, educational, and non - commercial use. Commercial inquiries or rights and permissions requests should be directed to the individual publisher as copyright holder.

---

BioOne sees sustainable scholarly publishing as an inherently collaborative enterprise connecting authors, nonprofit publishers, academic institutions, research libraries, and research funders in the common goal of maximizing access to critical research.

## Causes of Mortality in a Population of Marine-foraging River Otters (*Lontra canadensis*)

Joseph K. Gaydos,<sup>1,4</sup> Martha A. Delaney,<sup>2</sup> and Stephen Raverty<sup>3</sup> <sup>1</sup>The SeaDoc Society, University of California at Davis Karen C. Drayer Wildlife Health Center—Orcas Island Office, 942 Deer Harbor Rd., Eastsound, Washington 98245, USA; <sup>2</sup>Zoological Pathology Program, University of Illinois, 3300 Golf Rd., Brookfield, Illinois 60513, USA; <sup>3</sup>Animal Health Center, 1767 Angus Campbell Rd., Abbotsford, British Columbia V3G 2M3, Canada; <sup>4</sup> Corresponding author (email: jkgaydos@ucdavis.edu)

**ABSTRACT:** Retrospective analysis of diagnostic findings from 30 marine-foraging river otter (*Lontra canadensis*) carcasses opportunistically acquired between 2003 and 2013 revealed trauma as the most common cause of mortality (47%). Within this focal population, causes of trauma included vehicular, gunshot, and one case of suspect intraspecific aggression. Other causes of death included idiopathic (20%), infectious (13%), metabolic (10%), nutritional (7%), and neoplasia (3%). One case of neoplasia, a pancreatic islet cell adenoma, was identified in a 12-yr-old female. In six animals, diffuse renal interstitial fibrosis and multifocal glomerulosclerosis of unknown clinical significance were noted.

**Key words:** Coastal, *Lontra canadensis*, marine, mortality, neoplasia, renal disease, river otter, trauma.

North American river otters (*Lontra canadensis*) inhabit inland freshwater environments throughout much of North America. In the US, from Alaska (Bowyer et al. 2003) to California (Bouley et al. 2015), they also occur in coastal marine waters where they forage on a variety of marine fish and invertebrates (Buzzell et al. 2014) and play an important role in the transfer of marine-derived nitrogen to the terrestrial ecosystem (Ben-David et al. 1998). Little is known about diseases and mortality factors in marine-foraging river otters. Gaydos et al. (2007a) identified antibodies to *Toxoplasma gondii* and *Leptospira interrogans* in trapped otters that appeared healthy, and isolated *Cryptosporidium* and *Giardia* spp. from feces of otters of unknown health status (Gaydos et al. 2007b). Bouley et al. (2015) isolated four different *Vibrio* spp. from fecal samples from animals of unknown health status. Also, they investigated 15 mortalities, identifying 11 road-killed animals and two young that appeared to have been

abandoned. Mercury (Ben-David et al. 2001), organochlorine pesticides (Elliott et al. 2008; Guertin et al. 2010), polychlorinated biphenyls (Elliott et al. 2008; Guertin et al. 2010), polychlorinated dioxins (Elliott et al. 2008), polybrominated diphenyl ethers (Elliott et al. 2008; Guertin et al. 2010; Nelson et al. 2015), and polychlorinated furans (Elliott et al. 2008) have been detected in marine-foraging river otters, with polychlorinated biphenyls identified in some geographic locations at levels potentially harmful to the reproductive capacity or health of individual animals (Elliott et al. 2008; Guertin et al. 2010).

We reviewed necropsy data for marine-foraging river otters that were collected in San Juan County, Washington, US (48°35'N, 122°53'W) or nearby shorelines between 2003 and 2013. Carcasses collected by marine mammal stranding networks or presented to wildlife rehabilitation centers that were in good postmortem condition were examined at Friday Harbor Laboratories (Friday Harbor, Washington, USA), and a full suite of tissues was collected, routinely processed, embedded in paraffin, sectioned, and examined microscopically. Because necropsies focused on determining the cause of morbidity or mortality, diagnostic procedures for ancillary testing varied. Age was classified into four groups (<1 yr old; 1–4 yr old, 4–8 yr old, and >8 yr old) based on subjective examination of dental wear (Baitchman and Kollias 2000). A subset of eight animals suspected of being older than 1 yr was aged by microscopic cementum annuli analysis of an upper canine (Matson et al. 1993). This analysis superseded subjective examination in three cases where results differed: two animals subjectively identified as being 1–4 yr-old were identified

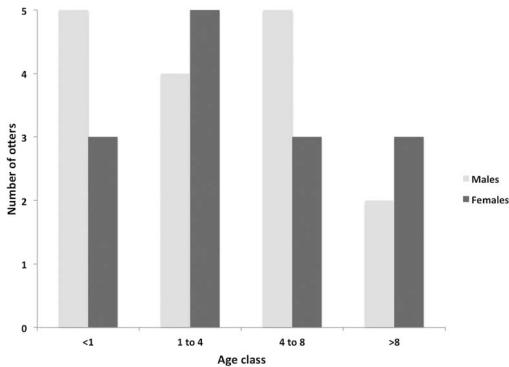


FIGURE 1. Sex and age class of river otters (*Lontra canadensis*) collected in San Juan County, Washington, USA or nearby shorelines between 2003 and 2013 and examined to determine cause of death.

as <1 yr old and 5 yr old, and another animal believed to be between 4 and 8 yr old was identified as being 11 yr old. Major diagnostic findings were categorized to primary cause of death and assigned to a diagnostic category. We included the following categories for cause of death: degenerative, developmental, anomalous, metabolic, neoplastic, nutritional, idiopathic, infectious, toxic, traumatic, and vascular. The chi-square test of independence was used to evaluate the distribution of cases by sex or age category and to compare the predicted-to-actual number of males and females dying from trauma ( $\alpha=0.05$ ).

Between 2003 and 2013, 30 marine-foraging river otters were examined, with a mean (SD) of 2.5 (1.2) animals examined per year. Most animals were found in spring (April–June;  $n=12$ ) or summer (July–September;  $n=11$ ), with fewer detected in fall (October–December;  $n=3$ ) and winter (January–March;  $n=4$ ). This could reflect seasonal mortality patterns or a collection bias because fewer people are resident and outside during fall and winter in San Juan County. Male and female cases were almost evenly split ( $n=16$  and 14, respectively), and all age classes were well-represented with similar numbers of males and females ( $\chi^2=0.623$ ,  $P=0.891$ ). The fewest animals belonged to the >8-yr-old age class (Fig. 1), and the oldest animal examined was a 13-yr-old male.

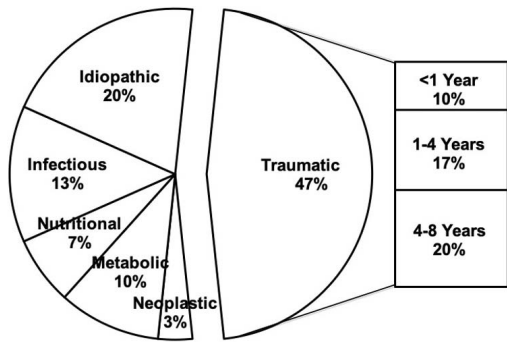


FIGURE 2. Categories for causes of mortality for 30 river otters (*Lontra canadensis*) collected in San Juan County, Washington, USA or nearby shorelines between 2003 and 2013 and examined. The pull-out details the age class breakdown of traumatic cases.

We identified six major categories of primary cause of mortality (Fig. 2); traumatic (47%), idiopathic (20%), infectious (13%), metabolic (10%), nutritional (7%), and neoplastic (3%). Of the 14 animals that died from trauma, nine were male and five were female, which suggests a male bias; however, there was no detectable difference between the actual and predicted numbers of males and females examined ( $\chi^2=0.026$ ,  $P=0.871$ ). An etiology was determined for eight of the trauma cases, including four hit by car (vehicular), three gunshot, and one case of suspect intra- or interspecific aggression that had multiple bite wounds to the face and head. Traumatic mortalities occurred in all seasons and in nine of the 12 mo of the year with no apparent seasonal patterns.

The four otters with infectious causes of death all had histologic signs of infection consistent with the infectious agent identified. These included a case of multisystemic lymphoid necrosis, necrosuppurative hepatitis, and splenitis with an undetermined etiology. There was also a case of presumed septicemia in a 193 g, <1-yr-old female pup with interstitial pneumonia and suppurative cholangiohepatitis where *Enterobacter cloacae* and *Klebsiella* sp. were isolated from multiple organs. A >8-yr-old female presented in winter with a tooth root abscess, granulomatous pneumonia, and endometritis that yielded light mixed growth of *Escherichia coli*.

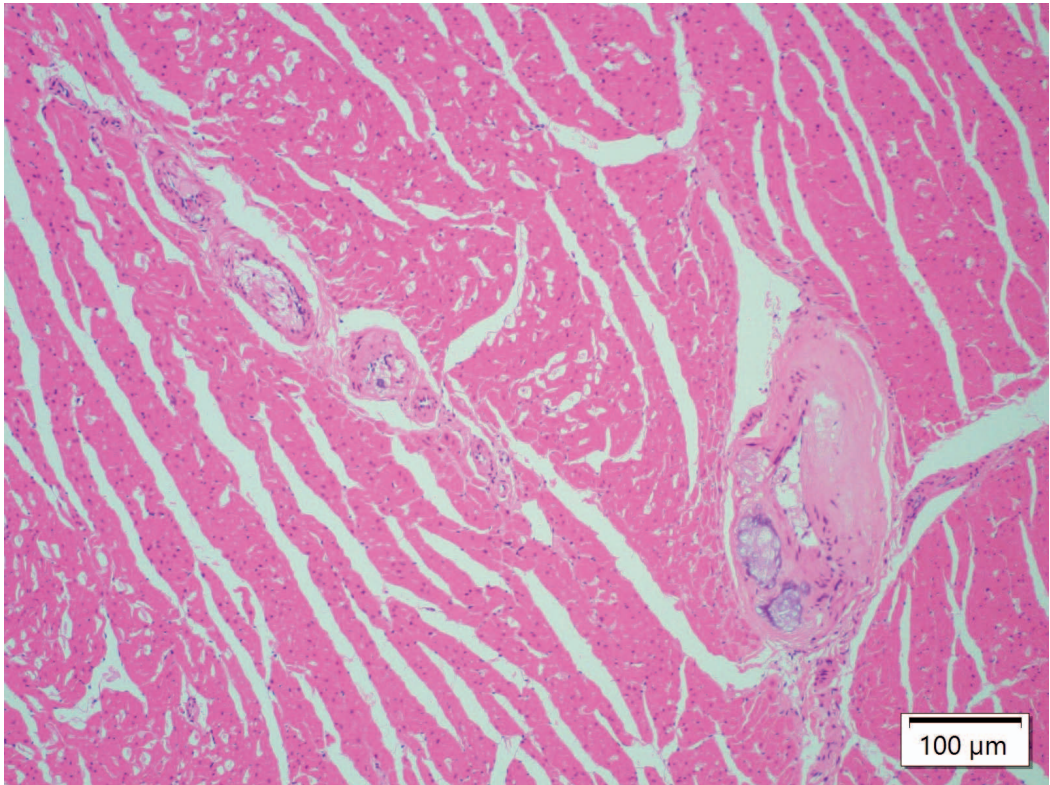


FIGURE 3. Photomicrograph of the heart of a 12-yr-old female river otter (*Lontra canadensis*) in San Juan County, Washington, USA showing substantial vascular lesions consistent with arterio- and atherosclerosis. Medium caliber intramyocardial coronary arteries have segmental to circumferential subintimal and mural accumulations of faintly basophilic amorphous material (mineral) with rare enmeshed and peripheral foamy macrophages, and few cholesterol clefts. H&E. 10X.

Finally, a 705 g, <1-yr-old pup was diagnosed with interstitial pneumonia and pulmonary edema. Aerobic bacterial culture of multiple tissues yielded light growth of *E. coli* (nonhemolytic) from the pup's spleen and lung.

Metabolic cases included two <1-yr-old animals with presumed maternal-neonatal separation and one 1- to 4-yr-old female with nephrolithiasis and hydronephrosis. Related renal lesions included tubular proteinosis, degeneration, and necrosis. The chemical composition of stones was not evaluated; however, nephrolithiasis with similar pathologic findings were previously reported in a river otter from the Skagit River in Washington state (Grove et al. 2003) with stones identified as 97% uric acid and 3% protein. In our case, the pathogenesis of stone formation is not known; however, it is possible that the

grossly noted emaciation (protein catabolism) might have exacerbated urolith formation. The two nutritional cases were emaciated animals with undetermined underlying etiologies.

The only case of neoplasia detected was a 12-yr-old female otter that had a pancreatic islet cell adenoma. This 3-mm-diameter, well-demarcated, partially encapsulated, expansile, nodular mass was composed of neoplastic epithelial cells arranged in variably sized nests, cords, and fewer pseudoacini and trabeculae supported by a moderate fibrovascular stroma. Neoplastic cells were small and cuboidal with round to oval hyperchromatic nuclei, contained small amounts of eosinophilic granular cytoplasm, and had well-defined borders. Anisokaryosis and anisocytosis were minimal and mitoses rare. Amongst



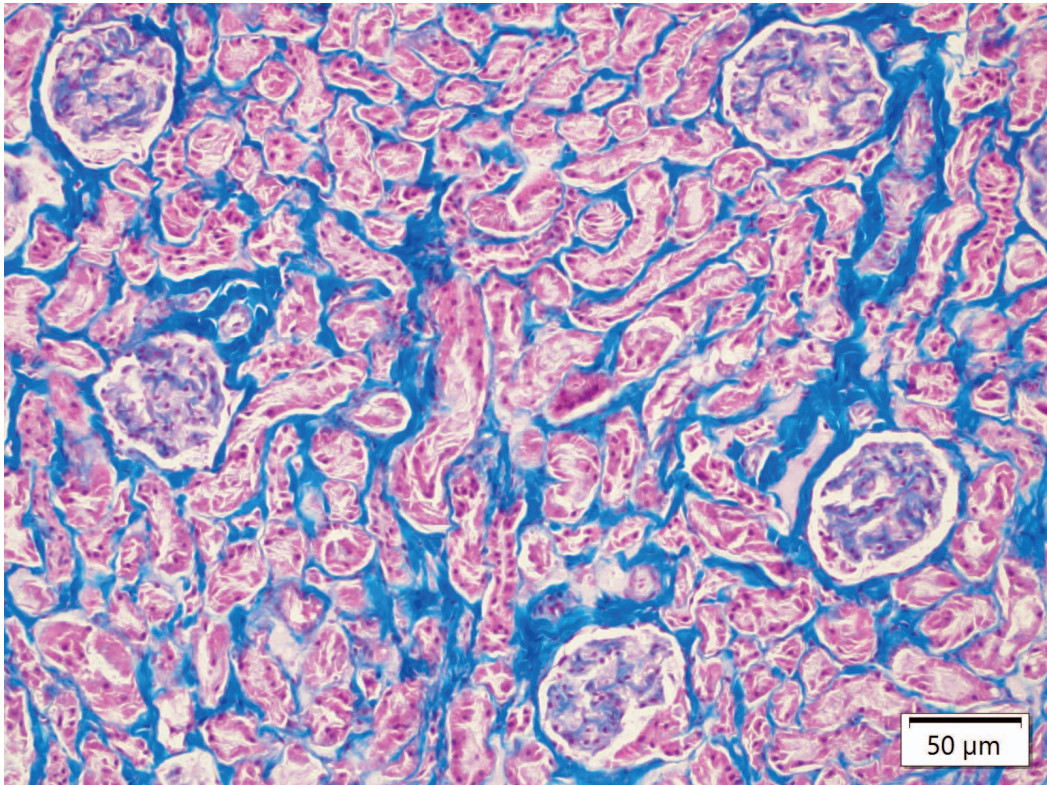


FIGURE 4. Photomicrograph of the kidney of a >8-yr-old female river otter (*Lontra canadensis*) in San Juan County, Washington, USA with interstitial fibrosis and segmental glomerulopathy. Renal tubules and glomeruli are separated and isolated by moderately increased interstitial collagenous tissue (blue) consistent with fibrosis. Multifocally, glomerular tufts have segmental hypocellularity and increases in mesangial matrix. Masson's trichrome. 20 $\times$ .

the stroma and separating the structures were accumulations of faintly eosinophilic, homogeneous, glassy material presumed to be amyloid deposition, although Congo Red staining was nonconfirmatory. Immunohistochemical staining could not confirm the cell of origin of the pancreatic islet cell adenoma, because the neoplastic cells did not stain with anti-insulin, antigastrin, or antiglucagon antibodies. Immunostaining was interpreted in the context of appropriate staining in normal pancreas, which served as an internal control. Due to the presence of concurrent gastric ulceration and hemorrhage in the absence of an inciting cause, hypergastrinemia and resulting secretion of excessive gastric acid were suspected. Given the lack of immunoreactivity of the islet adenoma with antigastrin antibodies, an additional undetected gastrin-secreting

duodenal mass was considered plausible. Previous reports of neoplasia in North American river otters include a malignant pheochromocytoma in a 21-yr-old captive animal (Schlanser et al. 2012) and a primary pleural squamous cell carcinoma in a free-ranging adult female (van de Velde et al. 2019). Although it was not associated with cause of mortality, the 12-yr-old female with a pancreatic islet cell adenoma had substantial vascular lesions consistent with arterio- and atherosclerosis (Fig. 3). Myocardial lesions such as degeneration, necrosis, and fibrosis were not appreciated, and there was no evidence of significant cardiac disease or insufficiency. We suspect this was associated with the advanced age of this animal.

In six animals, a diffuse renal interstitial fibrosis, mild to moderate multifocal segmen-

tal glomerulosclerosis, and multifocal tubular mineralization were noted (Fig. 4). The lesions were not associated with mortality, but severity seemed age-associated, with more severe lesions seen in older age classes. Lesions were not seen in any animals <1 yr old, were mild in the two 1- to 4-yr-old otters, and moderate to marked in the two 4- to 8-yr-old and the two >8-yr-old animals.

Although parasites were not observed during necropsies, microscopically, 12 cases (all 1- to 4-yr-olds or older) had rare intracytoplasmic protozoa morphologically compatible with *Sarcocystis* spp. in the diaphragm, esophagus, heart, tongue, or retrobulbar skeletal muscle. All sarcocysts were considered clinically insignificant. Enteric (small intestinal) coccidiosis was identified in one 1- to 4-yr-old male that had moderate eosinophilic enteritis with villous blunting. A 4- to 8-yr-old female had incidental multifocal intrabronchial metazoan parasites suspected to be *Paragonimus kellicotti*.

Carcasses examined in this case series were not obtained in a manner that permitted assigning relative importance of causes of mortality; however, trauma appears to be a major mortality factor. Although some local municipalities have begun to address vehicular trauma by placing caution signs at sites where accidents occur regularly, more work will be needed to minimize illegal shooting of otters, presumably done by disgruntled boat, dock, or home owners displeased with otters defecating on their property. Collecting mortality data on animals such as marine-foraging river otters that occur in relatively low density is a slow process, and more long-term studies are needed to better understand diseases of importance in this species.

This work was supported by private donations to the SeaDoc Society, a program of the Karen C. Drayer Wildlife Health Center at the University of California at Davis School of Veterinary Medicine. We thank the volunteers of The Whale Museum's San Juan County Marine Mammal Stranding Network and the staff at Wolf Hollow Wildlife Rehabilitation Center for providing carcasses. Carcasses were collected under Washington Depart-

ment of Fish and Wildlife Scientific Collection Permits for research. Thanks to Brian Johnson and staff at University of Washington Histology Imaging Core for histology and immunohistochemistry services.

#### LITERATURE CITED

- Baitchman EJ, Kollias GV. 2000. Clinical anatomy of the North American river otter (*Lontra canadensis*). *J Zoo Wildl Med* 31:473-483.
- Ben-David M, Bowyer RT, Duffy LK, Roby DD, Schell DM. 1998. Social behavior and ecosystem processes: River otter latrines and nutrient dynamics of terrestrial vegetation. *Ecology* 79:2567-2571.
- Ben-David M, Duffy LK, Blundell GM, Bowyer RT. 2001. Natural exposure of coastal river otters to mercury: Relation to age, diet, and survival. *Environ Toxicol Chem* 20:1986-1992.
- Bouley P, Isadore M, Carroll T. 2015. Return of North American river otters, *Lontra canadensis*, to coastal habitats of the San Francisco Bay Area, California. *Northwest Nat* 96:1-12.
- Bowyer RT, Blundell GM, Ben-David M, Jewett SC, Dean TA, Duffy LK. 2003. Effects of the Exxon Valdez oil spill on river otters: Injury and recovery of a sentinel species. *Wildl Monogr* 153:1-53.
- Buzzell B, Lance MM, Acevedo-Gutierrez A. 2014. Spatial and temporal variation in river otter (*Lontra canadensis*) diet and predation on rockfish (genus *Sebastes*) in the San Juan Islands, Washington. *Aquat Mamm* 40:150-161.
- Elliott JE, Guertin DA, Balke JME. 2008. Chlorinated hydrocarbon contaminants in feces of river otters from the southern Pacific coast of Canada, 1998-2004. *Sci Total Environ* 397:58-71.
- Gaydos JK, Conrad PA, Gilardi KV, Blundell GM, Ben-David M. 2007a. Does human proximity affect antibody prevalence in marine-foraging river otters? *J Wildl Dis* 43:116-123.
- Gaydos JK, Miller WA, Gilardi KVK, Melli A, Schwantje H, Englelstoft C, Fritz H, Conrad PA. 2007b. *Cryptosporidium* and *Giardia* in marine-foraging river otters (*Lontra canadensis*) from the Puget Sound Georgia Basin Ecosystem. *J Parasitol* 93:198-202.
- Grove RA, Bildfell R, Henny CJ, Buhler DR. 2003. Bilateral uric acid nephrolithiasis and ureteral hypertrophy in a free-ranging river otter (*Lontra canadensis*). *J Wildl Dis* 39:914-917.
- Guertin DA, Harestad AS, Ben-David M, Drouillard KG, Elliott JE. 2010. Fecal genotyping and contaminant analyses reveals individual variation in individual river otter exposure to localized persistent contaminants. *Environ Toxicol Chem* 29:275-284.
- Matson GM, Van Daele L, Goodwin E, Aumiller L, Reynolds H, Hristienko H. 1993. *A laboratory manual for cementum age determination of Alaska brown bear*

- PM1 teeth*. Alaska Department of Fish and Game and Matson's Laboratory, Milltown, Montana, 52 pp.
- Nelson C, Drouillard K, Cheng K, Elliott J, Ismail N. 2015. Accumulation of PBDEs in an urban river otter population and an unusual finding of BDE-209. *Chemosphere* 118:322–328.
- Schlanser, JR, Patterson JS, Kiupel M, Hencken C, Sikarskie JG, Harrison TM. 2012. Disseminated pheochromocytoma in a North American river otter (*Lontra canadensis*). *J Zoo Wildl Med* 43: 407–411.
- van de Velde N, Demetrick DJ, Duignan PJ. 2019. Primary pleural squamous cell carcinoma in a free-ranging river otter (*Lontra canadensis*). *J Wildl Dis* 55:728–732.

*Submitted for publication 21 February 2020.*

*Accepted 8 June 2020.*