

## **Management of a complete uterine prolapse in a cat**

Authors: Deroy, Claire, Bismuth, Camille, and Carozzo, Claude

Source: Journal of Feline Medicine and Surgery Open Reports, 1(1)

Published By: SAGE Publishing

URL: <https://doi.org/10.1177/2055116915579681>

---

BioOne Complete ([complete.BioOne.org](https://complete.bioone.org)) is a full-text database of 200 subscribed and open-access titles in the biological, ecological, and environmental sciences published by nonprofit societies, associations, museums, institutions, and presses.

Your use of this PDF, the BioOne Complete website, and all posted and associated content indicates your acceptance of BioOne's Terms of Use, available at [www.bioone.org/terms-of-use](https://www.bioone.org/terms-of-use).

Usage of BioOne Complete content is strictly limited to personal, educational, and non - commercial use. Commercial inquiries or rights and permissions requests should be directed to the individual publisher as copyright holder.

---

BioOne sees sustainable scholarly publishing as an inherently collaborative enterprise connecting authors, nonprofit publishers, academic institutions, research libraries, and research funders in the common goal of maximizing access to critical research.



## Management of a complete uterine prolapse in a cat

*Journal of Feline Medicine and Surgery*  
*Open Reports*  
 1–4

© The Author(s) 2015

Reprints and permissions:

sagepub.co.uk/journalsPermissions.nav

DOI: 10.1177/2055116915579681

jfmsopenreports.com



**Claire Deroy, Camille Bismuth and Claude Carozzo**

### Abstract

A young female cat was presented with a protrusion of the uterus through the vulvar lips. The cat had a history of recent parturition, with delivery without incident of three kittens 48 h earlier. No fetus was found in the uterus. The protruding uterus was amputated and a staged ovariohysterectomy was performed. The day after surgery, the queen was healthy with no evidence of vulvar discharge. Two months later, the owner reported that the queen was clinically normal with no recurrence of clinical signs.

**Accepted:** 22 July 2014

Uterine prolapse is a relatively uncommon complication of parturition, occurring infrequently in cats and rarely in dogs.<sup>1–5</sup> It occurs immediately or up to 48 h after delivery of the last neonate,<sup>6,7</sup> and, to facilitate management before accumulation of excessive oedema, contamination and mucosal trauma, should be regarded as an emergency condition. Uterine prolapse is essentially an eversion of the organ, which turns inside out as it passes through the cervix into the vagina. The prolapse can be complete, with both horns protruding from the vulva, or limited to the uterine body and one horn.

A 3-year-old female European Shorthair cat weighing 3.2 kg was presented to our emergency unit with a 24 h history of uterine prolapse. The queen had borne a litter of three kittens, which were all alive and of normal size, 48 h before the consultation without incident.

On physical examination, the animal was depressed, hypothermic at 37.3°C and slightly dehydrated. The pulse and respiratory rate were both within normal ranges. The prolapse was complete, with both horns protruding from the vulva (Figure 1). The exposed tissue was congested and oedematous with areas of necrosis, and was covered with debris. Serum biochemical analysis was performed (Table 1) and showed hyperglycaemia and hyperlactataemia. Other parameters of the biochemical analysis and packed cell volume were all normal in range.

Lactated Ringer's solution was administered through a 22 G cephalic catheter at a rate of 10 ml/kg/h. After premedication with 0.2 mg/kg intravenous morphine, anaesthesia

was induced with 0.2 mg/kg of midazolam and 2 mg/kg of alfaxalone (Alfaxan; Vetoquinol). An endotracheal tube was inserted and anaesthesia was maintained with isoflurane and oxygen at 100%. At induction, 20 mg/kg amoxicillin clavulanic acid (Augmentin; GlaxoSmithKline) was administered intravenously at the beginning and again at the end of the surgery. The queen was positioned in dorsal recumbency. The ventral abdomen, perineal zone and tail were clipped. A purse string suture was performed on the anus during the surgery. Gross debris was removed from the prolapsed organ by irrigation with warm saline water. A bandage was placed around the tail and the cat was prepared for aseptic surgery (Figure 1).

The surgery was performed in two steps: first the ovariectomy and then the amputation of the uterus.

A midline laparotomy was made to permit routine ovariectomy. Because of the traction on the ovaries, they were not in their physiological position but in the dorso-caudal portion of the abdomen (Figure 2). There was no rupture of the ovarian pedicle but the suspensory ligament with its ovarian artery and vein was elongated on both sides. The urethral tubercle was visualised before starting the amputation. The prolapse was opened close to the vulva

CHEVAC, Small Animal Department, VetAgro Sup, Veterinary Campus of Lyon, University of Lyon, Marcy l'Etoile, France

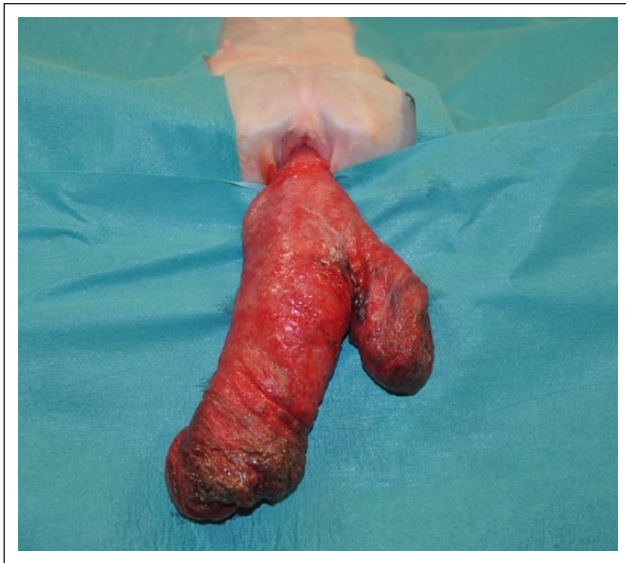### Corresponding author:

Claire Deroy, DVM, Surgical Department, Veterinary Hospital Frégis, Arcueil, France

Email: deroy.claire@hotmail.fr



Creative Commons CC-BY-NC: This article is distributed under the terms of the Creative Commons Attribution-NonCommercial 3.0 License (<http://www.creativecommons.org/licenses/by-nc/3.0/>) which permits non-commercial use, reproduction and distribution of the work without further permission provided the original work is attributed as specified on the SAGE and Open Access page (<http://www.uk.sagepub.com/aboutus/openaccess.htm>).

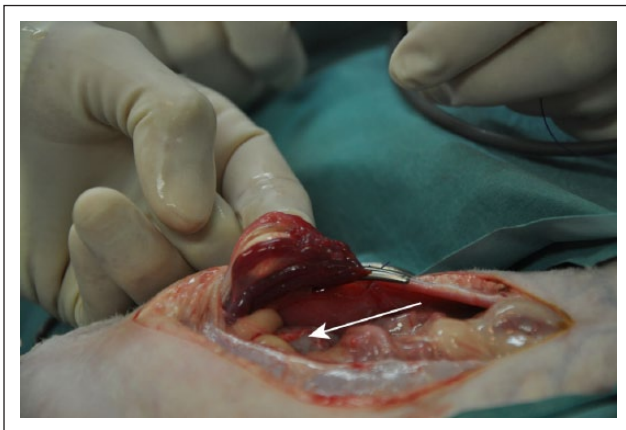


**Figure 1** Prolapsed uterus after removal of debris and aseptic preparation before amputation. Note the oedema, congestion and areas of necrosis

**Table 1** Serum biochemical analysis

Parameter	Value	Reference interval
Glucose (mmol/l)	10.72	3–8
Urea (mmol/l)	16.9	4–11
Creatinine ( $\mu\text{mol/l}$ )	56	50–180
Total protein (g/l)	68	54–79
ALT (U/l)	12	16–60
ALP (U/l)	20	1–100
Lactate (mmol/l)	2.64	0–2

ALT = Alanine aminotransferase; ALP = Alkaline phosphatase



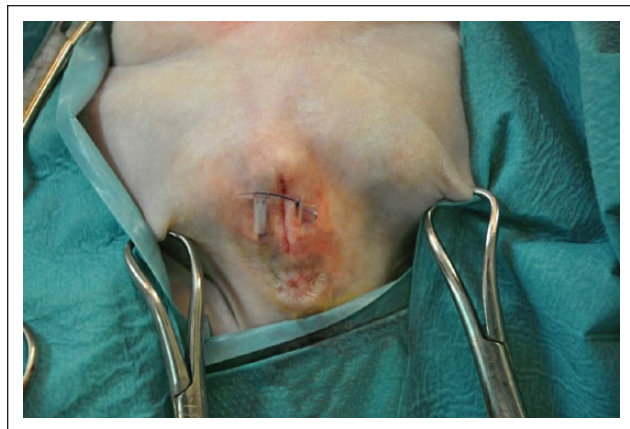**Figure 2** Abdominal step: ovariectomy. Ligation of the ovarian pedicle visualised by the mosquito clamp. Note the abnormal position of the ovary: the ovary is in a caudal position in the abdomen at the level of the urinary bladder (arrow)

just caudal to the urethral meatus to expose the uterine vessels. The uterine arteries were ligated. The uterus was then excised on the uterine body. The stump of the uterus was closed with a simple continuous pattern suture. The horns and attached tissues were removed distal to the suture. The remaining stump was reduced into the abdomen via the pelvic canal and the previous suture was oversewn. The abdominal cavity was examined for evidence of haemorrhage and lavaged with warm saline. The abdominal wall closure was routine. Apposition of vulvar lips was performed with a horizontal mattress pattern without tightening to allow vulvar discharge and normal urination. This stay suture was left in place for 5 days to prevent opening of the vulvar lips, which would allow recurrence of the prolapse (Figure 3). The purse string suture around the anus was removed at the end of the surgery.

The queen recovered well. Postoperative treatment included the use of an Elizabethan collar, intravenous fluid therapy, antibiotic (amoxicillin/clavulanic acid [Synulox; Pfizer]), 12.5 mg/kg q12h), narcotic analgesic (Topalgic Tramadol; Sanofi Aventis, 2 mg/kg q12h to q8h), and a single injection of metoclopramide (0.3 mg/kg) to promote lactation. Metoclopramide is a dopamine antagonist, which promotes the release of prolactin. The day after surgery, the cat was alert, urinated normally and the vulva was clean without any discharge. The cat was sent home at that time. Two months after the surgery, there was no recurrence of the prolapse.

Uterine prolapse is relatively uncommon.<sup>6,7</sup> Ekstrand and Linde-Forsberg reported it as accounting for 0.6% of the maternal causes of dystocia.<sup>8</sup>

The aetiology of uterine prolapse is unknown in queens. It is thought to occur as a result of decreased myometrial tone that may allow the uterus to fold in and permit part of the wall to move towards the pelvic inlet.<sup>9</sup>



**Figure 3** Vulvar stay sutures after amputation of the prolapse and replacement of the stump

Dystocia and increased straining, which may be caused by prolonged queening, incomplete placental separation, pain or discomfort after parturition, probably lead to uterine prolapse.<sup>1,3</sup> The cervix must be dilated and the uterine ligaments must have a high laxity or be ruptured for uterine prolapse to occur. In humans, many risk factors have been suggested and some of them are relevant in veterinary medicine, such as obesity, an oversized fetus and a prolonged labour.<sup>10</sup> In the present case, no direct causative factor was identified, but it was likely associated with the first hypothesis because the owner did not describe straining after parturition.

Clinical signs include vaginal discharge, straining, restlessness, pain and protrusion of a mass from the vulva,<sup>6</sup> and may progress to signs associated with shock or toxæmia.<sup>7</sup> In cats, considerable damage and contamination can occur rapidly as a result of exposure and licking of the prolapsed organ. The uterus may also be engorged and oedematous, as in the current case, due to venous congestion and stasis.<sup>11</sup> Signs of haemorrhagic shock may be seen if the ovarian or uterine vessels have ruptured as a result of tearing of the broad ligament. In addition, urinary tract infection and even acute urinary retention may occur.<sup>11</sup> In humans, symptoms include urinary incontinence, stranguria, dysuria and faecal incontinence.<sup>12</sup> The mechanism for urinary retention seems to be mechanical obstruction resulting from urethral kinking or compression.<sup>13</sup> Uterine prolapse can be associated with a uterine rupture.<sup>14</sup>

Prolapse of the uterus is a straightforward diagnosis made by observation. The exposed uterus has to be palpated to rule out the possible presence within it of any abdominal contents such as the urinary bladder or abdominal viscera.<sup>15</sup> Ultrasound examination of the abdomen and the uterine prolapse can be performed to reveal the position of the urinary bladder and the intestine and to rule out the presence of an additional kitten in the abdomen.

Uterine prolapse requires immediate attention and represents an obstetric emergency. To decrease the risk of uterine artery rupture or avulsion from the internal iliac leading to fatal haemorrhage, activity should be restricted until the prolapse is repaired.<sup>15</sup> Gross debris contaminating the prolapsed tissue should be removed by washing, preferably with a hypertonic solution. Topical application of osmotic agents has proven to be effective in reducing and preventing the oedema that rapidly accumulates within the prolapsed tissue.<sup>15</sup>

Uterine prolapse can be treated by medical (rarely successful) or by surgical management. The goal of treatment is to prevent infection. The organ can be cleaned and replaced if the organ is vital and replaceable.<sup>3-5</sup> Failure to achieve complete reduction of the prolapse can result in continued straining and uterine necrosis.<sup>9</sup> An episiotomy can be performed to assist with manual reduction.

Oxytocin (0.5–1.0 IU) can be administered to facilitate uterine involution, which will prevent recurrence.<sup>3</sup>

Ovariohysterectomy (OHE) is recommended if the uterus is too severely damaged, devitalised or if vessels in the broad ligament have been ruptured. OHE is preferred ahead of manual reduction unless the cat is a valuable breeding queen. OHE can be performed after or before reduction.<sup>2</sup> Indeed, in the current case, the uterus was too contaminated to push it back into the abdomen. In addition, urethral catheterisation prior to uterine amputation is important in order to prevent damaging the urethra. Caudal epidural anaesthesia can be performed to prevent straining and to facilitate replacement of the uterus.<sup>5,15</sup>

The uterus may be attached to the abdominal wall to prevent further prolapse.<sup>16</sup> In humans, the surgical management of uterine prolapse requires an apical suspension procedure, with or without uterine removal. Several methods have been described, including sacral colpopexy, vaginal sacrospinous ligament suspension, sacrospinous hysteropexy and sacral hysteropexy.<sup>17</sup> The colposuspension, well described in veterinary medicine, can be performed in the management of uterine prolapse to prevent recurrence and to maintain continence.<sup>18</sup>

Postoperatively, urination should be monitored as swelling and pain can lead to urethral obstruction. Complications may develop from minor laceration of the uterus to septicaemia or uterine rupture. Owing to 'pelvic bladder' syndrome, urinary incontinence may be seen after reduction of the prolapse.<sup>19</sup> Furthermore, detrusor atony secondary to urethral obstruction may induce urinary retention.

## Conclusions

Although rare, uterine prolapse should be managed as an emergency because of the risk of uterine rupture and haemorrhage, even with immediate attempts to reduce the oedema. Palpation and ultrasonographical examination are important to confirm the absence of abdominal contents in the uterus. The treatment for uterine prolapse depends upon the severity of damage to the uterus and may include hysterectomy. As with humans, a colposuspension can be performed. The prognosis following treatment for a uterine prolapse is guarded depending on the timing of veterinary intervention, as well as the recognition and treatment of secondary complications.

**Funding** The authors received no specific grant from any funding agency in the public, commercial or not-for-profit sectors for the preparation of this case report.

**Conflict of interest** The authors declare no conflicts of interest.

## References

- 1 Anderhust SR. **Bicornuate uterine prolapse in a cat: a photographic essay.** *Vet Med Small Anim Clin* 1975; 70: 681.
- 2 Bruinsma DL. **Feline uterine prolapse (a case report).** *Vet Med Small Anim Clin* 1981; 76: 60.
- 3 Maxson FB and Krausnick KE. **Dystocia with uterine prolapse in a Siamese cat.** *Vet Med Small Anim Clin* 1969; 64: 1065–1066.
- 4 Vaughan L and McGuckin S. **Uterine prolapse in a cat.** *Vet Rec* 1993; 132: 568.
- 5 Wallace LJ, Henry JD and Clifford JH. **Manual reduction of uterine prolapse in a domestic cat.** *Vet Med Small Anim Clin* 1970; 65: 595–596.
- 6 Feldman EC and Nelson RW. **Periparturient diseases.** In: Feldman EC and Nelson RW (eds). *Canine and feline endocrinology and reproduction*. 3rd ed. St Louis, MO: Saunders, 2004, p 808.
- 7 Stone EA. **Ovary and uterus.** In: Slatter DH (ed). *Textbook of small animal surgery*. 3rd ed. Philadelphia, PA: Saunders, 2003, p 1487.
- 8 Ekstrand C and Linde-Forsberg C. **Dystocia in the cat: a retrospective study of 155 cases.** *J Small Anim Pract* 1994; 35: 459–464.
- 9 Murphy AM and Dobson H. **Predisposition, subsequent fertility, and mortality of cows with uterine prolapse.** *Vet Rec* 2002; 151: 733–735.
- 10 Schaffer JI, Wai CY and Boreham MK. **Etiology of pelvic organ prolapse.** *Clin Obstet Gynecol* 2005; 48: 639–647.
- 11 Shumaili Y, Bushra H and Tabinda R. **Extensive uterovaginal prolapse during labor.** *J Obstet Gynaecol Res* 2011; 37: 264–266.
- 12 Ellerkmann RM, Cundiff GW, Melick CF, et al. **Correlation of symptoms with location and severity of pelvic organ prolapse.** *Am J Obstet Gynecol* 2001; 185: 1332–1337.
- 13 Barber MD. **Symptoms and outcome measures of pelvic organ prolapse.** *Clin Obstet Gynecol* 2005; 48: 648–661.
- 14 Carreira RP, Albuquerque C, Abreu H, et al. **Uterine prolapse with associated rupture in a Podengo bitch.** *Reprod Dom Anim* 2012; 47: 51–55.
- 15 Miesner DM and Anderson DE. **Management of uterine and vaginal prolapse in the bovine.** *Vet Clin Food Anim* 2008; 24: 409–419.
- 16 Hopper RM. **Surgical correction of abnormalities of genital organs of cows: management of uterine prolapse.** In: Youngquist RS and Threlfall WR (eds). *Current therapy in large animal theriogenology*. 2nd ed. Philadelphia, PA: Saunders, 2007, pp 470–471.
- 17 Maher CF, Qatawneh A, Dwyer PL, et al. **Abdominal sacral colpopexy or vaginal sacrospinous colpopexy for vaginal vault prolapse: a prospective randomized trial.** *Am J Obstet Gynecol* 2004; 190: 20–26.
- 18 Holt PE. **Long term evaluation of colposuspension in the treatment of urinary incontinence due to incompetence of the urethral sphincter mechanism in the bitch.** *Vet Rec* 1990; 127: 537–542.
- 19 Holt PE and Jones A. **In vitro study of the significance of bladder neck position in incontinent bitches.** *Vet Rec* 2000; 146: 437–439.