

Malignant transformation of a duodenal duplication cyst in a cat

Authors: Hobbs, Joshua, Penninck, Dominique, and Lyons, Jeremy

Source: Journal of Feline Medicine and Surgery Open Reports, 1(1)

Published By: SAGE Publishing

URL: <https://doi.org/10.1177/2055116915579946>

BioOne Complete (complete.BioOne.org) is a full-text database of 200 subscribed and open-access titles in the biological, ecological, and environmental sciences published by nonprofit societies, associations, museums, institutions, and presses.

Your use of this PDF, the BioOne Complete website, and all posted and associated content indicates your acceptance of BioOne's Terms of Use, available at www.bioone.org/terms-of-use.

Usage of BioOne Complete content is strictly limited to personal, educational, and non - commercial use. Commercial inquiries or rights and permissions requests should be directed to the individual publisher as copyright holder.

BioOne sees sustainable scholarly publishing as an inherently collaborative enterprise connecting authors, nonprofit publishers, academic institutions, research libraries, and research funders in the common goal of maximizing access to critical research.



Malignant transformation of a duodenal duplication cyst in a cat

Joshua Hobbs¹, Dominique Penninck¹ and Jeremy Lyons²

Journal of Feline Medicine and Surgery
Open Reports
 1–3

© The Author(s) 2015

Reprints and permissions:

sagepub.co.uk/journalsPermissions.nav

DOI: 10.1177/2055116915579946

jfmsopenreports.com



Abstract

Case summary A 15-year-old domestic shorthair cat presented for lethargy, vomiting and anorexia. Abdominal ultrasound showed a bi-lobed cystic duodenal mass. Based on ultrasonographic features, malignant transformation of a duodenal duplication cyst was suspected. A resection and anastomosis was performed. Histology of the mass was consistent with carcinoma and an intestinal mucosa was present along the inner surface of the mass, suggestive of a duplication cyst. The patient returned 3 months postsurgery with recurrence of clinical signs. Abdominal ultrasound showed a recurrent duodenal mass at the surgery site and body wall nodules. Fine-needle aspirates of these lesions showed epithelial neoplasia. Owing to the poor prognosis, the owners elected euthanasia.

Relevance and novel information Malignant transformation of duplication cysts in cats is rare but can be detected on ultrasound. The described ultrasonographic features can aid in prioritization of malignant transformation of duplication cysts as a differential diagnosis.

Accepted: 4 July 2014

A 15-year-old castrated male domestic shorthair cat presented to the Foster Hospital for Small Animals at the Cummings School of Veterinary Medicine for a 3 day history of lethargy and 2 day history of vomiting and anorexia. No abnormalities were noted on the referring veterinarian's blood work. Radiographs performed by the referring veterinarian showed a round soft tissue opaque cranial abdominal mass that was superimposed on the pylorus, and the stomach contained a moderate volume of fluid. Abdominal ultrasound showed a bi-lobed cystic mass-like structure that was closely associated with the duodenum (Figure 1a). The walls were echogenic and variably thickened (up to 9 mm; see Figure 1a), and a hyperechoic focus was seen within the wall of the mass. Focal loss of wall layering at the junction between the cavitated mass and the duodenum was seen and no connection to the duodenal lumen could be identified. The adjacent duodenal segment had thickened walls, focal loss of wall layering and a narrowed lumen (Figure 1b). The duodenal papilla was not identified in the region of the mass. The pancreas also appeared to be displaced by the mass but was otherwise normal. The remainder of the abdominal ultrasound was within normal limits.

Based on the ultrasonographic appearance of the bi-lobed cystic mass, a duodenal duplication cyst was suspected. The loss of wall layering was supportive of neoplasia. Fine-needle aspiration of the wall of the mass

was performed and fluid was removed from the cavity of the mass. Cytology of the mass revealed an epithelial neoplasm with squamous cell differentiation. The fluid portion of the mass revealed necrosis and cyst formation with chronic haemorrhage. Thoracic radiographs were performed to evaluate for evidence of metastasis. These showed a bronchial pattern, mild cardiomegaly and no evidence of pulmonary metastatic disease. An echocardiogram was performed and showed hypertrophic cardiomyopathy with no need for medical management. Exploratory laparotomy was considered but not performed at this time, as the patient was clinically improving with intravenous fluids and anti-nausea medications.

The patient returned 6 days later for recurrent anorexia and vomiting. Repeat ultrasound showed evidence of mechanical obstruction with a fluid-distended stomach and distended duodenum oral to the suspected malignantly transformed duodenal duplication cyst.

¹Department of Diagnostic Imaging, Tufts Cummings School of Veterinary Medicine, North Grafton, MA, USA

²Department of Pathology, Tufts Cummings School of Veterinary Medicine, North Grafton, MA, USA

Corresponding author:

Joshua Hobbs DVM, DACVR, Friendship Hospital for Animals, 4105 Brandywine Street, NW, Washington, DC 20016, USA
 Email: jhobbs@friendshiphospital.com



Creative Commons CC-BY-NC: This article is distributed under the terms of the Creative Commons Attribution-NonCommercial 3.0 License (<http://www.creativecommons.org/licenses/by-nc/3.0/>) which permits non-commercial use, reproduction and distribution of the work without further permission provided the original work is attributed as specified on the SAGE and Open Access page (<http://www.uk.sagepub.com/aboutus/openaccess.htm>).

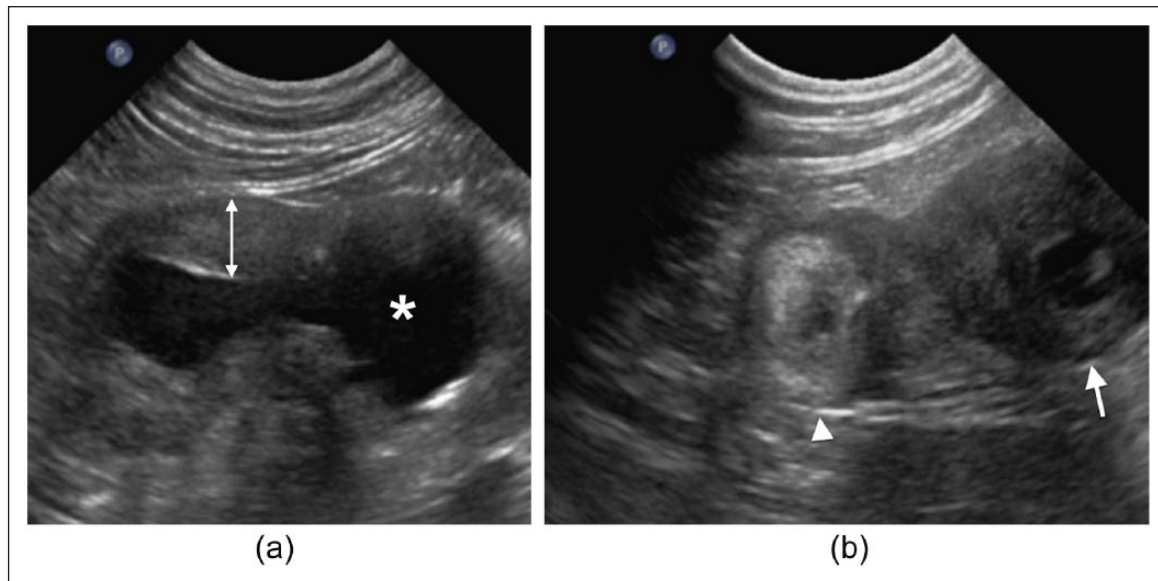


Figure 1 (a) Malignantly transformed duodenal duplication cyst in a longitudinal plane. The asterisk shows the cystic portion. The white double-headed arrow shows the thickened wall of the duodenal duplication cyst at the tumoral site (up to 9 mm). (b) Malignantly transformed duodenal duplication cyst and duodenum in a transverse plane. The arrowhead shows the duodenum with a thickened and hyperechoic wall. The white arrow shows the thickened duodenal duplication cyst. No communication is seen between the duodenal lumen and cystic portion of the duodenal duplication cyst

Exploratory laparotomy was performed. At surgery, a bi-lobed mass was seen associated with the duodenum. The duodenal papilla was located approximately 3 cm oral to the mass, and a resection and anastomosis of the cystic duodenal mass was performed with no complications (Figure 2). Histology of the mass revealed an adenocarcinoma with lymphatic invasion. Intestinal mucosa was present on the inner surface of the bi-lobed cystic region, supportive of a duplication cyst. Grossly, no connection between the intestinal lumen and caviated portion of the duplication could be found. Focal mineralization was present within the wall of the mass on histology, which likely represented the hyperechoic focus seen on ultrasound. The patient did well postoperatively and went home. The owners elected not to pursue chemotherapy.

Approximately 3 months after surgery, the cat returned for recurrent vomiting. Ultrasound was performed and a 2.5 cm, poorly echogenic mass was seen at the duodenal surgery site, and loss of intestinal wall layering was noted at this level. Additionally, three abdominal wall nodules were seen. Fine-needle aspirates of the duodenal mass and wall nodules were compatible with epithelial neoplasia. Given the progression of disease, the owners elected for humane euthanasia.

Enteric duplications are rare congenital abnormalities reported in humans, cats and dogs.¹⁻⁹ Enteric duplications are thought to be the result of abnormal recanalization of the gastrointestinal tract. The mucosal layer of enteric duplications is most often similar to adjacent intestinal mucosa.⁸ Duplication cysts can occur

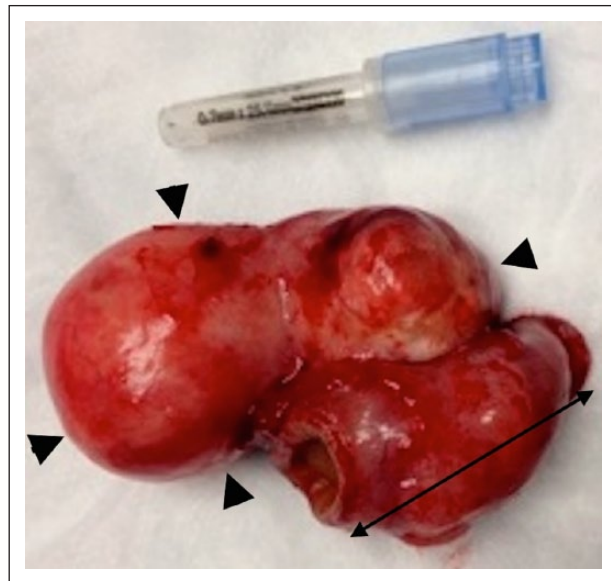


Figure 2 Gross image of the bi-lobed duodenal duplication cyst (arrowheads). The double-headed arrow shows the resected portion of the duodenum

anywhere along the gastrointestinal tract, and can be round or tubular in appearance. In humans, duodenal duplication cysts are rare and account for approximately 5% of enteric duplications.³ Children and adults often present with signs of obstruction or a painful abdomen.^{1,4,6} In veterinary patients, clinical signs are often absent.^{5,8} One case report of a rectal duplication cyst in a cat resulted in tenesmus and constipation due to

compression of the rectum.¹⁰ In humans and dogs, an ultrasonographic feature of duodenal duplication cysts is a cystic mass that is contiguous with an intestinal segment;^{9,11} thus, giving it the appearance of two non-communicative bowel segments adherent to one another. In humans and dogs, the presence of a muscular rim sign is suggestive of a duplication cyst.^{9,12} The muscular rim sign is seen as a hypoechoic muscularis layer that surrounds an inner echogenic mucosa.¹²

In humans, malignant transformation of duplication cysts is suspected when there is loss of the muscular rim sign and thickening of the normally thin-walled cyst.^{11,12} This is similar to the present case, where the wall of the cystic mass was irregularly thickened with loss of wall layering (Figure 1a). Therefore, wall layering of duodenal duplication cysts should be carefully evaluated, as loss of wall layering is supportive of neoplasia. Additionally, there was concurrent loss of wall layering of the adjacent duodenum (Figure 1b). Loss of gastrointestinal wall layering on abdominal ultrasound is a primary feature of gastrointestinal neoplasia.^{13,14} However, cystic dilation of gastrointestinal masses has not been reported as a primary feature of gastrointestinal neoplasia.^{13,14} For this reason, we suspected the duodenal mass in the current case was a malignantly transformed duplication cyst. In the current case, we speculated that the clinical signs were likely due to the presence of carcinoma restricting the lumen of the duodenum and not the malignantly transformed duodenal duplication cyst, as intestinal carcinoma has been reported in cats to cause mechanical obstruction due to a constrictive lesion.¹³

In humans, malignant transformation of duplications cysts is rare, with only 30 cases being reported in the literature.¹⁵ In the veterinary literature, duplication cysts have historically been thought of as an incidental finding. However, the current case presents the possibility of duplication cysts undergoing malignant transformation. For this reason, surgical removal of duplication cysts could prevent this rare occurrence.

Conclusions

Malignant transformation of a duodenal duplication cyst is possible in cats and can be detected on ultrasound. Malignant transformation of duplication cysts should be considered as a differential for a cystic mass with loss of wall layering associated with an intestinal segment or if clinical signs develop in a patient with a previously diagnosed incidental duplication cyst.

Funding The authors received no specific grant from any funding agency in the public, commercial or not-for-profit sectors for the preparation of this case report.

Conflict of interest statement The authors declare no conflicts of interest.

References

- 1 Antaki F, Tringali A, Deprez P, et al. **A case series of symptomatic intraluminal duodenal duplication cysts: presentation, endoscopic therapy, and long-term outcome (with video).** *Gastrointestinal Endosc* 2008; 67: 163–168.
- 2 Rice C, Anderson T and Sepahdari S. **Computed tomography and ultrasonography of carcinoma in duplication cysts.** *J Comput Assist Tomogr* 2006; 10: 233–235.
- 3 Tang SJ, Raman S, Reber HA, et al. **Duodenal duplication cyst.** *Endoscopy* 2002; 34: 1028–1029.
- 4 Guarise A, Faccioli N, Ferrari M, et al. **Duodenal duplication cyst causing severe pancreatitis: imaging findings and pathological correlation.** *World J Gastroenterol* 2006; 12: 1630–1633.
- 5 Parry-Smith P, Czerwinska M and Krudewig C. **Duodenal duplication cyst in a young cat.** *Vet Rec* 2008; 62: 826–827.
- 6 Zamir G, Gross E, Shmushkevich A, et al. **Duodenal duplication cyst manifested by duodeno-jejunal intussusception and hyperbilirubinemia.** *J Pediatr Surg* 1999; 34: 1297–1299.
- 7 Seeliger B, Piardi T, Marzano E, et al. **Duodenal duplication cyst: a potentially malignant disease.** *Ann Surg Oncol* 2012; 19: 3753–3754.
- 8 Radlinsky M, Biller D, Nietfield J, et al. **Subclinical intestinal duplication in a cat.** *J Feline Med Surg* 2005; 7: 223–226.
- 9 Spaulding KA, Cohn LA, Miller RT, et al. **Enteric duplication in two dogs.** *Vet Radiol Ultrasound* 1990; 31: 83–88.
- 10 Kook PH, Hagen R, Willi B, et al. **Rectal duplication cyst in a cat.** *J Feline Med Surg* 2010; 12: 978–981.
- 11 Narlawar RS, Rao JR, Karmarkar SJ, et al. **Sonographic findings in a duodenal duplication cyst.** *J Clin Ultrasound* 2002; 30: 566–568.
- 12 Hsu H, Gueng MK, Tseng YH, et al. **Adenocarcinoma arising from colonic duplication cyst with metastasis to omentum: a case report.** *J Clin Ultrasound* 2011; 39: 41–43.
- 13 Rivers B, Walter P, Feeney D, et al. **Ultrasonographic features of intestinal adenocarcinoma in five cats.** *Vet Radiol Ultrasound* 1997; 38: 300–306.
- 14 Penninck D, Moore A, Tidwell A, et al. **Ultrasonography of alimentary lymphosarcoma in the cat.** *Vet Radiol Ultrasound* 1994; 35: 299–304.
- 15 Hata H, Hiraoka N, Ojima H, et al. **Carcinoid tumor arising in a duplication cyst of the duodenum.** *Pathol Int* 2006; 56: 272–278.