



Osteitis fibrosa cystica in a domestic young cat

Authors: Leite-Filho, Ronaldo V, Bandinelli, Marcele B, Fredo, Gabriela, Bianchi, Matheus V, van der lan Fonini, Alessandra, et al.

Source: Journal of Feline Medicine and Surgery Open Reports, 1(2)

Published By: SAGE Publishing

URL: <https://doi.org/10.1177/2055116915607555>

BioOne Complete (complete.BioOne.org) is a full-text database of 200 subscribed and open-access titles in the biological, ecological, and environmental sciences published by nonprofit societies, associations, museums, institutions, and presses.

Your use of this PDF, the BioOne Complete website, and all posted and associated content indicates your acceptance of BioOne's Terms of Use, available at www.bioone.org/terms-of-use.

Usage of BioOne Complete content is strictly limited to personal, educational, and non - commercial use. Commercial inquiries or rights and permissions requests should be directed to the individual publisher as copyright holder.

BioOne sees sustainable scholarly publishing as an inherently collaborative enterprise connecting authors, nonprofit publishers, academic institutions, research libraries, and research funders in the common goal of maximizing access to critical research.



Osteitis fibrosa cystica in a domestic young cat

Journal of Feline Medicine and Surgery
Open Reports
 1–4

© The Author(s) 2015
 Reprints and permissions:
sagepub.co.uk/journalsPermissions.nav
 DOI: 10.1177/2055116915607555
jfmsopenreports.com



Ronaldo V Leite-Filho¹, Marcele B Bandinelli¹, Gabriela Fredo¹,
 Matheus V Bianchi¹, Alessandra van der Ian Fonini²,
 Marcelo M Alievi², David Driemeier¹, Saulo P Pavarini¹
 and Luciana Sonne¹

Abstract

Case summary A 4-month-old cat had bilateral swellings of the mandible, maxilla, humerus and femur, and angular deviations in the axial and appendicular skeleton. The biochemical profile indicated hypercalcemia, hyperphosphatemia and increased parathyroid hormone levels. Because of the poor prognosis, the cat was euthanized. At necropsy, malleable and fragile bones, associated with numerous cystic areas containing yellowish and translucent liquid, were observed. Histologically, the bones showed marked diffuse proliferation of fibrous connective tissue, and large numbers of osteoclasts surrounding numerous cystic structures were also observed within fibrotic areas at the periphery of the trabecular bone. In addition, enlargement of the parathyroid glands, which was associated with increased serum concentrations of calcium, phosphorus and parathyroid hormone, was detected.

Relevance and novel information The changes observed in this cat are consistent with hyperparathyroidism-associated osteitis fibrosa cystica, which is an unusual presentation in the cat. Hyperparathyroidism, either primary (neoplastic) or secondary (nutritional or renal), is the primary cause of this condition.

Accepted: 26 August 2015

Introduction

The skeletal changes in hyperparathyroidism are characterized by the diffuse or focal resorptive loss and fibrous replacement of bone due to an excess of osteoclastic activity over osteoblastic activity caused by an overproduction of parathyroid hormone (PTH) in either primary or secondary hyperparathyroidism. There is marked species variation in the gross and microscopic appearances of fibrous osteodystrophy. The condition called osteitis fibrosa cystica (OFC), or brown tumor, constitutes a small percentage of osteolytic lesions in people with either primary or secondary hyperparathyroidism.¹ OFC represents a focal bone lytic lesion that often develops at multiple sites.² The radiographic findings of OFC can mimic bone malignancy, while the simultaneous involvement of multiple skeletal segments can be interpreted as diffuse metastatic disease.³ In both presentations, the hypersecretion of PTH is observed, which results in increased osteoclastic activity, osteopenia and subperiosteal bone resorption. Increased osteoclast activity causes fibrovascular tissue proliferation in marrow spaces,

microfractures and hemorrhage, and also promotes the migration of macrophages to the site of injury.³ The purpose of this report is to describe a case of OFC in a young domestic cat.

Case description

The cat was a stray, estimated to be about 2 months old, when it was rescued together with its dam and the remaining litter. It was the smallest of the litter and was the only one to have impaired locomotion and intolerance for

¹Sector of Veterinary Pathology, Federal University of Rio Grande do Sul, Porto Alegre, RS, Brazil

²Veterinary Hospital, Federal University of Rio Grande do Sul, Porto Alegre, RS, Brazil

Corresponding author:

Luciana Sonne DVM, MSc, PhD, Sector of Veterinary Pathology, Veterinary Faculty, Federal University of Rio Grande Sul, Av Bento Gonçalves, 9090, Pr 42505, Porto Alegre, RS, Brazil
 Email: lusonne@yahoo.com.br



Creative Commons CC-BY-NC: This article is distributed under the terms of the Creative Commons Attribution-NonCommercial 3.0 License (<http://www.creativecommons.org/licenses/by-nc/3.0/>) which permits non-commercial use, reproduction and distribution of the work without further permission provided the original work is attributed as specified on the SAGE and Open Access page (<https://us.sagepub.com/en-us/nam/open-access-at-sage>).

physical activity. Since being adopted, the cat had been fed with commercial feline diets. Because the cat was a stray and had been adopted from the streets only 2 months previously, no information on its littermates or early dietary intake was available. By 4 months of age the cat's condition had worsened; bilateral enlargement of the mandibles developed, resulting in respiratory noise (snoring) while sleeping and progressing to severe dysphagia. On physical examination, mild dehydration; bilateral swelling of a firm consistency in the mandible, maxilla, humerus and femur; angular deviation of the radius, ulna, tibia and fibula; and kyphosis, were observed.

Radiographic examination revealed reduced bone density, and numerous bilateral cystic areas in the mandible, maxilla, humerus and femur were detected (Figure 1). Automated hematologic analyses were performed on a Horiba ABX-ABC-Vet (Horiba-ABX Diagnostics), and all parameters were within the reference intervals (RI). Serum samples were analyzed on a BS-800 Automatic Biochemical Analyzer (Mindray Diagnostics) using reagents supplied by the manufacturer, revealing reduced creatinine (0.40 mg/dl; RI 0.80–1.80 mg/dl) and increased phosphorus (13.52 mg/dl; RI 2.7–6.2 mg/dl) levels. A chemiluminescent assay to detect intact PTH was performed by using an Immulite 1000 Immunoassay System (Siemens Healthcare) and showed markedly elevated PTH levels (442.0 pg/ml;

RI 15–19 pg/ml). Blood ionized calcium was analyzed by using an ion-selective electrode on an Easylyte Analyzer (Medica) and revealed increased ionized calcium levels (8.6 mg/dl; RI 4.3–5.9 mg/dl). Urination occurred frequently, and the urine was clear and colorless with a specific gravity of 1.028, which was within the RI for this age group (<6 months old).⁴

Because of the poor prognosis, the cat was euthanized, and a necropsy was performed within 1 h of death. Gross findings included bilateral swelling of the mandible (Figure 2), maxilla, thoracic bones (humerus and radius) and pelvic limb bones (femur and tibia) (Figure 3). These bones were fragile and malleable, and had numerous cystic areas containing yellowish, translucent liquid. In the ribs, increased flexibility

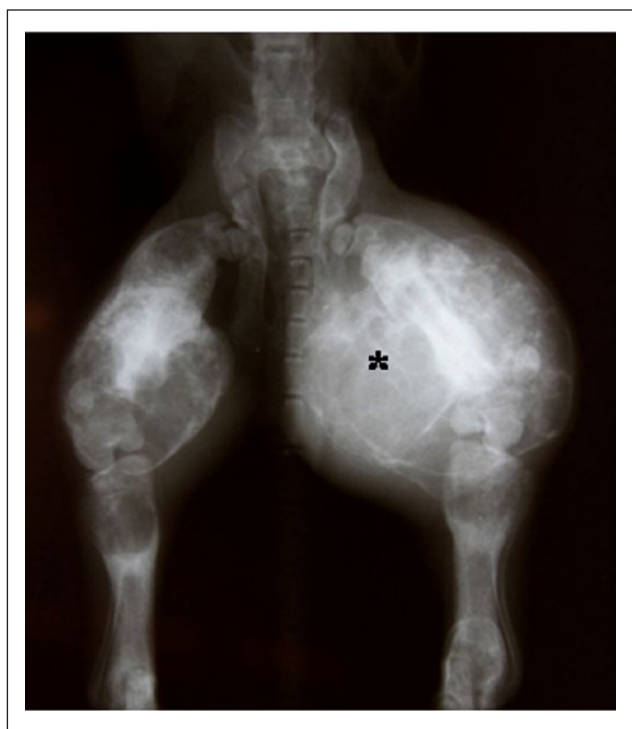

Figure 1 Ventrodorsal radiograph of a cat with osteitis fibrosa cystica. Severe deformation, osteopenia and cystic formations in the bones (asterisk) are observed

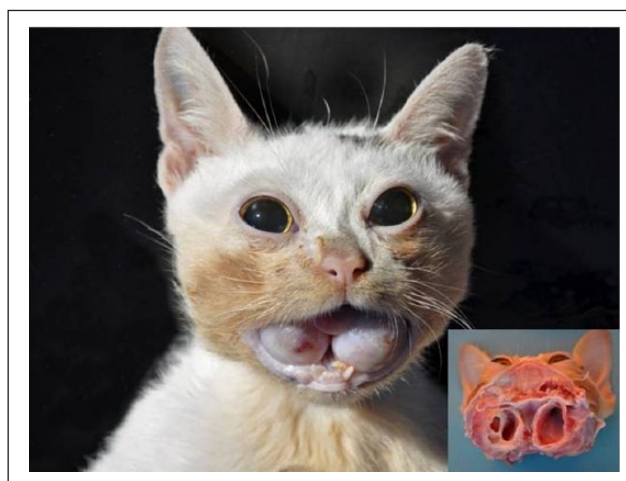

Figure 2 Bilateral mandibular enlargements and occlusion of the oral cavity. Cross-section of the head (inset) shows decreased bone density and cysts containing yellowish translucent material

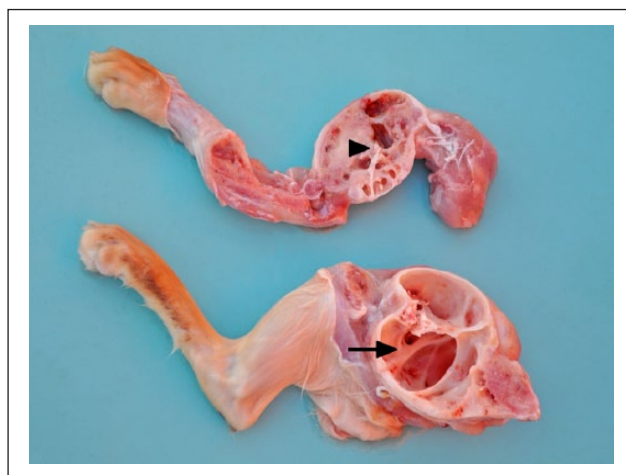


Figure 3 The humerus (arrowhead) and femur (arrow) are deformed and cystic

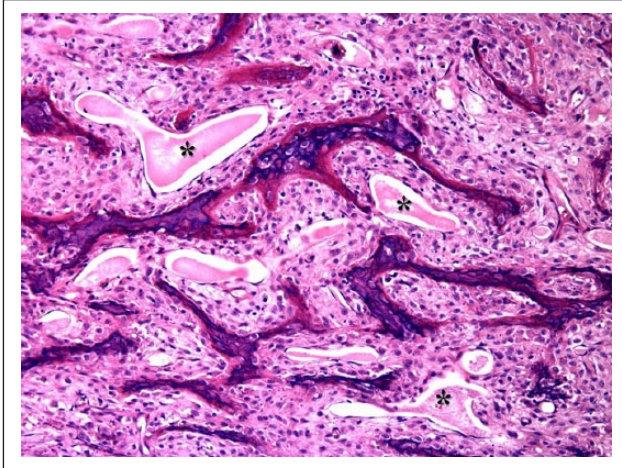


Figure 4 Bone resorption, fibrous tissue proliferation and multiple cysts containing eosinophilic material (asterisks) are seen in histopathology of mandible tissue. Hematoxylin and eosin staining; magnification $\times 400$

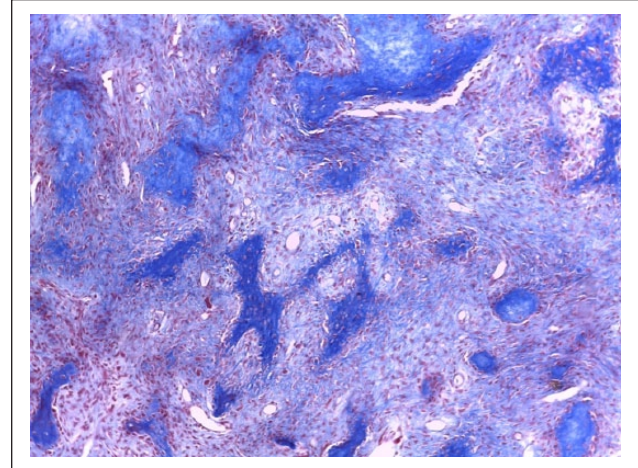


Figure 5 Diffuse proliferation of fibrous connective tissue is seen in histopathology of mandible tissue. Masson's trichrome staining; magnification $\times 100$

and pathological fractures were observed. Both parathyroid glands were uniformly and markedly increased in size, measuring 4.0 mm \times 5.0 mm (normal: 1.0 mm \times 3.0 mm).

Multiple organs were collected and fixed in 10% neutral buffered formalin. Subsequently, tissue samples were routinely processed, and sections (3 μ m thick) were stained with hematoxylin and eosin. Bone tissue sections were stained with Masson's trichrome and Prussian blue techniques. On histologic examination, the bones showed marked diffuse proliferation of the fibrous connective tissue (Figure 4). Many osteoclasts, surrounding numerous cystic structures, were also observed within fibrotic areas at the periphery of the trabecular bone. The cysts were filled with fibrillary and eosinophilic materials and erythrocytes. Osteolytic and cystic lesions were observed in the mandible and the maxilla, as well as in the thoracic bones (humerus and radius), the pelvic limb bones (femur and tibia) and the ribs, characterizing a multicentric presentation. In the parathyroid glands, marked diffuse hyperplasia, with moderate swelling in the principal cells, was observed. The lungs, kidneys, heart, spleen and stomach showed multifocal areas of moderate-to-marked mineralization in the parenchyma, as well as in the tunica adventitia of blood vessels. With Masson's trichrome and Prussian blue staining, the fibrous tissue and the granular material within macrophages (hemosiderin), respectively, stained blue (Figure 5).

Based on the clinical history and on ante- and post-mortem findings, a diagnosis of fibrous osteodystrophy variant OFC due to hyperparathyroidism was established.

Discussion

In this case, the skeletal lesions were consistent with a hypostatic–porotic form of fibrous osteodystrophy, with cystic areas similar to those observed in OFC in humans. OFC has been rarely described in animals, although the findings in this case are similar to those described within the long bones of a cat with hyperparathyroidism.⁵ The osteolytic lesions accompanied by cystic cavities are considered to be the result of bone reabsorption and necrosis, with collapse of the osteoid matrix and incomplete fibrous replacement of the bone matrix, which can be accompanied by hemorrhage. The severity of the lesions may be dependent on the PTH and calcium levels.⁶ The multifocal organ calcifications observed in this case are consistent with metastatic calcification associated with hypercalcemia and increased Ca:P product, as no underlying pathology was apparent in the affected organs. In domestic animals, primary and secondary hyperparathyroidism (nutritional or renal) is associated with the development of metabolic bone diseases that cause decreases in bone density and widespread increases in osteoclastic activity and in the proliferation of fibrous connective tissue in the bones (classical lesions of fibrous osteodystrophy).⁷ Differential diagnoses for fibrous osteodystrophy include renal hyperparathyroidism, which, in congenital forms, increasingly manifests as the cat grows; dietary imbalances, including excessive phosphorus, decreased calcium or altered vitamin D levels; vitamin receptor alterations (genetic); and osteogenesis imperfecta, all of which can present with significant fibrous replacement of bone. Primary bone tumors may also be considered, as the bones are distorted and increased in size, and the radiographic changes associated with the mottling of bone can

be observed with tumor metastasis or myeloma.⁸ Vitamin D levels were not measured in this cat, but the pathological changes in the bones are not consistent with those associated with vitamin D abnormalities.⁹

In humans, OFC affects 3–4% of patients with primary hyperparathyroidism and 1.50–1.75% of the patients with secondary hyperparathyroidism.¹⁰ In cats, primary hyperparathyroidism is considered a rare condition, and in dogs, although uncommon, it is described in older animals. Secondary hyperparathyroidism is far more common and may be of nutritional or renal origin.^{7,11} In primary hyperparathyroidism, the lesion is within the gland itself and results in the autonomous production of PTH. In secondary hyperparathyroidism, the increased PTH levels result from a response by the gland to altered mineral levels, which can occur with nutritional disease, with failure to absorb nutrients, with receptor alterations, with losses of calcium, magnesium or phosphorus in the urine, or with neoplasia. In this case, the primary cause of the altered mineral balance and of the increased PTH levels remains unclear.

Conclusions

Because of the morphological characteristics of bones in OFC, biochemical tests such as the measurements of calcium, serum phosphorus and PTH concentrations are important tools that aid in the diagnosis of OFC. Although OFC is a rare disease, it should be considered in the differential diagnosis of bone lesions in cats, especially when there are concomitant disorders involving the parathyroid glands.

Funding The authors received no specific grant from any funding agency in the public, commercial or not-for-profit sectors for the preparation of this case report/case series/short communication.

Conflict of interest The authors declared no potential conflicts of interest with respect to the research, authorship, and/or publication of this article.

References

- 1 Ergen FB, Ayvaz M, Yildiz AE, et al. **Brown tumour presenting as a soft-tissue mass.** *Clin Radiol* 2012; 67: 286–289.
- 2 Parisien M, Silverberg SJ, Shane E, et al. **Bone disease in primary hyperparathyroidism.** *Endocrinol Metab Clin North Am* 1990; 19: 19–34.
- 3 Hsieh MC, Ko JY and Eng HL. **Pathologic fracture of the distal femur in osteitis fibrosa cystica simulating metastatic disease.** *Arch Orthop Trauma Surg* 2004; 124: 498–501.
- 4 Rishniw M and Bicalho R. **Factors affecting urine specific gravity in apparently healthy cats presenting to first opinion practice for routine evaluation.** *J Feline Med Surg* 2015; 17: 329–337.
- 5 Gnudi G, Bertoni G, Luppi A, et al. **Unusual hyperparathyroidism in a cat.** *Vet Radiol Ultrasound* 2001; 42: 250–253.
- 6 Bodansky A and Jaffe HL. **Parathormone dosage and serum calcium and phosphorus in experimental chronic hyperparathyroidism leading to osteitis fibrosa.** *J Exp Med* 1931; 53: 591–604.
- 7 Savary KC, Price GS and Vaden SL. **Hypercalcemia in cats: a retrospective study of 71 cases (1991–1997).** *J Vet Intern Med* 2000; 14: 184–189.
- 8 Lee JH, Chung SM and Kim HS. **Osteitis fibrosa cystica mistaken for malignant disease.** *Clin Exp Otorhinolaryngol* 2013; 2: 110–113.
- 9 Dittmer KE and Thompson KG. **Vitamin D metabolism and rickets in domestic animals: a review.** *Vet Pathol* 2011; 48: 389–407.
- 10 Di Daniele N, Condò S, Ferrannini M, et al. **Brown tumour in a patient with secondary hyperparathyroidism resistant to medical therapy: case report on successful treatment after subtotal parathyroidectomy.** *Int J Endocrinol* 2009; 2009: 1–3.
- 11 Barber PJ. **Disorders of the parathyroid glands.** *J Feline Med Surg* 2004; 6: 259–269.