



Paraneoplastic neutrophilic leukocytosis syndrome in a cat with recurrent mammary carcinoma

Authors: Jark, Paulo C, Raposo-Ferreira, Talita MM, Terra, Erika M, Sierra Matiz, Oscar R, Anai, Letícia A, et al.

Source: Journal of Feline Medicine and Surgery Open Reports, 1(2)

Published By: SAGE Publishing

URL: <https://doi.org/10.1177/2055116915608202>

BioOne Complete (complete.BioOne.org) is a full-text database of 200 subscribed and open-access titles in the biological, ecological, and environmental sciences published by nonprofit societies, associations, museums, institutions, and presses.

Your use of this PDF, the BioOne Complete website, and all posted and associated content indicates your acceptance of BioOne's Terms of Use, available at www.bioone.org/terms-of-use.

Usage of BioOne Complete content is strictly limited to personal, educational, and non - commercial use. Commercial inquiries or rights and permissions requests should be directed to the individual publisher as copyright holder.

BioOne sees sustainable scholarly publishing as an inherently collaborative enterprise connecting authors, nonprofit publishers, academic institutions, research libraries, and research funders in the common goal of maximizing access to critical research.



Paraneoplastic neutrophilic leukocytosis syndrome in a cat with recurrent mammary carcinoma

Journal of Feline Medicine and Surgery

Open Reports

1–5

© The Author(s) 2015

Reprints and permissions:

sagepub.co.uk/journalsPermissions.nav

DOI: 10.1177/2055116915608202

jfmsopenreports.com



Paulo C Jark¹, Talita MM Raposo-Ferreira¹, Erika M Terra¹, Oscar R Sierra Matiz¹, Letícia A Anai¹, Carlos E Fonseca-Alves², Mirela Tinucci-Costa¹, Renee Laufer-Amorim² and Andriago B De Nardi¹

Abstract

Case summary A spayed 12-year-old female domestic shorthair cat presented with nodular lesions on the ventral-right thoracic wall after complete mastectomy 4 months previously. The prior diagnosis was tubulopapillary mammary carcinoma with axillary lymph node metastasis, and a recurrence was confirmed. A gradual and sequential increase in the total number of leukocytes with severe neutrophilia (95.632/μl) developed over the course of the illness, along with an increase in the size of the recurrent mass. The severe leukocytosis did not show any response to antibiotic therapy, and no evidence of infection was observed. Bone marrow cytology confirmed hypercellularity in the myeloid cell lineage. Based on these findings, paraneoplastic neutrophilic leukocytosis syndrome was suspected. An incisional biopsy of the recurrent mass was consistent with recurrent tubulopapillary mammary carcinoma. Malignant epithelial cells stained positive upon immunohistochemistry for granulocyte-macrophage colony-stimulating factor, cytokeratin and vimentin. After the final diagnosis of paraneoplastic neutrophilic leukocytosis syndrome, the cat was euthanized at the owner's request.

Relevance and novel information This is a novel case of paraneoplastic leukocytosis syndrome associated with mammary carcinoma in a cat. Although there are some reports describing paraneoplastic leukocytosis in cats, the relationship between this syndrome and feline mammary tumors has not been described.

Accepted: 7 August 2015

Introduction

Paraneoplastic neutrophilic leukocytosis syndrome (PNLS) is rarely described in dogs and cats.¹ PNLS has been reported more commonly in dogs diagnosed with renal carcinoma, although it has also been documented in association with lymphoma, primary lung tumor, metastatic fibrosarcoma and rectal polyps.^{2–6} In cats, this syndrome has been reported in even fewer cases.^{7,8} Herein, we describe a cat with PNLS associated with recurrent tubulopapillary mammary carcinoma, diagnosed through immunohistochemistry using granulocyte-macrophage colony-stimulating factor (GM-CSF). To our knowledge, there are no previous reports concerning this rare syndrome secondary to mammary carcinoma in cats.

Case description

A spayed 12-year-old female domestic shorthair cat weighing 4.3 kg was evaluated with suspected recurrent

mammary carcinoma when four subcutaneous small nodular lesions of 0.3–0.5 cm in diameter were detected in the right axillary region. The cat had been spayed at the age of 5 years. The cat was brought to a referring veterinarian 4 months previously with two masses located in the inguinal and abdominal left mammary glands. A double chain mastectomy with removal of the

¹Clinical Veterinary Department, College of Agricultural and Veterinary Sciences, São Paulo State University 'Júlio de Mesquita Filho' (UNESP), Jaboticabal, São Paulo, Brazil

²Pathology Veterinary Department, College of Veterinary and Zootechnical Medicine, São Paulo State University 'Júlio de Mesquita Filho' (UNESP), Botucatu, São Paulo, Brazil

Corresponding author:

Oscar Rodrigo Sierra Matiz MV, São Paulo State University, Av Prof. Paulo Donato Castellane s/n, CEP: 14884-900, Jaboticabal, São Paulo, Brazil

Email: osirra@hotmail.com



Creative Commons CC-BY-NC: This article is distributed under the terms of the Creative Commons Attribution-NonCommercial 3.0 License (<http://www.creativecommons.org/licenses/by-nc/3.0/>) which permits non-commercial use, reproduction and distribution of the work without further permission provided the original work is attributed as specified on the SAGE and Open Access page (<https://us.sagepub.com/en-us/nam/open-access-at-sage>).

axillary and inguinal lymph nodes was performed by the referring veterinarian. Tubulopapillary mammary carcinoma with metastasis to the axillary lymph node was subsequently diagnosed.

On presentation 4 months later at the veterinary hospital of the São Paulo State University, the cat was bright, alert, responsive and in good body condition. The diagnostic plan included a complete blood count (CBC), serum biochemical panel, abdominal ultrasound and thoracic radiographs. No evidence of metastasis was reported in the image analysis, and the blood test results were also within reference intervals (day 0). Surgical removal of the tumor was performed. The histopathology result was consistent with recurring tubulopapillary mammary carcinoma. After the procedure a single dose of cefovecin (8 mg/kg SC, Convenia; Pfizer) was administered, and a 5 day regimen of tramadol (2 mg/kg PO q8h) and meloxicam (0.1 mg/kg PO q24h) was prescribed. Ten days after surgery the cat was evaluated and a chemotherapy protocol was recommended involving doxorubicin associated with cyclophosphamide (doxorubicin 1 mg/kg IV every 3 weeks and cyclophosphamide 200 mg/m² divided over days 2, 3, 4 and 5).⁹ During the second session, routine CBC showed moderate leukocytosis with neutrophilia (28,400 leukocytes/ μ l with 83% neutrophils). The physical examination revealed no abnormalities, and a normal healing process was observed. Thus, a second prophylactic dose of cefovecin (Convenia; Pfizer) was administered, as the daily

administration of oral medication was difficult for the owner.

After the fourth session of chemotherapy (day 95) the owner reported weight-bearing lameness of the right frontlimb. Physical examination revealed a new nodule on the right axillary region, measuring approximately 2 cm in width and 1 cm in length. The animal lost weight (body weight 3.6 kg) and a normal body temperature was recorded (39.1°C). The lameness observed in the right frontlimb was believed to reflect local invasion of the mass in the axillar region. CBC showed significant leukocytosis (39,500 leukocytes/ μ l with 86% neutrophils), with no evidence of left shift (395 bands/ μ l) and thrombocytosis (683 \times 10³ cells/ μ l). The biochemical profile was normal, and the thoracic radiographs showed no evidence of lung metastasis. Physical examination revealed no signs of infection; however, amoxicillin and clavulanic acid (Clavamox; Pfizer) (20 mg/kg PO q12h for 7 days) and analgesic therapy with tramadol (Dorless V; Agener União) (2 mg/kg PO q8h) were administered.

Considering the poor response, the chemotherapy protocol was changed. A carboplatin/gemcitabine mixed protocol was initiated (carboplatin 10 mg/kg IV every 3 weeks and gemcitabine 2 mg/kg on days 0, 7 and 21).¹⁰

During the following weeks, a gradual and severe increase in the total number of leukocytes with severe neutrophilia (77,700 leukocytes/ μ l with 71% neutrophils and 9% bands) were observed, in addition to an increase in the size of the axillary mass (Table 1).

Table 1 Sequential complete blood count in a cat with paraneoplastic neutrophilic leukocytosis syndrome. Day 0 represents the day upon presentation to oncology service at São Paulo State University (UNESP). A gradual increase in the neutrophil count and size of the mass was evident over time

Parameter	Cat							RI*
	Day 0	Day 95	Day 137	Day 149	Day 158	Day 169	Day 191	
PCV (%)	46.7	36.7	27.8	25.4	28.1	24.6	33.5	24.0–45.0
Hemoglobin (g/dl)	13.8	11.4	9.2	7.8	8.8	7.7	9.8	8.0–14.0
Total red cell count (\times 10 ⁶ / μ l)	10.42	8.27	6.13	5.24	5.14	4.23	6.26	5.5–10.0
White blood cells (/ μ l)	15,000	39,500	40,900	77,700	111,200	59,600	72,200	8000–25,000
Segmented neutrophils (/ μ l)	11,100	33,970	36,400	55,167	95,632	48,276	51,262	2800–17,500
Band neutrophils (/ μ l)	0	395	1636	6993	3336	2980	2166	0–700
Lymphocytes (/ μ l)	2850	2765	1080	4662	6672	2980	7942	1600–13,700
Monocytes (/ μ l)	450	1580	892	4662	2224	1788	4332	0–1000
Eosinophils (/ μ l)	600	790	892	6216	3336	3576	6498	0–3000
Basophils (/ μ l)	0	0	0	0	0	0	0	Rare
Platelets (\times 10 ³ / μ l)	467	683	485	767	333	781	870	300–800
Size of the mass (cm) [†]	0.5	2	3	4.5	5	6	8	

*RIs were taken from Laboratory of Veterinary Clinic Pathology, UNESP Campus of Jaboticabal

[†]Size of the mass measured at its greatest diameter

RI = reference interval; PCV = packed cell volume

Upon physical examination during the follow-up period the animal was not febrile. The diagnostic plan included CBC, blood biochemical profile, urinalysis, radiographs and abdominal ultrasound. The images and blood test results showed no evidence of infection. Nevertheless, to exclude bacterial infection, treatment with metronidazole (20 mg/kg PO q12h) and cefalexin (22 mg/kg PO q12h) was administered. No clinical improvement was observed after 9 days of therapy, and a higher number of neutrophils were present (111,200 leukocytes/ μ l with 86% neutrophils and 3% bands). Therefore, infection was ruled out and antibiotic therapy was suspended.

Bone marrow aspiration was subsequently performed. Cytology analysis revealed a high number of myeloid cells, without any signs of cellular atypia. Additionally, an increased myeloid-to-erythroid ratio (M:E) was

observed, resulting from hypercellularity in the myeloid cell lineage. Based on these results and the absence of bone marrow neoplasia, paraneoplastic leukocytosis was highly suspected. To confirm this suspicion, an incisional biopsy of the right axillary mass was performed.

The histopathology results confirmed recurrent tubulopapillary carcinoma (Figure 1). Immunohistochemical staining was positive for cytokeratin (AE1/AE3) in the majority of the neoplastic epithelial cells, some (25%) stained positive for vimentin and there was a diffuse positive expression for GM-CSF observed in 90% of epithelial cells, favoring the diagnosis of PNLs secondary to recurrent tubular mammary carcinoma.

Upon final diagnosis, amputation of the right frontlimb with complete removal of the mass was suggested; however, the owner decided to euthanize the cat and necropsy was not authorized.

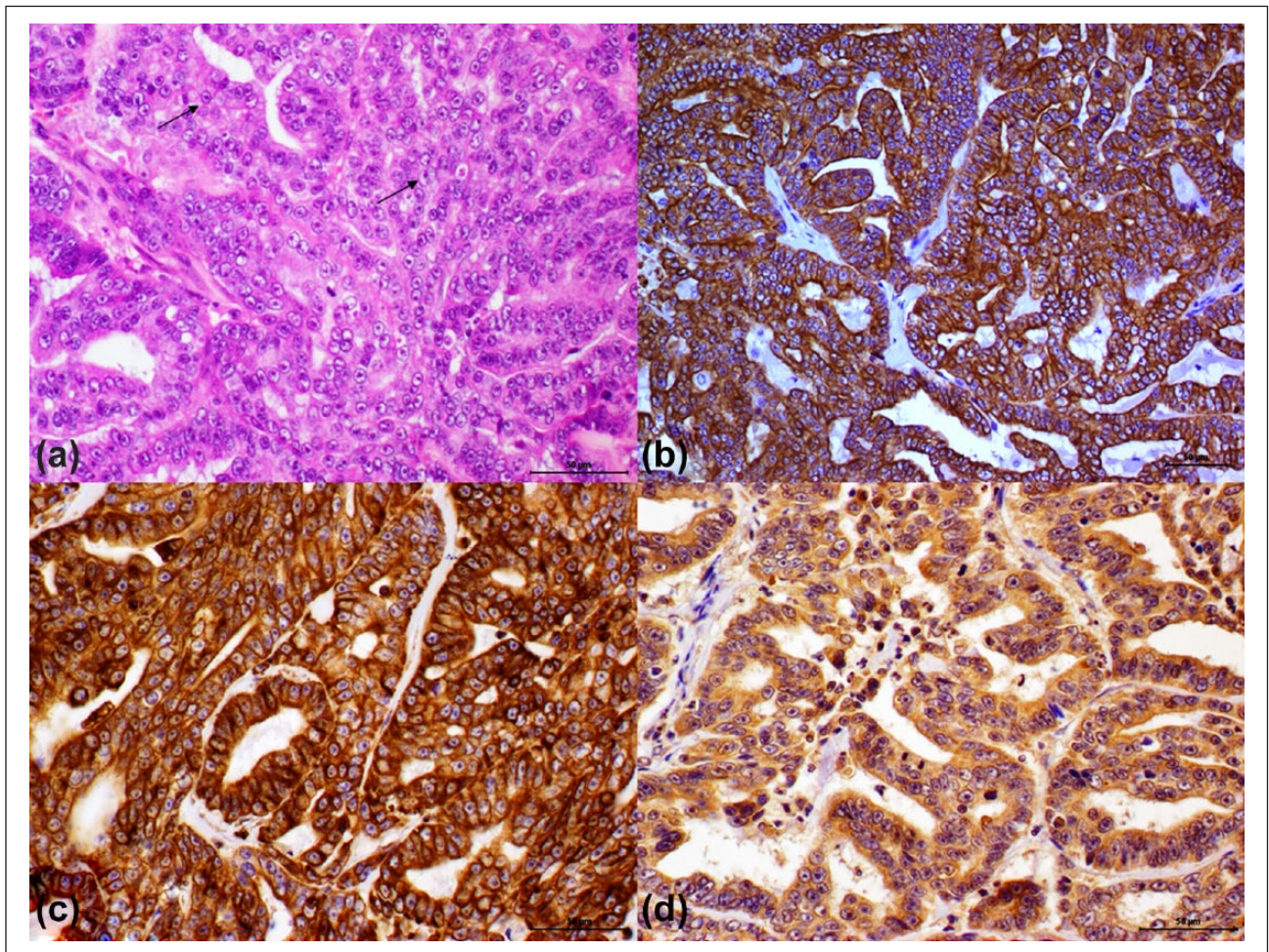


Figure 1 Histopathology and immunohistochemistry of feline mammary neoplasia. (a) A malignant epithelial population is observed with intraluminal proliferation of epithelial cells, showing moderate anisokaryosis and the presence of large nucleoli (arrow) (hematoxylin and eosin, $\times 20$). (b) Strong positive immunohistochemistry expression of malignant epithelial cells (cytokeratin immunohistochemistry stain AE1/AE3, $\times 40$). (c) Positive immunohistochemistry expression of stromal components and some epithelial cells for vimentin. Despite this, no loss of cytokeratin expression in epithelial cells was observed, and some cells showed the heterogeneous expression of this protein (vimentin immunohistochemistry stain, $\times 40$). (d) Positive diffuse immunohistochemistry expression of malignant epithelial cells (granulocyte-macrophage colony-stimulating factor immunohistochemistry stain, $\times 40$)

Discussion

In cats, PNLS has been reported secondary to squamous cell lung carcinoma and dermal adenocarcinoma. Herein, we described an uncommon case of PNLS in a cat secondary to recurrent tubulopapillary carcinoma as the first description of PNLS secondary to a malignant mammary tumor in cats; however, a previous diagnosis of an apocrine gland tumor with PNLS has been described and as mammary tissue is apocrine glandular tissue there could be a similar PNLS response.⁷

According to Stockham,¹¹ there are three major causes of neutrophilic leukocytosis in cats: inflammation, steroid and excitement responses. Nonetheless, other important causes have also been described, including immune-mediated disorders, necrosis, bone marrow neoplasia and paraneoplastic syndrome.^{8,12} In this case, infection was ruled out as there were no typical signs of infection and the total neutrophil count was not altered, even after antibiotic therapy. The animal was not febrile, and radiographic and ultrasound examinations revealed no abnormalities. The sustained and dramatic neutrophilia without significant lymphocytosis ruled out physiologic responses because lymphocytosis is a prominent feature of the feline excitement response.¹¹ Corticosteroids were not administered to the animal; thus, a steroid response as the cause of neutrophilia was also excluded.

Neutrophils play an important and active role in autoimmune disorders.¹³ Autoimmune diseases are generally recognized by the presence of other alterations, such as regenerative anemia, polyarthritis, skin lesions and other organ system dysfunctions.⁷ These alterations were not present in the animal described in the present study. Additionally, leukocytosis due to necrosis was also excluded, as this condition was not observed upon histologic evaluation of the mass.

The empiric antibiotic therapy used in an immunosuppressed animal after chemotherapy has the potential risk of developing antibiotic-resistant bacterial strains. Bacterial culture of the tissue to determine bacterial infection should be done, but in this case no material was available for culture.

The results of the bone marrow evaluation were compatible with granulocytic hyperplasia. The primary differential diagnosis was chronic myeloid leukemia (CML), characterized by an increase in the total number of mature neutrophils in the blood in response to the increased production of these cells in bone marrow and, typically, this excessive production occurs in response to an autonomous bone marrow stimulus.¹¹ However, as demonstrated in this case of PNLS, the malignant tumor cells secrete granulocyte colony-stimulating factor (G-CSF) or GM-CSF that excessively stimulates the bone marrow. Thus, bone marrow examination would not be helpful in the discrimination of CML from PLNS, as both of these diseases stimulate bone marrow and produce marked granulocytic hyperplasia with an increased M:E ratio.^{11,14}

The precise origin of PNLS in medicine is not readily understood; however, in dogs and cats the production of G-CSF or GM-CSF from tumor cells might represent a potential mechanism.³ PCR and immunohistochemistry have been used as confirmatory methods of the positive expression of these proteins from tumor cells.^{2,7} In this case, immunohistochemical staining for GM-CSF confirmed PNLS.

The overexpression of vimentin in neoplastic epithelial cells has been associated with the phenotypic transformation of malignant epithelial cells into mesenchymal cells, known as the epithelial–mesenchymal transition (EMT), which increases the invasiveness and metastatic potential of malignant epithelial cells.^{15,16} In feline mammary carcinoma, EMT has been associated with an invasive phenotype.¹⁷

The resolution of severe leukocytosis in PNLS is achieved after the complete excision of the tumor in cases with no evidence of metastatic masses.^{4,5} In one of the two cases reported in cats, the total number of leukocytes returned to normal values within 6 weeks of removing the pulmonary squamous cell carcinoma.⁸ Thus, the complete removal of the tumor is the only treatment reported for PNLS in veterinary medicine. Nevertheless, we believe that other therapeutic modalities like radiotherapy, although not yet described, should have the same effect as complete removal. Unfortunately, this therapy was not available for this cat.

In the case presented herein, severe leukocytosis was observed for several weeks and aggressive surgery was proposed after final diagnosis; however, the cat was euthanized at the request of the owner. PNLS, though rare, could be associated with recurrent mammary tumors in cats, and should be considered in the differential diagnosis of severe neutrophilia in cats presenting mammary masses.

Conclusions

This report describes a unique syndrome of PNLS associated with mammary carcinoma in the cat. Immunohistochemical expression of GM-CSF in the tumor and the absence of systemic infection support the neoplastic process as the cause of the leukocytosis.

Funding The authors received no specific grant from any funding agency in the public, commercial or not-for-profit sectors for the preparation of this case report/case series/short communication.

Conflict of interest The authors declared no potential conflicts of interest with respect to the research, authorship, and/or publication of this article.

References

- 1 Elliott J. Paraneoplastic syndromes in dogs and cats. *In Pract* 2014; 36: 443–452.

- 2 Peeters D, Clercx C, Thiry A, et al. **Resolution of paraneoplastic leukocytosis and hypertrophic osteopathy after resection of a renal transitional cell carcinoma producing granulocyte-macrophage colony-stimulating factor in a young Bull Terrier.** *J Vet Intern Med* 2001; 15: 407–411.
- 3 Petterino C, Luzio E, Baracchini L, et al. **Paraneoplastic leukocytosis in a dog with a renal carcinoma.** *Vet Clin Pathol* 2011; 40: 89–94.
- 4 Lappin MR and Lattimer KS. **Hematuria and extreme neutrophilic leukocytosis in a dog with renal tubular carcinoma.** *J Am Vet Med Assoc* 1988; 192: 1289–1292.
- 5 Thompson JP, Christopher MM, Ellison GW, et al. **Paraneoplastic leukocytosis associated with a rectal adenomatous polyp in a dog.** *J Am Vet Med Assoc* 1992; 201: 737–738.
- 6 Chinn DR, Myers RK and Matthews JA. **Neutrophilic leukocytosis associated with metastatic fibrosarcoma in a dog.** *J Am Vet Med Assoc* 1985; 186: 806–809.
- 7 Sharkey LC, Rosol TJ, Grone A, et al. **Production of granulocyte colony-stimulating factor and granulocyte-macrophage colony stimulating factor by carcinomas in a dog and a cat with paraneoplastic leukocytosis.** *J Vet Intern Med* 1996; 10: 405–408.
- 8 Dole RS, MacPhail CM and Lappin MR. **Paraneoplastic leukocytosis with mature neutrophilia in a cat with pulmonary squamous cell carcinoma.** *J Feline Med Surg* 2004; 6: 391–395.
- 9 Mauldin GN, Matus RE, Patnaik AK, et al. **Efficacy and toxicity of doxorubicin and cyclophosphamide used in the treatment of selected malignant tumors in 23 cats.** *J Vet Intern Med* 1988; 2: 60–65.
- 10 Martinez-Ruzafa I, Dominguez PA, Dervis NG, et al. **Tolerability of gemcitabine and carboplatin doublet therapy in cats with carcinomas.** *J Vet Intern Med* 2009; 23: 570–577.
- 11 Stockham SL, Keeton KS and Szladovits B. **Clinical assessment of leukocytosis: distinguishing leukocytoses caused by inflammatory, glucocorticoid, physiologic, and leukemic disorders or conditions.** *Vet Clin North Am Small Anim Pract* 2003; 33: 1335–1357.
- 12 Lucroy MD and Madewell BR. **Clinical outcome and diseases associated with extreme neutrophilic leukocytosis in cats: 104 cases (1991–1999).** *J Am Vet Med Assoc* 2001; 218: 736–739.
- 13 Németh T and Mócsai A. **The role of neutrophils in autoimmune diseases.** *Immunol Lett* 2012; 143: 9–19.
- 14 Mochizuki H, Seki T, Nakahara Y, et al. **Chronic myelogenous leukaemia with persistent neutrophilia, eosinophilia and basophilia in a cat.** *J Feline Med Sur* 2014; 16: 517–521.
- 15 Kokkinos M I, Wafai R, Wong MK, et al. **Vimentin and epithelial-mesenchymal transition in human breast cancer – observations in vitro and in vivo.** *Cells Tissues Organs* 2007; 185: 191–203.
- 16 Yamashita N, Tokunaga E, Kitao H, et al. **Vimentin as a poor prognostic factor for triple-negative breast cancer.** *J Cancer Res Clin Oncol* 2013; 139: 739–746.
- 17 Ly P, Blacking TM, Else RW, et al. **Feline mammary carcinoma stem cells are tumorigenic, radioresistant, chemoresistant and defective in activation of the ATM/p53 DNA damage pathway.** *Vet J* 2013; 196: 414–423.