



## **Persistent right aortic arch with an aberrant left subclavian artery, Kommerell's diverticulum and bicarotid trunk in a 3-year-old cat**

Authors: Shannon, Dylan, Husnik, Roman, Fletcher, Jon M, Middleton, Grant, and Gaschen, Lorrie

Source: Journal of Feline Medicine and Surgery Open Reports, 1(2)

Published By: SAGE Publishing

URL: <https://doi.org/10.1177/2055116915614590>

---

BioOne Complete ([complete.BioOne.org](https://complete.BioOne.org)) is a full-text database of 200 subscribed and open-access titles in the biological, ecological, and environmental sciences published by nonprofit societies, associations, museums, institutions, and presses.

Your use of this PDF, the BioOne Complete website, and all posted and associated content indicates your acceptance of BioOne's Terms of Use, available at [www.bioone.org/terms-of-use](http://www.bioone.org/terms-of-use).

Usage of BioOne Complete content is strictly limited to personal, educational, and non - commercial use. Commercial inquiries or rights and permissions requests should be directed to the individual publisher as copyright holder.

---

BioOne sees sustainable scholarly publishing as an inherently collaborative enterprise connecting authors, nonprofit publishers, academic institutions, research libraries, and research funders in the common goal of maximizing access to critical research.



# Persistent right aortic arch with an aberrant left subclavian artery, Kommerell's diverticulum and bicarotid trunk in a 3-year-old cat

*Journal of Feline Medicine and Surgery*  
*Open Reports*  
 1–4

© The Author(s) 2015  
 Reprints and permissions:  
[sagepub.co.uk/journalsPermissions.nav](http://sagepub.co.uk/journalsPermissions.nav)  
 DOI: 10.1177/2055116915614590  
[jfmsopenreports.com](http://jfmsopenreports.com)



Dylan Shannon, Roman Husnik, Jon M Fletcher,  
 Grant Middleton and Lorrie Gaschen

## Abstract

**Case summary** A 3-year-old male, neutered, domestic shorthair cat with a history of chronic regurgitation since being obtained as a kitten was presented for weight loss and regurgitation of all ingested food. The cat was in poor body condition and had a firm swelling in the ventral neck at the time of presentation. Thoracic radiographs showed severe dilation of the entire cervical and cranial intrathoracic esophagus to the level of the heart base. Computed tomographic angiography (CTA) showed a persistent right aortic arch with an aberrant left subclavian artery and severe dilation of the cervical and intrathoracic esophagus cranial to the heart base. CTA also showed a bicarotid trunk and Kommerell's diverticulum to be present, which are rare vascular structures in the cat. Esophagoscopy showed esophageal dilation and multiple compact trichobezoars obstructing the esophagus. Removal of the obstructing trichobezoars resulted in resolution of clinical signs, and the cat was able to drink water and eat a canned food slurry without regurgitation. Surgical correction was not pursued.

**Relevance and novel information** Vascular ring anomaly (VRA) should be considered in all cats with a history of regurgitation, regardless of their age at the time of presentation. CTA is a valuable diagnostic imaging procedure that allows differentiation of a VRA from other causes of esophageal obstruction and provides information about the VRA that can be used to determine amenability to surgical correction.

**Accepted:** 2 October 2015

## Case description

A 3 year-old male, neutered, domestic shorthair cat was presented with a 2 week history of severe regurgitation of all ingested food. The cat had a history of a voracious appetite and regurgitation of solid food since being acquired as a kitten, but was able to consume liquid meals without regurgitating until 2 weeks prior to presentation.

The physical examination revealed a poor body condition score (BCS 2/9) and a 4 cm firm tubular structure in the ventral neck, believed to be within or associated with the esophagus. The remainder of the examination was unremarkable. As a result of the cat's fractious nature, it was necessary to induce general anesthesia for further evaluation. Thoracic radiographs showed severe distention of the entire cervical and intrathoracic esophagus to the level of the heart base with heterogeneous

soft tissue opaque material surrounded by a thin gas rim (Figure 1). Differentials for the radiographic findings were constriction due to a vascular ring anomaly (VRA), most commonly a persistent right aortic arch, a mural defect or benign esophageal stricture.

Computed tomographic angiography (CTA) was performed in order to confirm and classify the suspected VRA and to determine if surgical correction would be possible. The esophagus cranial to the heart base was almost entirely

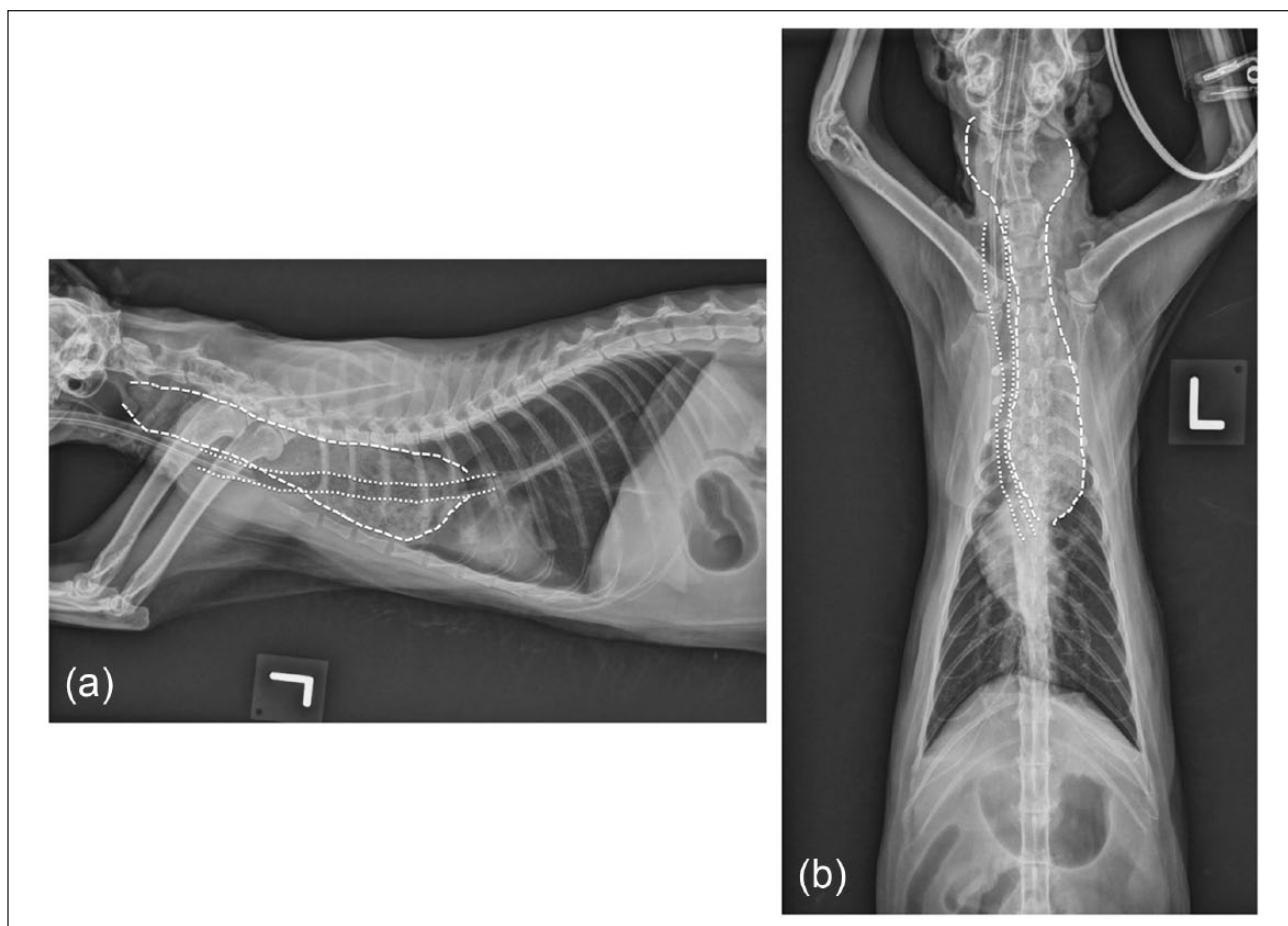
Department of Veterinary Clinical Sciences, Louisiana State University School of Veterinary Medicine, Baton Rouge, LA, USA

### Corresponding author:

Jon M Fletcher DVM, DACVIM, Department of Veterinary Clinical Sciences, Louisiana State University School of Veterinary Medicine, Skip Bertman Drive, Baton Rouge, LA 70810, USA  
 Email: [jmfletcher@lsu.edu](mailto:jmfletcher@lsu.edu)



Creative Commons CC-BY-NC: This article is distributed under the terms of the Creative Commons Attribution-NonCommercial 3.0 License (<http://www.creativecommons.org/licenses/by-nc/3.0/>) which permits non-commercial use, reproduction and distribution of the work without further permission provided the original work is attributed as specified on the SAGE and Open Access page (<https://us.sagepub.com/en-us/nam/open-access-at-sage>).



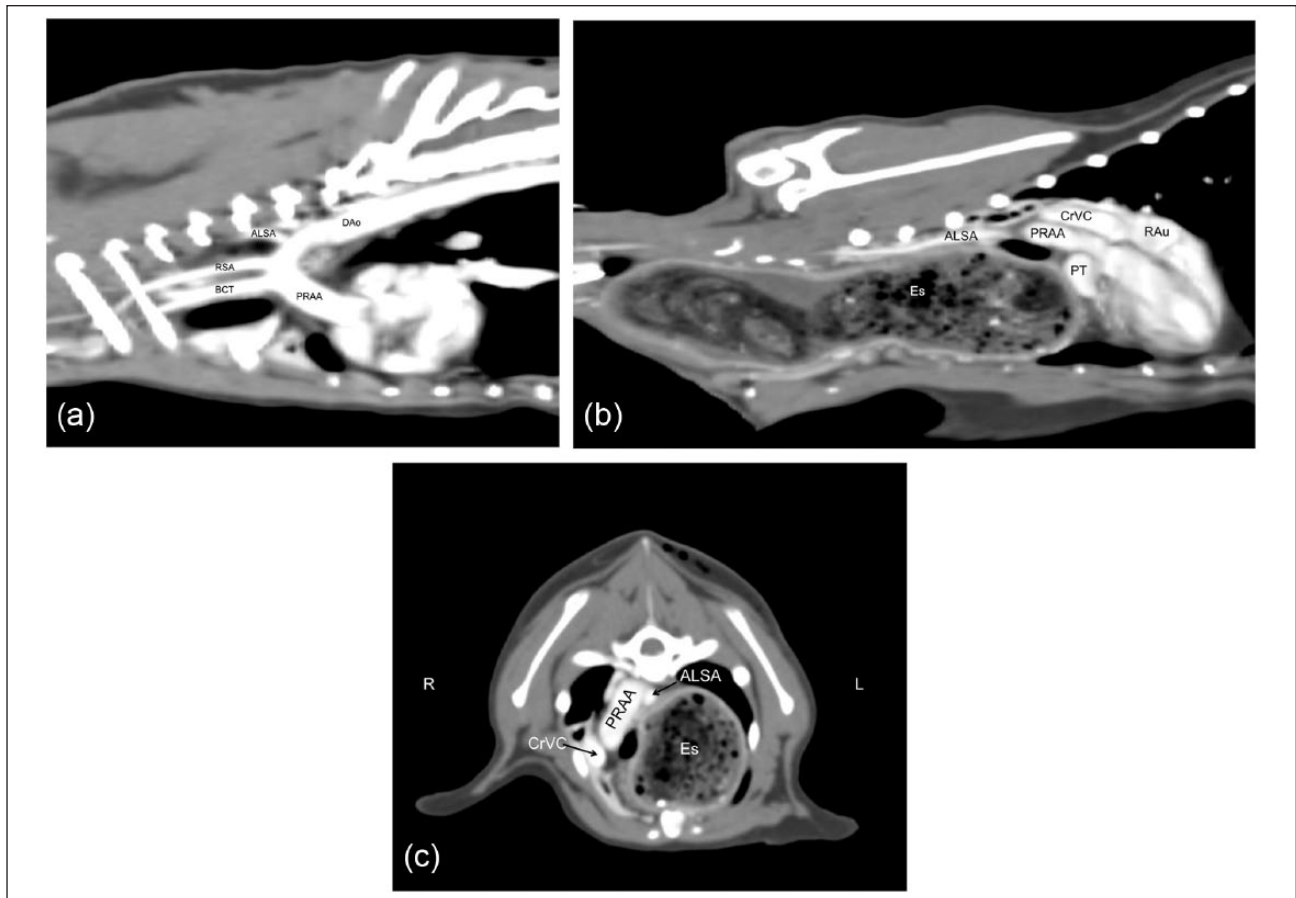
**Figure 1** (a) Left lateral and (b) ventrodorsal thoracic radiographs. The cervical and thoracic esophagus (dashed lines) is severely distended cranial to the carina, displacing the trachea (dotted lines) ventrally and to the right. Note the marked leftward deviation of the trachea at the level of the heart base

filled with heterogeneous soft tissue, gas and mineral opaque material. At the level of the heart base, the esophagus was focally and concentrically narrowed by the trachea and aorta on the right and the main pulmonary artery on the left. The site of constriction was apparent at the anatomic level of the ligamentum arteriosum; however, the ligamentum arteriosum could not be specifically identified on CTA. The aortic arch and proximal descending aorta were located just to the right of midline, with the distal descending aorta positioned immediately ventral to the thoracic spine. A bicarotid trunk and right subclavian artery were present, and branched from the aortic arch in close succession. The left subclavian artery branched aberrantly from the proximal descending aorta. Additionally, the origin of the aberrant left subclavian artery from the aorta was markedly dilated and then abruptly narrowed distally to a normal diameter; this finding is known as Kommerell's diverticulum.<sup>1</sup> Although the aberrant left subclavian artery created a dorsal indentation in the intrathoracic esophagus, it did not appear to be the primary cause of the constriction. Three-dimensional reconstruction of the CTA confirmed a type III VRA.<sup>2</sup>

Esophagoscopy was performed and multiple compact trichobezoars were removed. The esophagus remained dilated cranial to the level of the constriction and pulsation of the major vessels against the wall of the esophagus was observed at the level of the luminal narrowing (see video in the Supplementary material). Evidence of mild-to-moderate esophagitis, presumably due to stagnation of trichobezoars and putrefaction of food, was observed cranial to the constriction. It was possible to advance the endoscope past the constriction and no gross abnormalities were noted in the stomach.

Following recovery from anesthesia, the cat was able to drink water and eat a canned food slurry without complication or regurgitation. Surgical ligation and transection of the vascular ring anomaly with concurrent endoscopic balloon dilatation of the esophageal stricture was recommended as the treatment of choice. The owner elected not to pursue further treatment at that time. The cat was discharged with instructions to continue feeding a canned food slurry in an upright position.

The owner was contacted prior to submission and reported that the cat was doing well with multiple small



**Figure 2** Computed tomographic angiogram. (a,b) Parasagittal and (c) axial planes. Structures of note include the persistent right aortic arch (PRAA), bicarotid trunk (BCT), right subclavian artery (RSA), aberrant left subclavian artery (ALSA), descending aorta (DAo), esophagus (Es), cranial vena cava (CrVC), pulmonary trunk (PT) and right auricle (RAu)

feedings of canned food and had not regurgitated since discharge.

## Discussion

Although VRAs are common in dogs, with several reports of diagnosis in adult dogs,<sup>3,4</sup> they are uncommon in cats and infrequently diagnosed in adult cats. The most common feline VRA is persistent right aortic arch (PRAA) with a left ligamentum arteriosum; however, other described abnormalities include PRAA with coarctation of the aorta at the level of the left ligamentum arteriosum,<sup>5</sup> double aortic arch,<sup>6–8</sup> left aortic arch with right ligamentum arteriosum<sup>9,10</sup> and PRAA with concurrent left cranial vena cava.<sup>11</sup> VRAs have also been described in non-domestic felids.<sup>6,12,13</sup>

Recently, CTA has become more widely available as a diagnostic modality and has increased the frequency and accuracy of diagnosis. CTA proved valuable in this adult cat as it could confirm a congenital defect was present as the cause of the esophageal constriction and allow a surgical procedure to be planned. The vascular abnormality known as Kommerell's diverticulum has only recently been described in cats.<sup>1</sup> This vascular

structure is classically defined as a dilation of the aorta at the insertion of either the left or right subclavian artery that is 1.5 times greater than the diameter of the distal subclavian artery.<sup>14</sup> The presence of a bicarotid trunk branching directly from the aortic arch in this cat is also an unusual finding.

The treatment of choice for VRAs in companion animals is surgical ligation and transection of the anomalous vessel(s). If possible, periesophageal fibrosis should be reduced, and the stricture site should be dilated intraluminally with a balloon dilatation catheter.<sup>15</sup> This procedure has traditionally been performed via a thoracotomy, but thoracoscopy has also been used, and offers a less invasive treatment option.<sup>16</sup> Ligation and transection of the aberrant left subclavian artery can also be performed if the vessel contributes to the esophageal constriction. In an effort to decrease the severity of esophageal dilation and dysfunction, it is recommended that surgical intervention not be delayed following confirmation of the diagnosis. Although surgical correction is the treatment of choice, clinical signs may persist even after a successful procedure. Esophageal dilation may cause irreversible myenteric nerve degeneration and esophageal

hypomotility; however, a 90% or greater recovery rate has been reported in dogs.<sup>17</sup>

Nutritional management is critical in the postoperative period but is rarely successful as a primary treatment for VRA. Many of these patients require lifetime management with elevated feedings of canned or puréed food in small meals, but it is possible to transition those with less severe obstructions to a more solid diet. In cases of severe esophageal dysfunction or malnutrition, a gastrostomy tube may be necessary to achieve adequate nutritional supplementation.<sup>18</sup>

## Conclusions

Congenital causes of esophageal obstruction should be considered in cats presented with a history of regurgitation, regardless of age at the time of presentation. CTA confirmed the presence of an extraluminal constriction and provided valuable information about the vascular anomaly in the event that surgical correction would have been pursued. Surgical removal of the extraluminal constriction with balloon dilatation of the esophageal stricture was recommended and is considered the treatment of choice. However, considering the guarded prognosis for return of normal esophageal function in an adult cat with chronic esophageal dilation, medical management provided a viable alternative for this cat.

**Supplementary material** A video is available online showing extraluminal pulsating structures observed at the level of the esophageal constriction via endoscopy after trichobezoar removal.

**Funding** The authors received no financial support for the research, authorship, and/or publication of this article.

**Conflict of interest** The authors declared no potential conflicts of interest with respect to the research, authorship, and/or publication of this article.

## References

- Henjes CR, Nolte I and Wefstaedt P. **Multidetector-row computed tomography of thoracic aortic anomalies in dogs and cats: patent ductus arteriosus and vascular rings.** *BMC Vet Res* 2011; 7: 57. <http://dx.doi.org/10.1186/1746-6148-7-57>
- Helphrey M. **Vascular ring anomalies.** In: Bojrab MJ (ed). *Disease mechanisms in small animal surgery*. 2nd ed. Philadelphia, PA: Lea & Febiger, 1993, pp 350–254.
- Imhoff RK and Foster WJ. **Persistent right aortic arch in a 10 year old dog.** *J Am Vet Med Assoc* 1963; 143: 599–601.
- Fingerroth JM and Fossum TW. **Late-onset regurgitation associated with persistent right aortic arch in two dogs.** *J Am Vet Med Assoc* 1987; 191: 981–983.
- White RN, Burton CA and Hale JS. **Vascular ring anomaly with coarctation of the aorta in a cat.** *J Small Anim Pract* 2003; 44: 330–334. <http://dx.doi.org/10.1111/j.1748-5827.2003.tb00164.x>
- Ketz CJ, Radlinsky M, Armbrust L, et al. **Persistent right aortic arch and aberrant left subclavian artery in a white Bengal tiger (*Panthera tigris*).** *J Zoo Wildl Med* 2001; 32: 268–272. [http://dx.doi.org/10.1638/1042-7260\(2001\)032\[0268:praaa\]2.0.co;2](http://dx.doi.org/10.1638/1042-7260(2001)032[0268:praaa]2.0.co;2)
- Yarim M, Gültiken ME, Oztürk S, et al. **Double aortic arch in a Siamese cat.** *Vet Pathol* 1999; 36: 340–341. <http://dx.doi.org/10.1354/vp.36-4-340>
- van der Linde-Sipman JS, van den Ingh TS and Koeman JP. **Congenital heart abnormalities in the cat - a description of 16 cases.** *Zentralbl Veterinarmed A* 1973; 20: 419–425.
- McCandlish IA, Nash AS and Peggram A. **Unusual vascular ring in a cat – left aortic arch with right ligamentum arteriosum.** *Vet Rec* 1984; 114: 338–340. <http://dx.doi.org/10.1136/vr.114.14.338>
- van der Linde-Sipman JS and van de Gaag I. **Vascular ring caused by a left aortic arch, right ligamentum arteriosum, and part of the right dorsal aorta in a cat.** *Zentralbl Veterinarmed A* 1981; 28: 569–573. <http://dx.doi.org/10.1111/j.1439-0442.1981.tb01228.x>
- Wheaton LG, Blevins WE and Weirich WE. **Persistent right aortic arch associated with other vascular anomalies in two cats.** *J Am Vet Med Assoc* 1984; 184: 848–851.
- Goldin JP and Lambrechts NE. **Double aortic arch and persistent left vena cava in a white lion cub (*Panthera leo*).** *J Zoo Wildl Med* 1999; 30: 145–150.
- Rochat MC and Settles E. **Persistent right aortic arch in a cougar (*Felis concolor*).** *J Zoo Wildl Med* 1993; 24: 534–538.
- Tanaka A, Milner R and Ota T. **Kommerell's diverticulum in the current era: a comprehensive review.** *Gen Thorac Cardiovasc Surg* 2015; 63: 245–259. <http://dx.doi.org/10.1007/s11748-015-0521-3>
- Washabau RJ. **Diseases of the esophagus.** In: Ettinger SJ and Feldman EC (eds). *Textbook of veterinary internal medicine*. 5th ed. Philadelphia, PA: WB Saunders, 2000, pp 1142–1153.
- Plesman R, Johnson M, Rurak S, et al. **Thoracoscopic correction of a congenital persistent right aortic arch in a young cat.** *Can Vet J* 2011; 52: 1123–1128.
- Muldoon MM, Birchard SJ and Ellison GW. **Long-term results of surgical correction of persistent right aortic arch in dogs: 25 cases (1980–1995).** *J Am Vet Med Assoc* 1997; 210: 1761–1763.
- Jeffrey SC, Bataller N and Martin RA. **The post-surgical nutritional management of megaesophagus secondary to persistent right aortic arch in a kitten.** *Feline Pract* 1995; 23: 17–23.