



## **Adrenocortical tumor in a cat secreting more than one type of corticosteroid**

Authors: Guerios, Simone Domit, Souza, Carlos Henrique de Melo, and Bacon, Nicholas J

Source: Journal of Feline Medicine and Surgery Open Reports, 1(2)

Published By: SAGE Publishing

URL: <https://doi.org/10.1177/2055116915617970>

---

BioOne Complete ([complete.BioOne.org](https://complete.BioOne.org)) is a full-text database of 200 subscribed and open-access titles in the biological, ecological, and environmental sciences published by nonprofit societies, associations, museums, institutions, and presses.

Your use of this PDF, the BioOne Complete website, and all posted and associated content indicates your acceptance of BioOne's Terms of Use, available at [www.bioone.org/terms-of-use](http://www.bioone.org/terms-of-use).

Usage of BioOne Complete content is strictly limited to personal, educational, and non - commercial use. Commercial inquiries or rights and permissions requests should be directed to the individual publisher as copyright holder.

---

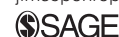BioOne sees sustainable scholarly publishing as an inherently collaborative enterprise connecting authors, nonprofit publishers, academic institutions, research libraries, and research funders in the common goal of maximizing access to critical research.



# Adrenocortical tumor in a cat secreting more than one type of corticosteroid

*Journal of Feline Medicine and Surgery*  
*Open Reports*  
 1–5

© The Author(s) 2015  
 Reprints and permissions:  
[sagepub.co.uk/journalsPermissions.nav](http://sagepub.co.uk/journalsPermissions.nav)  
 DOI: 10.1177/2055116915617970  
[jfmsopenreports.com](http://jfmsopenreports.com)



**Simone Domit Guerios<sup>1</sup>, Carlos Henrique de Melo Souza<sup>2</sup>  
 and Nicholas J Bacon<sup>2</sup>**

## Abstract

**Case summary** A 14-year-old, spayed female domestic shorthair cat was evaluated because of a right adrenal mass. The referring veterinarian had started treatment for hypokalemia and systemic arterial hypertension. During the initial evaluation the cat was alert and responsive, and serum potassium concentration was within the reference range. Serum concentrations of aldosterone and progesterone were increased. Atrophy of the contralateral adrenal and an exaggerated response of cortisol to stimulation with adrenocorticotrophic hormone suggested hypersecretion of cortisol. Unilateral adrenalectomy was performed and recovery was uneventful. Histologic examination of the mass revealed an adrenocortical tumor. After surgery, clinical signs of hypercortisolism, hyperaldosteronism and hyperprogesteronism were no longer observed, and neither potassium supplementation nor antihypertensive treatment were needed.

**Relevance and novel information** In cases with an adrenocortical tumor, clinicians should investigate whether the tumor hypersecretes glucocorticoids, mineralocorticoids, sex steroids or combinations of these. Hypersecretion of more than one adrenal hormone may occur in a cat with an adrenocortical tumor.

**Accepted:** 23 October 2015

A 14-year-old, 4.02 kg, spayed female domestic shorthair cat was referred to the Oncology Service at the University of Florida Small Animal Hospital with an 8 month history of increased vocalization, urination, food and water intake, and two episodes of hematuria. The referring veterinarian identified a right adrenal mass (3.57 cm × 2.71 cm) on ultrasound (Figure 1), and cytology of the mass was consistent with adrenocortical tumor. At the time of presentation, the cat was being medicated with amlodipine (1.5 mg PO q24h) for hypertension and with a potassium supplement (Tumil-K Powder 4 mEq PO q24h) for hypokalemia.

At presentation the cat was alert and responsive. Physical examination revealed tachycardia (220 beats/min) with a gallop rhythm and synchronous femoral pulse. The cat had a cardiovascular consult, which revealed no abnormalities (including hypertrophy). Capillary refill time was < 2 s and the respiratory rate was 35 breaths/min. A pendulous abdomen, prominent

dermal blood vessels and muscle atrophy along the epaxial muscles were observed. A complete blood count showed mild neutrophilia ( $13 \times 10^3/\mu\text{l}$ ; reference interval [RI] 2.3–9.8 × 10<sup>3</sup>/μl) and lymphopenia ( $0.43 \times 10^3/\mu\text{l}$ ; RI 0.9–5.5 × 10<sup>3</sup>/μl). Serum biochemical abnormalities included hyperglycemia (171 mg/dl; RI 70–140 mg/dl), mild decrease in alanine aminotransferase activity (27 U/l; RI 32–83 U/l), and normal potassium

<sup>1</sup>Department of Veterinary Medicine, Federal University of Parana, Parana, Brazil

<sup>2</sup>Department of Small Animal Clinical Sciences, University of Florida, Gainesville, FL, USA

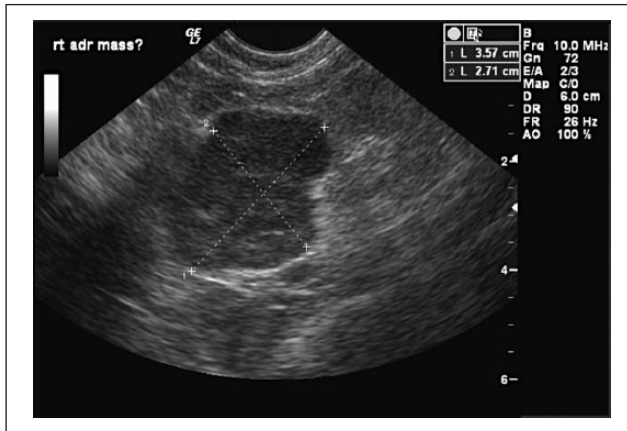
### Corresponding author:

Simone Domit Guerios, Associate Professor, DVM, PhD, Department of Veterinary Medicine, Federal University of Parana, Rua dos Funcionários, 1540 – Cabral – 80035-050, Curitiba, Parana, Brazil  
 Email: [sdguerios@gmail.com](mailto:sdguerios@gmail.com)



Creative Commons CC-BY-NC: This article is distributed under the terms of the Creative Commons Attribution-NonCommercial 3.0 License (<http://www.creativecommons.org/licenses/by-nc/3.0/>) which permits non-commercial use, reproduction and distribution of the work without further permission provided the original work is attributed as specified on the SAGE and Open Access page (<https://us.sagepub.com/en-us/nam/open-access-at-sage>).

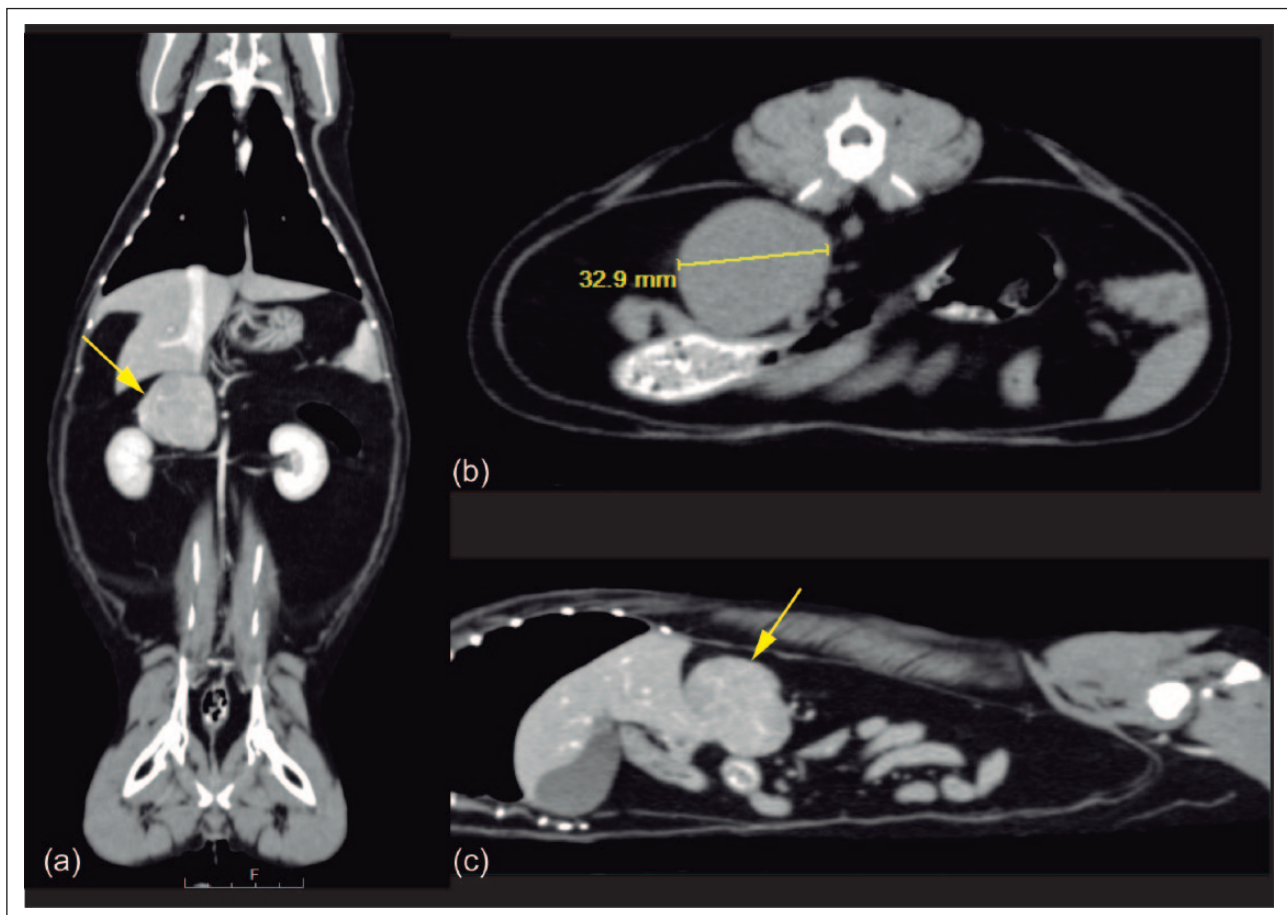
(3.9 mEq/l; RI 3.5–5.0 mEq/l). Urine specific gravity was 1.019 and urinalysis was otherwise unremarkable. Venous blood gas analysis was consistent with a



**Figure 1** A sagittal ultrasonographic image of the right adrenal gland showing a mass (3.57 cm × 2.71 cm) of mixed echogenicity

metabolic alkalosis (pH 7.341, HCO<sub>3</sub> 29.2 mmol/l) with respiratory compensation (partial pressure of carbon dioxide 53.4 mmHg). Subsequent venous blood gas analyses were in the normal range for cats. Computed tomography of the abdomen and thorax identified the left adrenal gland < 5 mm and the right adrenal gland as a 3.8 × 3.2 × 2.8 cm mass, which caused ventromedial deviation of the vena cava, as well as caudal displacement of the right renal artery and vein (Figure 2). There was no evidence of local vascular invasion or pulmonary metastasis.

An adrenocorticotropin hormone stimulation test (ACTH-ST) was performed. The baseline cortisol concentration was 6.59 µg/dl (RI 0.8–5.0 µg/dl) and 1 h postcortisol concentration was 20.0 µg/dl (RI 3.6–10.0 µg/dl). A blood sample was submitted to the University of Tennessee for measurement of adrenal sex hormone concentration. The endocrinology panel showed an increased concentration of aldosterone (> 1376 ng/ml; RI 11.3–294.3 ng/ml) and progesterone (2.59 ng/ml; RI 0.03–0.40 ng/ml). Normal levels of 17 OH progesterone (0.12 ng/ml; RI 0.08–0.20 ng/ml), androstenedione



**Figure 2** Representative computed tomography of the abdomen showing the right adrenal mass (arrow). (a) Coronal, (b) axial and (c) sagittal planes

(0.20 ng/ml; RI 0.1–0.3 ng/ml) and testosterone (0.02 ng/ml; RI 0.02–0.30 ng/ml) were observed; estradiol concentration was 27.3 pg/ml (RI 50.3–84.0 pg/ml) and cortisol was 2.1 ng/ml (reference range 5.2–54.4 ng/ml).

A presumptive diagnosis of a cortisol, aldosterone and progesterone co-secreting tumor of the right adrenal gland was made. With no signs of macroscopic metastasis or vena cava invasion, adrenalectomy was considered the treatment of choice. The calcium channel blocker (amlodipine) and the potassium supplement were discontinued immediately prior to surgery. General anesthesia was induced with propofol (6 mg/kg IV) and was maintained with isoflurane and fentanyl in 100% oxygen. Postoperative analgesia was maintained with methadone (0.3mg/kg IV q4h) and buprenorphine (0.1 mg/kg IV q6h). A dose of dexamethasone (1 mg/kg IV) was slowly administered during surgery. A right adrenalectomy was performed without complications; the adrenal mass seemed encapsulated and it was closely associated with the vena cava. The phrenicoabdominal vein was doubly clipped and transected; the tumor was excised with a combination of blunt dissection and electrocautery. No gross metastasis was observed to other abdominal organs and the left adrenal gland was considered grossly atrophied. Histopathology of the right adrenal gland was consistent with an adrenocortical tumor. Anisocytosis and anisokaryosis are mild to moderate, and one mitotic figure was observed in ten 400× fields. Postoperative therapy consisted of intravenous (IV) fluid therapy (lactated Ringer's solution at 10 ml/h), methadone (0.3 mg/kg IV q3–6h), amoxicillin and clavulanic acid (15 mg/kg IV or PO q12h) and one dose of desoxycorticosterone pivalate (DOCP; 2 mg/kg SC).

Twenty-four hours after surgery, venous blood gas analysis (pH 7.411) and blood pressure (90 mmHg) were in the normal range. Serum biochemical was unremarkable (blood glucose 134 mg/dl [RI 70–140 mg/dl]; potassium 3.54 mEq/l [RI 3.5–5.0 mEq/l]; sodium 154.9 mEq/l [RI 148–156 mEq/l]; creatinine 1.6 mg/dl [RI 1.0–2.1 mg/dl]; blood urea nitrogen 37 mg/dl [RI 17–40 mg/dl]). An ACTH-ST was performed, which showed a baseline cortisol concentration of <0.1 µg/dl (RI 0.8–5.0 µg/dl), and 1 hour postcortisol concentration was 0.146 µg/dl (RI 3.6–10.0 µg/dl), indicating a need for corticosteroid supplementation. The cat received one dose of DOCP (2.2 mg/kg SC) and oral administration of prednisolone solution (0.2 mg/kg q12h) was started as the cat was eating and drinking. The cat was discharged 4 days after surgery, with an improved attitude and appetite. On the day of discharge serum biochemical analysis showed hypokalemia (2.8 mEq/l; RI 3.5–5.0 mEq/l), normal systolic blood pressure (115 mmHg) and normal venous blood gas analysis (pH 7.406). The owner was instructed to start oral potassium supplementation and to maintain oral prednisolone.

Over the following 2 weeks, the cat showed progressive clinical improvement with normal food intake and a good activity level at home. Three weeks after surgery, potassium supplementation was discontinued as serum potassium concentration was consistently within the RI (between 4.1 and 4.5 mmol/l; RI 3.5–5.8 nmol/l) and aldosterone concentration was less than the RI (112 pmol/l; RI 194–338 pmol/l), and prednisolone were gradually tapered down and it was discontinued. Eighteen months after surgical removal of a hormone-secreting adrenal cortical tumor the cat is doing well. All laboratory values in both US and International System of Units are shown in Table 1.

## Discussion

Hyperadrenocorticism is defined as the excess production of steroid hormones by the adrenal gland. The most common cause of hyperadrenocorticism in cats is a functional pituitary tumor that secretes ACTH. However, cortisol-secreting adrenocortical tumors are rare in cats, and a functional adrenal tumor that secretes cortisol can also cause hyperadrenocorticism.<sup>1–3</sup> Adrenocortical tumors may also secrete other hormones, including mineralocorticoids and adrenal sex hormones.<sup>4–6</sup> Adrenal adenomas and adenocarcinomas are rare in cats and represent 0.2% of all cancers in this species.<sup>7</sup> Most primary adrenal tumors in cats secrete aldosterone, though there are a few reports that have documented secretion of sex hormones, cortisol and co-secretion of cortisol–progesterone, cortisol–aldosterone, aldosterone–progesterone and cortisol–progesterone or testosterone in cats.<sup>5,6,8</sup> This report describes an unusual case of a cat diagnosed with an adrenocortical tumor secreting more than one type of steroid hormones that was successfully treated with unilateral adrenalectomy.

The cat had clinical signs consistent with both hyperadrenocorticism and hyperthyroidism. Unfortunately, the circulating thyroxine concentration was not measured prior to adrenalectomy. However, the complete disappearance of clinical signs after adrenalectomy argue against hyperthyroidism as the cause of the clinical signs prior to adrenalectomy. Unlike in dogs, the renal tubules of cats are not very sensitive to cortisol.<sup>9</sup> Consequently, hypercortisolism does not automatically result in polyuria and polydipsia in this species. However, most, but not all, cats with hypercortisolism develop secondary diabetes mellitus, which does result in polyuria, polydipsia and polyphagia. In the present case the cat did not have diabetes mellitus.

The increase in cortisol level observed after the ACTH administration pointed to hypercortisolism. The left adrenal hypotrophy may also be consistent with a cortisol-secreting adrenocortical tumor, resulting in low pituitary ACTH secretion. Hypercortisolism due to an adrenocortical tumor could not be proven unequivocally



**Table 1** Laboratory results in both US and international units before and after adrenalectomy

| <b>Day 0 (day of admission)</b>     |  |                                     |
|-------------------------------------|--|-------------------------------------|
| <b>Parameter</b>                    | <b>US units (RI)</b>                   | <b>International units (RI)</b>     |
| WBC                                 | 13.0 x 10 <sup>3</sup> /μl (2.3–9.8)   | 13x10 <sup>9</sup> /l (2.3–9.8)     |
| Lymphocytes                         | 0.43 x 10 <sup>3</sup> /μl (0.90–5.50) | 0.43x10 <sup>9</sup> /l (0.9–5.5)   |
| Glucose                             | 171 mg/dl (70–140)                     | 9.5 mmol/l (3.89–7.78)              |
| ALT                                 | 27 IU/l (32–83)                        | 27 U/l (32–83)                      |
| Potassium                           | 3.9 mEq/l (3.5–5.0)                    | 3.9 mEq/l (3.5–5.0)                 |
| USG                                 | 1.019 (1.001–1.070)                    | 1.019 (1.001–1.070)                 |
| <b>ACTH-ST test</b>                 |  |                                     |
| Baseline cortisol                   | 6.59 μg/dl (0.80–5.00)                 | 181.8 nmol/l (22.1–138.0)           |
| 1 h cortisol                        | 20.0 μg/dl (3.6–10.0)                  | 551.80 nmol/l (99.32–276.00)        |
| Aldosterone                         | > 1376.0 ng/ml (11.3–294.3)            | 38.11 nmol/l (0.31–8.15)            |
| Progesterone                        | 2.59 ng/ml (0.03–0.40)                 | 8.24 nmol/l (0.10–1.30)             |
| 17 OH progesterone                  | 0.12 ng/ml (0.08–0.20)                 | 0.38 nmol/l (0.25–0.64)             |
| Androstenedione                     | 0.20 ng/ml (0.10–0.30)                 | 6.99 pmol/l (3.50–10.50)            |
| Testosterone                        | 0.02 ng/ml (0.02–0.30)                 | 0.0006 nmol/l (0.0006–0.0100)       |
| Estradiol                           | 27.3 pg/ml (50.3–84.0)                 | 100.21 pmol/l (184.65–308.40)       |
| Cortisol                            | 2.1 ng/ml (5.2–54.4)                   | 57.9 nmol/l (143.5–1501.0)          |
| <b>Day 1 (after adrenalectomy)</b>  |  |                                     |
| <b>Parameter</b>                    | <b>US units (RI)</b>                   | <b>International units (RI)</b>     |
| Glucose                             | 134 mg/dl (70–140)                     | 7.44 mmol/l (3.89–7.78)             |
| Potassium                           | 3.54 mEq/l (3.50–5.00)                 | 3.54 mEq/l (3.50–5.00)              |
| Sodium                              | 154.9 mEq/l (148.0–156.0)              | 154.9 mEq/l (148.0–156.0)           |
| Creatinine                          | 1.6 mg/dl (1.0–2.1)                    | 122.01 μmol/l (76.26–160.14)        |
| BUN                                 | 37 mg/dl (17–40)                       | 13.21 mmol/l (6.10–14.3)            |
| <b>ACTH-ST test</b>                 |  |                                     |
| Baseline cortisol                   | <0.1 μg/dl (0.8–5.0)                   | 2.76 nmol/l (22.10–138.00)          |
| 1 h cortisol                        | 0.146 μg/dl (3.600–10.000)             | 4.03 nmol/l (99.32–276.00)          |
| <b>Day 4 (after adrenalectomy)</b>  |  |                                     |
| <b>Parameter</b>                    | <b>US units (RI)</b>                   | <b>International units (RI)</b>     |
| Potassium                           | 2.8 mEq/l (3.5–5.0)                    | 2.8 mEq/l (3.5–5.0)                 |
| <b>Week 3 (after adrenalectomy)</b> |  |                                     |
| <b>Parameter</b>                    | <b>US units (RI)</b>                   | <b>International units (RI)</b>     |
| Potassium                           | Between 4.1 and 4.5 mEq/l (3.5–5.0)    | Between 4.1 and 4.5 mEq/l (3.5–5.0) |
| Aldosterone                         | 112.0 ng/ml (11.3–294.3)               | 3.10 nmol/l (0.31–8.15)             |

RI = reference interval; WBC = white blood cells; ALT = alanine aminotransferase; USG = urine specific gravity; BUN = blood urea nitrogen; ACTH-ST = adrenocorticotropin hormone stimulation test

because the endogenous ACTH concentration was not measured. In the presence of an adrenocortical tumor, even when basal cortisol concentration is low, clinical signs of hyperadrenocorticism may be seen.

Aldosterone is the main mineralocorticoid hormone produced by the zona glomerulosa of the adrenal cortex. The primary function of aldosterone is to regulate blood pressure through increasing reabsorption of water and sodium, and secretion of potassium in the distal renal tubules, colon and salivary glands.<sup>10</sup> In primary hyperaldosteronism, aldosterone is autonomously secreted in the adrenal cortex leading to sodium retention and systemic hypertension.<sup>11</sup> Primary hyperaldosteronism can be caused by unilateral or bilateral nodular hyperplasia,

adenoma or adenocarcinoma of the zona glomerulosa.<sup>12–14</sup> Secondary hyperaldosteronism may occur in cardiac or chronic renal disease owing to overactivity of the renin–angiotensin system.<sup>15</sup> Based on normal cardiac and kidney evaluations, secondary hyperaldosteronism was discounted. The suspicion of primary hyperaldosteronism was based on finding increased serum aldosterone prior to treatment and decrease in aldosterone concentration after surgical removal of the adrenal tumor, but plasma renin activity was not measured.

Cats with an adrenocortical tumor may also hypersecrete sex steroids.<sup>16,17</sup> In the cat in this report a high serum concentration of progesterone was observed. Studies have shown that high serum progesterone concentration

may increase free cortisol concentrations via displacing cortisol from cortisol binding protein, resulting in hypercortisolism.<sup>17</sup> Furthermore, high adrenocortical progesterone production may cause hypersecretion of mineralocorticoids, glucocorticoids and androgens because the progesterone synthesized in the adrenal cortex can be converted into these hormones.<sup>18,19</sup> Interestingly, adrenal tumors that secrete high concentrations of serum progesterone may cause mineralocorticoid excess syndrome, even in the absence of hyperaldosteronism.<sup>16</sup> In the cat discussed herein, a high serum concentration of progesterone was observed, which could also explain the high serum aldosterone concentration.

In general, adrenalectomy is the treatment of choice for a non-metastatic unilateral functional adrenal tumor.<sup>20–24</sup> In cats, after a complete removal of a functional adrenal tumor, hypokalemia and hypertension are resolved in the immediate postoperative period and no continued medical treatment is necessary.<sup>24</sup> Prognosis may not be favorable for medical management alone because cats became refractory to potassium supplementation and antihypertensive drugs.<sup>10</sup> However, perioperative hemorrhage has been reported as a major and frequent complication in cats with aldosterone-secreting adrenal tumors.<sup>10,14,24</sup> In this cat no surgical complications were detected and correction of clinical signs and long-term survival were achieved.

## Conclusions

As described herein, hypersecretion of glucocorticoids, mineralocorticoids, sex steroids or combination of these should be considered when an adrenocortical tumor is diagnosed.

**Funding** CAPES Foundation, Ministry of Education of Brazil for the fellowship of Simone Guérios (process number 3293-13-0).

**Conflict of interest** The authors declared no potential conflicts of interest with respect to the research, authorship, and/or publication of this article.

## References

- 1 Lowe AD, Campbell KL and Graves T. **Glucocorticoids in the cat.** *Vet Dermatol* 2008; 19: 340–347.
- 2 Smith RR, Mayhew PD and Berent AC. **Laparoscopic adrenalectomy for management of a functional adrenal tumor in a cat.** *J Am Vet Med Assoc* 2012; 241: 368–372.
- 3 Chiaramonte D and Greco DS. **Feline adrenal disorders.** *Clin Tech Small Anim Pract* 2007; 22: 26–31.
- 4 McKenzie TJ, Lillegard JB, Young WF Jr and Thompson GB. **Aldosteronomas – state of the art.** *Surg Clin North Am* 2009; 89: 1241–1253.
- 5 Rossmeisl JH, Scott-Moncrieff JC, Siems J, et al. **Hyperadrenocorticism and hyperprogesteronemia in a cat with an adrenocortical adenocarcinoma.** *J Am Anim Hosp Assoc* 2000; 36: 512–517.
- 6 DeClue AE, Breshears LA, Pardo ID, et al. **Hyperaldosteronism and hyperprogesteronism in a cat with an adrenal cortical carcinoma.** *J Vet Intern Med* 2005; 19: 355–358.
- 7 Feldman EC and Nelson RW. **Comparative aspects of Cushing's syndrome in dogs and cats.** *Endocrinol Metab Clin North Am* 1994; 23: 671–691.
- 8 Briscoe K, Barrs VR, Foster DF and Beatty JA. **Hyperaldosteronism and hyperprogesteronism in a cat.** *J Feline Med Surg* 2009; 11: 758–762.
- 9 Schulman RL. **Feline primary hyperaldosteronism.** *Vet Clin North Am Small Anim Pract* 2010; 40: 353–359.
- 10 Ash RA, Harvey AM and Tasker S. **Primary hyperaldosteronism in the cat: a series of 13 cases.** *J Feline Med Surg* 2005; 7: 173–182.
- 11 MacKay AD, Holt PE and Sparkes AH. **Successful surgical treatment of a cat with primary aldosteronism.** *J Feline Med Surg* 1999; 1: 117–122.
- 12 Rijnberk A, Voorhout G, Kooistra HS, et al. **Hyperaldosteronism in a cat with metastasised adrenocortical tumour.** *Vet Q* 2001; 23: 38–43.
- 13 Glaz E, Racz K, Varga I, et al. **Mineralocorticoid production of adrenal cortical adenomas.** *J Steroid Biochem Mol Biol* 1993; 45: 57–64.
- 14 Djajadiningrat-Laanen S, Galac S and Kooistra H. **Primary hyperaldosteronism: expanding the diagnostic net.** *J Feline Med Surg* 2011; 13: 641–650.
- 15 Flood SM, Randolph JF, Gelzer AR and Refsal K. **Primary hyperaldosteronism in two cats.** *J Am Anim Hosp Assoc* 1999; 35: 411–416.
- 16 Syme HM, Scott-Moncrieff JC, Treadwell NG, et al. **Hyperadrenocorticism associated with excessive sex hormone production by an adrenocortical tumor in two dogs.** *J Am Vet Med Assoc* 2001; 219: 1725–1728.
- 17 Selman PJ, Mol JA, Rutteman GR, et al. **Effects of progestin administration on the hypothalamic-pituitary-adrenal axis and glucose homeostasis in dogs.** *J Reprod Fertil Suppl* 1997; 51: 345–354.
- 18 Behrend EN, Weigand CM, Whitley EM, et al. **Corticosterone- and aldosterone-secreting adrenocortical tumor in a dog.** *J Am Vet Med Assoc* 2005; 226: 1662–1666.
- 19 Machida T, Uchida E, Matsuda K, et al. **Aldosterone-, corticosterone- and cortisol-secreting adrenocortical carcinoma in a dog: case report.** *J Vet Med Sci* 2008; 70: 317–320.
- 20 Kyles AE, Feldman EC, De Cock HE, et al. **Surgical management of adrenal gland tumors with and without associated tumor thrombi in dogs: 40 cases (1994–2001).** *J Am Vet Med Assoc* 2003; 223: 654–662.
- 21 Lang JM, Schertel E, Kennedy S, et al. **Elective and emergency surgical management of adrenal gland tumors: 60 cases (1999–2006).** *J Am Anim Hosp Assoc* 2011; 47: 428–435.
- 22 Massari F, Nicoli S, Romanelli G, et al. **Adrenalectomy in dogs with adrenal gland tumors: 52 cases (2002–2008).** *J Am Vet Med Assoc* 2011; 239: 216–221.
- 23 Wang W, Hu W, Zhang X, et al. **Predictors of successful outcome after adrenalectomy for primary aldosteronism.** *Int Surg* 2012; 97: 104–111.
- 24 Lo AJ, Holt DE, Brown DC, et al. **Treatment of aldosterone-secreting adrenocortical tumors in cats by unilateral adrenalectomy: 10 cases (2002–2012).** *J Vet Intern Med* 2014; 28: 137–143.