



Antigenemia without antigenuria in a cat with histoplasmosis

Authors: Jarchow, Anthony, and Hanzlicek, Andrew

Source: Journal of Feline Medicine and Surgery Open Reports, 1(2)

Published By: SAGE Publishing

URL: <https://doi.org/10.1177/2055116915618422>

BioOne Complete (complete.BioOne.org) is a full-text database of 200 subscribed and open-access titles in the biological, ecological, and environmental sciences published by nonprofit societies, associations, museums, institutions, and presses.

Your use of this PDF, the BioOne Complete website, and all posted and associated content indicates your acceptance of BioOne's Terms of Use, available at www.bioone.org/terms-of-use.

Usage of BioOne Complete content is strictly limited to personal, educational, and non - commercial use. Commercial inquiries or rights and permissions requests should be directed to the individual publisher as copyright holder.

BioOne sees sustainable scholarly publishing as an inherently collaborative enterprise connecting authors, nonprofit publishers, academic institutions, research libraries, and research funders in the common goal of maximizing access to critical research.



Antigenemia without antigenuria in a cat with histoplasmosis

Anthony Jarchow and Andrew Hanzlicek

Journal of Feline Medicine and Surgery
 Open Reports
 1–4

© The Author(s) 2015
 Reprints and permissions:
sagepub.co.uk/journalsPermissions.nav
 DOI: 10.1177/2055116915618422
jfmsopenreports.com



Abstract

Case summary Based on demonstration of the yeast phase of *Histoplasma capsulatum* on fine-needle aspirate cytology of the kidney, a 5-year-old cat was diagnosed with histoplasmosis. Urine and serum were tested for antigen via a *Histoplasma* antigen enzyme immunoassay. At the time of diagnosis, and on multiple occasions during antifungal treatment, antigenemia was detected without antigenuria. The cat was treated with standard therapy and achieved clinical remission.

Relevance and novel information Diagnosis is most commonly made by finding the yeast phase of *H capsulatum* via cytology of fluid samples or cytology or histopathology of infected tissues. In certain cases this may require invasive tests. Recently, a non-invasive test, a *Histoplasma* antigen enzyme immunoassay, has been shown to be a sensitive test for supporting the diagnosis of histoplasmosis in cats. Urine has been considered the biologic specimen of choice for antigen testing and there is a paucity of information concerning the use of other specimens such as serum. The case herein reports a cat with antigenemia without antigenuria. These findings suggest that further research is necessary to better understand the ideal biologic sample or combination of samples as it pertains to antigen testing in cats. It also suggests that to maximize sensitivity both urine and serum may need to be tested in cats with suspected histoplasmosis.

Accepted: 28 October 2015

Case description

A 5-year-old neutered male domestic shorthair cat was presented for weight loss and decreased appetite of 8 months' duration. The cat lived exclusively in Arkansas with the first out-of-state travel to Oklahoma at the time of presentation. Four years previously, the cat was diagnosed with and treated for cytauxzoonosis. On initial physical examination the cat was found to be bright, alert and responsive. The cat had a body condition score (BCS) of 4/9 and appeared mildly dehydrated. No abnormalities were detected on arterial pulse and respiratory rates, body temperature, thoracic auscultation and abdominal palpation. Serum biochemistry panel, complete blood count (CBC) and urinalysis showed moderate azotemia (creatinine 2.2 mg/dl, reference interval [RI] 0.6–2.4 mg/dl; blood urea nitrogen [BUN] 52 mg/dl, RI 14–36 mg/dl), a non-regenerative anemia (hematocrit 20%; RI 29–48%) and minimally concentrated urine and proteinuria with an inactive sediment (urine specific gravity 1.032; 2+ protein on urine dipstick). Urine protein was not confirmed or quantified by an alternate method. A total thyroxine

concentration was normal (1.4 mg/dl; RI 0.8–4.0 mg/dl). An ELISA test (SNAP FIV/FeLV Combo Test, IDEXX Laboratories) for feline immunodeficiency virus antibody and feline leukemia virus (FeLV) antigen was negative. Abdominal ultrasonography revealed bilaterally enlarged and hyperechoic kidneys with irregular margination and a loss of corticomedullary distinction (Figure 1), bilaterally enlarged adrenal glands and multiple hypoechoic splenic nodules. Thoracic radiographs showed no abnormalities. An ultrasound-guided fine-needle aspirate was performed for both kidneys. Cytology showed *Histoplasma capsulatum* organisms along with inflammation consisting of non-degenerate

Department of Veterinary Clinical Sciences, Oklahoma State University, Stillwater, OK, USA

Corresponding author:

Andrew Hanzlicek DVM, Department of Veterinary Clinical Sciences, Oklahoma State University, 213 W Farm Rd, Stillwater, OK 74078, USA
 Email: andrew.hanzlicek@okstate.edu



Creative Commons CC-BY-NC: This article is distributed under the terms of the Creative Commons Attribution-NonCommercial 3.0 License (<http://www.creativecommons.org/licenses/by-nc/3.0/>) which permits non-commercial use, reproduction and distribution of the work without further permission provided the original work is attributed as specified on the SAGE and Open Access page (<https://us.sagepub.com/en-us/nam/open-access-at-sage>).

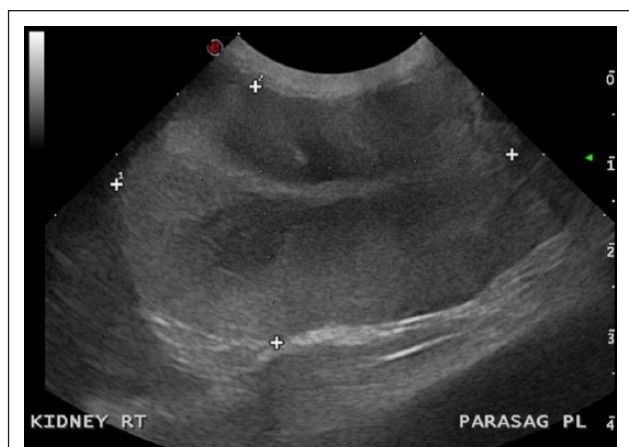

Figure 1 Ultrasonographic image of the right kidney in the parasagittal plane of a cat with histoplasmosis and renal involvement

neutrophils and a mixture of lymphocytes, plasma cells and macrophages. Serum and urine were submitted for *Histoplasma* antigen enzyme immunoassay (EIA) (*Histoplasma* Quantitative EIA Test; MiraVista Diagnostics). No antigen was detected in the urine but antigen was detected in the serum (3.16 ng/ml; RI none detected). Itraconazole was prescribed at 10 mg/kg/day by mouth. To treat inflammation associated with dying *H capsulatum* organisms, prednisolone was prescribed at 0.8 mg/kg/day by mouth and tapered over 21 days. Mirtazapine was prescribed at 3.75 mg total dose by mouth every 48 h for appetite stimulation.

The cat was presented for a scheduled recheck 1 month after diagnosis. At this visit, the cat was reported to be more active, with an increased appetite. Physical examination was unremarkable with the exception of continuing leanness (BCS 4/9) and slight mucosal pallor. Serum biochemistry analysis showed progressive azotemia (creatinine 3.0 mg/dl, RI 0.6–2.4 mg/dl; BUN 73 mg/dl; RI 14–36 mg/dl), elevated transaminase activity (alanine transaminase 392 IU/l, RI 10–100 IU/l; aspartate transaminase 124 IU/l, RI 10–100 IU/l) and slightly improved anemia that remained non-regenerative (hematocrit 23%, RI 29–48%). Owing to concern for hepatotoxicity, itraconazole was discontinued and fluconazole was prescribed at 11.6 mg/kg/day by mouth. Subsequent rechecks occurred monthly. Urine and serum were collected for *Histoplasma* antigen EIA at each recheck.

The cat continued to improve clinically when a CBC at a regularly scheduled recheck, approximately 4 months after diagnosis, revealed neutropenia (1827/ μ l, RI 2500–8500/ μ l). Owing to the neutropenia, amoxicillin/clavulanic acid was prescribed at 15 mg/kg by mouth q12h for 2 weeks. A month later a repeat CBC showed neutropenia (1908/ μ l, RI 2500–8500/ μ l)

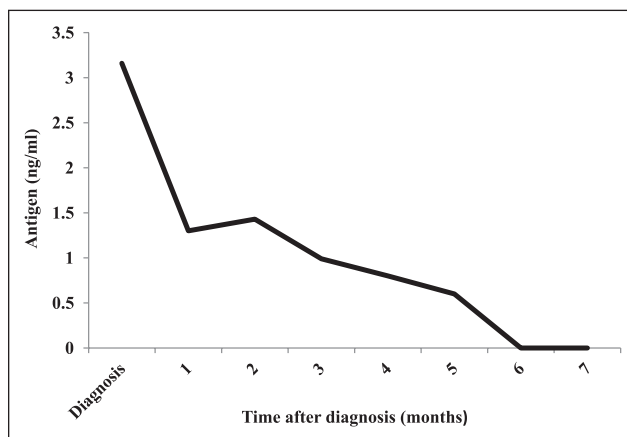


Figure 2 Serum antigen concentrations, as measured by a *Histoplasma* antigen enzyme immunoassay, over time in a cat with histoplasmosis treated with antifungal therapy (reference interval = no antigen detected)

and non-regenerative anemia (hematocrit 22%, RI 29–48%). A bone marrow aspirate and cytology revealed myeloid and erythroid hypoplasia. No evidence of neoplastic cells or infectious organisms, including *H capsulatum*, was identified within either the bone marrow or repeat kidney cytology samples. Immunofluorescent antibody testing of the bone marrow for FeLV, performed by a commercial veterinary diagnostic laboratory, was positive (Oklahoma Animal Disease Diagnostic Laboratory, Stillwater, OK, USA). At that time the cat was free of clinical signs. Neither repeat FeLV ELISA on peripheral blood nor PCR on bone marrow was performed. Repeat *Histoplasma* antigen EIA testing continued to fail to detect antigenuria. Serum antigen concentrations decreased with treatment and antigen clearance was achieved 6 months after the start of antifungal therapy (Figure 2). Based on the resolution of clinical signs and negative bone marrow and kidney aspirate cytology for inflammation and *H capsulatum* organisms the cat was considered to be in clinical remission 6 months after diagnosis. Approximately 4 months following clinical remission the cat was euthanized by the primary care veterinarian for worsening azotemia (actual serum BUN and creatinine unknown) and anorexia. A post-mortem examination was not performed.

Discussion

This is the first report of a cat with histoplasmosis with antigenemia without antigenuria. Over the past 18 months, approximately 12% of canine and feline samples submitted for *Histoplasma* antigen EIA testing were serum samples (L Joseph Wheat, 2015, personal communication). The majority of the remaining samples were urine. This suggests that it is common practice to submit only urine for antigen testing in cats with suspected

histoplasmosis. Considering the case reported herein there is a need for further research concerning antigen testing in cats, including the ideal specimen or specimens to be tested. A recent study in humans with acute pulmonary histoplasmosis showed that sensitivity was increased from 64.6% with urine testing alone and 68.6% with serum testing alone to 82.8% when both samples were tested.¹ Details of the case reported herein suggest that, like humans, when histoplasmosis is considered likely, testing both urine and serum may be necessary to maximize sensitivity.

The dimorphic fungal organism *H capsulatum var capsulatum* is the causative agent of histoplasmosis in people, cats and many other mammalian species in North America. Diagnosis is most commonly made by finding *H capsulatum* yeast in infected tissue or fluid samples. *H capsulatum* yeast has a characteristic appearance as round (2–4 µm) intracellular organisms with a clear halo around a central basophilic body.² Disadvantages of cytology or histopathology include the risks or invasiveness of collecting tissue samples. This may be most apparent with disease localized to the respiratory tract. The terms 'risks' and 'invasiveness' are subjective, but few veterinarians would argue that collecting a blood or urine sample, required for antigen testing, carries the same risks as a lung aspirate. The *Histoplasma* antigen EIA may provide a less invasive alternative when tissue aspiration or biopsy is not possible or fails to provide a definitive diagnosis and histoplasmosis remains likely. Other reported tests to aide in the diagnosis include fungal culture and serum antibody testing. Fungal culture is slow (2–4 weeks), poses a risk to laboratory personnel and lacks sensitivity.^{3–7} There is a paucity of information concerning serum antibody testing in cats with histoplasmosis.

Histoplasma antigen EIA (*Histoplasma* Quantitative EIA Test; MiraVista Diagnostics) performed on urine has been shown to be a sensitive (94%) test for disseminated histoplasmosis in cats.⁸ The antigen-detected galactomannan is released from the fungal cell wall into bodily fluids.⁹ There is cross-reactivity with other fungal organisms.⁹ As such, the positive predictive value of the *Histoplasma* antigen EIA will be dependent upon the prevalence of other systemic mycoses in the geographic location. In our hospital, owing to a very low prevalence of other mycoses, the *Histoplasma* antigen EIA is a relatively specific test for histoplasmosis in cats. This may not be the case in a geographic location where other mycoses are more common.

In a single abstract, the *Histoplasma* antigen EIA performed on serum has been reported in six cats.¹⁰ Of those six cats, one tested positive with a urine antigen test and negative with a serum antigen test. The other five cats tested positive with both urine and serum. There are a few published studies in humans reporting both urine

and serum *Histoplasma* antigen EIA testing in the same group of patients. Results have been mixed, with two studies showing a better sensitivity for the diagnosis of histoplasmosis when urine was tested, and one study showing a slightly better sensitivity when serum was tested.^{1,9,11} Antigenemia in the absence of antigenuria is an uncommon finding in humans and the cause remains unknown. It has been reported in one person receiving tumor necrosis factor- α blocker therapy and in seven people with acute pulmonary histoplasmosis.^{1,11} The opposite scenario of antigenuria without antigenemia is apparently more common in people who are immunocompromised.^{9,11}

The cat reported herein had evidence of kidney disease at the time of diagnosis and continued to do so until the time of death. It is unclear what impact, if any, decreased renal function may have had on the lack of antigenuria. There is no published information regarding this in any species. One possible explanation is the binding of antibodies to antigens in the urine. Owing to size, antigen–antibody complexes should not be found in the urine. With kidney disease this was considered possible. Finally, laboratory error is always possible but seems very unlikely considering similar test results on six different occasions. The cause for antigenemia without antigenuria in this cat remains unknown.

Conclusions

Results from the case reported herein suggest that to maximize sensitivity both urine and serum may need to be tested for antigen in cats with suspected histoplasmosis. Additionally, this case highlights the need for further research investigating the ideal sample or combination of samples for antigen testing in cats with suspected histoplasmosis.

Funding The authors received no financial support for the research, authorship, and/or publication of this article.

Conflict of interest The authors declared no potential conflicts of interest with respect to the research, authorship, and/or publication of this article.

References

- 1 Swartzentruber S, Rhodes L, Kurkjian K, et al. **Diagnosis of acute pulmonary histoplasmosis by antigen detection.** *Clin Infect Dis* 2009; 49: 1878–1882.
- 2 Bromel C and Greene CE. **Histoplasmosis.** In: Greene CE (ed). *Infectious diseases of the dog and cat.* St Louis, MO: Elsevier, 2012, pp 614–621.
- 3 Selby LA, Menges RW and Habermann RT. **Survey for blastomycosis and histoplasmosis among stray dogs in Arkansas.** *Am J Vet Res* 1967; 28: 345–349.
- 4 Porter BM, Comfort BK, Menges RW, et al. **Correlation of fluorescent antibody, histopathology, and culture on tis-**

- sues from 372 animals examined for histoplasmosis and blastomycosis. *J Bacteriol* 1965; 89: 748–751.
- 5 VanSteenhouse JL and DeNovo RC, Jr. **Atypical *Histoplasma capsulatum* infection in a dog.** *J Am Vet Med Assoc* 1986; 188: 527–528.
 - 6 Johnson LR, Fry MM, Anez KL, et al. **Histoplasmosis infection in two cats from California.** *J Am Anim Hosp Assoc* 2004; 40: 165–169.
 - 7 Wheat LJ. **Current diagnosis of histoplasmosis.** *Trends Microbiol* 2003; 11: 488–494.
 - 8 Cook AK, Cunningham LY, Cowell AK, et al. **Clinical evaluation of urine *Histoplasma capsulatum* antigen measurement in cats with suspected disseminated histoplasmosis.** *J Feline Med Surg* 2012; 14: 512–515.
 - 9 Connolly PA, Durkin MM, Lemonte AM, et al. **Detection of *Histoplasma* antigen by a quantitative enzyme immunoassay.** *Clin Vaccine Immunol* 2007; 14: 1587–1591.
 - 10 Cook AK, Cunningham LY, Cowell AK, et al. **Diagnostic reliability of an antigen assay for feline histoplasmosis.** *J Vet Intern Med* 2011; 25: 705–706.
 - 11 Vergidis P, Avery RK, Wheat LJ, et al. **Histoplasmosis complicating tumor necrosis factor-alpha blocker therapy: a retrospective analysis of 98 cases.** *Clin Infect Dis* 2015; 61: 409–417.