



## **Surgical management of myelopathy caused by a solitary spinal osteochondroma in a young cat**

Authors: Heblinski, Nikola, and Schmökel, Hugo

Source: Journal of Feline Medicine and Surgery Open Reports, 3(1)

Published By: SAGE Publishing

URL: <https://doi.org/10.1177/2055116916688397>

---

BioOne Complete ([complete.BioOne.org](https://complete.BioOne.org)) is a full-text database of 200 subscribed and open-access titles in the biological, ecological, and environmental sciences published by nonprofit societies, associations, museums, institutions, and presses.

Your use of this PDF, the BioOne Complete website, and all posted and associated content indicates your acceptance of BioOne's Terms of Use, available at [www.bioone.org/terms-of-use](https://www.bioone.org/terms-of-use).

Usage of BioOne Complete content is strictly limited to personal, educational, and non - commercial use. Commercial inquiries or rights and permissions requests should be directed to the individual publisher as copyright holder.

---

BioOne sees sustainable scholarly publishing as an inherently collaborative enterprise connecting authors, nonprofit publishers, academic institutions, research libraries, and research funders in the common goal of maximizing access to critical research.



# Surgical management of myelopathy caused by a solitary spinal osteochondroma in a young cat

Nikola Heblinski and Hugo Schmökel

*Journal of Feline Medicine and Surgery Open Reports*  
1–4

© The Author(s) 2017

Reprints and permissions:

sagepub.co.uk/journalsPermissions.nav

DOI: 10.1177/2055116916688397

journals.sagepub.com/home/jfmsopenreports

This paper was handled and processed by the European Editorial Office (ISFM) for publication in JFMS Open Reports



## Abstract

**Case summary** A 10-month-old, male castrated, domestic shorthair cat was presented with fast-progressing ataxia of the pelvic limbs. MRI and CT were performed, revealing a bony proliferation at T11, with mass effect and laterodorsal compression of the spinal cord. After hemilaminectomy and the removal of the bony mass, the cat recovered uneventfully. At the 1 year follow-up, the cat did not show any neurological deficits or signs of recurrence.

**Relevance and novel information** Solitary osteochondroma as a cause of neurological deficits in the pelvic limb has been described in dogs and humans, but, to the best of our knowledge, there are no reported feline cases described in the literature, in which CT and MRI were performed in combination with the successful removal of the lesion and an excellent outcome for the patient.

**Accepted:** 13 December 2016

## Introduction

Solitary osteochondromatosis of the spine is a rare disease described in people, horses and dogs, as well as one case involving a cat.<sup>1,2</sup> Osteochondroma (OC) is a benign tumour of the bones. It can appear in either single form or the multiple, hereditary form (osteochondromatosis or hereditary multiple exostosis).<sup>1,3</sup> Even in humans, the involvement of the thoracic spine is rare, with only 27 cases reported.<sup>4</sup> Although their aetiology is unclear, OCs originate from the separation of epiphyseal growth plate cells, followed by herniation through the periosteum adjacent to the growth plate; alternatively, the cells may originate from the separate secondary ossification centres in the spinal processes.<sup>3,4</sup> Throughout the process of growth, the exostoses are continuously replaced by spongiosome bone tissue.<sup>5–7</sup>

## Case description

A 10-month-old, castrated male indoor domestic shorthair cat was presented with a history of fast-progressing ataxia of the pelvic limbs. The referring veterinarian had prescribed pain management with opioids and non-steroidal anti-inflammatory drugs (NSAIDs), without improvement after 2 days. A radiographic examination

of the thoracolumbar spine was unable to reveal the reason for the neurological deficits.

At presentation the cat was alert, and the general examination was unremarkable. The cranial nerves and front legs were normal. Further neurological examination revealed a non-ambulatory paraparesis, without the ability to bear weight on the pelvic limbs (modified Frankel score 3). In the pelvic limbs, proprioceptive responses were absent, and the sciatic and femoralis reflexes were hyperactive. The cat was able to urinate consciously. The examination indicated a T3–L3 myelopathy. The results of the haematology and serum chemistry were within the normal limits.

To further diagnose the lesion, an MRI scan with a low-field Esaote Vet-MR Grande was performed (T3–S3),

Evidensia Specialist Animal Hospital Strömsholm, Strömsholm, Sweden

### Corresponding author:

Nikola Heblinski DVM, Evidensia Specialist Animal Hospital Strömsholm, Djursjukhusvägen 11, 73494 Strömsholm, Sweden  
Email: nikola.heblinski@gmx.de



Creative Commons Non Commercial CC-BY-NC: This article is distributed under the terms of the Creative Commons

Attribution-NonCommercial 3.0 License (<http://www.creativecommons.org/licenses/by-nc/3.0/>) which permits non-commercial use, reproduction and distribution of the work without further permission provided the original work is attributed as specified on the SAGE and Open Access pages (<https://us.sagepub.com/en-us/nam/open-access-at-sage>).

followed by a CT scan with a Phillips Brilliance CT 40 Channel, using the cervical spine helical program with 1mm slices and 0.5 mm increments (C5–L3). The MRI revealed a mass effect within the spinal canal of T11. There was a heterogenous hypointensity in the turbo three-dimensional and T2 sequence. The revealed mass showed contrast uptake that was visible in the T1 sequence. There was a T2-hyperintense signal change within the spinal cord at the level of the compression (Figure 1). The CT showed a bony proliferation originating from the left pedicle of T11, with laterodorsal compression of the spinal cord. No periosteal reactions or lysis of the adjacent bone indicating infection or malignant behaviour were noted (Figure 2).

With the presumptive diagnosis of a solitary OC, surgery was recommended to the owner. After premedication with methadone (0.3 mg/kg) and acepromazine (0.05 mg/kg), anaesthesia in the cat was induced with propofol (4 mg/kg) and maintained with isoflurane and oxygen. An electrocardiogram, capnography and oxygen saturation, blood pressure and body core temperature measurements with an oesophageal sensor were used to monitor the anaesthesia.

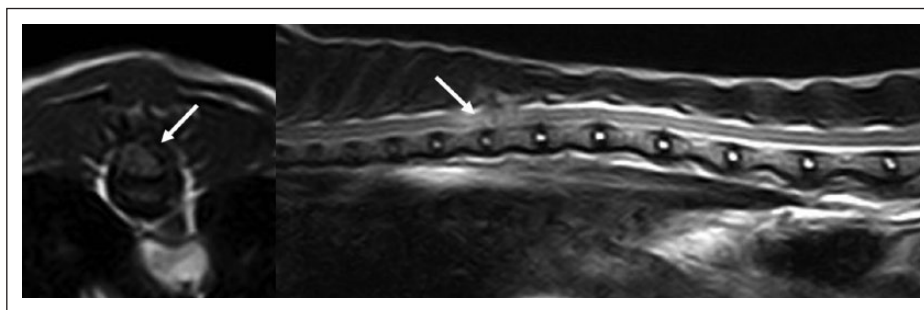
An extended left-sided hemilaminectomy T11 was performed, including the left facet joints T10–11 and T11–12 and the spinous process of T11. The proliferative bony mass was removed with small rongeurs, and

bone samples were collected for histological examination. After flushing with sterile saline, the defect was covered with an autologous fat graft and the incision was closed routinely. Postoperative analgesia consisted of 0.3 mg/kg methadone every 2–4 h. A transdermal fentanyl patch was applied for 3 days together with an NSAID (meloxicam 0.05 mg/kg) every 24 h for 14 days.

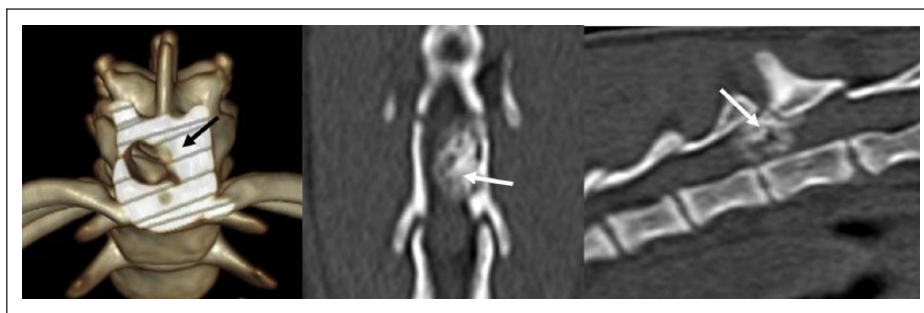
The 8 week postoperative control showed a great improvement in the motoric function of the pelvic limbs, with the ability to walk and positive proprioceptive responses (ambulatory paraparesis, modified Frankel score 2). No pain in the operated area could be detected. One year after surgery, the cat was free of obvious neurological deficits, as seen in several video sequences provided by the owner.

## Discussion

In contrast to dogs and humans, where the growth of the exostoses ceases with skeletal maturity, OCs in cats proliferate beyond physeal closure.<sup>8–12</sup> Most commonly, solitary OCs affect older cats and are also often related to feline leukaemia virus diseases.<sup>10,12–14</sup> No breed or sex predisposition has been identified.<sup>12</sup> Nevertheless, in dogs, the possibility of an inherited predisposition has been discussed.<sup>6,8,15–18</sup>



**Figure 1** Transverse and sagittal T2 MRI sequence of the thoracolumbal spine. The heterogenous, hypointense mass compressing the spinal cord from the left laterodorsal side is marked by the arrow



**Figure 2** Transverse three-dimensional reconstruction and dorsal and sagittal CT scans revealed a bony proliferation compressing the spinal cord from the left, laterodorsal at the level of T10–11 (arrows)

Even although these benign lesions are usually clinically insignificant, malignant transformation into osteosarcoma, chondrosarcoma or parosteal sarcoma is possible.<sup>13,17,19–21</sup>

Most OCs are asymptomatic, but mechanical signs can occur, depending on the location and size of the OC. Clinical signs usually occur if an OC creates pressure on neighbouring structures, such as tendons, vessels, the spinal cord or the trachea.<sup>2,10,11,14,22–27</sup> OC lesions can be amorphous (or sometimes linear or oval-shaped), heterogeneous mineralised formations, which may or may not be attached to the skeleton.<sup>2,9–11,24,25,27–29</sup> Consequently, cartilaginous exostoses in the spine may be revealed to be connected to a physical plate radiographically.<sup>13</sup>

To the best of our knowledge, solitary OCs triggering neurological signs have been described in dogs and humans, but there is only one such case report for a cat reported in the literature.<sup>2,24,30</sup> The present case report describes a 10-month-old, castrated male, domestic shorthair cat with progressive ataxia of both hindlimbs. Radiographs of the skeletal system did not reveal any pathological findings to explain the clinical signs. The unique composition of hyaline cartilage, with its low number of cells and high water content, allows for a good MRI display of OCs. MRI is therefore considered the best diagnostic modality for OCs.<sup>7</sup> In addition, MRI can be used to determine the exact localisation and extent of any potential compression of the surrounding soft tissue. Another advantage is the possibility of monitoring the thickening of the cartilage caps, and this may allow detection of the early transformation to malignancy.<sup>7,17</sup> In the literature on humans a thickness of the cartilage cap of more than 2 cm may indicate a malignant transformation,<sup>31</sup> but this has not been evaluated in affected animals thus far.<sup>13</sup> Nevertheless, the MRI of the cat described here suggests an OC of the T11 vertebra (Figure 1).

In human medicine, CT is used to evaluate the physical characteristics of an OC.<sup>32</sup> For optimal preoperative planning and to further rule out possible differential diagnoses, such as periosteal chondromas, calcinosis circumscripta or osteochondrosarcoma, a CT was performed in addition to the MRI.<sup>25,31</sup> The findings of the CT further supported the existence of an OC. No other pathological findings were seen (Figure 2).

Despite the fact the spinal cord from C1 to C4 has not been evaluated via either MRI or CT, the preoperative neurological examination suggests a T3–L3 myelopathy. Additionally, postoperative recovery suggests the conclusion of a lesion affecting a single vertebra and therefore the presence of a solitary OC.

Given the continuing growth of OCs in cats beyond skeletal maturity and the marked neurological changes these create, the surgical removal of the mass and the

decompression of the neuronal tissue are the treatments of choice.<sup>13</sup> According to the literature, a histopathological examination is mandatory to confirm the diagnosis.<sup>13</sup> The histopathology of the tissue removed from the cat described here revealed bone tissue composed of well-differentiated osteoid tissue. There were no findings suggestive of necrosis in the osteoid tissue and no signs of malignancy. Assuming complete removal of the tumour and no malignancy detected at histopathology, the prognosis is good and there is minimal likelihood of local recurrence. Postoperatively, the cat already showed an improvement in motor function and normal proprioception of the pelvic limbs after 8 weeks. One year later, the cat had an unremarkable gait, and no signs of recurrence were seen on the video sequences provided by the owner.

## Conclusions

Spinal solitary osteochondroma is rarely observed in cats. This case report describes the diagnostic imaging findings, including CT and MRI, of a solitary OC in the spinal cord of a cat. The cat was successfully treated with surgery and was free of clinical signs 1 year after surgery. Advanced imaging was essential for surgical planning and delineating the surgical margins. Histopathology should be used to confirm the diagnosis and indicate the long-term prognosis.

**Author note** This manuscript had been previously displayed on the private webpage: [www.rygg.center](http://www.rygg.center). The manuscript is no longer available on the above link.

**Funding** The authors received no financial support for the research, authorship, and/or publication of this article.

**Conflict of interest** The authors declared no potential conflicts of interest with respect to the research, authorship, and/or publication of this article.

## References

- 1 Marioni K, Hathcock JT and Simpson ST. **What is your neurologic diagnosis? Osteochondroma of the dorsal process of T4.** *J Am Vet Med Assoc* 2001; 219: 917–920.
- 2 Reidarson TH, Metz AL and Hardy RM. **Thoracic vertebral osteochondroma in a cat.** *J Am Vet Med Assoc* 1988; 192: 1102–1104.
- 3 Sciubba DM, Macki M, Bydon M, et al. **Long-term outcomes in primary spinal osteochondroma: a multicenter study of 27 patients.** *J Neurosurg Spine* 2015; 22: 582–588.
- 4 Upadhyaya GK, Jain VK, Arya RK, et al. **Osteochondroma of upper dorsal spine causing spastic paraparesis in hereditary multiple exostosis: a case report.** *J Clin Diagn Res* 2015; 9: RD04–RD06.
- 5 Beck JA, Simpson DJ and Tisdall PL. **Surgical management of osteochondromatosis affecting the vertebrae and trachea in an Alaskan Malamute.** *Aust Vet J* 1999; 77: 21–23.

- 6 Jacobson LS and Kirberger RM. **Canine multiple cartilaginous exostoses: unusual manifestations and a review of the literature.** *J Am Anim Hosp Assoc* 1996; 32: 45–51.
- 7 Silver GM, Bagley RS, Gavin PR, et al. **Radiographic diagnosis: cartilaginous exostoses in a dog.** *Vet Radiol Ultrasound* 2001; 42: 231–234.
- 8 Doige CE. **Multiple cartilaginous exostoses in dogs.** *Vet Pathol* 1987; 24: 276–278.
- 9 Gradner G, Weissenbock H, Kneissl S, et al. **Use of latisimus dorsi and abdominal external oblique muscle for reconstruction of a thoracic wall defect in a cat with feline osteochondromatosis.** *J Feline Med Surg* 2008; 10: 88–94.
- 10 Levitin B, Aroch I, Aizenberg I, et al. **Linear osteochondromatosis in a cat.** *Vet Radiol Ultrasound* 2003; 44: 660–664.
- 11 Tan C, Allan GS, Barfield D, et al. **Synovial osteochondroma involving the elbow of a cat.** *J Feline Med Surg* 2010; 12: 412–417.
- 12 Thompson KG, Pool RR and Meuten DJ. **Tumor of bones.** In: Meuten DJ (ed). *Tumors in domestic animals*. 4th ed. Ames, IA: Blackwell Publishing, 2008, pp 245–317.
- 13 Kent M and Northrup N. **Spinal neoplasia.** In: Tobias KM and Johnston SA (eds). *Veterinary surgery small animal*. Vol 1. St Louis, MO: Elsevier Saunders, 2012, pp 542–543.
- 14 Pool RR and Carrig CB. **Multiple cartilaginous exostoses in a cat.** *Vet Pathol* 1972; 9: 350–359.
- 15 Chester DK. **Multiple cartilaginous exostoses in two generations of dogs.** *J Am Vet Med Assoc* 1971; 159: 895–897.
- 16 Franch J, Font J, Ramis A, et al. **Multiple cartilaginous exostosis in a Golden Retriever cross-bred puppy. Clinical, radiographic and backscattered scanning microscopy findings.** *Vet Comp Orthop Traumatol* 2005; 18: 189–193.
- 17 Green EM, Adams WM and Steinberg H. **Malignant transformation of solitary spinal osteochondroma in two mature dogs.** *Vet Radiol Ultrasound* 1999; 40: 634–637.
- 18 Mozos E, Novales M, Ginel PJ, et al. **A newly recognized pattern of canine osteochondromatosis.** *Vet Radiol Ultrasound* 2002; 43: 132–137.
- 19 Owen LN and Bostock DE. **Multiple cartilaginous exostoses with development of a metastasizing osteosarcoma in a Shetland sheepdog.** *J Small Anim Pract* 1971; 12: 507–512.
- 20 Jongeward SJ. **Primary bone tumors.** *Vet Clin North Am Small Anim Pract* 1985; 15: 609–641.
- 21 Doige CE. **Multiple osteochondromas with evidence of malignant transformation in a cat.** *Vet Pathol* 1987; 24: 457–459.
- 22 Nollf MC, Puff C, Langer B, et al. **Feline osteochondromatosis in a FeLV European shorthair cat.** *Tierarztl Prax Ausg K Kleintiere Heimtiere*. 2014; 42: 55–59.
- 23 Alexander JW. **Selected skeletal dysplasias: craniomandibular osteopathy, multiple cartilaginous exostoses, and hypertrophic osteodystrophy.** *Vet Clin North Am Small Anim Pract* 1983; 13: 55–70.
- 24 Bruckner M, Klumpp S, Ondreka N, et al. **Atypical solitary osteochondroma in a Labrador Retriever.** *Tierarztl Prax Ausg K Kleintiere Heimtiere* 2010; 38: 97–105.
- 25 Caporn TM and Read RA. **Osteochondromatosis of the cervical spine causing compressive myelopathy in a dog.** *J Small Anim Pract* 1996; 37: 133–137.
- 26 Withrow SJ. **Cancer of the larynx and trachea.** In: Withrow SJ and Vail DM (eds). *Withrow and MacEwen's small animal clinical oncology*. 4th ed. St Louis, MO: Saunders Elsevier, 2007, p 515.
- 27 Rosa C and Kirberger RM. **Extraskeletal osteochondroma on a cat's elbow.** *J S Afr Vet Assoc* 2012; 83: 104.
- 28 Perazzi A, Bernardini M, Mandara MT, et al. **Cavernous sinus syndrome due to osteochondromatosis in a cat.** *J Feline Med Surg* 2013; 15: 1132–1136.
- 29 Ranade SA and Pacchiana PD. **What is your diagnosis? Osteochondromatosis.** *J Am Vet Med Assoc* 2011; 238: 1243–1244.
- 30 Albrecht S, Crutchfield JS and SeGall GK. **On spinal osteochondromas.** *J Neurosurg* 1992; 77: 247–252.
- 31 Kenney PJ, Gilula LA and Murphy WA. **The use of computed tomography to distinguish osteochondroma and chondrosarcoma.** *Radiology* 1981; 139: 129–137.
- 32 Li Y-P. **Genetic nonneoplastic diseases of bone.** In: McManus LM and Mitchell RN (eds). *Pathobiology of human disease*. Amsterdam, MA: Elsevier, 2014, pp 770–780.