



## **Non-iatrogenic traumatic isolated bilothorax in a cat**

Authors: Mullins, Ronan A, Barandun, Marc A, Gallagher, Barbara, and Cuddy, Laura C

Source: Journal of Feline Medicine and Surgery Open Reports, 3(1)

Published By: SAGE Publishing

URL: <https://doi.org/10.1177/2055116917714871>

---

BioOne Complete ([complete.BioOne.org](https://complete.BioOne.org)) is a full-text database of 200 subscribed and open-access titles in the biological, ecological, and environmental sciences published by nonprofit societies, associations, museums, institutions, and presses.

Your use of this PDF, the BioOne Complete website, and all posted and associated content indicates your acceptance of BioOne's Terms of Use, available at [www.bioone.org/terms-of-use](https://www.bioone.org/terms-of-use).

Usage of BioOne Complete content is strictly limited to personal, educational, and non - commercial use. Commercial inquiries or rights and permissions requests should be directed to the individual publisher as copyright holder.

---

BioOne sees sustainable scholarly publishing as an inherently collaborative enterprise connecting authors, nonprofit publishers, academic institutions, research libraries, and research funders in the common goal of maximizing access to critical research.



# Non-iatrogenic traumatic isolated bilothorax in a cat

Ronan A Mullins, Marc A Barandun, Barbara Gallagher and Laura C Cuddy\*

*Journal of Feline Medicine and Surgery Open Reports*  
1–6

© The Author(s) 2017

Reprints and permissions:

sagepub.co.uk/journalsPermissions.nav

DOI: 10.1177/2055116917714871

journals.sagepub.com/home/jfmsopenreports

This paper was handled and processed by the European Editorial Office (ISFM) for publication in *JFMS Open Reports*



## Abstract

**Case summary** A 6-month-old spayed female domestic shorthair cat presented for evaluation of suspected bite wounds over the right caudal thorax and left cranial flank. Thoracic radiographs identified a mild right-sided pneumothorax, a small volume of right-sided pleural effusion, with increased soft tissue opacity in the right cranial and middle lung lobes. Abdominal ultrasound identified a very small gall bladder and several small pockets of free peritoneal fluid. Cytological analysis of peritoneal fluid was consistent with a modified transudate. Following initial diagnostic investigations, yellow–orange fluid began to emanate from the right-sided thoracic wound. Biochemical analysis of this fluid was consistent with bile. Exploratory coeliotomy revealed a right-sided radial diaphragmatic tear, with herniation of the quadrate liver lobe and a portion of the gall bladder into the right pleural space. The gall bladder was bi-lobed and avulsion of a single herniated lobe resulted in leakage of bile into the right pleural cavity, without concurrent bile peritonitis (biloadomem). The cat underwent total cholecystectomy and diaphragmatic defect repair and recovered uneventfully.

**Relevance and novel information** To our knowledge, at the time of writing non-iatrogenic isolated bilothorax without concurrent biloadomem has not been previously reported in the cat. This case highlights the importance of thorough assessment of cats with seemingly innocuous thoracic bite wounds. Despite the rarity of its occurrence, bilothorax should be considered a differential in cats with pleural effusion, even in the absence of bile peritonitis. We believe that the optimal treatment of cases of bilothorax is multifactorial and should be determined on a case-by-case basis.

**Accepted:** 12 May 2017

## Case description

A 6-month-old 3.12 kg (6.87 lb) spayed female domestic shorthair cat presented for evaluation of suspected thoracic and abdominal bite wounds. The cat had presented to its primary veterinarian the preceding day, having been found collapsed on a neighbour's driveway. On initial presentation, the cat demonstrated signs of shock and was administered intravenous fluid support, flow-by oxygen supplementation, amoxicillin clavulanic acid (Synulox; Zoetis) and buprenorphine (Bupaq; Chanelle). Packed cell volume and total solids were 19% and 40 g/l, respectively. Moderate bleeding was observed from a wound over the caudal right thorax and a pressure bandage was applied. Following this initial stabilisation, the cat was referred for further evaluation.

On physical examination, the cat was quiet, alert and responsive. It was tachycardic (280 beats per minute),

with strong femoral pulses and pink mucous membranes. Rectal temperature was 39.2°C (102.5°F). Lung sounds were adequate and breathing was not laboured. Two small (~0.5 cm diameter) full-thickness circular skin wounds were present on the right caudal thorax and left

Section of Veterinary Clinical Sciences, University College Dublin School of Veterinary Medicine, Belfield, Dublin 4, Ireland

\*Current address: Vets Now Emergency and Specialty Hospital, 98 Bury Old Road, Whitefield, Manchester, M45 6TQ, UK

### Corresponding author:

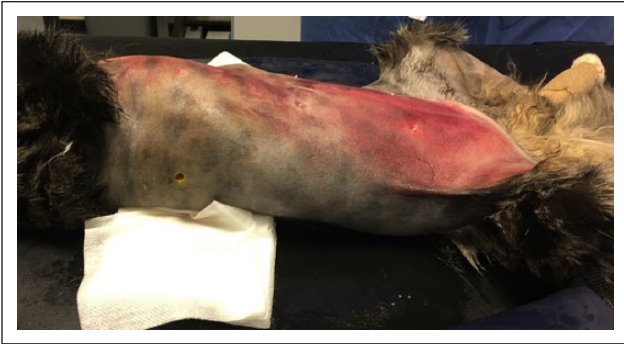Ronan A Mullins MVB, Section of Veterinary Clinical Sciences, University College Dublin School of Veterinary Medicine, Belfield, Dublin 4, Ireland

Email: ronan.mullins@ucdconnect.ie

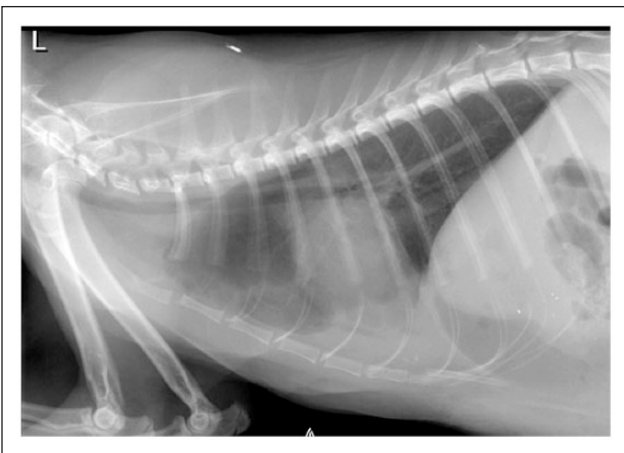

Creative Commons Non Commercial CC-BY-NC: This article is distributed under the terms of the Creative Commons

Attribution-NonCommercial 4.0 License (<http://www.creativecommons.org/licenses/by-nc/4.0/>) which permits non-commercial use, reproduction and distribution of the work without further permission provided the original work is attributed as specified on the SAGE and Open Access pages (<https://us.sagepub.com/en-us/nam/open-access-at-sage>).



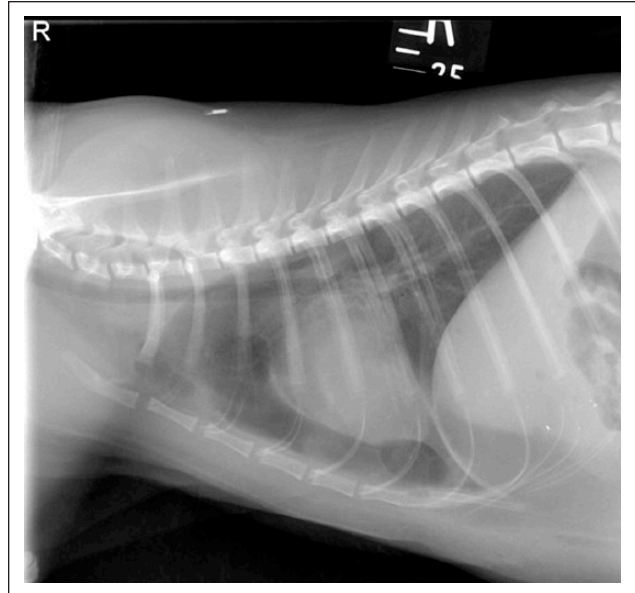
**Figure 1** Preoperative image showing substantial bruising of the ventral abdomen and the skin wound over the right caudal thorax. Cranial is to the left of the image



**Figure 2** Left lateral radiograph of the thorax depicting the presence of a mild caudoventrally located pleural effusion. The diaphragm appears intact. Several discrete mineral opacities can be seen in the caudoventral thorax and cranial abdomen

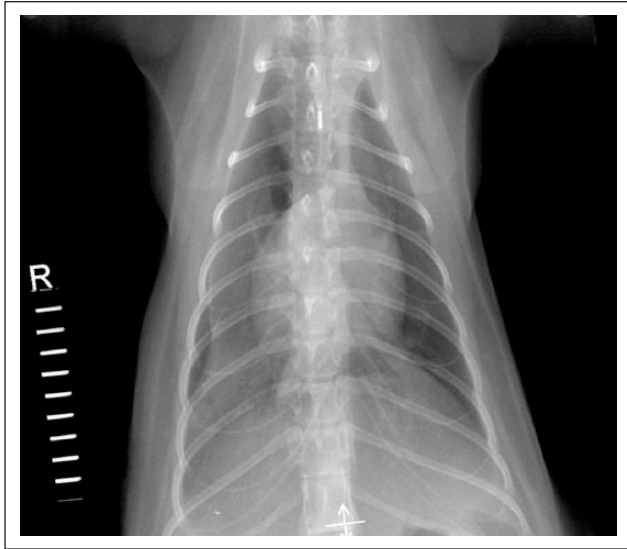
cranial flank (Figure 1). There was substantial bruising of the ventral abdomen, with mild discomfort on abdominal palpation. The cat was ambulatory and orthopaedic examination was unremarkable.

Post-lavage swabs for microbiology were obtained from both wounds following liberal clipping of the surrounding hair and aseptic preparation of the skin. No organisms were cultured from the left flank wound, while growth of *Serratia marcescens* was isolated from the right-sided wound. Haematology identified a mild, slightly regenerative anaemia (haematocrit 0.19 l/l, reference interval [RI] 0.24–0.45; red blood cells  $4.72 \times 10^{12}/l$ , RI 5–10). The leukocyte count was within the RI. Platelet count was mildly decreased ( $150 \times 10^9/l$ ; RI 180–550). Biochemical analysis identified a moderate increase in creatine kinase (3412 IU/l; RI 0–122), a severe increase in alanine aminotransferase (2760 IU/l; RI 0–45) activity, a moderate increase in aspartate

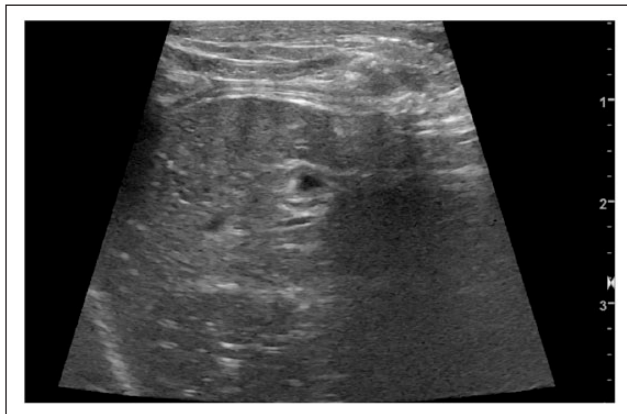

**Figure 3** Right lateral radiograph of the thorax depicting mild pneumothorax. The diaphragm appears intact

aminotransferase (700 IU/l; RI 0–70) activity, a mild increase in alkaline phosphatase activity (143 IU/l; RI 0–66), mild hypocholesterolaemia (1.43 mmol/l; RI 1.8–6.5), moderately decreased urea (3.8 mmol/l; RI 6.6–10), mild-to-moderate panhypoproteinaemia (46.9 g/l; RI 59–78), mild hypoalbuminaemia (23.8 g/l; RI 25–35), mild hypoglobulinaemia (23.1 g/l; RI 24–40) and mild total hyperbilirubinaemia (9.5  $\mu\text{mol}/l$ ; RI 1.7–5.1). Feline pancreatic-like immunoreactivity (SNAP fPL test; IDEXX Laboratories) was normal. Thoracic radiographs identified a mild right-sided pneumothorax, increased soft tissue opacity in the right cranial and middle lung lobes, and a small volume of pleural effusion within the caudoventral aspect of the right thoracic cavity along with several discrete mineral opacities (Figures 2–4). Abdominal ultrasound identified a moderate amount of anechoic free fluid within the pleural cavity. Several small pockets of anechoic free peritoneal fluid were identified. The gall bladder was visualised and appeared very small in size (Figure 5). The diaphragm appeared intact. Abdominocentesis was performed and the fluid obtained was submitted for cytology and bacterial culture and susceptibility testing. Cytology was consistent with a modified transudate, with non-septic neutrophilic inflammation (white blood cell count  $2.44 \times 10^9/l$ , total protein (TP) 38 g/l). No bacterial growth was isolated. Following initial diagnostic investigations, a change in the character of the fluid from the right-sided thoracic wound from sanguinous to yellow–orange fluid was observed (Figure 6). A sample of this fluid was collected and found to be consistent with bile via biochemical analysis (wound fluid bilirubin: 335  $\mu\text{mol}/l$ ,



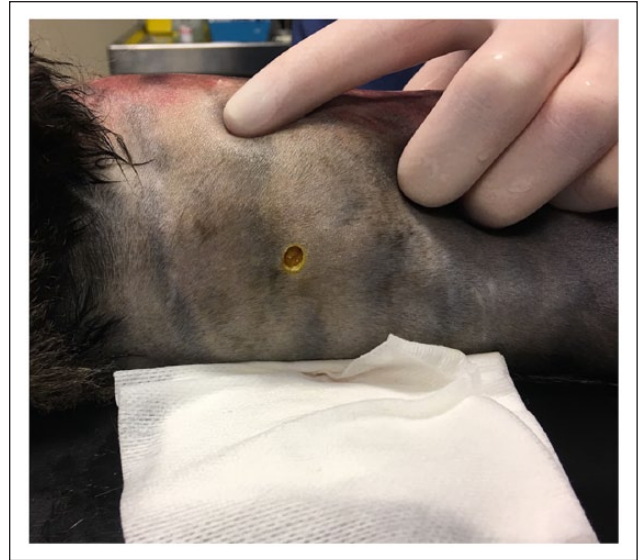**Figure 4** Dorsoventral radiograph of the thorax showing increased soft tissue opacity of the right caudal and middle lung lobes and mild right-sided pneumothorax. Discrete mineral opacities are present in the caudal right thorax/cranial abdomen



**Figure 5** Preoperative ultrasound image depicting the small-sized gall bladder surrounded by liver parenchyma

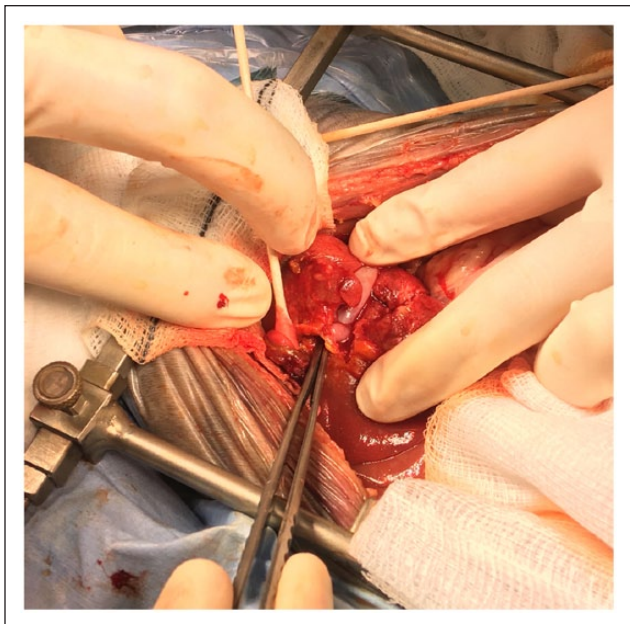
peripheral blood bilirubin:  $9.5 \mu\text{mol/l}$ ). Careful probing of the left-sided flank wound using a sterile microbiology swab confirmed the presence of a small slit-like defect in the abdominal wall musculature, with protrusion of what appeared to be intra-abdominal fat through this defect.

The cat was anaesthetised and standard ventral mid-line coeliotomy from the xiphoid to the pubis was performed. There was bile staining of the ventral subcutaneous tissues. A small amount of serosanguinous free peritoneal fluid was present, which was not grossly consistent with bile. There was no gross evidence of peritonitis. A radial tear was identified on the ventral aspect

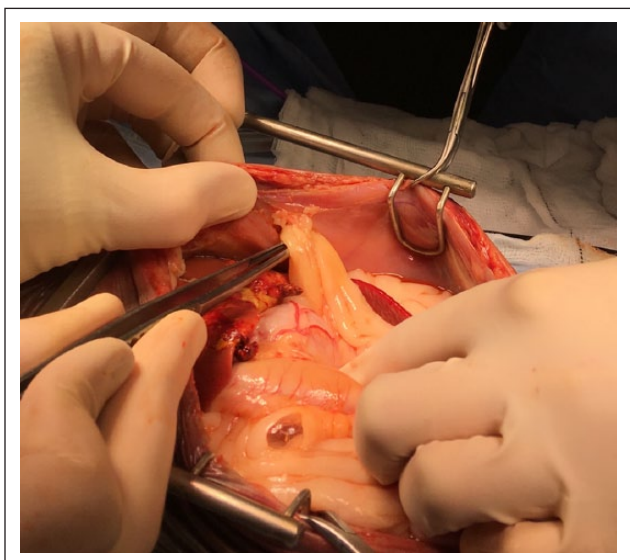


**Figure 6** Preoperative image depicting the yellow–orange fluid draining from the right-sided thoracic skin wound

of the right side of the diaphragm, with herniation of the quadrate liver lobe and a portion of the gall bladder through the defect. The herniated organs were carefully reduced into the peritoneal cavity. The gall bladder was identified as bi-lobed (both lobes shared a common cystic duct), with one lobe within the pleural space and one lobe remaining within the peritoneal space; avulsion of the single herniated lobe had resulted in leakage of bile into the right pleural cavity (Figure 7). The diaphragmatic defect was enlarged with Metzenbaum scissors in order to permit exploration of the right pleural space. A mild-to-moderate volume of orange–brown fluid, grossly consistent with bile, was present within the caudal right pleural cavity. There was a ~1 cm diameter defect in the middle-third of the right caudal thoracic wall, communicating with the right-sided thoracic skin wound. There was mild contusion of the right caudal lung lobe. A sample of fluid from the right pleural cavity was obtained and submitted for bacterial culture. No bacterial growth was isolated. The thoracic wall defect was debrided and closed primarily using 3-0 poliglecaprone 25 (Monocryl; Ethicon) in a simple continuous pattern and skin staples (Reflex one; Medcon Corporation). The liver appeared friable, with a homogenous pale red–chocolate brown appearance. Fibrinous exudate and foreign material (hair) on the surface of liver lobes were carefully excised. A liver biopsy was obtained via the guillotine technique and submitted for microbial culture. No bacterial growth was isolated. The common bile duct appeared grossly normal; patency was confirmed by antegrade catheterisation through the avulsed lobe of the gall bladder into the duodenum and flushing with sterile saline. The entire gall bladder was dissected free from the hepatic fossa. A



**Figure 7** Intraoperative image demonstrating the bi-lobed gall bladder. Notice the yellow bile staining of the avulsed lobe (a closed DeBakey thumb forceps has been inserted into the avulsed gall bladder lobe). Cranial is to the left of the image



**Figure 8** Intraoperative image depicting herniation of omental fat through a left-sided ventrolateral abdominal wall defect. Note the absence of gross signs of peritonitis. Cranial is to the left of the image

routine cholecystectomy was performed and a portion of the gall bladder was submitted for microbial culture. No bacterial growth was isolated.

There was herniation of omental fat through a left-sided ventrolateral abdominal wall defect, caudal to the

rib cage (Figure 8), and communicating with the skin wound on the left flank. The herniated omental fat was reduced and excised. The communicating left flank wound was debrided, lavaged and closed primarily in a similar fashion to the right-sided thoracic wall defect. The right diaphragmatic tear was closed in a simple continuous pattern using 3-0 polydioxanone (PDS II; Ethicon) following thorough lavage of the right pleural cavity. There was a second diaphragmatic tear beside the xiphoid on the left and was closed routinely. A 14 Fr transdiaphragmatic thoracostomy tube (Vygon Vet) was placed into the right pleural space through a paramedian stab incision in the right body wall and secured to the diaphragm using a purse-string suture and fixed to the skin using a modified Roman Sandal suture (Ethilon; Ethicon). The thoracic cavity was evacuated of air. The ventral midline coeliotomy was closed routinely.

Histopathology of excised gall bladder tissue identified necrosis and ulceration of its mucosal lining, often involving the glands, and a markedly oedematous submucosa, with multifocal areas of haemorrhage, necrosis and dilated lymphatics. Histopathology of the liver biopsy specimen identified no significant abnormalities.

The cat was admitted to the intensive care unit and received intravenous fluid support with Hartmann's solution (Vetivex; Duggan Veterinary) and supplemental potassium chloride (Braun Medical) until eating and drinking. Postoperative analgesia was provided with continuous rate infusions of fentanyl hydrochloride 0.6–6 µg/kg/h (Sublimaze; Janssen-Cilag) and ketamine hydrochloride 2.5 µg/kg/min (Narketan; Vetoquinol) for 72 and 24 h, respectively, followed by intermittent boluses of buprenorphine hydrochloride 20 µg/kg q6h (Bupaq; Chanelle) for a further 24 h. Empirical amoxicillin–clavulanic acid 20 mg/kg q8h (Augmentin; GlaxoSmithKline) was administered for the first 96 h postoperatively. The thoracostomy tube was removed after 5 days when drain production reduced to <2 ml/kg/day. The cat was discharged from the hospital after 7 days with a 2 week course of amoxicillin–clavulanic acid 16 mg/kg (Noroclav; Norbrook) and S-adenosyl methionine 20 mg/kg (Samylin; VetPlus). The cat was presented to its primary veterinarian 5 days later for suture removal. Physical examination was within normal limits apart from mild swelling in the region of the right thoracic wound. Repeat serum biochemical analysis was normal. Telephone follow-up with the owner at 5 months postoperatively revealed the cat to have recovered completely and returned to normal activity.

## Discussion

Bilothorax, either alone or in combination with bilious peritoneal effusion (bilioabdomen), has been rarely reported in both the human and veterinary literature.<sup>1–13</sup> In people, it occurs most commonly as a complication of

percutaneous transhepatic biliary drainage and hepatobiliary surgery.<sup>8–13</sup> In the cat of the present report, partial avulsion and herniation of a bi-lobed gall bladder through the diaphragm resulted in leakage of bile into the right pleural cavity. Confinement of the avulsed region of the gall bladder within the thorax by the adjacent liver lobes precluded development of concurrent biloabdomen.

A total of seven cases of bilothorax, most with concurrent biloabdomen,<sup>1,3,4,7</sup> have been described in dogs and cats in the past two decades, with the majority of these due to trauma.<sup>1–7</sup> Three dogs sustained gunshot injuries which resulted in bile leakage into the thorax through concomitant diaphragmatic defects in two dogs,<sup>1,2</sup> and the formation of a fistula between the gall bladder and the pleural cavity without concurrent bile peritonitis in the remaining dog.<sup>5</sup> One dog developed dyspnoea and bilothorax of unknown aetiology without concurrent peritoneal effusion following cholecystectomy for the management of a gall bladder mucocele.<sup>3</sup> A further dog developed bile peritonitis and bilothorax following traumatic rupture of the extrahepatic biliary tract in the face of an intact diaphragm.<sup>4</sup> In the latter two cases, diffusion of bile constituents across diaphragmatic lymphatics and subsequent damage thereto was suspected to have resulted in leakage of bile into the thorax.<sup>3,4</sup> Only two cases have been reported in cats,<sup>6,7</sup> one of which had isolated bilothorax in the absence of concurrent biloabdomen.<sup>6</sup> The latter cat developed iatrogenic bilothorax without bile peritonitis following the creation of a bilopleural fistula as a complication of thoracostomy tube placement.<sup>6</sup> The second cat developed bile peritonitis and bilothorax as a result of laceration of the diaphragm and cystic duct following gunshot injuries.<sup>7</sup>

This case proved to be a diagnostic challenge for several reasons. While preoperative thoracic radiographs identified increased soft tissue opacity in the right cranial and middle lung lobes and a small volume of caudally located right-sided pleural effusion, these findings were suspected to be secondary to traumatic lung contusion and resultant mild haemothorax. On this basis, and the absence of dyspnoea following initial stabilisation, diagnostic thoracocentesis was not performed as part of the initial diagnostic work-up. Preoperative abdominal ultrasonography had identified a very small gall bladder within the abdominal cavity; however, this did not preclude the possibility of partial disruption of the gall bladder or another part of the extrahepatic biliary tract.<sup>14</sup> This small-sized gall bladder identified ultrasonographically likely represented the lobe of the gall bladder that remained intact on the abdominal surface of the diaphragm. The identification of only a mild increase in total bilirubin on biochemical analysis and peritoneal fluid consistent with a modified transudate further complicated prompt diagnosis of gall bladder rupture. While

gall bladder rupture without associated hyperbilirubinaemia and tissue staining (anicteric gall bladder rupture) has been recently reported in dogs,<sup>15</sup> possible explanations for this finding in the cat described in the present report include continued flow of some bile through the hepatic and common bile ducts and into the descending duodenum, and drainage of the bile to the exterior through the right-sided thoracic wall defect.<sup>15</sup> A high index of suspicion for the presence of bilothorax, however, was present following development of yellow–orange drainage from the right thoracic wall wound and was quickly confirmed by comparison of fluid and peripheral blood bilirubin concentrations (wound fluid bilirubin:peripheral blood bilirubin ratio >1).<sup>3,6,7</sup>

The prognosis for dogs and cats with bilothorax receiving appropriate medical or surgical intervention appears to be excellent, with all reported cases having survived to discharge, similar to the cat of the present report.<sup>1–7</sup> However, this may reflect a publication bias. Five cases were managed surgically,<sup>1,2,5–7</sup> whereas the remaining two were managed with repeated drainage and supportive care,<sup>3,4</sup> combined with administration of oral prednisolone in one case.<sup>3</sup> The optimal treatment of bilothorax in dogs and cats is unknown, in large part due to only isolated published reports.<sup>1–7</sup> While the authors of one clinical report recommend surgical exploration for cases that do not respond to initial thoracocentesis or thoracostomy tube placement, we believe treatment to be strongly case dependent and influenced by several factors, including the nature and size of biliary disruption, the presence of concomitant injuries (eg, penetrating abdominal wounds or diaphragmatic hernia), and the haemodynamic stability of the animal.<sup>6</sup> In the cat reported by Wustefeld-Janssens et al,<sup>6</sup> inadvertent penetration of the diaphragm and gall bladder during thoracostomy tube placement for the management of pyothorax resulted in the creation of 2–3 mm defects in the diaphragm and gall bladder and the formation of a bilopleural fistula. In our case, the identification of a defect in the abdominal wall with protrusion of abdominal fat was, in itself, an indication for immediate abdominal exploration.<sup>16</sup> It is interesting to note that a positive bacterial culture was not isolated from the bilious pleural effusion in any of the previously reported cases of bilothorax.<sup>1–7</sup> It is well known in cases of bile peritonitis that dogs and cats with concurrent bacterial infection have significantly higher mortality rates compared to those without.<sup>17</sup> No bacterial growth was isolated from the peritoneal or pleural effusion in the cat of the present report. *S. marcescens* was isolated from the right-sided wound; however, this was suspected to be a contaminant.

## Conclusions

To our knowledge, at the time of writing non-iatrogenic isolated bilothorax without concurrent biloabdomen has not been previously reported in the cat. This case

highlights the importance of thorough assessment of cats with seemingly innocuous thoracic bite wounds. Despite the rarity of its occurrence, biliothorax should be considered a differential in cats with pleural effusion, even in the absence of bile peritonitis. We believe that the optimal treatment of cases of biliothorax is multifactorial and should be determined on a case-by-case basis.

**Funding** The authors received no financial support for the research, authorship, and/or publication of this article.

**Conflict of interest** The authors declared no potential conflicts of interest with respect to the research, authorship, and/or publication of this article.

## References

- Bellenger CR, Trim C and Summer-Smith G. **Bile pleuritis in a dog.** *J Small Anim Pract* 1975; 16: 575–577.
- Davis KM and Spaulding KA. **Imaging diagnosis: bilio-pleural fistula in a dog.** *Vet Radiol Ultrasound* 2004; 45: 70–72.
- Guillaumin J, Chanoit G, Decosne-junot C, et al. **Biliothorax following cholecystectomy in a dog.** *J Small Anim Pract* 2006; 47: 733–736.
- Barnhart MD and Rasmussen LM. **Pleural effusion as a complication of extrahepatic biliary tract rupture in a dog.** *J Am Anim Hosp Assoc* 1996; 32: 409–412.
- Bartolin F, Didier M, Ludica B, et al. **What is your diagnosis? Pleural effusion in a dog with a gunshot wound.** *Vet Clin Pathol* 2015; 44: 333–334.
- Wustefeld-Janssens BG, Loureiro JF, Dukes McEwan J, et al. **Biliothorax in a Siamese cat.** *J Feline Med Surg* 2011; 13: 984–987.
- Murgia D. **A case of combined biliothorax and bile peritonitis secondary to gunshot wounds in a cat.** *J Feline Med and Surg* 2013; 15: 513–516.
- Strange C, Allen ML, Freedland PN, et al. **Bilio-pleural fistula as a complication of percutaneous biliary drainage: experimental evidence for pleural inflammation.** *Am Rev Respir Dis* 1988; 137: 959–961.
- Bilal M, Chong J and Lega M. **Education and imaging. Hepatology: biliothorax after percutaneous transhepatic biliary drainage.** *J Gastroenterol Hepatol* 2015; 30: 802.
- Hamers LAC, Bosscha K, van Leuken MH, et al. **Biliothorax: a bitter complication of liver surgery.** *Case Rep Surg* 2013; 2013: 372827
- Kim SH and Zangan SM. **Percutaneous transhepatic biliary drainage complicated by biliothorax.** *Semin Intervent Radiol* 2015; 32: 54–56.
- Sano A and Yotsumoto T. **Biliothorax as a complication of percutaneous transhepatic biliary drainage.** *Asian Cardio-vasc Thorac Ann* 2016; 24: 101–103.
- Basu S, Bhadani S and Shukla VK. **A dangerous pleural effusion.** *Ann R Coll Surg Engl* 2010; 92: 53–54.
- Parchman MB and Flanders JA. **Extrahepatic biliary tract rupture: evaluation of the relationship between the site of rupture and the cause of rupture in 15 dogs.** *Cornell Vet* 1990; 80: 267–272.
- Guess SC, Harkin KR and Biller DS. **Anicteric gallbladder rupture in dogs: 5 cases (2007–2013).** *J Am Vet Med Assoc* 2015; 247: 1412–1414.
- Bjorling DE, Crowe DT, Kolata RJ, et al. **Penetrating abdominal wounds in dogs and cats.** *J Am Anim Hosp Assoc* 1982; 18: 742.
- Ludwig LL, McLoughlin MA, Graves TK, et al. **Surgical treatment of bile peritonitis in 24 dogs and 2 cats: a retrospective study.** *Vet Surg* 1997; 26: 90–98.