



Dynamic chronic rectal obstruction causing a severe colonic dilatation in a cat

Authors: García-Pertierra, Sofia, González-Gasch, Esteban, Catalá Puyol, Carmen, and Closa Boixeda, Jose María

Source: Journal of Feline Medicine and Surgery Open Reports, 3(2)

Published By: SAGE Publishing

URL: <https://doi.org/10.1177/2055116917725222>

BioOne Complete (complete.BioOne.org) is a full-text database of 200 subscribed and open-access titles in the biological, ecological, and environmental sciences published by nonprofit societies, associations, museums, institutions, and presses.

Your use of this PDF, the BioOne Complete website, and all posted and associated content indicates your acceptance of BioOne's Terms of Use, available at www.bioone.org/terms-of-use.

Usage of BioOne Complete content is strictly limited to personal, educational, and non - commercial use. Commercial inquiries or rights and permissions requests should be directed to the individual publisher as copyright holder.

BioOne sees sustainable scholarly publishing as an inherently collaborative enterprise connecting authors, nonprofit publishers, academic institutions, research libraries, and research funders in the common goal of maximizing access to critical research.



Dynamic chronic rectal obstruction causing a severe colonic dilatation in a cat

Sofia García-Pertierra, Esteban González-Gasch, Carmen Catalá Puyol and Jose María Closa Boixeda

Journal of Feline Medicine and Surgery Open Reports
1–5

© The Author(s) 2017

Reprints and permissions:

sagepub.co.uk/journalsPermissions.nav

DOI: 10.1177/2055116917725222

journals.sagepub.com/home/jfmsopenreports

This paper was handled and processed by the European Editorial Office (ISFM) for publication in *JFMS Open Reports*



Abstract

Case summary A 5-year-old male neutered domestic shorthair cat was presented to our referral centre with a 13 month history of chronic tenesmus due to malunion of the right caudal iliac body. Constipation and pelvic canal stenosis were initially addressed by the referring veterinarian with a right femoral head and neck excision and a right acetabulectomy without observable clinical improvement. At admission, abdominal radiographs revealed severe colonic distension and a narrowed pelvic canal caused by the right proximal femur. Rectal examination and colonography revealed a dynamic compression of the rectum, which worsened with femoral abduction and improved with femoral adduction. A right hindlimb amputation was performed to relieve the obstruction. The cat defaecated 2 days postoperatively and was discharged uneventfully. Neither faecal tenesmus nor dyschaezia were observed over the following 10 months.

Relevance and novel information The dynamic nature of the rectal obstruction most likely prevented the development of an irreversible colonic dilatation leading to a megacolon. This is the first report describing a chronic dynamic rectal compression, which was successfully managed with a right hindlimb amputation without the need for subtotal colectomy.

Accepted: 13 July 2017

Introduction

Constipation and obstipation are clinical signs related to the same problem but differ in their severity. Constipation has been defined as absent, infrequent or difficult defaecation associated with the retention of faeces within the colon and rectum.^{1,2} Intractable constipation that has become refractory to cure or control is referred to as obstipation.² Megacolon is a persistent, irreversible increase in colonic diameter and is the most advanced stage of chronic constipation.³ Any event that slows faecal transit or obstructs colonic flow can eventually lead to constipation, obstipation or megacolon.² Megacolon can be classified as primary or secondary depending on its aetiology. The most common aetiology of feline primary megacolon is idiopathic. Secondary megacolon is due to many conditions such as pelvic fractures, neoplasia, anal or rectal stricture, anal atresia and neurological disorders. Pelvic fracture malunion accounts for approximately 25% of all secondary megacolon cases.⁴

This report describes the diagnosis and surgical treatment of a dynamic obstruction of the rectum causing chronic colonic dilatation and intractable constipation in a cat.

Case description

A 5-year-old male neutered domestic shorthair cat was presented to our referral hospital for evaluation of a 13 month history of chronic constipation. The cat was a stray, which had been adopted before presentation to the referring veterinarian. Initial pelvic radiographs

Hospital Ars Veterinaria, Barcelona, Spain

Corresponding author:

Sofia García-Pertierra DVM, Hospital Ars Veterinaria, Calle Cardedeu 3, Barcelona, Cataluña, 08023, Spain

Email: s.garciapertierra@gmail.com



Creative Commons Non Commercial CC BY-NC: This article is distributed under the terms of the Creative Commons

Attribution-NonCommercial 4.0 License (<http://www.creativecommons.org/licenses/by-nc/4.0/>) which permits non-commercial use, reproduction and distribution of the work without further permission provided the original work is attributed as specified on the SAGE and Open Access pages (<https://us.sagepub.com/en-us/nam/open-access-at-sage>).

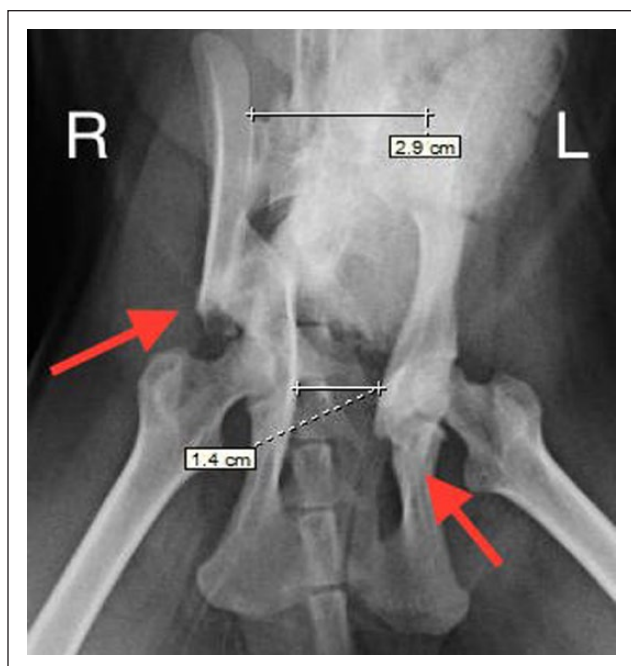


Figure 1 Ventrodorsal pelvic radiographs (initial referring practice radiographs). Malunion of the right caudal iliac body (left arrow) and malunion of the left caudal acetabulum (right arrow). Sacral index of 0.48 (52% of pelvic narrowing, according to Hamilton et al⁵). R = right; L = left

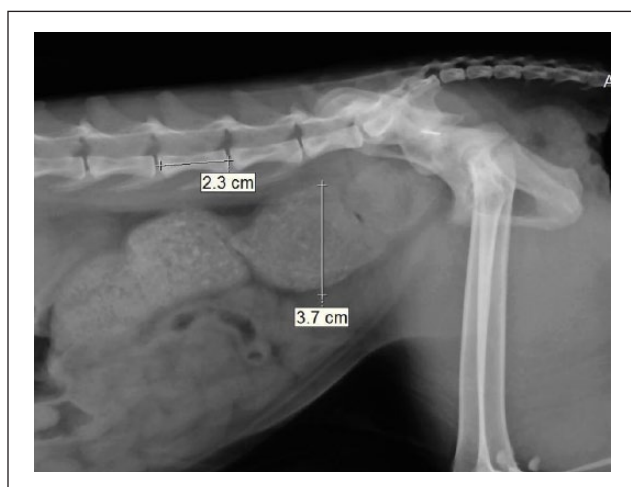


Figure 2 Right lateral caudal abdominal radiograph (initial referring practice radiographs). Colonic diameter 3.7 cm. Ratio of colonic diameter to L5 length is 1.61, compatible with megacolon (a ratio >1.48 is suggestive of megacolon, according to Trevail et al⁶)

were performed by the referring veterinarian, which showed malunion of the right caudal iliac body and the left caudal acetabulum. Fractures on both cranial pubic ramii were also noticed. The exact time or aetiology of the fractures were unknown. Severe stenosis of the pelvic canal due to malunion of the right caudal

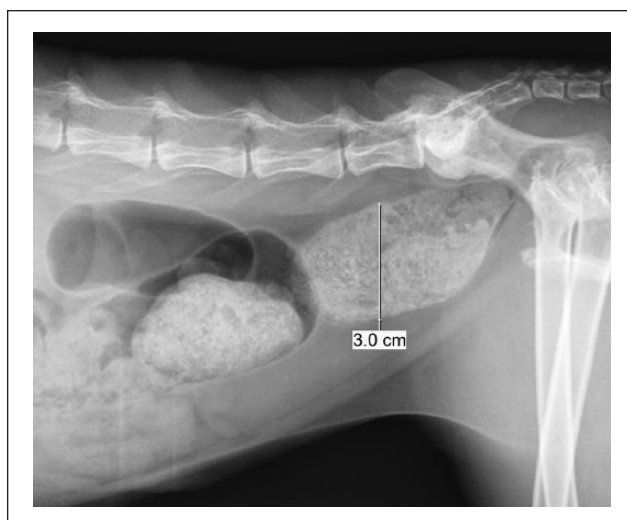


Figure 3 Right lateral caudal abdominal radiograph (admission radiographs at our referral hospital; 13 months after initial referring practice radiographs). Colonic diameter 3.0 cm. Ratio of colonic diameter to L5 length is 1.3, compatible with colonic distension

iliac body with 52% narrowing of the pelvic canal, as described by Hamilton et al,⁵ was observed (Figure 1). Based on the colonic ratios described by Trevail et al,⁶ a dilated colon suggestive of megacolon was also noticed (colonic diameter of 3.7 cm; colonic diameter to L5 length ratio of 1.61; Figure 2). The referring veterinarian performed a femoral head and neck excision (FHNE) and an acetabulectomy of the right femur. Persistent constipation was observed after surgery. Therefore, oral lactulose (0.5 ml/kg PO q8h Duphalac; Abbot) and weekly warm-water enemas were started. Constipation did not improve after initiating medical management.

At admission to our referral centre, physical examination was unremarkable, except for mild muscular atrophy on both hindlimbs, which was more severe on the right side. Neurological examination revealed mild ambulatory monoparesis of the right hindlimb with decreased cutaneous sensation in the right thigh. Withdrawal reflex was decreased in the right hindlimb. Perineal reflex was normal and rectal examination was not painful. Neurological examination of the left hindlimb was unremarkable with normal patellar and withdrawal reflexes. On abdominal radiographs, colonic distension without megacolon was noted (colonic diameter 3.0 cm; colonic diameter to L5 length ratio of 1.3). Pelvic canal narrowing was 62% (Figures 3 and 4). Bloodwork was within normal limits, except for a positive feline immunodeficiency virus SNAP test (SNAP FIV/FeLV Combo test; IDEXX).

The cat was anaesthetised the day after admission for an enema administration. A dynamic obstruction of the

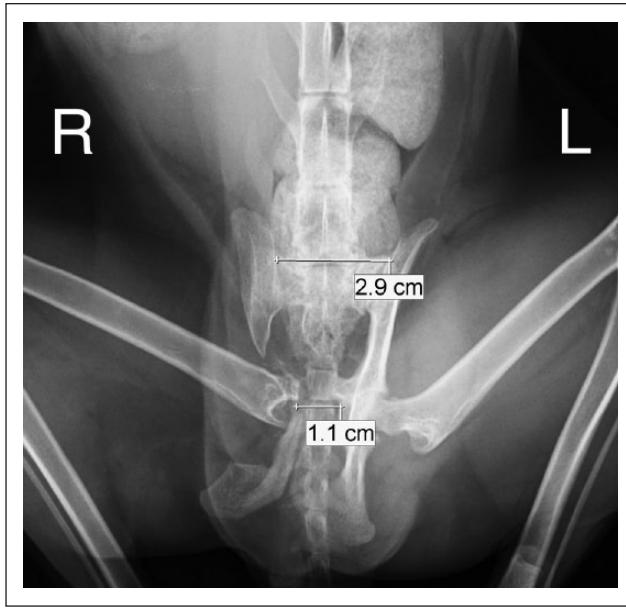


Figure 4 Ventrodorsal pelvic radiograph (admission radiographs at our referral hospital, 13 months after initial referring practice radiographs). Right acetabulectomy and femoral head and neck excision can be observed on the right hemipelvis. Sacral index of 0.38 (62% of pelvic narrowing). R = right; L = left

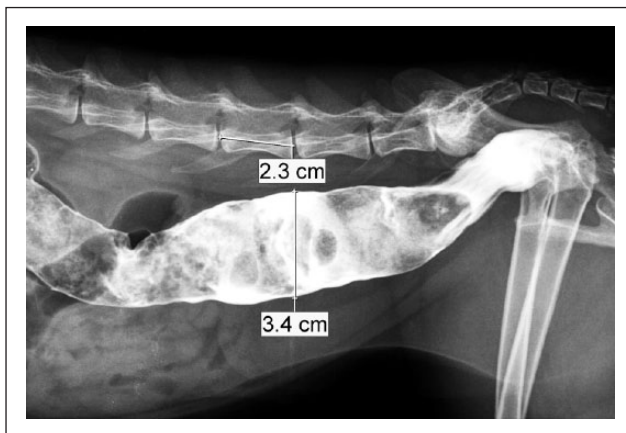


Figure 5 Right lateral caudal abdominal radiograph after colonography (1 day after admission at our referral centre). Colonic diameter 3.4 cm. Ratio of colonic diameter to L5 length is 1.48, compatible with borderline megacolon

rectum was noted on rectal examination. When the right hindlimb was abducted, the rectum was compressed by the proximal femur; when it was adducted, the compression was relieved. Digital palpation of the rectum did not reveal any stricturing fibrotic tissue.

A colonography was performed under the same general anaesthesia. A volume of 5 ml of iodine contrast (Urografin; Bayer) diluted with 5 ml saline was injected intrarectally. A rectal compression could be visualised,

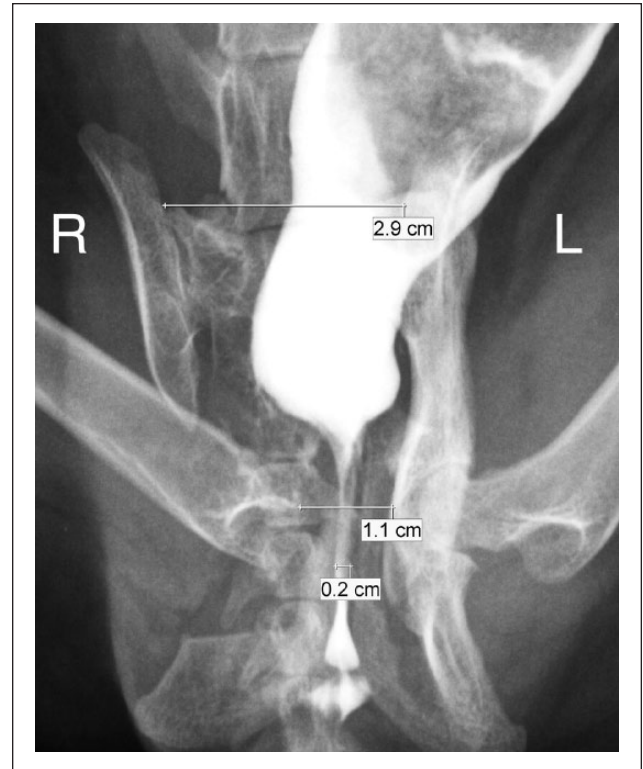


Figure 6 Ventrodorsal pelvic radiograph after colonography (1 day after admission at our referral centre). Rectal stricture of 2 mm can be seen due to abduction of the right femur. Sacral index of 0.07. Narrowing of the pelvic canal of 93%. R = right; L = left

which was caused by impingement of the proximal part of the femur on the adjacent area, where the right acetabulectomy had been performed (Figures 5 and 6). The pelvic canal diameter at the level of the rectal compression was 2 mm. Colonic diameter was 3.4 cm, with a colonic diameter to L5 length ratio of 1.48. At this time, as the cat had been hyporexic for 3 days prior to presentation, it was decided to place an oesophagostomy tube while the cat was still under anaesthesia.

A right hindlimb amputation was recommended in order to relieve the dynamic rectal obstruction caused by the proximal part of the femur. The cat was premedicated with buprenorphine (0.015 mg/kg IM Buprenodale; Dechra) and meloxicam (0.1 mg/kg SC Metacam; Boehringer Ingelheim). Anaesthesia was induced with propofol (4 mg/kg IV Lipuro; Braun) and midazolam (0.3 mg/kg IV Midazolam; Normon) and it was maintained with isoflurane (Isovet; Braun) and oxygen during the procedure. A standard lateral approach for a coxofemoral disarticulation was performed. Meticulous dissection was performed around the fibrotic tissue surrounding the proximal part of the femur adjacent to the rectum. This fibrotic tissue was bluntly dissected off the rectal wall and around the sciatic nerve to avoid

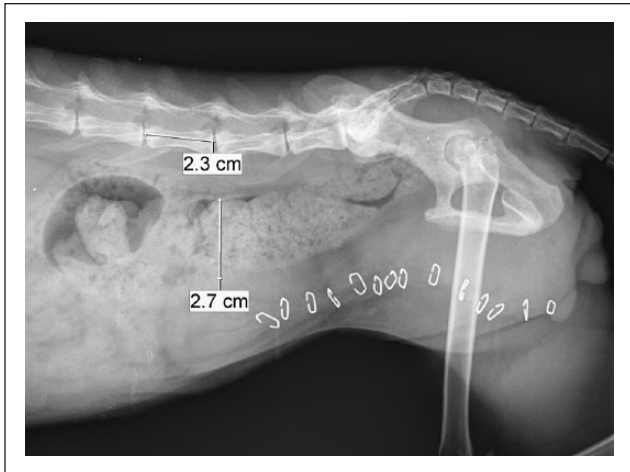


Figure 7 Right lateral caudal abdominal radiograph taken 2 days after right hindlimb amputation. Colonic diameter decreased to 2.7 cm and megacolon was not observed. Ratio of colonic diameter to L5 length was 1.17 (within normal limits)

damaging these structures. A sciatic nerve block was performed using bupivacaine (0.5 mg/kg Bupivacaine 0.5%; Braun). The rest of the femoral muscular attachments were cut with diathermy. An incisional catheter was inserted for local analgesia. Muscular fascia and subcutaneous tissue were sutured with 3/0 polydioxanone (Monoplus; Braun). The skin was closed using staples. After surgery, rectal examination did not reveal any signs of rectal obstruction.

During hospitalisation, the cat was treated with oral lactulose (0.5 ml/kg PO q8h for 2 days [Duphalac; Abbot]), cefazoline (25 mg/kg IV q8h for 5 days [Cefazolina Normon; Normon Laboratories]), meloxicam (0.05 mg/kg SC q24h for 10 days [Metacam; Boehringer Ingelheim]), incisional bupivacaine (0.5 mg/kg q8h for 2 days [Bupivacaine 0.5%; Braun]) and buprenorphine (0.015 mg/kg IV q6h for 5 days [Buprenodale; Dechra]). The cat voluntarily defaecated 2 days after the surgery and started eating 3 days postoperatively. Oral lactulose was stopped just after defaecation. The oesophagostomy tube was removed 4 days postoperatively. Radiographs performed just after defaecation showed moderate colonic distension (2.7 cm in diameter) with an unobstructed pelvic canal (Figure 7). At the request of the owners, the cat was kept hospitalised for 2 weeks. Then, the cat was discharged uneventfully without any medications. The owners were contacted by telephone at the time of writing this case report (10 months post-amputation). No faecal tenesmus or dyschaezia had been noticed during this time. The cat has been able to walk and jump without manifesting any problems, despite the right hindlimb amputation.

Discussion

This case report describes a cat with chronic constipation lasting for over a year due to an iliac fracture malunion. Pelvic fractures are common in cats, accounting for 20–32% of all fractures.⁷ A large retrospective study investigating pelvic fractures in cats reported that 49% of the cats had iliac fractures and 26% had acetabular fractures.⁸ Historically, feline pelvic fractures have been managed conservatively.⁷ However, there has been a shift towards surgical management over the past few years.⁹ Several complications can be associated with pelvic fractures such as pelvic canal stenosis and secondary constipation, disruption of the weightbearing axis that can be associated with an inability to ambulate, and sciatic or sacral nerve impingement resulting in urinary and neurological deficits, as well as severe pain.⁹ Pelvic canal narrowing >45–50% has been suggested as a risk factor for obstipation/constipation.^{5,9} This narrowing may induce megacolon, requiring surgical treatment such as subtotal colectomy and/or pelvic osteotomies.¹⁰

Iliac fractures, either affecting the iliac body or the iliac wing, must be surgically repaired because they affect the weightbearing forces transmitted to the spine.^{5,9} In the case described here, a malunion of the right caudal iliac body caused pelvic canal stenosis of 52%, which was initially managed with a FHNE and an acetabulectomy. The lack of acetabular support produced a dynamic compression of the rectum caused by the proximal femur. Pelvic canal narrowing should be corrected by either performing a corrective osteotomy, stabilised with a plate on the iliac wing and body to widen the pelvic canal, or by distracting the pubic symphysis (symphyseal distraction-osteotomy).¹¹ A recent study by Meeson and Geddes¹⁰ could not find any relationship between obstipation and constipation and the degree of pelvic canal narrowing when considering narrowing of the pelvic canal up to 50%.

When this case was referred to our practice, pelvic canal stenosis caused by the proximal femur was 62%. However, the colonography revealed an actual pelvic canal narrowing of 93%, which had been previously missed because of the dynamic nature of the femur compression. Survey abdominal and pelvic radiographs are typically performed in order to identify underlying causes of constipation and to assess the content and diameter of the colon.³ In this case, a dilated colon was seen on pelvic radiographs, but the radiographs underestimated the actual degree of pelvic canal stenosis, which was later observed during colonography. Therefore, it is recommended to perform a colonography in cases where the obstruction is thought to be dynamic. Both colonography and digital rectal examination revealed the dynamic rectal stenosis that was being caused by the right proximal femur. It is likely that the

femur was causing impingement on the pelvic canal when the cat was weightbearing and squatting in its litter tray, as there was no acetabular support to prevent this from happening.

Megacolon is defined as a colon diameter >1.48 times the length of the fifth lumbar vertebra (L5).⁶ In this case, the initial colonic diameter measured at admission was 3.0 cm (colonic diameter to L5 ratio of 1.3), which increased to 3.4 cm during the colonography performed 1 day after admission (colonic diameter to L5 ratio of 1.48). Based on these results a severe colonic dilatation without megacolon was diagnosed. However, previous pelvic radiographs performed at the referring veterinarian had shown megacolon with a colonic diameter of 3.7 cm (colonic diameter to L5 ratio of 1.61). The absence of megacolon after 13 months of chronic constipation might be explained by the dynamic nature of the obstruction. The pathophysiology of megacolon is described as a colonic distension and chronic obstipation that eventually renders the colonic muscle non-functional, leading to irreversible changes in colonic smooth muscle and nerves, and causing inertia.¹² Outlet obstruction will initially result in the development of a hypertrophic megacolon, often reversible with the early removal of the colonic outflow obstruction.¹³ The degree of distension and the time needed to produce irreversible changes are unknown, although both are likely to be important factors. Some authors have suggested that pelvic osteotomies are only advised if the megacolon has been present for less than 6 months; otherwise, the changes on the colonic wall are deemed to be permanent and subtotal colectomy is the recommended procedure.^{3,12} However, distraction osteotomy procedures have been reported in two cats with obstipation and constipation of 6 months' and 8 months' duration, respectively, both with excellent outcomes.¹⁴

In this case, the cat had been constipated for 13 months and had a severely dilated colon but no obvious megacolon, except for the one time in which megacolon was observed on the radiographic study initially performed at the referring practice. A subtotal colectomy was initially discussed with the owners, because of the likelihood of having an impaired colonic peristalsis. However, after discovering that the rectal obstruction appeared to be intermittent, a right hindlimb amputation was advised. The dynamic nature of the obstruction may have allowed the colonic wall to maintain its normal structure. After the amputation, the colonic diameter decreased and the cat was able to defaecate without any straining or tenesmus. Therefore, cats might benefit from surgical procedures to relieve outlet obstructions, even if the clinical signs have been present for longer than 6 months, especially in cases of dynamic lesions.

To our knowledge, this is the first report of a dynamic rectal obstruction causing constipation and colonic dilatation in a cat.

Conclusions

A dynamic obstruction of the rectum caused by the proximal femur may be observed when the acetabular support is no longer available. Diagnosis can be made by rectal examination and colonography. Survey abdominal radiographs may underestimate the severity of the pelvic narrowing. Releasing the outlet obstruction must be considered before performing a subtotal colectomy, even if the constipation and tenesmus have been present for more than 6 months.

Conflict of interest The authors declared no potential conflicts of interest with respect to the research, authorship, and/or publication of this article.

Funding The authors received no financial support for the research, authorship, and/or publication of this article.

References

- 1 Yam P. **Decision making in the management of constipation in the cat.** *In Pract* 1997; 19: 434–440.
- 2 Foley P. **Constipation, tenesmus, dyschezia, and fecal incontinence.** In: Ettinger SJ, Feldman EC and Côté E (eds). *Textbook of veterinary internal medicine*. 8th ed. Philadelphia, PA: WB Saunders, 2017, pp 171–174.
- 3 Bertoy RW. **Megacolon in the cat.** *Vet Clin North Am Small Anim Pract* 2002; 32: 901–915.
- 4 Washabau RJ and Hasler AG. **Constipation, obstipation and megacolon.** In: August JR (ed). *Consultations in feline internal medicine*. 3rd ed. Philadelphia, PA: Saunders, 1997, pp 104–111.
- 5 Hamilton MH, Evans DA and Langley-Hobbs SJ. **Feline ilial fractures: assessment of screw loosening and pelvic canal narrowing after lateral plating.** *Vet Surg* 2009; 38: 326–333.
- 6 Trevail T, Gunn-Moore D, Carrera I, et al. **Radiographic diameter of the colon in normal and constipated cats and in cats with megacolon.** *Vet Radiol Ultrasound* 2011; 52: 516–520.
- 7 Hill FW. **A survey of bone fractures in the cat.** *J Small Anim Pract* 1977; 18: 457–463.
- 8 Bookbinder PE and Flanders JA. **Characteristics of pelvic fracture in the cat. A 10-year retrospective study.** *Vet Comp Orthop Traumatol* 1992; 5: 37–42.
- 9 Meeson R and Corr S. **Management of pelvic trauma.** *J Feline Med Surg* 2011; 13: 347–361.
- 10 Meeson RL and Geddes AT. **Management and long-term outcome of pelvic fractures: a retrospective study of 43 cats.** *J Feline Med Surg* 2017; 19: 36–41.
- 11 Witte P and Scott H. **Conditions of the feline pelvic region.** *In Pract* 2012; 34: 498–511.
- 12 Ryan SD. **Megacolon.** In: Monnet E (ed). *Small animal soft tissue surgery*. Ames, IA: John Wiley, 2013, pp 387–397.
- 13 Washabau RJ and Holt D. **Pathogenesis, diagnosis, and therapy of feline idiopathic megacolon.** *Vet Clin North Am Small Anim Pract* 1999; 29: 589–603.
- 14 Prassinis NN, Adamama-Moraitou KK, Gouletsou PG, et al. **Symphyseal distraction-osteotomy using a novel spacer of spirally fashioned orthopaedic wire for the management of obstipation.** *J Feline Med Surg* 2007; 9: 23–28.