



## **Cutaneous non-epitheliotropic T-cell lymphoma associated with a fracture site in a cat**

Authors: Jegatheeson, Selvi, Wayne, Julie, and Brockley, Laura K

Source: Journal of Feline Medicine and Surgery Open Reports, 4(1)

Published By: SAGE Publishing

URL: <https://doi.org/10.1177/2055116918760357>

---

BioOne Complete ([complete.BioOne.org](https://complete.BioOne.org)) is a full-text database of 200 subscribed and open-access titles in the biological, ecological, and environmental sciences published by nonprofit societies, associations, museums, institutions, and presses.

Your use of this PDF, the BioOne Complete website, and all posted and associated content indicates your acceptance of BioOne's Terms of Use, available at [www.bioone.org/terms-of-use](https://www.bioone.org/terms-of-use).

Usage of BioOne Complete content is strictly limited to personal, educational, and non - commercial use. Commercial inquiries or rights and permissions requests should be directed to the individual publisher as copyright holder.

---

BioOne sees sustainable scholarly publishing as an inherently collaborative enterprise connecting authors, nonprofit publishers, academic institutions, research libraries, and research funders in the common goal of maximizing access to critical research.



# Cutaneous non-epitheliotropic T-cell lymphoma associated with a fracture site in a cat

Selvi Jegatheeson<sup>1</sup>, Julie Wayne<sup>2</sup> and Laura K Brockley<sup>1</sup>

*Journal of Feline Medicine and Surgery Open Reports*  
1–6

© The Author(s) 2018

Reprints and permissions:

sagepub.co.uk/journalsPermissions.nav

DOI: 10.1177/2055116918760357

journals.sagepub.com/home/jfmsopenreports

This paper was handled and processed by the European Editorial Office (ISFM) for publication in *JFMS Open Reports*



## Abstract

**Case summary** A 7-year-old male neutered domestic shorthair cat presented for investigation of a swelling over the right forelimb. Radiographs of the right forelimb revealed significant lysis and soft tissue swelling surrounding a previously implanted surgical plate, used to repair a fracture of the distal radius 5 years prior. The implant was removed, and a biopsy was collected. Histopathological analysis and immunohistochemistry diagnosed a non-epitheliotropic T-cell cutaneous lymphoma. Staging confirmed multiple regional lymph node involvement. The cat was started on a CHOP-based protocol (vincristine, doxorubicin, cyclophosphamide and prednisolone). At week 4, the disease progressed both locally and within the regional lymph nodes. The primary lesion became severely ulcerated and the cat was euthanased, 42 days post-diagnosis.

**Relevance and novel information** This is the first report of a cutaneous non-epitheliotropic lymphoma developing at the site of a previous traumatic fracture and metal implant. The cat's response to chemotherapy was poor and euthanasia was performed owing to progressive disease. More investigation is required to understand the role that malignant transformation could have at sites of chronic inflammation, bone fractures and surgical implants.

**Accepted:** 3 January 2018

## Case description

A 7-year-old, 4.0 kg male neutered cat was referred to Victorian Animal Cancer Care, Melbourne, Australia, for treatment of cutaneous non-epitheliotropic lymphoma (CNEL).

Six years prior to presentation, the cat underwent a traumatic event (suspected road traffic accident), which resulted in a fracture of the right distal radius and ulna. At this time, the fracture was repaired using a metal implant. Five years later, the patient re-presented to its local veterinarian for assessment of swelling in this region.

Cytological assessment of fine-needle aspirates taken from the swelling revealed degenerate neutrophils. A 2 week course of amoxicillin and clavulanic acid (12.5 mg/kg PO q12h) was dispensed, and over the following 12 months, the wound swelled intermittently. Nine months after the initial course of antibiotics, an open, discharging lesion was present at the site. Repeat fine-needle aspiration and cytology revealed degenerate neutrophils only, and a 2 week course of marbofloxacin (5 mg/kg PO q24h) was dispensed, but there was no improvement. Two weeks later a mass was palpated deep to the draining sinus. Radiographs

of the limb revealed significant lysis and soft tissue swelling around two loose screws at the previous surgical site (Figure 1). It was noted that the original transverse fracture appeared to have healed apart from a small defect at the lateral aspect of the distal radius. The loose screws were removed under general anaesthesia, and a swab of the tissue was taken for culture. Cefovecin (8 mg/kg SC) was administered immediately postoperatively. Given the concern for infection, a repeat surgery was planned for 3 weeks later to remove the bone plate and remaining screws. An incisional biopsy of the abnormal tissue was taken at the time of the second surgery, and stored in formalin (histopathological assessment was declined owing to financial constraints). The culture taken perioperatively did not

<sup>1</sup>Victorian Animal Cancer Care, Box Hill South, Victoria, Australia

<sup>2</sup>ASAP Laboratory, Mulgrave, Victoria, Australia

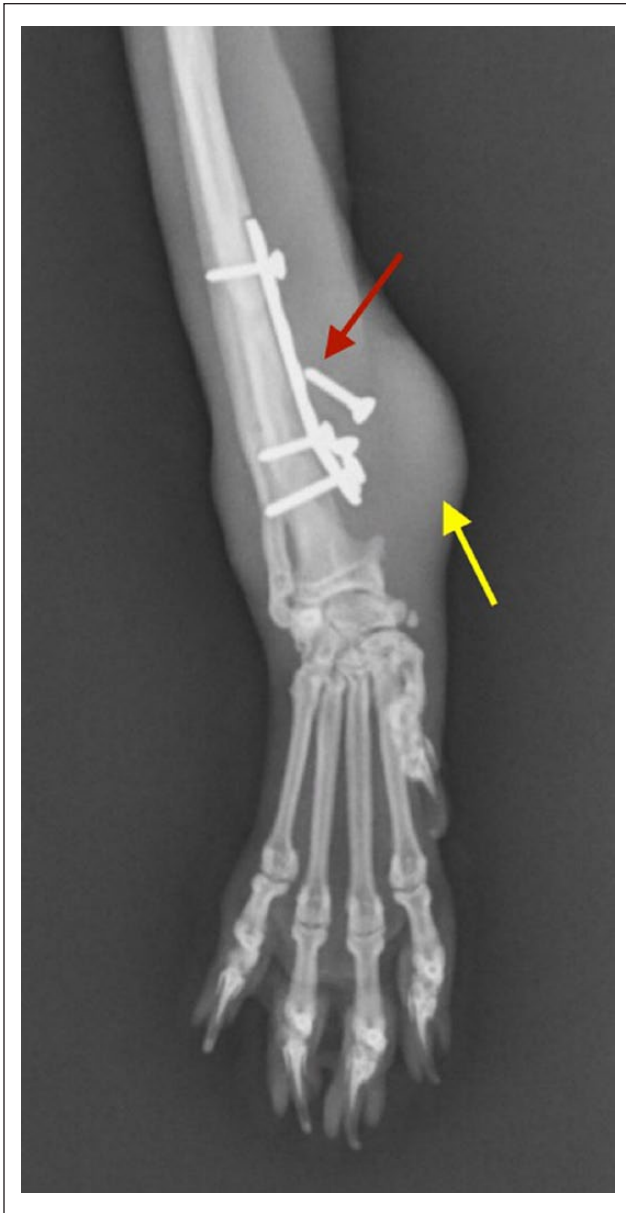
### Corresponding author:

Selvi Jegatheeson DVM, Victorian Animal Cancer Care, 316A Station Street, Box Hill South, Victoria, 3128, Australia  
Email: sjeg001@gmail.com



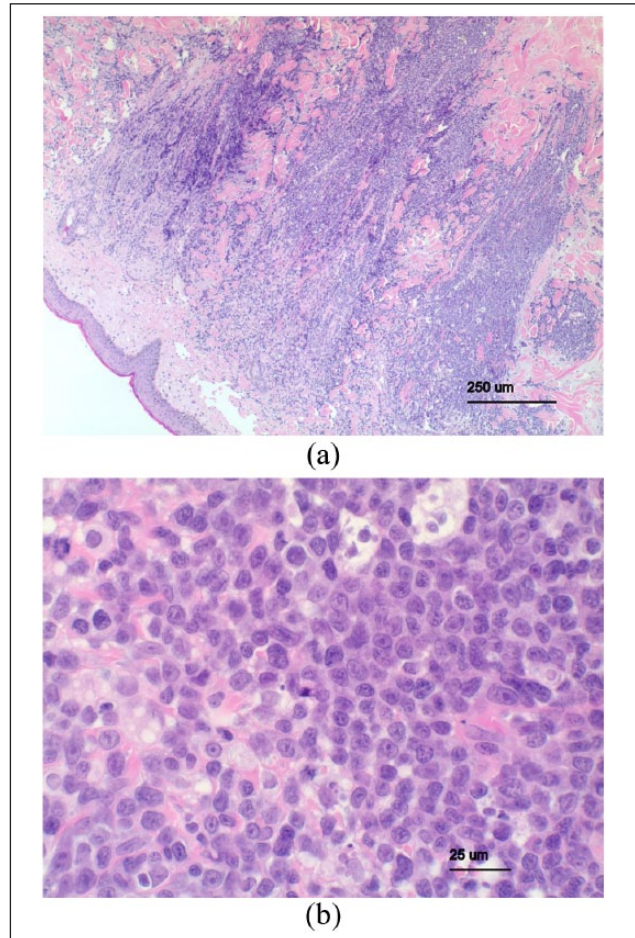
Creative Commons Non Commercial CC BY-NC: This article is distributed under the terms of the Creative Commons

Attribution-NonCommercial 4.0 License (<http://www.creativecommons.org/licenses/by-nc/4.0/>) which permits non-commercial use, reproduction and distribution of the work without further permission provided the original work is attributed as specified on the SAGE and Open Access pages (<https://us.sagepub.com/en-us/nam/open-access-at-sage>).

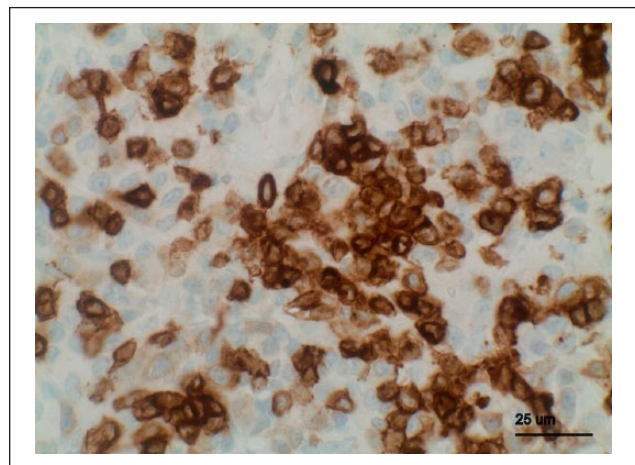


**Figure 1** Radiograph of the right distal forelimb (dorsopalmar view) showing loose screws (red arrow) and associated soft tissue swelling (yellow arrow)

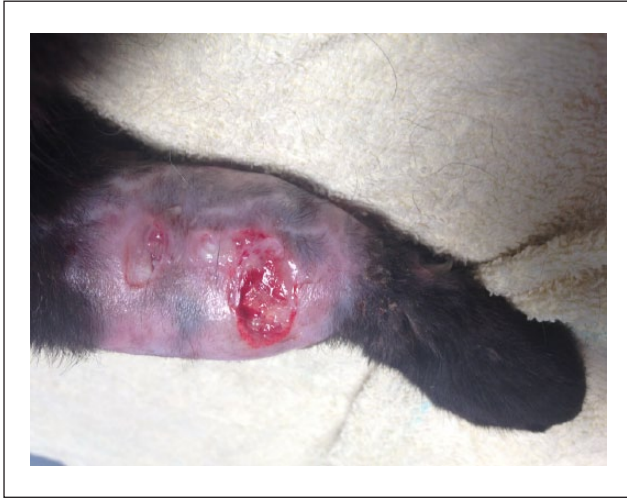grow any bacterial species. One month following the procedure, the patient became non-weight-bearing lame on the right forelimb, and the wound became ulcerated. The cat was recommenced on marbofloxacin (5 mg/kg PO q24h), cefovecin (8 mg/kg SC) and meloxicam (0.3 mg/kg SC). The biopsied tissue was then submitted for histopathology, approximately 2 months after it had been collected. Histological examination of the biopsy revealed medium-to-large-sized neoplastic round cells infiltrating through the dermis and subcutis, most consistent with a cutaneous round-cell tumour. There was no evidence of epitheliotropism (Figure 2). The neoplastic cells showed high mitotic



**Figure 2** (a) Haematoxylin and eosin photomicrograph (X 40) revealing a poorly defined, densely cellular tumour infiltrating through the dermis. (b) Haematoxylin and eosin photomicrograph (X 200) showing a monomorphic population of neoplastic round cells



**Figure 3** Immunohistochemistry against CD3, counterstained with haematoxylin (X 200). Many of the neoplastic cells exhibit moderate-to-strong cytoplasmic staining indicating a tumour of T lymphocyte origin



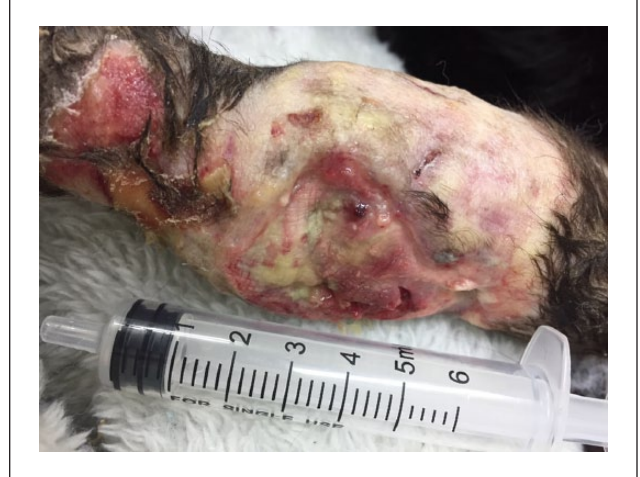**Figure 4** Photograph of the primary lesion at time of referral to Victorian Animal Cancer Care

activity, up to 15 mitotic figures per high-powered field. Immunohistochemistry confirmed a predominant population of round cells exhibiting strong cytoplasmic positivity for CD3 antigen (Figure 3). These findings indicated a diagnosis of cutaneous non-epitheliotropic T-cell lymphoma.

Two weeks later, the cat presented to Victorian Animal Cancer Care, Melbourne, Australia, where the primary lesion was ulcerated and swollen (Figure 4). On clinical examination, the right pre-scapular and right axillary lymph nodes were enlarged, measuring  $2.3 \times 2.2 \times 2.0$  cm and  $1.5 \times 2.0 \times 2.0$  cm, respectively. All other peripheral nodes were within normal limits. Fine-needle aspiration and cytology from the right pre-scapular and axillary lymph nodes revealed large atypical lymphocytes with round, irregularly lobulated nuclei, varied nuclear size and high levels of mitotic figures, consistent with a large-cell, likely high-grade lymphoma. Haematology and serum biochemical analyses were performed. Cytological examination of peripheral blood revealed rare atypical lymphocytes; however, the haematology panel was otherwise unremarkable. There was a mild elevation in aspartate transaminase (122 U/l; reference interval [RI] 10–60 U/l) and creatine kinase (439 U/l; RI 50–300 U/l). The urine specific gravity was 1.038, thus the urine was adequately concentrated.

#### Management and outcome

The cat was treated with a modified version of the University of Wisconsin-Madison protocol for feline lymphoma, a chemotherapy protocol based on CHOP (vincristine, doxorubicin, cyclophosphamide and prednisolone), with discontinuation of therapy planned at 6 months (UWM-25). This included the following chemotherapeutic agents; vincristine ( $0.7 \text{ mg/m}^2$  IV; Pfizer Injectables/Hospira Australia), cyclophosphamide (200



**Figure 5** Photograph demonstrating progression of the primary lesion. The cat was euthanased on the day this photograph was taken

$\text{mg/m}^2$  PO; Baxter Healthcare), doxorubicin (1 mg/kg IV; Accord Healthcare) and prednisolone (2 mg/kg PO q24h [tapering course]; Mavlab). Oral transmucosal buprenorphine hydrochloride (0.03 mg/kg) was used intermittently for analgesia. Four weeks following commencement of chemotherapy, progressive disease was noted within the cutaneous lesion (Figure 5) and right axillary lymph node. Palliative surgery (amputation) and rescue chemotherapy were discussed. The owner elected to euthanase the cat 1 week later, 42 days post-diagnosis, and a necropsy was declined.

#### Discussion

To our knowledge, this is the first report of a possible association between the development of CNEL and a previous fracture site in a cat.

Feline primary cutaneous lymphoma is a rare malignancy seen predominately in older cats, representing 0.2–3% of all feline lymphomas.<sup>1</sup> This malignancy can present as epitheliotropic T-cell lymphoma, with preference for invasion of the epidermis and adnexal epithelium.<sup>2</sup> It can also present as the non-epitheliotropic form, which invades the dermis and subcutis.<sup>1,3</sup> The underlying aetiology of cutaneous lymphoma is not well understood; however, chronic inflammation is thought to be a risk factor for its development.

Historically, it was thought that CNEL was not associated with presence of feline leukaemia virus (FeLV); however, recent studies have questioned this assumption.<sup>3</sup> A study by Weiss et al found that 80% of feline primary cutaneous lymphoma cases studied detected either FeLV antigen or the provirus.<sup>4</sup> Another report described a case of CNEL that tested negative for FeLV using serum ELISA; however, PCR detected a fragment of proviral FeLV.<sup>5</sup> Furthermore, a recent study examining the development of CNEL associated with previous injection sites

demonstrated the presence of FeLV proteins gp70 and p23, in 10/17 cases examined.<sup>1</sup> Therefore, FeLV may play a role in the aetiology of cutaneous lymphoma, and these recent cases may represent an improvement in the techniques available for virus detection.<sup>4</sup> Some authors have questioned the significance of the presence of proviral DNA in the absence of FeLV antigens.<sup>6,7</sup> There are doubts over the significance of latent FeLV infection in the aetiology of lymphoma development.<sup>6-8</sup> More research with larger populations is required to further elucidate this relationship.

There are numerous reports of the development of neoplasms at sites of foreign material in dogs, cats and humans. It has been clearly demonstrated that sarcomas can develop at sites of injections or retained surgical material in cats.<sup>9-11</sup> Interestingly, there have also been several published cases of fracture-associated sarcomas arising in dogs and humans.<sup>12,13</sup> A recent retrospective study found 16 cases of dogs that had developed sarcomas associated with metallic implants. Osteosarcoma was by far the most common tumour seen, followed by single cases of histiocytic sarcoma, fibrosarcoma and spindle-cell sarcoma.<sup>13</sup>

Feline cases of implant-associated malignancy have rarely been reported in the literature. One case report described osteosarcoma in a cat that developed at the site of a metal implant used to repair a fracture in the proximal femur 15 months earlier.<sup>14</sup>

Cutaneous lymphoma is reported to have arisen at regions of injection-site sarcomas in cats, following chemotherapy or radiation treatment of the primary tumour. It is hypothesised that this may be due to the mutagenic effects of these treatments.<sup>15</sup> One study described 17 cases of feline primary cutaneous lymphoma that developed at injection sites, without any association with sarcomas. Eleven cases were considered large B-cell lymphoma, three cases were anaplastic large T-cell lymphoma, one case was classified as natural killer cell-like lymphoma and one case was considered peripheral T-cell lymphoma.<sup>16</sup> Time to tumour development post-injection ranged from 15 days to approximately 9 years. Cutaneous lymphomas at injection sites in this study shared some clinical and pathological features with feline injection-site sarcomas and with lymphomas developing in the setting of subacute-to-chronic inflammation reported in human beings, with all cases lacking epitheliotropism. The authors proposed a possible mechanism involving chronic inflammation from an immunogenic stimulus, and reactivation of FeLV expression, enabling viral transformation of lymphocytes in certain cases.<sup>1</sup>

To date, there have been no reports of cutaneous lymphoma at a previous fracture site in either canine or feline patients. There have been several cases of non-Hodgkin B-cell lymphoma occurring at the site of a metallic implant in humans.<sup>17,18</sup> Recently, there was also a report of an anaplastic large-cell T-cell lymphoma

occurring in a human patient, associated with a metal implant.<sup>18</sup> A study in rats with orthopaedic implants showed a direct association between the development of sarcoma or lymphoma and the presence of this implant. The study also found intramedullary implants were associated with an increased incidence of neoplasia, indicating that location of the surgical device plays a key role in oncogenic transformation.<sup>19</sup> The authors of this report, and others, have hypothesised that metal implants may play a key role in tumour pathogenesis, and may influence metabolic, immunogenic and oncogenic processes via chronic antigenic stimulation and inflammation.<sup>12,19-21</sup> Others hypothesise that trauma itself can play a role in malignant transformation. In some cases, sarcomas develop at the site of the previous fracture, rather than at the location of surgical implants.<sup>22</sup>

It is likely, however, that multiple factors influence malignant transformation, including chronic inflammation, aberrant healing processes, genetic and epigenetic factors, and possibly a carcinogenic role of metal implants.

Protocols for treatment of cutaneous lymphoma in cats have not been standardised or widely reported. For local lesions, surgery or radiation can be considered following staging to rule out distant disease.<sup>23</sup> Furthermore, there has been a report of a complete remission to lomustine in a cat with non-epitheliotropic lymphoma; therefore, this treatment could be considered in cases of disseminated disease.<sup>24</sup> One study examined 23 cases of feline cutaneous lymphoma treated at a number of veterinary hospitals. Nine patients were treated with a CHOP-based protocol, either with or without L-asparaginase or lomustine. Response rates were variable, with some cats maintaining stable disease, and one cat achieving a complete remission. Radiotherapy was also trialled in combination with chemotherapy. The study maintained that other treatment protocols should be investigated; however, a multi modal approach would likely achieve the best control of the disease.<sup>23</sup>

This case had several limitations in relation to the diagnostic work-up, absence of full staging once the diagnosis was confirmed, lack of FeLV testing and the inability to perform a necropsy. Many of these were related to financial restrictions, as is encountered in non-funded, retrospective cases. During the diagnostic work-up, antibiotics were administered multiple times before further diagnostics were performed, despite no evidence of overt infection (degenerate neutrophils only on cytology) and a lack of response to previous antibiotic therapy. There was also no attempt to confirm an infection using culture and sensitivity of the affected area. Finally, there was a significant delay in obtaining a histopathological diagnosis, as owing to cost constraints the sample was not submitted for 2 months after collection. It is not possible to determine if an earlier diagnosis may have affected outcome in this case. However, in retrospect, any lesions that occur

particularly if associated with a site of previous trauma or surgery – should be carefully assessed, and, in the absence of overt infection or a conclusive cytological diagnosis, should be biopsied. It is unusual that cytology from the local site on two occasions did not reveal an increased population of lymphocytes, as noted on the biopsy, as lymphocytes generally exfoliate well and lymphoma is often diagnosed with cytology. It is possible the cytological samples were too superficial and not representative of the deeper, underlying disease process centred around the fracture site and implant. It is also possible the lymphoma developed after the cytological samples were collected, particularly the first sample, as this preceded the incisional biopsy by 12 months. This would seem less likely for the second cytological sample, which was collected only 7 weeks prior to biopsy.

The cytological findings from regional lymph node aspirates were consistent with at least stage II disease, with confirmed involvement of two peripheral nodes. It is possible this case presented as true stage II disease without further systemic involvement; however, it is not possible to differentiate loco-regional disease from systemic disease without full staging. There are numerous possible explanations for the presence of rare atypical lymphocytes in circulation. First, the atypical lymphocytes may have represented a spillover effect from the enlarged lymph nodes or cutaneous site, particularly as the lymphocyte count remained within normal range. Alternatively, it may have represented stage V involvement. It also remains possible these were atypical reactive lymphocytes. Finally, the presence of these cells may have occurred as a result of spillover from another location, such as the spleen. As splenic aspirates were not performed, this could not be ruled out.

Further staging, including bone marrow aspiration, thoracic and abdominal imaging and feline immunodeficiency virus/FelV testing was recommended and was declined by the owner. These staging tests would have clarified the extent of disease and directed treatment options. If no distant disease beyond the dermal site and loco-regional lymph nodes was noted, amputation could have been considered, in combination with systemic chemotherapy. This may have improved outcome, although further studies are required to clarify the role of local treatments in this disease. If distant disease was noted on staging tests, then proceeding directly to chemotherapy would have been indicated. Without staging, and necropsy, it was assumed the lesion over the right forelimb was the primary site, with involvement of the loco-regional lymph nodes. It remains possible that the lymphoma developed in another organ (centralised phenomenon) and developed a tropism for the cutaneous site mediated by the inflammatory process. In future, staging and/or necropsy would be useful to assess the extent of involvement, further evaluating local and

systemic disease presence. This may have clarified whether chronic inflammation associated with the fracture, or metal implant had an aetiological role in the development of the cancer, or rather supplied an ideal environment for the cancer to traffic to and thrive at.

## Conclusions

To our knowledge, this is the first report of CNEL developing at the site of a previous fracture and metal implant in a cat. Owing to the low incidence of reported cases, more investigation is required to understand the association between the development of lymphoma and other malignancies, at sites of previous trauma, and in the presence of surgical implants. To improve outcome, prompt sampling of lesions associated with previous fracture or surgical sites should be performed in cases where overt infection is not detected.

**Acknowledgements** We would like to thank Dr Emma Fields for her help collecting primary information and images.

**Conflict of interest** The authors declared no potential conflicts of interest with respect to the research, authorship, and/or publication of this article.

**Funding** The authors received no financial support for the research, authorship, and/or publication of this article.

## References

- 1 Roccabianca P, Avallone G, Rodriguez A, et al. **Cutaneous lymphoma at injection sites: pathological, immunophenotypic, and molecular characterization in 17 cats.** *Vet Pathol* 2016; 53: 823–832.
- 2 Fontaine J, Heimann M and Day MJ. **Cutaneous epitheliotropic T-cell lymphoma in the cat: a review of the literature and five new cases.** *Vet Dermatol* 2011; 22: 454–461.
- 3 Moore PF and Olivry T. **Cutaneous lymphomas in companion animals.** *Clin Dermatol* 1994; 12: 499–505.
- 4 Weiss ATA, Klopfleisch R and Gruber AD. **Prevalence of feline leukaemia provirus DNA in feline lymphomas.** *J Feline Med Surg* 2010; 12: 929–935.
- 5 Favrot C, Wilhelm S, Grest P, et al. **Two cases of FelV-associated dermatoses.** *Vet Dermatol* 2005; 16: 407–412.
- 6 Herring E, Troy G, Toth T, et al. **Detection of feline leukaemia virus in blood and bone marrow of cats with varying suspicion of latent infection.** *J Feline Med Surg* 2001; 3: 133–141.
- 7 Stützer B, Simon K, Lutz H, et al. **Incidence of persistent viraemia and latent feline leukaemia virus infection in cats with lymphoma.** *J Feline Med Surg* 2011; 13: 81–87.
- 8 Sultz M, Failing K, Hecht W, et al. **High prevalence of non-productive FelV infection in necropsied cats and significant association with pathological findings.** *Vet Immunol Immunopathol* 2010; 136: 71–80.
- 9 Kass PH, Spangler WL, Hendrick MJ, et al. **Multicenter case-control study of risk factors associated with development**

- of vaccine-associated sarcomas in cats. *J Am Vet Med Assoc* 2003; 223: 1283–1292.
- 10 Haddad JL, Goldschmidt MH and Patel RT. **Fibrosarcoma arising at the site of a retained surgical sponge in a cat.** *Vet Clin Pathol* 2010; 39: 241–246.
- 11 Daly MK, Saba CF, Crochik SS, et al. **Fibrosarcoma adjacent to the site of microchip implantation in a cat.** *J Feline Med Surg* 2008; 10: 202–205.
- 12 Stevenson S. **Fracture-associated sarcomas.** *Vet Clin North Am Small Anim Pract* 1991; 21: 859–872.
- 13 Burton AG, Johnson EG, Vernau W, et al. **Implant-associated neoplasia in dogs: 16 cases (1983–2013).** *J Am Vet Med Assoc* 2015; 247: 778–785.
- 14 Fry P and Jukes H. **Fracture associated sarcoma in the cat.** *J Small Anim Pract* 1995; 36: 124–126.
- 15 Madewell BR, Gieger TL, Pesavento PA, et al. **Vaccine site-associated sarcoma and malignant lymphoma in cats: a report of six cases (1997–2002).** *J Am Anim Hosp Assoc* 2004; 40: 47–50.
- 16 Norris D and Stone J. WHO classification of tumours of haematopoietic and lymphoid tissues. Geneva: WHO, 2008.
- 17 Cheuk W, Chan AC, Chan JK, et al. **Metallic implant-associated lymphoma: a distinct subgroup of large B-cell lymphoma related to pyothorax-associated lymphoma?** *Am J Surg Pathol* 2005; 29: 832–836.
- 18 Palraj B, Paturi A, Stone RG, et al. **Soft tissue anaplastic large T-cell lymphoma associated with a metallic orthopedic implant: case report and review of the current literature.** *J Foot Ankle Surg* 2010; 49: 561–564.
- 19 Memoli VA, Urban RM, Alroy J, et al. **Malignant neoplasms associated with orthopedic implant materials in rats.** *J Orthop Res* 1986; 4: 346–355.
- 20 Sinibaldi K, Rosen H, Liu S-k, et al. **Tumors associated with metallic implants in animals.** *Clin Orthop Relat Res* 1976; 118: 257–266.
- 21 Woodward KN. **Origins of injection-site sarcomas in cats: the possible role of chronic inflammation – a review.** *ISRN Vet Sci* 2011; 2011: 210982.
- 22 Jackson LC and Pacchiana PD. **Common complications of fracture repair.** *Clin Tech Small Anim Pract* 2004; 19: 168–179.
- 23 Burr HD, Keating JH, Clifford CA, et al. **Cutaneous lymphoma of the tarsus in cats: 23 cases (2000–2012).** *J Am Vet Med Assoc* 2014; 244: 1429–1434.
- 24 Komori S, Nakamura S, Takahashi K, et al. **Use of lomustine to treat cutaneous nonepitheliotropic lymphoma in a cat.** *J Am Vet Med Assoc* 2005; 226: 237–239.