



Trismus, masticatory myositis and antibodies against type 2M fibers in a mixed breed cat

Authors: Blazejewski, Stanley W, and Shelton, G Diane

Source: Journal of Feline Medicine and Surgery Open Reports, 4(1)

Published By: SAGE Publishing

URL: <https://doi.org/10.1177/2055116918764993>

BioOne Complete (complete.BioOne.org) is a full-text database of 200 subscribed and open-access titles in the biological, ecological, and environmental sciences published by nonprofit societies, associations, museums, institutions, and presses.

Your use of this PDF, the BioOne Complete website, and all posted and associated content indicates your acceptance of BioOne's Terms of Use, available at www.bioone.org/terms-of-use.

Usage of BioOne Complete content is strictly limited to personal, educational, and non - commercial use. Commercial inquiries or rights and permissions requests should be directed to the individual publisher as copyright holder.

BioOne sees sustainable scholarly publishing as an inherently collaborative enterprise connecting authors, nonprofit publishers, academic institutions, research libraries, and research funders in the common goal of maximizing access to critical research.



Trismus, masticatory myositis and antibodies against type 2M fibers in a mixed breed cat

Stanley W Blazejewski¹ and G Diane Shelton²

Journal of Feline Medicine and Surgery Open Reports
1–4

© The Author(s) 2018

Reprints and permissions:

sagepub.co.uk/journalsPermissions.nav

DOI: 10.1177/2055116918764993

journals.sagepub.com/home/jfmsopenreports

This paper was handled and processed by the American Editorial Office (AAFP) for publication in *JFMS Open Reports*



Abstract

Case summary A 1-year-old male neutered mixed breed cat presented with a 2 month history of inability to fully open the mouth when yawning and decreased ability to prehend food. Physical examination revealed severe bilaterally symmetrical masticatory muscle atrophy, a restricted vertical mandibular range of motion of 11–12 mm, and a normal body condition score. Skull radiography was normal. A canine ELISA system against unique masticatory muscle fibers (2M antibody titer), was positive at 1:1000 (reference interval <1:100 in dogs, and was <1:100 using serum from five archived normal cats), indicating the presence of cross-reacting antibodies. Owing to the chronicity and clinical severity, corticosteroid treatment did not result in improved jaw mobility, consistent with end-stage masticatory myositis. Masticatory muscle biopsy was declined at initial presentation. However, 1 year later at elective euthanasia, CT ruled out temporomandibular joint osseous restrictions, and masticatory and biceps femoral muscle histopathology evaluation confirmed end stage feline masticatory myositis with normal limb muscle.

Relevance and novel information Masticatory myositis should be included in the differential diagnosis of trismus in cats. A canine ELISA can be used to indicate the presence of feline 2M cross-reacting antibodies. More cases are needed to fully elucidate the clinical presentation and best course of treatment.

Accepted: 17 February 2018

Introduction

Masticatory myositis is a well documented disease in the dog,¹ but has been considered rare or to not occur in cats. Similar to canine masticatory muscles,^{2,3} feline masticatory muscles contain type 2M fibers,⁴ which are not present in limb muscles. The masticatory muscles are innervated by the mandibular branch of the trigeminal nerve and include the temporalis, masseter and pterygoid muscles.⁵ The autoimmune nature of canine masticatory myositis (MM) was documented in 1985 and in 1987 with the identification of fiber-type-specific autoantibodies against type 2M fibers.^{6,7}

In canine MM, an acute phase may be manifested as jaw pain, swelling of the masticatory muscles and restricted jaw mobility, or the inability to open the jaw even under anesthesia. The acute phase may progress to a chronic phase with atrophy of the masticatory muscles, fibrosis and restricted jaw mobility. A chronic form of MM may also occur with slowly progressive atrophy of the masticatory muscles without an obvious acute phase.

To our knowledge, the clinical signs of MM in cats have not been described in the veterinary literature. This may result in clinicians not being aware of the occurrence of MM in cats and a possible misdiagnosis. Additionally, the independent and reclusive nature of cats, and the tendency for many cats not to engage in oral play behavior or pick up toys or balls, may contribute to a delayed diagnosis or misdiagnosis of feline MM. Here we present the first case of feline MM in the veterinary literature documented by histopathology and a positive serum antibody titer against masticatory muscle type 2M fibers.

¹VRC, Malvern, PA, USA

²Comparative Neuromuscular Laboratory, School of Medicine, University of California San Diego, La Jolla, CA, USA

Corresponding author:

Stanley W Blazejewski VMD, DAVDC (Oral Surgery and Dentistry), 3rd VRC, 340 Lancaster Ave, Malvern, PA 19355, USA
sblazejewski@vrcmalvern.com



Creative Commons Non Commercial CC BY-NC: This article is distributed under the terms of the Creative Commons

Attribution-NonCommercial 4.0 License (<http://www.creativecommons.org/licenses/by-nc/4.0/>) which permits non-commercial use, reproduction and distribution of the work without further permission provided the original work is attributed as specified on the SAGE and Open Access pages (<https://us.sagepub.com/en-us/nam/open-access-at-sage>).

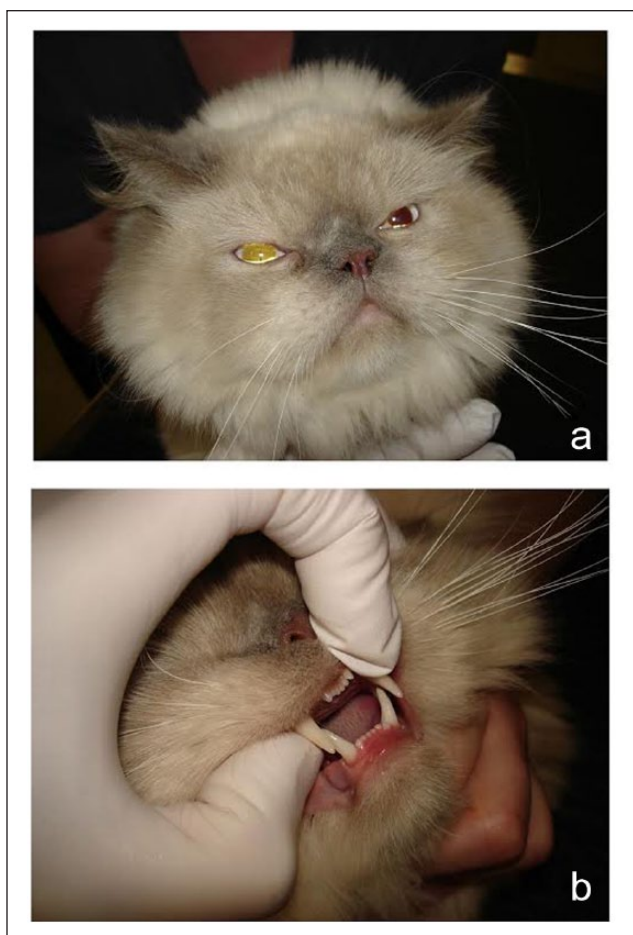


Figure 1 (a) Images of a 1-year-old mixed breed cat at the time of initial evaluation showing the long thick hair on the head and inability of the observer to appreciate the severe masticatory muscle atrophy. (b) Maximum vertical mandibular range of motion was measured as 12 mm

Case description

A 1-year-old male neutered mixed breed cat (4.6 kg) was presented for difficulty prehending hard food. The cat was housed strictly indoors. About 2 months prior to presentation, the owner noticed the cat was not fully opening its mouth when yawning but had been able to eat slowly, managing soft food and pieces of hard food. No other behavioral or clinical signs of disease were reported. On physical examination the cat was very bright, alert, appropriate and clinically well hydrated with a body condition score of 6/9. Owing to the long haircoat palpation was necessary to appreciate the severe bilaterally symmetrical atrophy of the masticatory musculature (Figure 1a). Ocular retropulsion and palpation of the mandibular lymph nodes were normal.

An intraoral examination was impossible owing to the decreased vertical mandibular range of motion

(vmROM) of 11–12 mm as measured with a metric ruler between the upper and lower incisor tips (Figure 1b). Visible teeth were age appropriate and normal in appearance. Occlusion was symmetrical. Limited vmROM was smooth and without discernible crepitus, but had a firm endpoint at 12 mm. The remainder of the physical and neurological examinations was unremarkable. Owing to financial constraints and anesthetic risks associated with the restricted vmROM, CT to rule out osseous abnormalities and biopsy of a masticatory muscle were declined. Blood tests and skull radiography were approved.

Complete blood count (CBC) values were unremarkable. Serum biochemistry values, including creatine kinase activity, were within normal limits, except for an elevation of alanine transferase (214 U/l; reference interval [RI] 10–100 U/l) and aspartate aminotransferase (176 U/l; RI 10–100 U/l) activities. Dorsoventral skull radiography showed no bony abnormalities associated with the temporomandibular joints or elsewhere in the skull. Since a feline-specific assay has not yet been established for the detection of antibodies against masticatory muscle type 2M fiber proteins, an established canine ELISA system was used to detect cross-reacting antibodies against canine type 2M fiber antigens.⁵ The serum 2M antibody titer was positive at a dilution of 1:1000 (RI <1:100 in dogs, and also <1:100 using serum from five archived normal cats). Circulating antibodies against type 2M fibers are diagnostic of MM in dogs.⁵

Methylprednisolone (Depo-Medrol; Zoetis) was administered intramuscularly (24 mg; 5.2 mg/kg). Forced jaw opening to improve vmROM was not performed owing to the risk of iatrogenic osseous fracture or soft tissue damage. Two weeks after the initial treatment, further examination revealed no change in the extent or character of vmROM. Appetite and activity remained good. Repeat CBC and serum biochemistry values were unremarkable. Oral prednisolone (Lloyd [5 mg; 1 mg/kg q12h]) was prescribed. One month later, in a follow-up telephone conversation with the owner, it was determined the oral prednisolone prescription had not been filled. The oral prednisolone prescription was subsequently filled and administered crushed in soft food. The cat was again evaluated almost 2 months after the initial presentation. Body weight was slightly increased (4.7 kg). The vmROM, as determined with a millimeter ruler in the relaxed conscious cat, remained restricted at 11–12 mm. Severe bilaterally symmetrical masticatory muscle atrophy persisted, suggesting end-stage disease and a poor prognosis. Biopsy from a masticatory muscle would be required to determine the degree of fibrosis, population of remaining type 2M fibers, and subsequent prognosis, but this was declined.

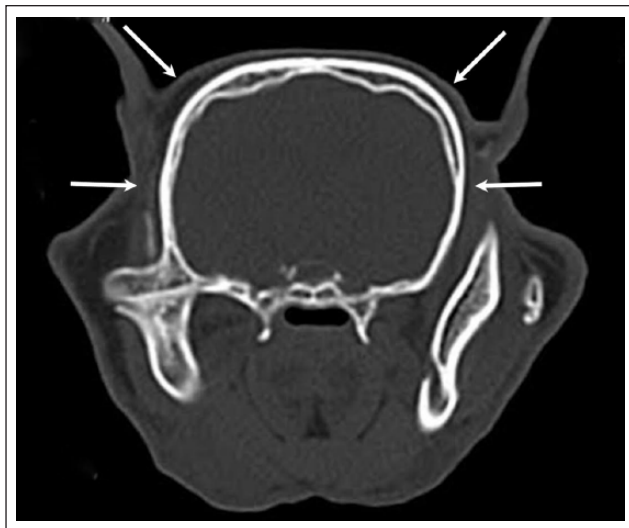


Figure 2 Post-mortem axial CT demonstrating severe bilateral atrophy of the temporalis muscles (white arrows)

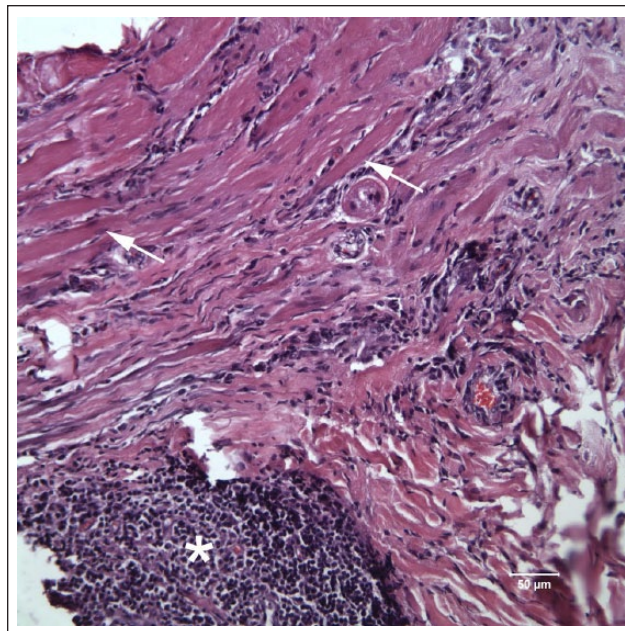


Figure 3 Histopathologic features, hematoxylin and eosin staining on the temporalis muscle of the cat in Figures 1 and 2 showing marked myofiber loss and fibrosis. Remaining myofibers are atrophic (arrows). A large cluster of mononuclear cells are present in the lower left corner (asterisk). Bar = 50 μ m

The cat was lost to follow-up until 1 year after initial presentation. At this time the cat was presented to the emergency service with a recent history of vomiting, anorexia and nasal discharge. Corticosteroid therapy had been discontinued 10 months previously. The cat was alert with appropriate behavior. Body condition score was 5/9 (4.3 kg). Body temperature was 40.3°C (104.6°F) and a bilateral purulent nasal discharge was evident. vmROM remained restricted at 11–12 mm. Thoracic radiography was unremarkable. A SNAP FeLV/FIV ELISA assay (IDEXX) was negative. After 18 h of supportive treatment, body temperature remained elevated at 40.7°C (105.3°F), and severe nasal discharge and anorexia persisted. The owners elected euthanasia on welfare grounds and approved post-mortem examination to further investigate MM.

Head CT was performed post mortem using contiguous 2.0 slice thickness with 0.1 incremental helical slides using an ultra sharp bone algorithm (Somatom, 16 slice; Siemens). It revealed pronounced bilaterally symmetrical atrophy of the masticatory muscles with no radiographic abnormalities of the temporomandibular joints or other bony structures that would restrict mouth opening (Figure 2).

Specimens were collected from the right and left temporalis and masseter muscles, and the biceps femoris muscle, fixed in 10% neutral buffered formalin, then evaluated at the Comparative Neuromuscular Laboratory (CNL), University of California San Diego. All of the temporalis and masseter muscles exhibited similar pathological changes (Figure 3). Myofiber loss and fibrosis was marked with multifocal areas of lymphocytic infiltration having an endomysial and perimysial distribution. Large nodules of lymphocytic infiltration were focally present.

The biopsy from the biceps femoris muscle was normal in appearance, without obvious cellular infiltration or fibrosis, supporting the focal nature of this inflammatory myopathy and making a generalized disorder such as polymyositis unlikely. The pathologic diagnosis was severe and end-stage inflammatory myopathy myositis with extensive fibrosis in all masticatory muscles evaluated. As in dogs, inflammation restricted to the masticatory muscles and the positive serum 2M antibody titer confirmed the diagnosis of MM in this cat.

Discussion

Here we report the first case of MM in a cat with a clinical presentation, histopathology findings and a positive serum 2M antibody titer consistent with the disease as described in dogs. A search of the CNL database documented positive serum 2M antibody titers using the canine ELISA assay in nine cats since 2001. Based on these findings, the incidence of feline MM may be low compared with dogs. In dogs with MM, early recognition, diagnosis and appropriate treatment are critical to a good therapeutic outcome.^{5,8}

Prednisolone therapy did not result in improvement of jaw mobility, and there was no clinically discernible change in the vmROM or the severity of masticatory muscle atrophy over the 1 year course of this case. Severe masticatory muscle atrophy, chronic restricted jaw

opening and lack of response to treatment in a dog would be consistent with end stage MM.⁵ The prognosis for improvement in vmROM with corticosteroids is dependent on the amount of fibrosis and myofiber loss at the time treatment is initiated. An early and accurate diagnosis and appropriate therapy are essential. Relapses are common in canine MM, but the natural course of the disease in cats is not known. Unfortunately, a muscle biopsy was not available at the initial presentation, and corticosteroid therapy was not aggressively administered.

The serum 2M antibody titer is a non-invasive test to confirm a diagnosis of MM, although it may be negative in end-stage disease if all the type 2M fibers are destroyed.^{5,8} This test does not provide information about severity or prognosis. While the assay uses canine antigen, feline antibodies cross-react with the canine masticatory muscle 2M proteins. CT or MRI have been used to document distribution and severity of lesions, and areas of hyperintensity.^{9,10}

It is not clear how long clinical signs were present in this cat owing to the long haircoat over the head and lack of indicators of jaw pain or restricted jaw mobility visible to the owner. Over the 1 year span from initial presentation to euthanasia, body weight was maintained, demonstrating that the cat could eat with only an 11–12 mm mouth opening. Feline jaw fractures are frequently stabilized with interarch splinting of opposing canine teeth with dental composite. These cats have no difficulty licking up soft food and water between the 10 mm incisor opening that is provided during the 6 week healing following maxillary-mandibular fixation.¹¹

Feline MM may be underrecognized. Cats receive only about half the number of veterinary visits as dogs.¹² Owners may miss early or vague clinical signs, as cats tend to conceal oral dysfunction and pain. Thorough oral examination in the conscious cat or dog can be challenging, especially with liability concerns for animal bites. Owners are often reluctant to approve anesthesia or even sedation that may aid in the early detection of oral disorders.

Conclusions

Autoimmune masticatory myositis does occur in cats with clinical signs of restricted jaw mobility and masticatory muscle atrophy. The canine 2M antibody test by ELISA can be used to confirm the diagnosis along with biopsies from a masticatory muscle. As in dogs, early recognition of clinical signs and appropriate treatment may be necessary for a good clinical outcome. Further

studies with information regarding treatment and long-term outcome in cats are clearly needed.

Acknowledgements The authors thank Darwin Pagaduan and Rachel Chan for excellent technical assistance and Laura Ateca VMD and Eva Larouche-Lebel DVM for their referral.

Conflict of interest The authors declared no potential conflicts of interest with respect to the research, authorship, and/or publication of this article.

Funding The authors received no financial support for the research, authorship, and/or publication of this article.

References

- Evans J, Levesque D and Shelton GD. **Canine inflammatory myopathies: a clinicopathologic review of 200 cases.** *J Vet Intern Med* 2004; 5: 679–691.
- Orvis JS and Cardinet GH, III. **Canine muscle fiber types and susceptibility of masticatory muscles to myositis.** *Muscle Nerve* 1981; 4: 354–359.
- Shelton GD, Bandman E and Cardinet GH, III. **Electrophoretic comparison of myosins from masticatory muscles and selected limb muscles in the dog.** *Am J Vet Res* 1985; 2: 493–498.
- Rowlerson A, Pope B, Murray J, et al. **A novel myosin present in cat jaw closing muscles.** *J Muscle Res Cell Motil* 1981; 2: 415–438.
- Melmed C, Shelton GD, Bergman R, et al. **Masticatory muscle myositis: pathogenesis, diagnosis, and treatment.** *Compendium* 2004; 8: 590–605.
- Shelton GD, Cardinet GH, III and Bandman E. **Fiber type-specific autoantibodies in a dog with eosinophilic myositis.** *Muscle Nerve* 1985; 9: 783–790.
- Shelton GD, Cardinet GH, III and Bandman E. **Canine masticatory muscle disorders: a study of 29 cases.** *Muscle Nerve* 1987; 8: 753–765.
- Shelton GD. **Treatment of myopathies and neuropathies.** In: Bonagura JD and Twedt DC (eds). *Kirk's current veterinary therapy XV*. Philadelphia, PA: Elsevier Saunders, 2008, pp 1113–1118.
- Reiter AM and Schwarz T. **Computed tomographic appearance of masticatory myositis in dogs: 7 cases (1999–2006).** *J Am Vet Med Assoc* 2007; 6: 924–930.
- Cauduro A, Paolo F, Asperio RM, et al. **Use of MRI for the early diagnosis of masticatory muscle myositis.** *J Am Anim Hosp Assoc* 2013; 5: 347–352.
- Bennett JW, Kapatkin AS and Marretta SM. **Dental composite for the fixation of mandibular fractures and luxations in 11 cats and 6 dogs.** *Vet Surg* 1994; 3: 190–194.
- Burns K, JAVMA news. **6 factors in declining veterinary visits.** <https://www.avma.org/News/JAVMANews/Pages/x110301a.aspx> (2011, accessed April 19, 2018).