



Acquired urea cycle amino acid deficiency and hyperammonaemic encephalopathy in a cat with inflammatory bowel disease and chronic kidney disease

Authors: Dor, Cécile, Adamany, Jessica L, Kisielewicz, Caroline, de Brot, Simone, Erles, Kerstin, et al.

Source: Journal of Feline Medicine and Surgery Open Reports, 4(2)

Published By: SAGE Publishing

URL: <https://doi.org/10.1177/2055116918786750>

BioOne Complete (complete.BioOne.org) is a full-text database of 200 subscribed and open-access titles in the biological, ecological, and environmental sciences published by nonprofit societies, associations, museums, institutions, and presses.

Your use of this PDF, the BioOne Complete website, and all posted and associated content indicates your acceptance of BioOne's Terms of Use, available at www.bioone.org/terms-of-use.

Usage of BioOne Complete content is strictly limited to personal, educational, and non - commercial use. Commercial inquiries or rights and permissions requests should be directed to the individual publisher as copyright holder.

BioOne sees sustainable scholarly publishing as an inherently collaborative enterprise connecting authors, nonprofit publishers, academic institutions, research libraries, and research funders in the common goal of maximizing access to critical research.



Acquired urea cycle amino acid deficiency and hyperammonaemic encephalopathy in a cat with inflammatory bowel disease and chronic kidney disease

Journal of Feline Medicine and Surgery Open Reports
1–5

© The Author(s) 2018

Reprints and permissions:


sagepub.co.uk/journalsPermissions.nav

DOI: 10.1177/2055116918786750

journals.sagepub.com/home/jfmsopenreports

This paper was handled and processed by the European Editorial Office (ISFM) for publication in *JFMS Open Reports*



Cécile Dor^{1,2*} , Jessica L Adamany²,
Caroline Kisielewicz², Simone de Brot³,
Kerstin Erles⁴ and Marc P Dhumeaux²

Abstract

Case summary A 5-year-old male neutered Persian cat was referred for investigation of a 4 week history of weight loss, inappetence and intermittent vomiting. Chronic kidney disease (CKD) and inflammatory bowel disease were diagnosed, and despite immunosuppressive therapy and assisted enteral nutrition, the cat experienced persistent anorexia, vomiting and severe weight loss. After 2 additional weeks of treatment, the cat developed acute-onset neurological signs associated with severe hyperammonaemia and was euthanased. Plasma amino acid assessment revealed deficiency of several amino acids involved in the urea cycle, including arginine.

Relevance and novel information To our knowledge, this is the first reported case of an acquired urea cycle amino acid deficiency without nutritional deprivation in a cat. Several contributing factors were suspected, including intestinal malabsorption and CKD. This case demonstrates the importance of urea cycle amino acids in feline metabolism and possible necessity for parenteral supplementation, particularly in the context of persistent weight loss despite adequate enteral nutrition.

Keywords: Arginine, amino acids, hyperammonaemic encephalopathy, hyperammonaemia, inflammatory bowel disease, chronic kidney disease

Accepted: 1 June 2018

Introduction

Arginine is an essential amino acid in dogs and cats; it plays a crucial role in the urea cycle (Figure 1), where ammonia is converted into urea. Cats are able to produce arginine in enterocytes and proximal renal tubular cells but in limited amounts.^{1–4} Dietary intake remains the main source of arginine for cats.^{5–11} In addition, cats have higher requirements for arginine than other species because their urea cycle is not downregulated during periods of fasting or after consuming low-protein diets.¹¹

As a result of the limited endogenous synthesis of arginine and its precursors (ornithine, citrulline), as well as their higher metabolic arginine demand, the exogenous

¹Department of Internal Medicine, School of Veterinary Medicine and Science, University of Nottingham, Nottingham, UK

²Department of Internal Medicine, Pride Veterinary Centre, Derby, UK

³School of Veterinary Medicine and Science, University of Nottingham, Nottingham, UK

⁴Bridge Pathology, Bristol, UK

*Current address: Department of Internal Medicine, Pride Veterinary Centre, Riverside Road, Derbyshire DE24 8HX, UK

Corresponding author:

Cécile Dor DVM, MRCVS, School of Veterinary Medicine and Science, University of Nottingham, Sutton Bonington Campus, School Road, Leicestershire LE12 5RD, UK
Email: cecile.dor@scarsdalevets.com



Creative Commons Non Commercial CC BY-NC: This article is distributed under the terms of the Creative Commons

Attribution-NonCommercial 4.0 License (<http://www.creativecommons.org/licenses/by-nc/4.0/>) which permits non-commercial use, reproduction and distribution of the work without further permission provided the original work is attributed as specified on the SAGE and Open Access pages (<https://us.sagepub.com/en-us/nam/open-access-at-sage>).

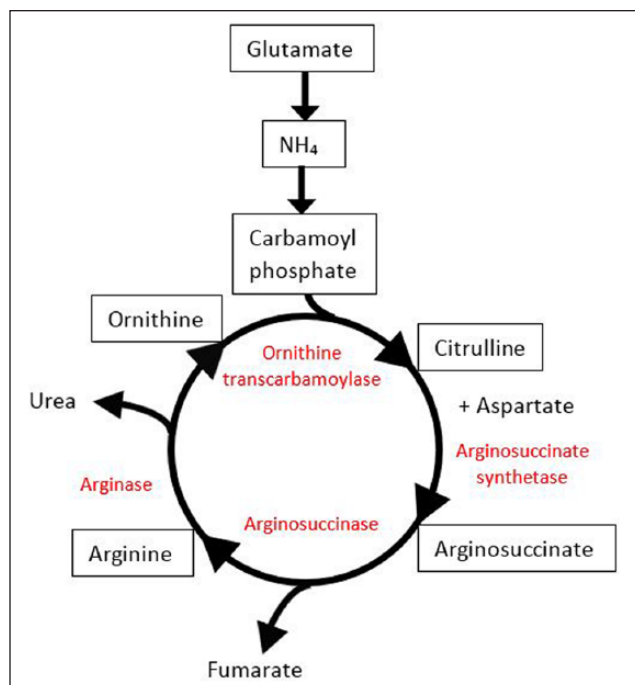


Figure 1 The urea cycle

arginine supply must be sufficient in order to prevent hypoargininaemia and therefore hyperammonaemia.

Other causes of hypoargininaemia and hyperammonaemia unrelated to the diet or urea cycle enzyme deficiencies have been poorly described in the human and veterinary literature. Contributing factors such as decreased intestinal absorption due to inflammatory bowel disease (IBD) or decreased renal synthesis owing to chronic kidney disease (CKD) have been suggested.^{12–15}

Case description

A 5-year-old male neutered Persian cat was referred for investigation of a 4 week history of weight loss, inappetence and vomiting, following management of feline lower urinary tract disease, with repeated urethral catheterisations and assisted nutrition by an oesophagostomy tube. The nutritional support provided at that time was estimated at approximately 40% of its basal energy requirement (BER).

On examination, its body condition score was estimated at 4/9 and the body weight was 2.95 kg. A subcutaneous abscess was noticed at the level of the oesophagostomy tube insertion site. Mild pyrexia (39.6°C) and a left systolic parasternal heart murmur grade II/VI were also identified. The remainder of the physical examination was unremarkable.

A CT scan revealed a large left cervical abscess associated with the oesophagostomy tube, treated with surgical debridement followed by drainage and antibiotic therapy (amoxicillin-clavulanic acid). A naso-oesophageal tube was placed to allow continuation of assisted nutrition.

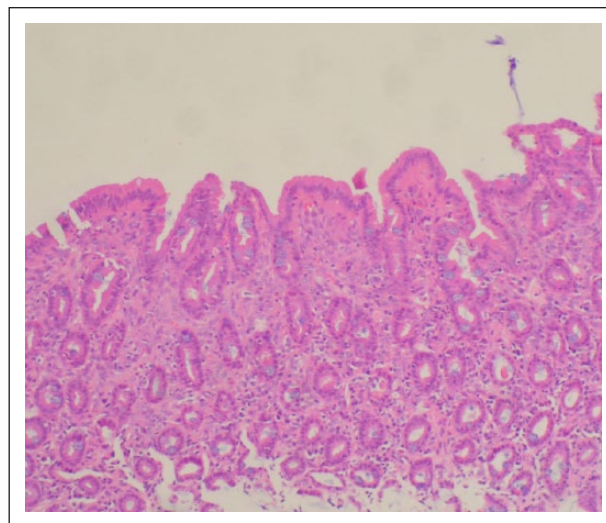


Figure 2 Marked enteritis with blunting of villi and a plasmacytic, neutrophilic and histiocytic infiltrate within the lamina propria. Haematoxylin and eosin stain ($\times 100$ magnification)

Despite having received 100% of its BER for 10 days followed by 150% BER for 4 days using an energy-dense complete commercial diet (Royal Canin Convalescence Support), the cat continued to lose weight and remained anorexic. Energy requirement was calculated with the standard formula: BER (kcal) = $30 \times \text{body weight} + 70$.

Haematology and biochemistry revealed mild non-regenerative anaemia (haematocrit 25%; reference interval [RI] 28–52%) and elevation of symmetric dimethylarginine (20 $\mu\text{g}/\text{dl}$; RI 0–14) with creatinine within the upper range of the reference interval (112 $\mu\text{mol}/\text{l}$; RI 0–140), suggestive of International Renal Interest Society stage 1 CKD. The fasting serum bile acids, folate and cobalamin and feline trypsin-like immunoreactivity were within normal limits. Urinalysis revealed a urine specific gravity of 1.041, inactive urine sediment, borderline proteinuria (urine protein to creatinine ratio 0.37; RI <0.2) and negative urine culture. Faecal parasitology and culture for *Salmonella* and *Campylobacter* species were negative. Ultrasonography showed bilateral renal changes consistent with CKD and prominence of the jejunal muscularis layer, compatible with chronic enteropathy or – less likely – intestinal lymphoma. Endoscopy revealed oedema of the gastric and duodenal mucosae. Histology revealed mild eosinophilic, lymphoplasmacytic gastritis and marked neutrophilic, plasmacytic, histiocytic enteritis, with villous blunting (Figure 2).

Oral maropitant at 4 mg daily (Cerenia 16 mg tablets; Zoetis) along with mirtazapine (Mirtazapine 2 mg tablets; reconditioned tablets) at 2 mg every other day were provided as appetite stimulants during the hospitalisation. Immunosuppressive therapy was started 6 days after admission, with dexamethasone initially (0.5 mg/kg IV

Table 1 Plasma amino acid profile of the patient

Plasma amino acids	Results ($\mu\text{mol/l}$)	RI
Phosphoserine	8	3–5
Taurine	337	53–200
Pethanolamine	1	0–40
Aspartate	32	6–20
Hydroxyproline	23	2–4
Threonine*	92	96–353
Serine	75	19–231
Asparagine*	21	35–74
Glutamate	74	26–56
Glutamine*	457	759–1312
Proline*	128	173–550
Glycine*	121	189–564
Alanine*	402	450–672
Citrulline*	3	40–83
Alpha-aminobutyric*	10	21–43
Valine*	138	172–287
Half-cystine	8	0–46
Methionine	73	54–109
Isoleucine	84	57–105
Leucine	129	125–197
Tyrosine	65	42–67
Phenylalanine*	56	58–69
Homocysteine	0	0–1
Ornithine*	10	23–40
Lysine	145	145–201
1-Methylhistidine	7	0–34
Histidine	168	78–131
3-Methylhistidine	6	0–23
Arginine*	52	140–220
Ethanolamine	0	0–153
Tryptophan	18	10–140
Beta-aminoisobutyric	0	0–2
Cystathionine	3	0–3
Sarcosine	0	0–2
Anserine	0	0–2
Hydroxylysine	0	0–2
Alpha-amino adipic	0	0–6
Carnosine	20	0–2
Beta-alanine	1	0–12
Gamma-aminobutyric	0	0–1
Alloisoleucine	0	0–1
Argininosuccinic	0	0–1
Homocitrulline	0	0–1

*Deficient amino acid
RI = reference interval

q24h for 7 days [Rapidexon 2 mg/ml injectable solution; Eurovet], followed by prednisolone (1.8 mg/kg PO q24h [Prednicare 5 mg tablets; Animalcare]). Owing to a lack of improvement, another immunosuppressive drug was added 4 days after initiation of steroids: ciclosporin (Cyclavance 100 mg/ml oral solution; Virbac) at 5 mg/kg q12h on an empty stomach.

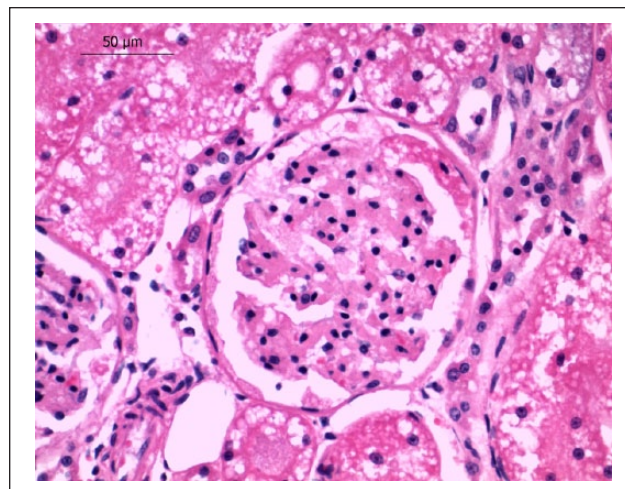


Figure 3 Microphotograph of the kidney. Note the global thickening of the glomerular membrane, suspicious of membranous glomerulonephritis. Haematoxylin and eosin stain ($\times 400$ magnification)

Seventeen days after admission, the cat became acutely subdued. This progressed rapidly to loss of consciousness, opisthotonos and bilateral light-responsive mydriasis, consistent with an intracranial neurolocalisation. The plasma ammonia was markedly elevated ($>286 \mu\text{mol/l}$) and likely responsible for the neurological signs. At that stage, the cat's owners elected euthanasia, and consented to blood collections for plasma amino acids, serum organic acids measurement and post-mortem examination. This revealed low plasma concentrations of the urea cycle amino acids arginine, citrulline and ornithine, which was suggestive of acquired urea cycle amino acid deficiencies resulting in hyperammonaemic encephalopathy (Table 1). Measurement of serum organic acids did not provide additional relevant information.

On necropsy, the following organs and tissues were examined histologically: heart, lung, liver, spleen, pancreas, intestine (duodenum, jejunum, ileum, colon), kidneys, urinary bladder, perioral skin and brain. Duodenal histopathological changes revealed minimal multifocal predominantly lymphocytic submucosal inflammatory reaction. Both kidneys presented with mild-to-moderate multifocal to global thickening of most glomerular membranes, which was suspicious of membranous glomerulonephritis (Figure 3). No relevant histological lesions were identified in any of the remaining organs.

Discussion

Hyperammonaemia can develop secondarily to different mechanisms: (1) acquired urea cycle amino acid deficiency; (2) cobalamin deficiency leading to accumulation of methylmalonic acid (MMA) and subsequent impaired uptake of ammonia into the urea cycle;^{16,17} and (3) congenital deficiency in urea cycle enzymes such as ornithine

transcarbamylase (OTC) deficiency.¹⁸ The plasma amino acid profile in this case revealed several urea cycle amino acids deficiencies (citrulline, ornithine and arginine), which could be responsible for the hyperammonaemia. Nutrition with a good quality liquid diet (Royal Canin Convalescence), which contained adequate levels of arginine, as well as the other essential amino acids, was provided. Based on the European Pet Food Industry Federation nutrient recommendations, the minimum arginine levels recommended in cats are 0.33 g per 100 kcal of metabolisable energy, and the liquid diet provided contained 0.6 g per 100 kcal of metabolisable energy. Data concerning ornithine and citrulline levels were not available. Post-mortem examination did not show evidence of a portosystemic shunt or parenchymal hepatic lesions. Although serum cobalamin was normal, MMA aciduria as a cause or contributing factor for the encephalopathy of this cat could not be ruled out. In people, the association of increased ammonia, low citrulline and increased orotic acid in the urine is a typical biochemical phenotype for OTC deficiency. In the present case, a urine organic acid profile could not be performed for practical reasons, and therefore OTC deficiency could not be completely ruled out. However, this rare congenital disease is usually diagnosed in kittens, and is thus unlikely in this adult cat.¹⁸ In addition, people affected by this disease often have a high glutamine concentration, which was not present in this cat (Table 1).¹⁹ Besides OTC deficiency, arginosuccinate synthetase deficiency, another urea cycle enzyme deficiency, has been described in dogs but not in cats.²⁰ Humans with the latter enzyme deficiency have been shown to have a high plasma citrulline concentration; again, this was not identified in this cat (Table 1).

Acute-onset hyperammonaemia secondary to an arginine-restricted diet is well recognised in cats.^{8,10} Experimentally, near-adult cats given a single meal of a diet deficient in arginine, but containing all other amino acids, developed hyperammonaemia with clinical signs of ammonia toxicity within 2 h, including emesis, lethargy, vocalisation, frothing at the mouth, hyperactivity, hyperaesthesia, ataxia, emprosthotonos, extended limbs, exposed claws, and marked bradypnoea and cyanosis in severely affected cats.⁸ Most of these clinical signs correspond to this cat's neurological presentation. Owing to the absence of relevant histopathological changes in the brain, such as the presence of Alzheimer type 2 cells and spongiosis, and the presence of a markedly elevated plasma ammonia, an acute hyperammonaemic encephalopathy was considered most likely. Although the exact cause for the cat's hyperammonaemia remains unclear, several contributing factors, discussed below, were suspected, including decreased intestinal absorption of essential amino acids due to IBD and decreased renal arginine synthesis secondary to CKD.

Intestinal absorption of arginine involves a transport system shared with lysine, ornithine and cystine. The transport system is adenosine triphosphate and sodium dependent and has substrate specificity.^{21–23} Theoretically, this transporter could be affected in the presence of IBD, and, consequently, decreased intestinal arginine uptake would be expected. One human case of short bowel syndrome and chronic renal failure associated with secondary hyperammonaemia has been reported. The concurrent decrease in ornithine plasma levels supports this theory.¹² In the current case, the duodenal biopsies revealed enteritis with severe villous blunting and this is likely to have caused malabsorption. Hence, decreased intestinal absorption of arginine likely contributed to the hypoargininaemia in our case.

Marked hyperammonemia was reported in a case series of four severely azotaemic cats, and in two of these cats the hyperammonaemia was associated with neurological signs consistent with an encephalopathy.¹⁵ However, in another study with azotaemic cats, plasma arginine concentrations were almost always within the normal range.²⁴ Therefore, azotaemia should not be considered as the only triggering factor for hyperammonaemia in cats with CKD.

In one study, cats with CKD were found to have significantly lower serum cobalamin concentration and higher serum MMA concentration than healthy cats. However, their serum cobalamin concentration was often within the normal range. Some authors suggest that cobalamin deficiency may be a potential cause of urea cycle dysfunction in cats with CKD.²⁵ In our case, 250 µg cyanocobalamin was pre-emptively administered subcutaneously on admission and the serum cobalamin on blood taken prior to supplementation was well within the normal range (375 ng/l; RI 240–440). The MMA status could not be assessed in this cat; however, the few feline cases reported in the literature with hyperammonaemic encephalopathy and high MMA concentration had low serum cobalamin concentrations.^{16,17}

Conclusions

This case report demonstrates that hyperammonaemia secondary to hypoargininaemia can occur despite appropriate supplementation with a commercially formulated enteral diet. The presence of enteritis and CKD were considered to be contributing factors. In such cases, if amino acid deficiency is identified, parenteral amino acid supplementation would be recommended in order to prevent a life-threatening onset of hyperammonaemic encephalopathy.

Conflict of interest The authors declared no potential conflicts of interest with respect to the research, authorship, and/or publication of this article.

Funding The authors received no financial support for the research, authorship, and/or publication of this article.

ORCID iD Cécile Dor  <https://orcid.org/0000-0001-8549-4553>

References

- Porembska Z, Baranczyk A and Jachimowicz. **Arginase isoenzymes in liver and kidney of some mammals.** *Acta Biochim Polon* 1971; 18: 77–85.
- Ratner S. **Enzymes of arginine and urea synthesis.** *Adv Enzymol* 1973; 39: 1–90.
- Ratner S and Petrack B. **The mechanism of arginine synthesis from citrulline in kidney.** *J Biol Chem* 1953; 200: 175–185.
- Morris JG, Rogers QR, Winterrowd DL, et al. **The utilization of ornithine and citrulline by the growing kitten.** *J Nutr* 1979; 109: 724–729.
- Levillain O, Parvy P and Hus-Citharel A. **Arginine metabolism in cat kidney.** *J Physiol* 1996; 491: 471–477.
- Rogers QR and Phang JM. **Deficiency of pyrroline-5-carboxylate synthase in the intestinal mucosa of the cat.** *J Nutr* 1985; 115: 146–150.
- Morris JG and Rogers QR. **Arginine: an essential amino acid for the cat.** *J Nutr* 1978; 108: 1944–1953.
- Morris JG and Rogers QR. **Ammonia intoxication in the near-adult cat as a result of a dietary deficiency of arginine.** *Science* 1978; 199: 431–432.
- Morris JG and Rogers QR. **Essentiality of amino acids for the growing kitten.** *J Nutr* 1979; 109: 718–723.
- Stewart PM, Batshaw M, Valle D, et al. **Effects of arginine-free meals on ureagenesis in cats.** In: Lowenthal A, Mori A and Marescau B (eds). *Urea cycle diseases. advances in experimental medicine and biology.* Boston, MA: Springer, 1982, p 153.
- Zoran ZL. **The carnivore connection to nutrition in cats.** *J Vet Am Med Assoc* 2002; 221: 1559–1567.
- Yokoyama K, Ogura Y, Kawabata M, et al. **Hyperammonemia in a patient with short bowel syndrome and chronic renal failure.** *Nephron* 1996; 72: 693–695.
- Coburn LA, Horst SN, Allaman MM, et al. **L-arginine availability and metabolism is altered in ulcerative colitis.** *Inflamm Bowel Dis* 2016; 22: 1847–1858.
- Coburn LA, Gong X, Singh K, et al. **L-arginine supplementation improves responses to injury and inflammation in dextran sulfate sodium colitis.** *PLoS One* 2012; 7: e33546.
- Adagra C and Foster DJ. **Hyperammonaemia in four cats with renal azotemia.** *J Feline Med Surg* 2015; 17: 168–172.
- Watanabe T, Hoshi K, Zhang C, et al. **Hyperammonemia due to cobalamin malabsorption in a cat with exocrine pancreatic insufficiency.** *J Feline Med Surg* 2012; 14: 942–945.
- Simpson K, Battersby I and Lowry M. **Suspected acquired hypcobalaminemic encephalopathy in a cat; resolution of encephalopathic signs and MRI lesions subsequent to cobalamin supplementation.** *J Feline Med Surg* 2012; 14: 350–355.
- Washizu T, Washizu M, Zhang C, et al. **A suspected case of ornithine transcarbamylase deficiency in a cat.** *J Vet Med Sci* 2004; 66: 701–703.
- Lichter-Konecki U, Caldovic L, Morizono H, et al. **Ornithine transcarbamylase deficiency.** *GeneReviews.* Seattle, WA: University of Washington, Seattle, 1993–2018.
- Strombeck DR, Meyer DJ and Freedland RA. **Hyperammonemia due to a urea cycle enzyme deficiency in two dogs.** *J Am Vet Med Assoc* 1975; 166: 1109–11.
- Thier SO, Segal S, Fox M, et al. **Cystinuria: defective intestinal transport of dibasic amino acids and cystine.** *J Clin Invest* 1965; 46: 442–448.
- Milne MD, Asatoor AM, Edwards KDG, et al. **The intestinal absorption defect in cystinuria.** *Gut* 1961; 2: 323–337.
- Barbul A. **Arginine: biochemistry, physiology, and therapeutic implications.** *Parenter Enteral Nutr* 1986; 10: 227–238.
- Jepson RE, Syme HM, Vallance C, et al. **Plasma asymmetric dimethylarginine, symmetric dimethylarginine, L-arginine, and nitrite/nitrate concentrations in cats with chronic kidney disease and hypertension.** *J Vet Intern Med* 2008; 22: 317–324.
- Pera J, Eatroff A, Langston C, et al. **Serum cobalamin, folate and methylmalonic acid concentrations in cats with chronic kidney disease.** *ACVIM Forum Research Abstract Program.* *J Vet Intern Med* 2013; 27: 604–756.