



Recanalisation of a congenital extrahepatic portosystemic shunt previously attenuated with cellophane banding in a cat

Authors: Crowley, James, Foo, Timothy, Boland, Lara, and Brunel, Laurencie

Source: Journal of Feline Medicine and Surgery Open Reports, 4(2)

Published By: SAGE Publishing

URL: <https://doi.org/10.1177/2055116918795717>

BioOne Complete (complete.BioOne.org) is a full-text database of 200 subscribed and open-access titles in the biological, ecological, and environmental sciences published by nonprofit societies, associations, museums, institutions, and presses.

Your use of this PDF, the BioOne Complete website, and all posted and associated content indicates your acceptance of BioOne's Terms of Use, available at www.bioone.org/terms-of-use.

Usage of BioOne Complete content is strictly limited to personal, educational, and non - commercial use. Commercial inquiries or rights and permissions requests should be directed to the individual publisher as copyright holder.

BioOne sees sustainable scholarly publishing as an inherently collaborative enterprise connecting authors, nonprofit publishers, academic institutions, research libraries, and research funders in the common goal of maximizing access to critical research.



Recanalisation of a congenital extrahepatic portosystemic shunt previously attenuated with cellophane banding in a cat

Journal of Feline Medicine and Surgery Open Reports
1–5

© The Author(s) 2018

Reprints and permissions:

sagepub.co.uk/journalsPermissions.nav

DOI: 10.1177/2055116918795717

journals.sagepub.com/home/jfmsopenreports

This paper was handled and processed by the European Editorial Office (ISFM) for publication in *JFMS Open Reports*



James Crowley, Timothy Foo, Lara Boland and Laurencie Brunel

Abstract

Case summary A congenital extrahepatic portosystemic shunt was attenuated with commercial roll cellophane banding in a cat and postoperative liver changes were monitored using CT angiography (CTA). The patient clinically improved after cellophane banding, characterised by resolution of hepatic encephalopathy, weight gain, reference interval (RI) bile acid stimulation tests, as well as CTA-documented increased liver size, increased hepatic vasculature and shunt attenuation. Six months later the cat re-presented with recurrence of clinical signs and increased bile acids. CTA confirmed recanalisation of the shunt. Shunt attenuation was repeated using pure cellophane banding and nearly complete closure of the shunt was later documented by CTA. Seven months later, recanalisation was again documented via CTA and associated with clinical signs and increased bile acids. Complete ligation of the shunt was achieved using a polypropylene ligature and a titanium ligating clip. At long-term follow-up, the cat was clinically well, and bile acids and biochemistry were within the RIs.

Relevance and novel information This is the first report of CTA-documented recanalisation of an extrahepatic portosystemic shunt previously attenuated with cellophane banding. Recanalisation should be considered as a differential for recurrence of hepatic encephalopathy following cellophane banding.

Keywords: Extrahepatic portosystemic shunt; cellophane banding; recanalisation; computed tomography angiography

Accepted: 6 July 2018

Introduction

Congenital portosystemic shunts (PSS) are anomalous vessels that connect the portal and systemic venous circulation, allowing blood to bypass the liver.^{1–3} PSS result in inadequate hepatic development, altered protein metabolism and production, and reduced clearance of toxins and drugs. Congenital PSS are uncommon in cats, with a reported incidence of 2.5 per 10,000 cats treated in referral practice.⁴ Most animals with a congenital PSS present at a young age, with chronic illness and clinical signs associated with gastrointestinal, urinary or neurological dysfunction.

A variety of imaging modalities have been described for the diagnosis of PSS, including abdominal ultrasound,

portovenography, scintigraphy, MRI and CT angiography (CTA). CTA was recently described as a less invasive means of determining shunt morphology than more

University Veterinary Teaching Hospital Sydney, Sydney School of Veterinary Science, Faculty of Science, University of Sydney, NSW, Australia

Corresponding author:

Laurencie Brunel DVM, MVS, Dip ECVS, University Veterinary Teaching Hospital Sydney, Sydney School of Veterinary Science, Faculty of Science, University of Sydney, Evelyn Williams Building B10, NSW 2006, Australia
Email: laurencie.brunel@sydney.edu.au



Creative Commons Non Commercial CC BY-NC: This article is distributed under the terms of the Creative Commons

Attribution-NonCommercial 4.0 License (<http://www.creativecommons.org/licenses/by-nc/4.0/>) which permits non-commercial use, reproduction and distribution of the work without further permission provided the original work is attributed as specified on the SAGE and Open Access pages (<https://us.sagepub.com/en-us/nam/open-access-at-sage>).

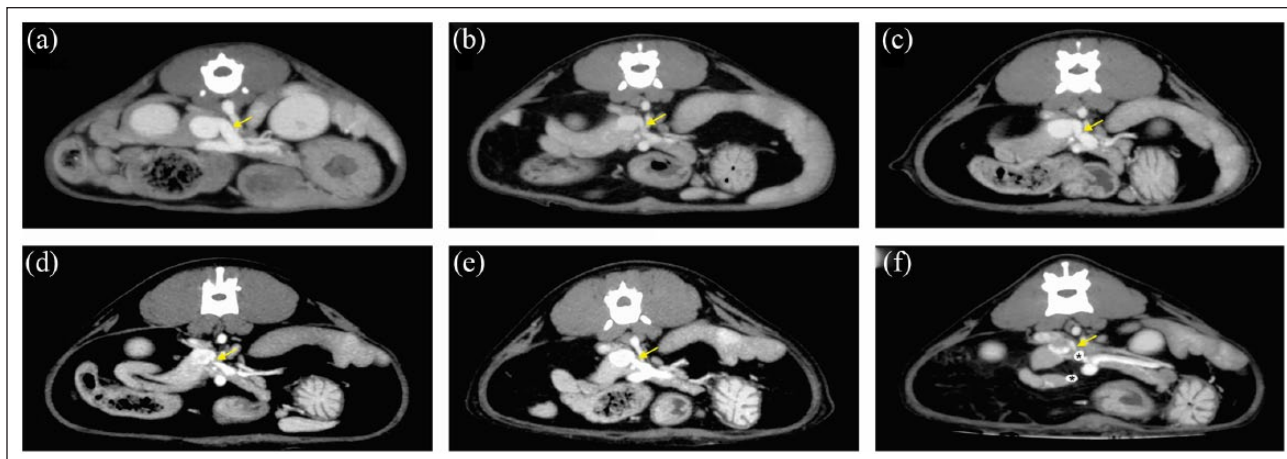


Figure 1 Thick-slab maximum intensity projection (MIP) (4 mm) CTA images of the cat. The right of the animal is to the left of the image. (a) Preoperative CTA shows the 4.2 mm diameter shunt vessel (arrow) anastomosing with the left side of the caudal vena cava. (b) Two month postoperative CTA shows moderate reduction in the size of the shunt vessel (2 mm) (arrow). (c) Six month postoperative CTA shows dilation of the shunt vessel (3.5 mm) (arrow) compared with the previous study, consistent with shunt recanalisation. (d) Four month postoperative CTA obtained after revision surgery shows almost complete attenuation of the PSS (<1 mm) (arrow). (e) Seven month post-revision CTA shows dilation of the shunt vessel (3 mm) (arrow) consistent with shunt recanalisation. (f) Final 4 month post-revision CTA shows complete attenuation of the shunt (arrow). Haemoclips are visible (asterisks)

traditional portograms, providing greater morphological information than trans-splenic scintigraphy and greater sensitivity than abdominal ultrasound.⁵

Medical management may control clinical signs of hepatic encephalopathy in the short term. In dogs, surgery is correlated with a longer survival time.^{6,7} In cats, no study has directly compared the outcome of medical and surgical management.⁸ There are limited reports of poor outcomes with medical management,⁹ whereas several studies have reported favourable outcomes with surgical management.^{10–13} Surgical treatment involves attenuation of the shunt with a polypropylene ligature or gradual attenuation using an ameroid constrictor, cellophane banding, hydraulic occluder or thrombogenic coil.¹⁴

Partial ligation of PSS is associated with a greater recurrence of clinical signs and patient morbidity than complete ligation in dogs.⁶ The prognosis for cats with extrahepatic PSSs attenuated by cellophane banding is reportedly variable, ranging from poor to good.^{11,12} Many cats have recurrence of clinical signs presumably due to persistent shunting, development of multiple acquired shunts or congenital portal venous hypoplasia; however, the cause often remains undetermined.¹⁵ In this report, we describe a case of CTA-documented recanalisation of an extrahepatic PSS previously attenuated twice with cellophane banding in a cat.

Case description

A 4-month-old male entire British Shorthair cat was referred with a 2 week history of ptyalism, head pressing, ataxia, lethargy and constipation. On physical

examination, vital signs were within normal limits. The cat weighed 1.4 kg, was of small stature, had a body condition score of 4/9 and was mildly obtunded. A bile acid stimulation test was markedly increased (fasting 191 $\mu\text{mol/l}$, reference interval [RI] 0–16 $\mu\text{mol/l}$; post-prandial 138 $\mu\text{mol/l}$, RI 0–25). Haematology and serum biochemistry were within the RIs.

Abdominal CTA consisting of pre- and post-contrast scans was performed under general anaesthesia with a 16-slice multi-detector CT scanner (Philips Brilliance, 16 Slice; Philips Medical Systems). A soft tissue algorithm reconstruction filter was used. The cat received 740 mgI/kg of an iso-osmolar iodinated intravenous contrast medium (Omnipaque; GE Healthcare) using a concentration of 370 mgI/ml at 2 ml/kg administered over 20 minutes via the cephalic vein by means of an automated injector (Empower CTA; EZ-EM). A single, slightly tortuous, anomalous vessel was identified arising from the portal vein junction between the left gastric and splenic vein. This vessel coursed dorsally and slightly caudally before anastomosing with the left side of the caudal vena cava. This vessel measured 4.2 mm at its widest point. A single extrahepatic portocaval shunt (left gastric to caudal vena cava) was diagnosed (Figure 1a). A retained left inguinal testicle was also noted. Medical management was commenced with amoxicillin–clavulanate (12.5 mg/kg PO q12 h), lactulose (0.5 ml PO q12 h), levetiracetam (20 mg/kg PO q8h) and a restricted protein prescription diet (Hill's k/d; Hills' Pet Nutrition) for 2 weeks prior to surgery.

A routine midline coeliotomy was performed and allowed visualisation of the anomalous vessel cranial to

the right kidney, creating a communication between the left gastric vein and the caudal vena cava. A band of commercial cellophane roll (10 cm long \times 1.2 cm wide) was prepared as previously described.¹⁶ Briefly, the band of cellophane was folded longitudinally to form a three-layered strip (10 cm long, approximately 4 mm wide).¹¹ The cellophane was placed circumferentially around the vessel and secured with a single polymer-ligating clip (Hem-o-lok; Teleflex). The final internal diameter of the cellophane band was based on portal pressure changes (portal pressure \leq 16 mmHg) and changes in colour and motility of the small intestine and pancreas.¹⁴ A single polypropylene suture was placed around the shunt to serve as a potential point of reference. Hepatic biopsies were collected via the guillotine method. Open castration was performed (left inguinal, right scrotal testicle). Opioid analgesia was provided intraoperatively (fentanyl 3–5 μ g/kg/h IV via constant rate infusion) and postoperatively (methadone 0.2 mg/kg IM q4h).

The cat recovered uneventfully and was discharged 3 days later on continued medical management. Hepatic histopathology revealed moderate portal arteriole hyperplasia, mild hepatocellular vacuolation, biliary hyperplasia and portal fibrosis, which were all consistent with a congenital vascular anomaly, such as a PSS.¹⁷

Two months after surgical attenuation, the cat was doing well, with a good appetite and weight gain. Repeat abdominal CTA revealed significant reduction in the size of the shunt vessel (2 mm diameter), moderate increase in size of the post-shunt portal vein and improved visualisation of intrahepatic portal veins (Figure 1b). Repeat serum bile acids were within the RI (fasting $<$ 1 μ mol/l [RI 0–11 μ mol/l]; postprandial 2 μ mol/l [RI 0–21 μ mol/l]).

The cat re-presented 6 months postoperatively for recurrence of clinical signs compatible with hepatic encephalopathy. Oral medications had been discontinued 6 weeks earlier and the cat had started to receive a non-protein-restricted commercial diet. Serum bile acids were increased (fasting 33 μ mol/l [RI 0–16 μ mol/l]; postprandial 111 μ mol/l [RI 0–25 μ mol/l]). Abdominal CTA revealed the shunt had enlarged (3.5 mm) compared to the study performed 2 months postoperatively (2 mm), consistent with recanalisation (Figure 1c). There was no evidence of the development of acquired shunts. Medical management was recommenced prior to repeat surgical attenuation.

Two weeks later, the cat underwent exploratory laparotomy. The previously attenuated shunt vessel was identified and associated with fibrous adhesions. The polymer clip was palpable and surrounded by fibrous tissue; however, the cellophane band was no longer distinguishable. An attempt was made to ligate the shunt vessel, but there was evidence of intraoperative portal hypertension. It was not possible to insert an ameroid

constrictor owing to the presence of the polymer clip and the short distance between the caudal vena cava and the first vessel anastomosing into the shunt. Cellophane banding was repeated as previously described, this time using pure cellophane (Cello sheet, Clear Cello; Hallmark Cards) and a polypropylene ligature was tied loosely over the shunt vessel as a reference. Opioid analgesia was provided as described previously. Recovery from general anaesthesia and surgery was, again, uneventful.

Four months later, serum bile acids were within the RI (fasting $<$ 1 μ mol/l [RI 0–11 μ mol/l]; postprandial 12 μ mol/l [RI 0–21 μ mol/l]). Abdominal CTA revealed increased liver volume and vascularisation, as well as nearly complete closure of the PSS ($<$ 1 mm diameter) (Figure 1d). Seven months postoperatively, clinical signs of hepatic encephalopathy recurred. Serum bile acids were markedly increased (fasting 115 μ mol/l [RI 0–11 μ mol/l]). CTA findings were again consistent with recanalisation of the shunt vessel (3 mm diameter) without evidence of acquired shunting (Figure 1e). The cat again underwent exploratory laparotomy, where it was possible to ligate the shunt using a polypropylene suture and a titanium ligating clip (Hemclip; Teleflex). There was no evidence of intraoperative portal hypertension.

Two days postoperatively, the cat developed a chyloabdomen, suspected owing to mild portal hypertension. The fluid leaked through the abdominal wall via the surgical incision. The chyloabdomen resolved spontaneously after 5 days. The cat also developed an oesophageal fistula following removal of an oesophageal feeding tube (in situ for 3 days). The fistula was surgically explored and closed 1 week following shunt ligation.

One month later, the cat was doing well with serum bile acids within the RI (fasting 1 μ mol/l, RI 0–11; postprandial 4 μ mol/l, RI 0–21). Abdominal CTA revealed closure of the shunt (Figure 1f). At the most recent follow-up 5 months after the final surgery, the cat had had no recurrence of hepatic encephalopathy.

Discussion

To our knowledge, this is the first reported case of CTA-documented recanalisation of an extrahepatic PSS previously attenuated with cellophane banding in a cat. Long-term outcome associated with surgical treatment of PSS in cats appears highly variable, with survival rates ranging from 56–100%.^{11,12,18} Up to 75% of cats have been reported to have complications.¹⁰ The most common is neurological dysfunction, such as seizures or central blindness. Failure of PSS attenuation may be due to persistent shunting due to incomplete attenuation, the presence of a second anomalous vessel, development of multiple acquired shunts, congenital portal venous hypoplasia or recanalisation.¹⁴ Prognosis and outcomes following PSS attenuation in cats are incompletely understood and do not necessarily correlate with hepatic

function test results.^{10,12,18} Consistent postoperative ultrasound, scintigraphy or abdominal CTA is not usually reported but could provide additional information.

Extravascular placement of cellophane bands produces a chronic foreign body reaction responsible for the progressive vascular occlusion produced over 6–8 weeks.¹⁴ Hunt et al reported 100% survival of five cats with PSS attenuated by cellophane banding.¹¹ One cat had improvement in clinical signs, despite lack of attenuation of the shunt. The authors hypothesised that failure of shunt attenuation may indicate a species difference in response to cellophane banding. Similarly, in this case report, we can only speculate on the reason for attenuation followed by recanalisation. It is suspected that the initial shunt attenuation is maintained by the cellophane band itself until breakage and recanalisation secondary to a lack of fibrous tissue formation. Indeed, cellophane banding of PSS in cats may result in insufficient inflammatory reaction to cause permanent attenuation.

The type of cellophane used has been previously discussed as a possible explanation for long-term outcomes in both dogs and cats. Cellophane is an anisotropic hydrophilic thin film made of regenerated cellulose.¹⁹ There are many types of thin film, and cellophane in particular, which vary significantly in their structural and mechanical properties.²⁰ Smith et al concluded that a number of thin films used for shunt attenuation are often not consistent with true cellophane.²¹ We used commercial roll cellophane and then pure cellophane (Cello sheet, Clear Cello; Hallmark Cards) in our case. Both types of cellophane still resulted in vessel recanalisation, which may oppose the theory that the composition of cellophane used is clinically important.

Interestingly, our case presents a unique set of circumstances where by the cat's shunt recanalised twice, and it developed an oesophageal fistula following oesophageal feeding tube removal and chyloabdomen where chylous fluid leaked through the abdominal wall via the surgical incision. The possibility of delayed wound healing due to a congenital collagen defect in this cat was not excluded. However, the cat had recovered uneventfully from the first two surgeries and heritable collagen defects have not been reported in British Shorthair cats. Cutaneous asthenia has been reported in cats,²² and this cannot be excluded as a cause of failed shunt attenuation; however, there was no clinical evidence of this condition and wound healing otherwise occurred normally.

CTA is the gold standard for PSS evaluation in humans and has proven to be a reliable imaging modality for dogs and cats.^{5,23–26} CTA is increasingly favoured to provide a definitive diagnosis and accurate representation of shunt morphology and intrahepatic vasculature development to aid surgical correction.²⁷ CTA is particularly useful for preoperative planning and does not significantly impact surgical procedure time, complication

rate or clinical outcome in dogs.²⁸ Recent prospective studies in dogs have reported the use of CTA to document the response of the liver and vasculature to surgical attenuation and can provide indications of device failure or development of acquired shunts.^{29,30} In this case report, CTA was able to document long-term PSS recanalisation following surgical attenuation with cellophane banding. CTA findings should be interpreted together with liver function testing, history, clinical signs and physical examination findings.

Conclusions

Recanalisation of previously attenuated extrahepatic PSS in cats might be under-reported in veterinary practice. A larger case series is required to determine the incidence of PSS recanalisation in cats and its correlation with recurrence of clinical signs of hepatic encephalopathy, as well as the incidence of recanalisation in relation to the device used (cellophane banding vs ameroid constrictor vs ligature). Our report suggests that CTA should not only be considered for shunt diagnosis, but also for monitoring shunt attenuation by gradual occluding devices.

Conflict of interest The authors declared no potential conflicts of interest with respect to the research, authorship, and/or publication of this article.

Funding The authors received no financial support for the research, authorship, and/or publication of this article.

References

- McAlinden AB, Buckley CT and Kirby BM. **Biomechanical evaluation of different numbers, sizes and placement configurations of ligaclips required to secure cellophane bands.** *Vet Surg* 2010; 39: 59–64.
- Vogt JC, Krahwinkel DJ Jr, Bright RM, et al. **Gradual occlusion of extrahepatic portosystemic shunts in dogs and cats using the ameroid constrictor.** *Vet Surg* 1996; 25: 495–502.
- Szatmári V, Rothuizen J, van Sluijs FJ, et al. **Ultrasonographic evaluation of partially attenuated congenital extrahepatic portosystemic shunts in 14 dogs.** *Vet Rec* 2004; 155: 448–456.
- Levy JK, Bunch SE and Komtebedde J. **Feline portosystemic vascular shunts.** In: Bonagura JD (ed). *Kirk's current veterinary therapy XII small animal practice*. Philadelphia, PA: WB Saunders, 1995, pp 743–749.
- Zwingenberger AL. **CT diagnosis of portosystemic shunts.** *Vet Clin North Am Small Anim Pract* 2009; 39: 783–792.
- Traverson M, Lussier B, Huneault L, et al. **Comparative outcomes between ameroid ring constrictor and cellophane banding for treatment of single congenital extrahepatic portosystemic shunts in 49 dogs (1998–2012).** *Vet Surg* 2018; 47: 179–187.
- Sereda CW and Adin CA. **Methods of gradual vascular occlusion and their applications in treatment of congenital portosystemic shunts in dogs: a review.** *Vet Surg* 2005; 34: 83–91.

- 8 Tivers M and Lipscomb VJ. **Congenital portosystemic shunts in cats – surgical management and prognosis.** *J Feline Med Surg* 2011; 13: 185–194.
- 9 Blaxter AC, Holt PE, Pearson GR, et al. **Congenital portosystemic shunts in the cat: a report of nine cases.** *J Small Anim Pract* 1988; 29: 631–645.
- 10 Kyles AE, Hardie EM, Mehl M, et al. **Evaluation of ameroid ring constrictors for the management of single extra hepatic portosystemic shunts in cats: 23 cases (1996–2001).** *J Am Vet Med Assoc* 2002; 220: 1341–1347.
- 11 Hunt GB, Kummelling A, Tisdall PLC, et al. **Outcomes of cellophane banding for congenital portosystemic shunts in 106 dogs and 5 cats.** *Vet Surg* 2004; 33: 25–31.
- 12 Lipscomb VJ, Jones HJ and Brockman DJ. **Complications and long-term outcomes of the ligation of congenital portosystemic shunts in 49 cats.** *Vet Rec* 2007; 160: 465–470.
- 13 Cabassu J, Seim HB 3rd, MacPhail CM, et al. **Outcomes of cats undergoing surgical attenuation of congenital extrahepatic portosystemic shunts through cellophane banding: 9 cases (2000–2007).** *J Am Vet Med Assoc* 2011; 238: 89–93.
- 14 Landon B, Abraham L and Charles J. **Use of transcolonic portal scintigraphy to evaluate efficacy of cellophane banding of congenital extrahepatic portosystemic shunts in 16 dogs.** *Aust Vet J* 2008; 86: 169–179.
- 15 Wolschrijn CF, Mahapokai W, Rothuizen J, et al. **Gauged attenuation of congenital portosystemic shunts: results in 160 dogs and 15 cats.** *Vet Q* 2000; 22: 94–98.
- 16 Youmans KR and Hunt GB. **Cellophane banding for the gradual attenuation of single extrahepatic portosystemic shunts in eleven dogs.** *Aust Vet J* 1998; 76: 531–537.
- 17 Maxie G. **Developmental disorders.** In: Jubb, Kennedy and Palmer's pathology of domestic animals. 6th ed. St Louis, MO: Elsevier, 2016, p 267.
- 18 Havig M and Tobias KM. **Outcome of ameroid constrictor occlusion of single congenital extrahepatic portosystemic shunts in cats: 12 cases (1993–2000).** *J Am Vet Med Assoc* 2002; 220: 337–341.
- 19 Hayden WL. **Manufacture and properties of regenerated cellulose films.** *Ind Eng Chem* 1929; 21: 405–410.
- 20 Laity PR, Glover PM, Godward J, et al. **Structural studies and diffusion measurements of water-swollen cellophane by NMR imaging.** *Cellulose* 2000; 7: 227–246.
- 21 Smith RR, Hunt GB, Garcia-Nolen TC, et al. **Spectroscopic and mechanical evaluation of thin film commonly used for banding congenital portosystemic shunts in dogs.** *Vet Surg* 2013; 42: 478–487.
- 22 Hansen N, Foster SF, Burrows AK, et al. **Cutaneous asthenia (Ehlers-Danlos like syndrome) of Burmese cats.** *J Feline Med Surg* 2015; 17: 954–963.
- 23 Frank P, Mahaffey M, Egger C, et al. **Helical computed tomographic portography in ten normal dogs and ten dogs with a portosystemic shunt.** *Vet Radiol Ultrasound* 2003; 44: 392–400.
- 24 Nelson NC and Nelson LL. **Anatomy of extrahepatic portosystemic shunts in dogs as determined by computed tomography angiography.** *Vet Radiol Ultrasound* 2011; 52: 498–506.
- 25 Zwingenberger AL and Schwarz T. **Dual-phase CT angiography of the normal canine portal and hepatic vasculature.** *Vet Radiol Ultrasound* 2004; 45: 117–124.
- 26 Zwingenberger AL, Schwarz T and Saunders HM. **Helical computed tomographic angiography of canine portosystemic shunts.** *Vet Radiol Ultrasound*. 2005; 46: 27–32.
- 27 Brown JC, Chanoit G and Reeder J. **Complex extra hepatic portocaval shunt with unusual caval features in a cat: computed tomographic characterisation.** *J Small Anim Pract* 2010; 51: 227–230.
- 28 Brunson BW, Case JB, Ellison G, et al. **Evaluation of surgical outcome, complications and mortality in dogs undergoing preoperative computed tomography angiography for diagnosis of an extrahepatic portosystemic shunt: 124 cases (2005–2014).** *Can Vet J* 2016; 57: 59–64.
- 29 Zwingenberger AL, Daniel L, Steffey MA, et al. **Correlation between liver volume, portal vascular anatomy, and hepatic perfusion in dogs with congenital portosystemic shunt before and after placement of ameroid constrictors.** *Vet Surg* 2014; 43: 926–934.
- 30 Nelson NC and Nelson LL. **Imaging and clinical outcomes in 20 dogs treated with thin film banding for extrahepatic portosystemic shunts.** *Vet Surg* 2016; 45: 736–745.