



Pericardial flap to repair a pulmonary laceration in a cat with pyothorax

Authors: Pérez López, Pablo, and Martinoli, Stefania

Source: Journal of Feline Medicine and Surgery Open Reports, 4(2)

Published By: SAGE Publishing

URL: <https://doi.org/10.1177/2055116918817385>

BioOne Complete (complete.BioOne.org) is a full-text database of 200 subscribed and open-access titles in the biological, ecological, and environmental sciences published by nonprofit societies, associations, museums, institutions, and presses.

Your use of this PDF, the BioOne Complete website, and all posted and associated content indicates your acceptance of BioOne's Terms of Use, available at www.bioone.org/terms-of-use.

Usage of BioOne Complete content is strictly limited to personal, educational, and non - commercial use. Commercial inquiries or rights and permissions requests should be directed to the individual publisher as copyright holder.

BioOne sees sustainable scholarly publishing as an inherently collaborative enterprise connecting authors, nonprofit publishers, academic institutions, research libraries, and research funders in the common goal of maximizing access to critical research.



Pericardial flap to repair a pulmonary laceration in a cat with pyothorax

Pablo Pérez López  and Stefania Martinoli

Journal of Feline Medicine and Surgery Open Reports

1–8

© The Author(s) 2018

Article reuse guidelines:

sagepub.com/journals-permissions

DOI: 10.1177/2055116918817385

journals.sagepub.com/home/jfmsopenreports

This paper was handled and processed by the European Editorial Office (ISFM) for publication in *JFMS Open Reports*



Abstract

Case summary A 2-year-old female neutered domestic shorthair cat was presented for investigation of acute onset tachypnoea and dyspnoea. Pyothorax was diagnosed based on thoracic radiographs and fluid analysis. Medical treatment consisted of bilateral thoracostomy tube placement, antibiotic therapy and thoracic lavage. After 12 days of medical management infection was still present, warranting exploratory thoracotomy. At surgery, encapsulated abscesses were found in the left lung, right cranial and right middle lobes. The right caudal lobe was the only macroscopically non-abscessated lobe, and appeared to have a parenchymal laceration 8 mm long over the dorsolateral surface. Following partial pericardiectomy, mediastinectomy and debridement of abscesses, a pericardial flap was reflected caudolaterally and apposed over the laceration to seal the affected lung lobe. This flap was sutured to a rim of fibrinous adhesion that was partially covering this lobe. After 8 days the cat was discharged with antibiotic therapy for 3 more weeks. Follow-up assessment at 19 and 38 weeks postoperatively confirmed the cat to have good exercise tolerance. Thoracic radiographs at 19 weeks revealed good bilateral aeration of the pulmonary parenchyma without pleural effusion.

Relevance and novel information Lung lobe laceration can be treated by lung lobectomy or direct suturing of the lung parenchyma. This is the first report using a pericardial flap to repair a lung laceration. Pericardial flap was successfully used to treat this lung laceration where lobectomy was contraindicated. Encouraging results were present at 8 months postoperatively.

Keywords: Lacerations; lung; sternotomy; pericardium; pleural effusion

Accepted: 13 November 2018

Introduction

Pyothorax is characterised by the accumulation of purulent exudate within the pleural space. The cause of pyothorax is identified in only 46–67% of feline cases.^{1–3}

Causative mechanisms for pyothorax include haematogenous or lymphatic spread from a distant site, extension from an adjacent intrathoracic structure or direct inoculation. In cats, extension of the infection from an adjacent intrathoracic structure accounts for 59% of the cases and is the most reported cause.³

Lung lobe laceration can be induced by blunt or penetrating trauma to the thoracic cavity, but may also occur with diagnostic or therapeutic procedures such as closed thoracostomy tube placement, thoracocentesis or lung aspirates.^{4,5}

To our knowledge, this is the first report of a pericardial flap used to close a parenchymal lung laceration.

Case description

A 2-year-old female neutered domestic shorthair cat was presented to our multidisciplinary specialist referral hospital for investigation of acute onset of tachypnoea and dyspnoea.

On physical examination, the patient was depressed, 5% dehydrated, tachycardic (180 beats per minute) and tachypnoeic (60 breaths per minute). Mild respiratory effort was present and lung sounds were attenuated,

Dick White Referrals, Six Mile Bottom, UK

Corresponding author:

Pablo Pérez López Ldo Vet, MRCVS, PGDip, PGCert, RCVS Advanced Practitioner in Small Animal Surgery, 9 Delamere Close, Six Mile Bottom, Cambridgeshire CB8 0XF, UK
Email: pabloperezlopez@hotmail.com



Creative Commons Non Commercial CC BY-NC: This article is distributed under the terms of the Creative Commons

Attribution-NonCommercial 4.0 License (<http://www.creativecommons.org/licenses/by-nc/4.0/>) which permits non-commercial use, reproduction and distribution of the work without further permission provided the original work is attributed as specified on the SAGE and Open Access pages (<https://us.sagepub.com/en-us/nam/open-access-at-sage>).

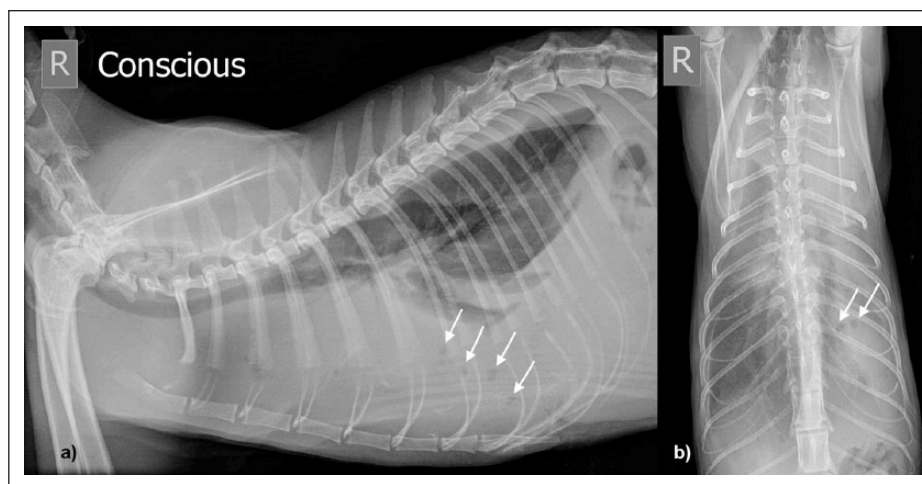


Figure 1 Right (a) lateral and (b) dorsoventral conscious radiographs of the thorax on admission showing bilateral pleural effusion, more marked in the left hemithorax. A few isolated gas bubbles in the left hemithorax were identified (arrows)

especially in the left hemithorax. The remainder of the physical examination was normal, including temperature (38.9°C) and body condition score (2/5; 3.2 kg).

Abnormalities on haematological and serum biochemical analysis performed at our hospital were confined to a neutrophilia with a left shift (neutrophils $22.7 \times 10^9/l$, reference interval [RI] $5.5\text{--}19.5 \times 10^9/l$; band neutrophils $4.54 \times 10^9/l$, RI $2.5\text{--}12.5 \times 10^9/l$) and mild hypoproteinaemia (49 g/l; RI 54–78 g/l). Thoracic radiography showed bilateral pleural effusion, which was more marked on the left, and a small number of isolated gas bubbles in the left hemithorax (Figure 1). Thoracostomy tubes (12 Fr G; Portex, Smiths Medical International) were placed bilaterally with the Seldinger technique and the pleural effusion drained. The cytological analysis of the fluid was compatible with septic inflammation, confirming the diagnosis of pyothorax (Table 1). *Actinobacillus ureae* was cultured.

Following drainage of the pleural effusion, intravenous fluid therapy (IVFT) was initiated with Hartmann's solution (Aquapharm 11; Animalcare) at 4 ml/kg/h. Multimodal analgesia consisting of meloxicam (Metacam; Boehringer Ingelheim) 0.1 mg/kg subcutaneously continued orally (0.05 mg/kg PO q24h), methadone (0.2 mg/kg IV q6h [Comfortan; Dechra] and levobupivacaine (1mg/kg intrapleurally q8h [Chirocaine; AbbVie]) was initiated. Antibiotic therapy was instituted with metronidazole (10 mg/kg IV q12h [Metronidazole; Baxter Healthcare]) and cefuroxime sodium (20 mg/kg IV q8h [Zinacef; GSK]), prior to receiving the bacterial culture results. Once bacterial culture results became available, the antibiotic choice was confirmed to be suitable.

The thoracostomy tubes were drained every 4 h initially and flushed every 12 h with 40 ml (12.5 ml/kg) of saline in each side. The fluid was then re-aspirated after

2 mins in order to decrease the bacterial burden. Full fluid analysis, including cytology, was performed periodically in our in-house laboratory (Table 1).

Pain was assessed every 2 h, according to the Glasgow Feline Composite Measure Pain Scale and analgesic requirements were adjusted accordingly.

Respiratory rate and effort improved within 2 days of hospitalisation. Pleural fluid analysis over the first 12 days revealed reducing cellularity but persistent septic inflammation (Table 1). Thoracic radiographs were acquired on day 7 and day 10 following admission.

On day 7, thoracic radiographs were acquired as the patient improved clinically and only small volumes were drained from the thoracostomy tube. The thoracic imaging was performed in order to identify an underlying cause and any residual pleural effusion. No underlying cause was found. The pleural effusion was reduced but unresolved, and lucent areas superimposed over the left lung were still present. These areas were likely gas pockets, although a cavitory lesion such as an abscess with gas content could not be ruled out. Owing to this possibility and the lack of resolution of effusion, the left thoracostomy drain was repositioned. Correct positioning of this drain was confirmed with further thoracic radiography.

On day 10, thoracic radiographs were repeated to reassess the thorax and identify an underlying cause for the pyothorax. No underlying cause was identified on these radiographs. The left thoracic drain was in the subcutaneous tissues and no longer intrathoracic, while the right remained correctly positioned. The volume of pleural effusion from the left hemithorax had increased when compared with the volumes previously drained. The right drain was removed due to minimal production and the left drain was repositioned, confirming its correct location with further thoracic radiography. Thoracic

Table 1 Fluid analysis and cytological interpretation of the pleural effusion during hospitalisation

	Analysis		Cytological interpretation
Day 1	Fluid nucleated cell count	$265.7 \times 10^9/l$	Septic pyothorax
	Fluid red cell count	$0.09 \times 10^{12}/l$	
Day 4	Fluid nucleated cell count	$6.5 \times 10^9/l$	Persistent septic inflammation
	Fluid red cell count	$0.004 \times 10^{12}/l$	
	Fluid protein	19 g/l	
	Fluid albumin	7 g/l	
Day 6	Fluid nucleated cell count	$25.5 \times 10^9/l$	Persistent septic inflammation
	Fluid red cell count	$0.05 \times 10^{12}/l$	
	Fluid protein	19 g/l	
	Fluid albumin	7 g/l	
Day 10	Fluid nucleated cell count	$109.4 \times 10^9/l$	Severe septic inflammation
	Fluid red cell count	$0.04 \times 10^{12}/l$	
	Fluid protein	39 g/l	
	Fluid albumin	15 g/l	
Day 12	Fluid nucleated cell count	$85 \times 10^9/l$	Marked septic inflammation
	Fluid red cell count	$0.19 \times 10^{12}/l$	
	Fluid protein	36 g/l	
	Fluid albumin	12 g/l	
Day 16	Fluid nucleated cell count	$21 \times 10^9/l$	Significant reduction in inflammatory response with a lower nucleated cell count and no organisms observed
	Fluid red cell count	$0.05 \times 10^{12}/l$	
	Fluid protein	32 g/l	
	Fluid albumin	12 g/l	
Day 19	Fluid nucleated cell count	$15.3 \times 10^9/l$	Count improvement in the nucleated cell count although there is still evidence of neutrophilic inflammation
	Fluid red cell count	$0.03 \times 10^{12}/l$	
	Fluid protein	32 g/l	
	Fluid albumin	15 g/l	

ultrasound was performed, which revealed evidence of persistent pleural free fluid, mainly in the left hemithorax, suggesting further pockets of infection or abscessation. Fluid analysis confirmed worsening septic inflammation (Table 1).

Given the deterioration of the infection after 12 days of antibiotic therapy, drainage and lavage, the patient underwent exploratory thoracotomy in the light of the persistent infection as assessed by cytology.

Anaesthesia protocol

The patient was premedicated with dexmedetomidine hydrochloride (Dexdomitor; Orion Pharma) 5 µg/kg and methadone (0.2 mg/kg IV). General anaesthesia was induced with alfaxalone (3 mg/kg IV [Alfaxan; Jurox]) and maintained with total IV anaesthesia with alfaxalone 7 mg/kg/h. After endotracheal intubation, oxygen was supplemented and lungs were mechanically ventilated using a volume-controlled mode. Intraoperative monitoring included electrocardiogram, pulse oximetry, capnography, spirometry, oesophageal temperature, and oscillometric and invasive arterial blood pressures. Intraoperative analgesia consisted of 1 mg/kg IV ketamine boluses (Anaestamine; Animalcare) and 10 µg/kg/h remifentanyl hydrochloride (Ultiva;

Aspen Pharma) infusion. Hartmann's solution was administered intraoperatively at a rate of 5 ml/kg/h. Metronidazole and cefuroxime sodium were continued as previously prescribed with no additional antibiotics given.

Surgical technique

A standard median sternotomy was performed with an oscillating saw to osteotomise the sternum and allow access to both hemithoraces.

Surgical exploration identified thickened, fibrotic mediastinum covered with purulent material. The mediastinum was debrided and areas of encapsulated abscesses were found in the thoracic cavity and, of particular concern, an abscess involving the right cranial lung lobe and heart base (Figure 2).

The right cranial lobe was atelectatic and the right caudal lung lobe was covered by non-restrictive fibrinous adhesions. The left lung lobes were replaced by a thick cord of fibrotic tissue. Lung recruitment manoeuvres were performed manually, achieving only a small degree of inflation of the right caudal and accessory lobes (Figure 2). During debridement of the right caudal lobe, air leakage was detected from the parenchymal surface, due to an 8 mm pulmonary laceration on the

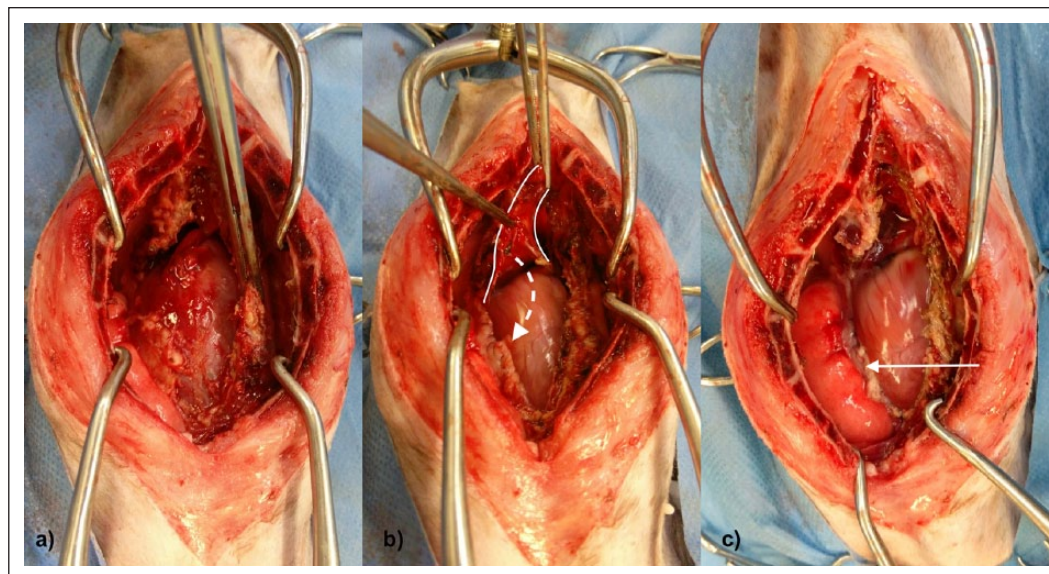


Figure 2 Intraoperative views of the thorax: (a) pre-debridement, DeBakey forceps holding fibrinous adhesions; (b) harvesting the pericardial flap during subtotal pericardiectomy, DeBakey forceps holding the pericardial flap that was moved towards the laceration (dotted arrow); (c) post-debridement with pericardial flap in place (solid arrow) during lung recruitment manoeuvres where the only visibly functional lung lobe was the right caudal one

ventromedial aspect of this lung lobe. There was no evidence of acute or historical haemorrhage associated with the laceration.

A subtotal pericardiectomy was performed. Part of the pericardium was excised and a 2 cm × 2 cm pericardial flap was raised from the pericardium adjacent to the laceration. The pericardium used for this flap was overlying the heart's apex and part of the right ventricle. The base of the flap was overlying the right ventricle. During this procedure a minimal amount of purulent pericardial effusion was drained. Tissue samples of pericardium and mediastinum were submitted for bacterial culture.

The pericardial flap was reflected caudolaterally and apposed over the laceration of the cranial part of the right caudal lung lobe. The free edge of the patch was then sutured with 4/0 polydioxanone (PDS II; Ethicon) in a simple continuous pattern to a rim of fibrinous adhesion that was partially covering this lobe. Further debridement of the adhesions was not possible without causing further severe parenchymal lacerations.

Prior to closure, the chest was lavaged with 300 ml/kg of warmed sterile saline (Aquapharm 1; Animalcare) and checked for air leakage. A thoracostomy tube was placed in the right side, and the previously placed left-sided tube was maintained.

The thoracic cavity was closed routinely with 2/0 polydioxanone placed in a figure-of-eight pattern for apposition of the sternbrae and 3/0 polyglecaprone 25 (Monocryl; Ethicon) simple continuous closure for the subcutaneous and intradermal layers.

Postoperative care

The cat was hospitalised in our intensive care unit for the first 48 h postoperatively and oxygen supplemented in an oxygen cage for the first 16 h. The cat was mildly tachycardic and tachypnoeic, but no dyspnoea was observed in the immediate postoperative period. Thoracostomy tubes were drained every 2 h.

Postoperative medication consisted of meloxicam (0.05 mg/kg q24h PO), levobupivacaine (1 mg/kg intrapleurally q4h), methadone (0.2 mg/kg IV q6h), cephalexin (20 mg/kg PO q12h; Therios; SOGEVAL), metronidazole (20 mg/kg PO q12h; Metronidazole, Zentiva) and marbofloxacin (2 mg/kg PO q24h; Marbocyl; Vétoquinol). IVFT was continued with Hartmann's solution (4 ml/kg/h). Pain assessment was continued as preoperatively and analgesia was titrated accordingly.

The left-sided thoracostomy tube was removed after 9 h owing to minimal fluid production. The right-sided tube was removed after 7 days and the tip sent for bacterial culture.

During the postoperative period of hospitalisation, tachycardia and tachypnoea improved and no episodes of pyrexia were recorded. Samples of the pleural effusion were sent for cytological analysis periodically, showing resolving neutrophilic inflammation with no bacteria. The bacterium isolated from the surgical tissue sample was *Staphylococcus epidermidis*, and was sensitive to cephalexin and marbofloxacin. Metronidazole was discontinued when the second culture and sensitivity results were available.

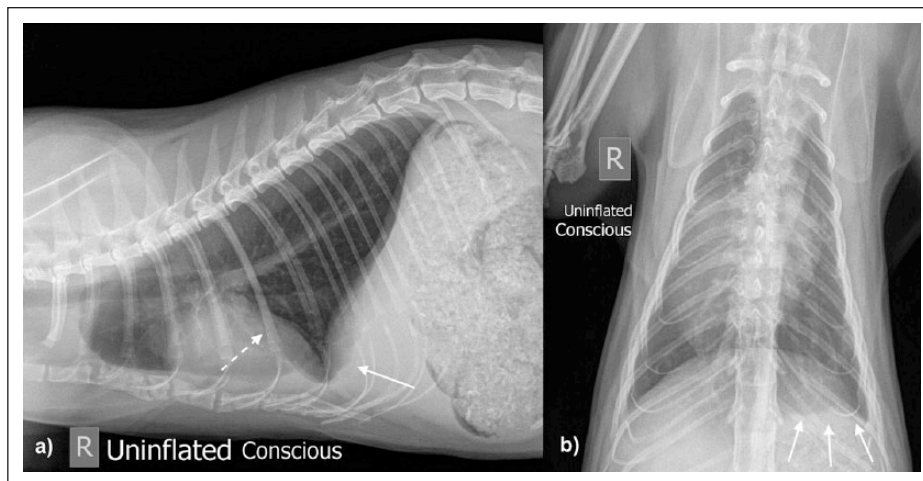


Figure 3 Right (a) lateral and (b) dorsoventral conscious radiographs of the thorax 19 weeks postoperatively showing good bilateral aeration of the pulmonary parenchyma with mild retraction of the sternum. The caudoventral border of the left caudal lung lobe shows a mildly undulating margin (solid arrow) and there are pleural fissure lines (dotted arrow) between the right cranial and middle lung lobes

The cat was discharged 8 days postoperatively. Marbofloxacin and cephalexin were continued for 3 weeks after discharge.

Thirteen weeks postoperatively, the cat was presented to the referring vet with a 24 h history of lethargy. No increase in respiratory rate or effort was detected on initial examination, but pyrexia (40.2°C) was detected. This episode was treated with amoxicillin/clavulanic acid (20 mg/kg PO q12h) and metronidazole (20 mg/kg PO q12h) for 7 days and resolved with no complications.

The cat was re-examined 19 weeks postoperatively and had received no treatment for the previous 5 weeks. The owner reported good progress since the time of surgery, no dyspnoea, an active demeanour and good appetite. The patient tolerated normal levels of activity with no episodes of dyspnoea. Only occasional episodes of a dry, non-productive cough were noted once every couple of days, which were triggered when the animal was in dusty environments. On thoracic auscultation, mild, muffled lung sounds were noted in the left hemithorax. The rest of the physical examination was unremarkable, including temperature, respiratory rate and effort.

Survey radiographs obtained at this point revealed good bilateral aeration of the pulmonary parenchyma. The caudoventral border of the left caudal lung lobe demonstrated a mildly undulating margin on the right lateral projection and mild retraction on the dorsoventral projection. These changes were interpreted as focal areas of lack of full expansion of the lung. In addition, there were pleural fissure lines between the right cranial and middle lung lobes, likely secondary to fibrosis from the previous confirmed pyothorax. No pleural effusion

was noted (Figure 3). Owner instructions at this stage consisted of continuing normal activity and monitoring the cough. In case of deterioration or persistence of the cough, it was advised to re-examine the patient and discuss further diagnostic options.

Thirty-eight weeks postoperatively, the owner still reported an occasional cough, less evident during cold weather. No episodes of dyspnoea were reported and exercise tolerance was still good with some periods of tachypnoea for less than 1 min after high levels of activity. No more episodes of lethargy or pyrexia were described.

Discussion

The cat reported here made a good clinical recovery following surgery. It is possible that this good clinical outcome was due to a progressive lung recruitment of the left atelectatic side. The progressive improvement in exercise tolerance could be also explained by a hyperplastic response that would increase alveolar components.⁶ More objective measurements, such as arterial blood gas analysis, would be needed to demonstrate improvement in ventilation.

The origin of the laceration in this cat is uncertain. One possible option is an iatrogenic laceration was created, either partially or completely, during debridement of the fibrinous adhesions from the surface of the lung. Further, debridement of the adhesions may have exposed a previously sealed laceration in the pulmonary parenchyma. The lack of bruising or bleeding in the laceration site may suggest a chronic lesion. Iatrogenic laceration during the placement of the thoracostomy tubes is considered less likely. While iatrogenic laceration is a complication reported in trocar-type drains,⁷ this has not

been well recognised in small-bore, wire-guided chest drains using the Seldinger technique as were used in this case.⁸ This, together with the absence of pneumothorax during the first 12 days, makes the hypothesis of iatrogenic laceration due to the thoracostomy tube in this cat unlikely. Migration of a foreign body from the lung to the pleural space is another differential and could also explain the concurrent pyothorax. Although at exploratory sternotomy no foreign body was identified it cannot be ruled out, as the underlying cause of pyothorax can only be identified in 46–67% of cats.^{1–3}

Total IV anaesthesia was performed owing to the possibility of collapsed lung lobes and resulting poor ventilation. The depth of anaesthesia does not depend on ventilation when using total IV anaesthesia, therefore maintaining a more stable anaesthetic depth throughout the procedure as opposed to inhalational anaesthesia.

Surgical management may have been warranted, and was suggested, before day 12; however, the owner preferred to continue medical management. At surgery, it was found that the entirety of the left lung, which represents 42% of lung mass,⁹ was affected. Part of the right lung was also affected, resulting in approximately 75% of non-functional lung parenchyma. Lobectomy of the abscessated right cranial lung lobe could have been considered as part of the surgical treatment. Dogs can tolerate a 50% loss of the total lung volume but not a 75% resection.¹⁰ The amount able to be safely resected is not as well-defined in cats, as such, the authors elected to open and debride the abscess, in an attempt to conserve as much functional parenchyma as possible. However, right pneumonectomy has been reported in dogs and cats and shows that survival is possible in cases where chronic disease allows adaptation prior to pneumonectomy.^{11,12}

Surgical treatment for pulmonary laceration involves closing the site with a mattress pattern of absorbable suture or partial lung lobectomy.¹³ In this case, a lung lobectomy was not performed, as it would have involved excising the only major lobe with adequate ventilation. It was essential to preserve this lobe for the patient's survival. Direct appositional suturing was considered to repair this laceration, but the friability of the tissue was a concern; there was a high chance of causing additional tears while attempting suturing it.

However, as the infectious process affected most of the pulmonary parenchyma, the authors opted to open and debride this abscess, in an attempt to conserve as much parenchyma as possible.

Autologous and heterologous pericardium has been used in human medicine for a number of different applications, including cardiovascular procedures,^{14–16} abdominal herniorrhaphy,¹⁷ cholangioplasty,¹⁸ meningo-myelocoele closure,¹⁹ treatment for corneal perforation²⁰

or tracheal reconstruction.²¹ In veterinary medicine, pericardium has previously been used in cardiovascular surgery,^{22–26} oesophageal patching, diaphragmatic herniorrhaphy²⁷ and closure of large defects.^{28,29} The use of pericardium in the form of a flap for a lung laceration is a novel use.

Owing to the tissue characteristics of pericardium, which include durability, strength, reliable consistency and biocompatibility,³⁰ heterologous pericardium has been used in human medicine to reduce air leakage, secondary to tearing of the lung by surgical staples.³¹ Although this use was reported in emphysematous lungs and this was not the case in this cat, this reference demonstrates the pericardium's ability to reduce air leakage. We opted to use pericardium sutured securely to fibrinous tissue adhered to the lung lobe to seal the laceration and preserve the lobe. Polytetrafluoroethylene has been described in veterinary literature as an alternative to a pericardial patch,^{32–34} and could have been applied in this case. Acellular dermal matrix,³⁵ canine fascia lata³⁶ and porcine small animal intestinal submucosa³⁶ are other alternatives that could have been used in this case. However, the immediate availability and non-economic impact of the pericardium make it a very interesting option.

The pericardium is supplied by paired pericardial branches of the internal thoracic arteries, which course caudoventrally across the ventrolateral aspect of the pericardium. The pericardiophrenic arteries, which also arise from the internal thoracic arteries, course with the phrenic nerves and supply the dorsolateral aspects of the pericardium.³⁷ This blood supply should be preserved for survival of the flap. A viable blood supply may not be essential for its use, however, as autologous pericardial patch has been described previously.^{22–26} Although in this case the pericardial flap reached the desired location, in cases where this is not possible it may be warranted to use a pericardial patch; however, this hypothesis requires further study.

A small volume of pericardial effusion was identified during the harvesting of the pericardial flap. This pericardial effusion was not identified in previous diagnostic imaging or during the exploratory thoracotomy and was only noted when the pericardium was incised; this was attributed to the minimal volume of fluid present. Bacterial infections are uncommon causes of pericardial effusion, and most cases arise from intrapericardial foreign body penetration.³⁸ A foreign body was not identified during surgery; however, this aetiology could not be completely ruled out.

Initial antimicrobial therapy in pyothorax is empiric until culture and sensitivity results are available.³⁹ *Pasteurella* species are the most common bacteria isolated from feline pyothorax, accounting for 63% of cases.⁴⁰ *Pasteurella* species are susceptible to penicillin and its

derivatives, as well as to fluoroquinolones and aminoglycosides.³⁹ In the case presented here, a fluoroquinolone – marbofloxacin – was added postoperatively and before the culture results were received. This decision was based on the lack of clinical improvement achieved by the antibiotics selected preoperatively. The authors opted for a broader spectrum that was confirmed later by the culture results.

This case report is limited by its retrospective nature. At 3 weeks, re-examination was advised at discharge. Owing to economic concerns and marked clinical improvement, the owner felt it unnecessary to have the cat re-examined at that point. The patient was re-examined at 19 weeks postoperatively, but the cause of the persistent cough present at follow-up was not investigated further owing to the owner's decision and financial concerns. The lack of serial clinical re-evaluations following discharge and the non-investigation of the occasional cough due to the owner's reluctance are the most relevant limitations.

Conclusions

The use of a pericardial flap has shown encouraging results for the treatment of a pulmonary tear in this case where lung lobectomy was contraindicated. It could be considered an alternative surgical option to lung lobectomy or direct repair of the laceration. However, further studies with a larger caseload are required to fully endorse this technique.

Conflict of interest The authors declared no potential conflicts of interest with respect to the research, authorship, and/or publication of this article.

Funding The authors received no financial support for the research, authorship, and/or publication of this article.

ORCID iD Pablo Pérez López  <https://orcid.org/0000-0003-0343-9134>

References

- 1 Waddell LS, Brady CA and Drobatz KJ. **Risk factors, prognostic indicators, and outcome of pyothorax in cats: 80 cases (1986–1999).** *J Am Vet Med Assoc* 2002; 221: 819–824.
- 2 Davies C and Forrester SD. **Pleural effusion in cats: 82 cases (1987 to 1995).** *J Small Anim Pract* 1996; 37: 217–224.
- 3 Barrs VR, Allan GS, Martin P, et al. **Feline pyothorax: a retrospective study of 27 cases in Australia.** *J Feline Med Surg* 2005; 7: 211–222.
- 4 DeBerry JD, Norris CR, Samii VF, et al. **Correlation between fine-needle aspiration cytopathology and histopathology of the lung in dogs and cats.** *J Am Anim Hosp Assoc* 2002; 38: 327–336.
- 5 Spackman CJ and Caywood DD. **Management of thoracic trauma and chest wall reconstruction.** *Vet Clin North Am Sm Anim Pract* 1987; 17: 431–447.
- 6 Rannels DE and Rannels SR. **Compensatory growth of the lung following partial pneumonectomy.** *Exp Lung Res* 1988; 14: 157–182.
- 7 Dugdale A. **Chest drains and drainage techniques.** *In Pract* 2000; 22: 2–15.
- 8 Valtolina C and Adamantos S. **Evaluation of small-bore wire-guided chest drains for management of pleural space disease.** *J Small Anim Pract* 2009; 50: 290–297.
- 9 Liptak JM, Monnet E, Dernell WS, et al. **Pneumonectomy: four case studies and a comparative review.** *J Small Anim Pract* 2004; 45: 441–447.
- 10 Brugarolas A and Takita H. **Regeneration of the lung in the dog.** *J Thorac Cardiovasc Surg* 1973; 65: 187–190.
- 11 Wavreille V, Boston SE, Souza C, et al. **Outcome after pneumonectomy in 17 dogs and 10 cats: a veterinary society of surgical oncology case series.** *Vet Surg* 2016; 45: 782–789.
- 12 Majeski SA, Steffey MA, Mayhew PD, et al. **Postoperative respiratory function and survival after pneumonectomy in dogs and cats.** *Vet Surg* 2016; 45: 775–781.
- 13 Tobias KM and Johnston SA. **Lungs.** In: Tobias KM and Johnston SA (eds). *Veterinary surgery: small animal.* St Louis, MO: Elsevier, 2012, pp 1752–1768.
- 14 Latremouille CP, Vincentelli A, Zegdi R, et al. **Autologous pericardial patch harvesting site for cardiac valve repair: anatomic and morphometric considerations.** *J Heart Valve Dis* 1998; 7: 19–23.
- 15 Grimsley BR, Wells JK, Pearl GJ, et al. **Bovine pericardial patch angioplasty in carotid endarterectomy.** *Am Surg* 2001; 67: 890–895.
- 16 Us MH, Sungun M, Sanioglu S, et al. **A retrospective comparison of bovine pericardium and polytetrafluoroethylene patch for closure of ventricular septal defects.** *J Int Med Res* 2004; 32: 218–221.
- 17 Szerafin T, Leny A, Palotas L, et al. **Abdominal hernia repair with no-react treated bovine pericardial patch.** *Magy Seb* 2008; 61: 61–65.
- 18 Wang Y, Xu YD and Li JS. **Cholangioplasty by using a patch of bovine pericardium in treatment of stricture of extrahepatic bile duct.** *Zhonghua Wai Ke Za Zhi* 1994; 32: 269–270.
- 19 Güner B, Kertmen H, Akturk UD, et al. **Use of the bovine pericardial patch and fibrin sealant in meningomyelocele closure.** *Acta Neurochir* 2014; 156: 1345–1350.
- 20 Khanna RK and Mokhtar E. **Bovine pericardium in treating large corneal perforation secondary to alkali injury: a case report.** *Indian J Ophthalmol* 2008; 56: 429–430.
- 21 Barbetakis N, Samanidis G, Paliouras D, et al. **Intraoperative tracheal reconstruction with bovine pericardial patch following iatrogenic rupture.** *Patient Saf Surg* 2008; 2: 4. DOI: 10.1186/1754-9493-2-4.
- 22 Li W, Xu K, Ni Y, et al. **A canine model of proximal descending thoracic aortic aneurysm created with an autologous pericardial patch.** *Ann Thorac Cardiovasc Surg* 2013; 19: 131–135.
- 23 Monnet E, Orton EC, Gaynor J, et al. **Diagnosis and surgical repair of partial atrioventricular septal defects in two dogs.** *J Am Vet Med Assoc* 1997; 211: 569–572.
- 24 Tanaka R, Shimizu M, Hoshi K, et al. **Efficacy of open patch-grafting under cardiopulmonary bypass for pulmonary stenosis in small dogs.** *Aust Vet J* 2009; 87: 88–93.

- 25 Hunt GB, Pearson MRB, Bellenger CR, et al. **Use of a modified open patch-graft technique and valvectomy for correction of severe pulmonic stenosis in dogs: eight consecutive cases.** *Aust Vet J* 1993; 70: 244–248.
- 26 Brockman DJ, Borer KE, Baines SJ, et al. **Partial right ventriculectomy using the incised patch technique to treat double chambered right ventricle and chylothorax in a cat.** *Vet Surg* 2009; 38: 631–635.
- 27 Bjorling DE and Keene BW. **Canine pericardial disease.** *Comp Anim Pract* 1989; 19: 9–15.
- 28 Badylak S, Kokini K, Tullius B, et al. **Morphologic study of small intestinal submucosa as a body wall repair device.** *J Surg Res* 2002; 103: 190–202.
- 29 Bellows CF, Alder A and Helton WS. **Abdominal wall reconstruction using biological tissue grafts: present status and future opportunities.** *Expert Rev Med Devices* 2006; 3: 657–675.
- 30 Li X, Guo Y, Ziegler KR, et al. **Current usage and future directions for the bovine pericardial patch.** *Ann Vasc Surg* 2011; 25: 561–568.
- 31 Cooper JD. **Technique to reduce air leaks after resection of emphysematous lung.** *Ann Thorac Surg* 1994; 57: 1038–1039.
- 32 Uechi M, Harada K, Mizukoshi T, et al. **Surgical closure of an atrial septal defect using cardiopulmonary bypass in a cat.** *Vet Surg* 2011; 40: 413–417.
- 33 Yamano S, Uechi M, Tanaka K, et al. **Surgical repair of a complete endocardial cushion defect in a dog.** *Vet Surg* 2011; 40: 408–412.
- 34 Orton EC, Mama K, Hellyer P, et al. **Open surgical repair of tetralogy of Fallot in dogs.** *J Am Vet Med Assoc* 2001; 219: 1089–1093.
- 35 An G, Walter RJ and Nagy K. **Closure of abdominal wall defects using acellular dermal matrix.** *J Trauma* 2004; 56: 1266–1275.
- 36 Arnold GA, Mathews KG, Roe S, et al. **Biomechanical comparison of four soft tissue replacement materials: an in vitro evaluation of single and multilaminar porcine small intestinal submucosa, canine fascia lata, and polypropylene mesh.** *Vet Surg* 2009; 38: 834–844.
- 37 Evans HE and de Lahunta A. **Heart and arteries.** In: Evans HE and de Lahunta A (eds). *Miller's anatomy of the dog*. 4th ed. St Louis, MO: Elsevier, 2013, pp 428–504.
- 38 Aronson AR and Gregory CR. **Infectious pericardial effusion in five dogs.** *Vet Surg* 1995; 24: 402–407.
- 39 Barrs VR and Beatty JA. **Feline pyothorax – new insights into an old problem: part 2. Treatment recommendations and prophylaxis.** *Vet J* 2009; 179: 171–178.
- 40 Demetriou JL, Foale RD, Ladlow J, et al. **Canine and feline pyothorax: a retrospective study of 50 cases in the UK and Ireland.** *J Small Anim Pract* 2002; 43: 388–394.