



## **Fatal pulmonary hemorrhage associated with vascular amyloid deposition in a cat**

Authors: Mawby, Dianne I, Whittemore, Jacqueline C, and Donnell, Robert L

Source: Journal of Feline Medicine and Surgery Open Reports, 4(2)

Published By: SAGE Publishing

URL: <https://doi.org/10.1177/2055116918817993>

---

BioOne Complete ([complete.BioOne.org](https://complete.BioOne.org)) is a full-text database of 200 subscribed and open-access titles in the biological, ecological, and environmental sciences published by nonprofit societies, associations, museums, institutions, and presses.

Your use of this PDF, the BioOne Complete website, and all posted and associated content indicates your acceptance of BioOne's Terms of Use, available at [www.bioone.org/terms-of-use](https://www.bioone.org/terms-of-use).

Usage of BioOne Complete content is strictly limited to personal, educational, and non - commercial use. Commercial inquiries or rights and permissions requests should be directed to the individual publisher as copyright holder.

---

BioOne sees sustainable scholarly publishing as an inherently collaborative enterprise connecting authors, nonprofit publishers, academic institutions, research libraries, and research funders in the common goal of maximizing access to critical research.



# Fatal pulmonary hemorrhage associated with vascular amyloid deposition in a cat

Dianne I Mawby<sup>1</sup> , Jacqueline C Whittemore<sup>1</sup> and Robert L Donnell<sup>2</sup>

*Journal of Feline Medicine and Surgery Open Reports*  
1–7

© The Author(s) 2018

Article reuse guidelines:

sagepub.com/journals-permissions

DOI: 10.1177/2055116918817993

journals.sagepub.com/home/jfmsopenreports

This paper was handled and processed by the American Editorial Office (AAFP) for publication in *JFMS Open Reports*



## Abstract

**Case summary** An adult female spayed Siamese-cross cat of unknown age was presented for bilateral hemorrhagic otorrhea. Nasopharyngeal polyps were diagnosed by CT and biopsy; bilateral ventral bulla osteotomies were performed. Episodic epistaxis, otic hemorrhage and hemoptysis with respiratory distress progressed over 18 months. Systolic blood pressure, complete blood count, plasma biochemistries, prothrombin time, partial thromboplastin time and coagulation factor 12, 9 and 8 activities were normal. Serial thoracic radiographs revealed patchy interstitial to alveolar patterns. Airway hemorrhage prevented diagnostic bronchoscopy. Respiratory hemorrhage was ultimately fatal. Amyloid deposition was identified in pulmonary vasculature, bronchial wall, lymphoid tissues, nasal-pharyngeal tissue and tympanic bullae based on microscopic examination and confirmed by Congo red staining with green birefringence under polarized light.

**Relevance and novel information** Amyloidosis should be considered as a differential diagnosis in cats with spontaneous hemorrhage of the respiratory or otic tracts. Although systemic amyloidosis is associated with a grave prognosis, this case suggests that prolonged survival is possible after the initial onset of signs in cats with pulmonary amyloidosis.

**Keywords:** Serum amyloid A; hemoptysis; otorrhea; epistaxis; nasopharyngeal polyps; otic hemorrhage

**Accepted:** 15 November 2018

## Case description

An adult female spayed indoor-only Siamese-cross cat of unknown age was presented for hemorrhagic otorrhea (time 0). The cat had been adopted from an animal shelter as an adult 4 years prior; at which time complete blood count, biochemistry panel, urinalysis and feline leukemia virus/feline immunodeficiency virus testing were unremarkable. Four months after adoption, the cat developed yeast otitis externa of the left ear. Although otitis resolved with treatment (topical clotrimazole/dexamethasone solution q12h for 14 days), head shaking progressed and was accompanied by mild serous nasal and ocular discharge. ACT scan of the ears and video otoscopy were performed, which were unremarkable, and untargeted nasal biopsies revealed mild lymphocytic and histiocytic rhinitis. Clinical signs resolved without treatment.

Diagnostics performed and therapeutics implemented after re-presentation (time 0) are summarized in Table 1. Briefly, evaluation revealed spontaneous bilateral hemorrhagic otorrhea, fluid-filled bullae, bilateral ruptured tympanic membranes and a mass in the left aural canal. The mass was removed using manual traction and diagnosed as a nasopharyngeal polyp based

<sup>1</sup>Department of Small Animal Clinical Sciences, University of Tennessee College of Veterinary Medicine, Knoxville, TN, USA

<sup>2</sup>Department of Biomedical Diagnostic Services, University of Tennessee College of Veterinary Medicine, Knoxville, TN, USA

### Corresponding author:

Dianne I Mawby DVM, MVSc, DACVIM, Departments of Small Animal Clinical Sciences, University of Tennessee College of Veterinary Medicine, C247 Veterinary Teaching Hospital, 2407 River Dr, Knoxville, TN 37996-4544, USA  
Email: dmawby@utk.edu



Creative Commons Non Commercial CC BY-NC: This article is distributed under the terms of the Creative Commons

Attribution-NonCommercial 4.0 License (<http://www.creativecommons.org/licenses/by-nc/4.0/>) which permits non-commercial use, reproduction and distribution of the work without further permission provided the original work is attributed as specified on the SAGE and Open Access pages (<https://us.sagepub.com/en-us/nam/open-access-at-sage>).

**Table 1** Chronological summary of clinical signs, physical examination abnormalities, diagnostic findings and treatments in a cat with progressive spontaneous episodic hemorrhage of the respiratory and otic tracts

Time point	Presenting complaints and abnormalities on examination	Diagnostics performed	Abnormalities on diagnostic evaluation	Treatment
0	Bilateral hemorrhagic otorrhea	CBC*, plasma biochemistry panel†, PT‡, PTT‡, CT scan Mass removal by manual traction Nasal biopsies with histopathology	Ruptured tympanic membranes Nasopharyngeal polyp in the left ear	Prednisone (5 mg PO q24h for 7 days then q48h for 7 days) Topical flucinolone with dimethyl sulfoxide and topical silver sulfadiazine for both ears
1 month	Bilateral hemorrhagic otorrhea	Histopathology	Bilateral nasopharyngeal polyps	Bilateral ventral bulla osteotomies
6 months	Intermittent epistaxis Gingival recession Stage 1 periodontal disease	BP§ 170–180 mmHg (with acclimation decreased to 140–150 mmHg) Ophthalmic/fundic examination CBC, plasma biochemistry panel PT, PTT Dental radiographs Otic and oral exams under general anesthesia	Blood noted on endotracheal tube upon extubation	Dental cleaning
8 months	Intermittent hemoptysis and epistaxis	BP 150 mmHg Thoracic radiographs Coagulation factor 8, 9 and 12 analysis	Interstitial infiltrate in caudoventral aspect of left cranial lung lobe Ill-defined nodule in right caudal lung lobe	None
8.5 months	Intermittent hemoptysis and epistaxis	Thoracic radiographs CBC, plasma biochemistry panel Blastomyces urine antigen quantitation	Interstitial infiltrate unchanged in left cranial lung lobe Nodule in right caudal lung lobe more defined and another soft tissue opacity in same lung lobe	Itraconazole (10 mg/kg PO q24h) for 2 weeks
9.5 months	Intermittent hemoptysis and epistaxis Grand mal seizure	Thoracic radiographs MRI of head CSF tap for cytology Video otoscopy Bronchoscopy	Mild interstitial pattern in right caudal lung lobe Interstitial pattern in caudal subsegment of left cranial lobe Right tympanic bulla and ear canal filled with suspected hemorrhage Bulging tympanic membrane in the right ear Tracheal hemorrhage	Myringotomy with removal of blood clot in the right ear Tobramycin otic drops for both ears
10–18 months	Intermittent hemoptysis with respiratory distress			Prednisolone (5 mg PO q24h) Enrofloxacin (5 mg/kg PO q24h for 10 days) Phenoxybenzamine (2.5 mg PO q12h)

(continued)

**Table 1** (Continued)

Time point	Presenting complaints and abnormalities on examination	Diagnostics performed	Abnormalities on diagnostic evaluation	Treatment
18 months	Intermittent hemoptysis with respiratory distress	BP 130 mmHg Sedation (butorphanol [0.4 mg/kg] and dexmedetomidine [2 µg/kg IV]) Thoracic radiographs Limited abdominal ultrasound CBC, plasma biochemistry panel <i>Toxoplasma</i> IgG and IgM antibody titers	Multifocal, coalescing, structured, interstitial and alveolar lung patterns. Pleural effusion Small adrenal glands Non-regenerative normocytic normochromic anemia (hematocrit 34%) <i>Toxoplasma</i> -positive IgG titer (≥8192) and negative IgM titer (<512)	
18.3 months	Acute hemoptysis and severe respiratory distress	Necropsy	Severe chronic-active widespread multifocal lymphoplasmacytic, suppurative and hemorrhagic broncho-interstitial pneumonia with bronchiectasis, and extensive fibrosis. No infectious organisms seen on routine or gram special staining Amyloidosis type AA involving the pulmonary vessels, bronchi, bronchioles, retropharyngeal lymph node and tympanic bullae	Terbutaline (0.01 mg/kg SC) Butorphanol (0.2 mg/kg SC)

\*ADVIA 2120i (Siemens Medical Solutions USA)

†Cobas c 501 analyzer (Hoffman-LaRoche)

‡STA Compact, Diagnostica Stago

§Indirect systolic blood pressure (BP) taken using the Doppler flow method

CBC = complete blood count; PT = prothrombin time; PTT = partial thromboplastin time; CSF = cerebrospinal fluid

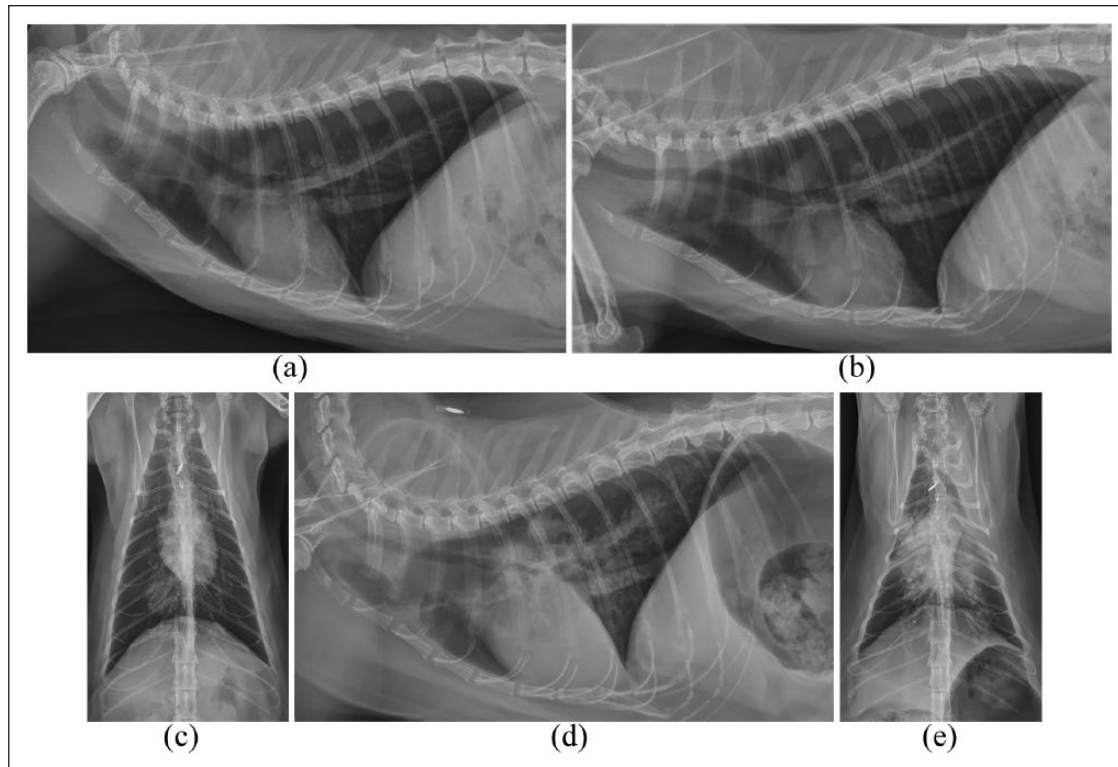
on anatomic location, gross appearance and histologic changes. Intermittent bilateral hemorrhagic otorrhea persisted over the next month in spite of medical therapy. Sedation and/or analgesia was administered as appropriate for all described diagnostic and therapeutic procedures. Bilateral ventral bulla osteotomies were performed to remove bilateral nasopharyngeal polyps. Episodic hemorrhagic otorrhea continued.

Five months postoperatively, unilateral epistaxis of unknown cause occurred during physical examination for dental prophylaxis. An etiology was not identified on diagnostic testing, although primary hemostasis was not evaluated. Dental prophylaxis was uneventful, but blood was noted on the endotracheal tube upon extubation.

Hemoptysis developed 2 months later, which increased in frequency over the next 6 weeks. Diagnostic findings included multifocal shifting infiltrates and nodular change on radiographs (Figure 1).

Neurologic evaluation, including MRI and cerebrospinal fluid analysis, was performed owing to a grand mal seizure 6 weeks after the onset of hemoptysis. The right tympanic bulla and ear canal were filled with heterogeneously hyperintense material on T2-weighted sequences consistent with hemorrhage. A large blood clot was removed via myringotomy. Bronchoscopy was attempted, but extensive hemorrhage in the trachea precluded visualization. Given the patient's instability and our inability to visualize the tracheal lumen due to hemorrhage, bronchoalveolar lavage was not attempted. Recovery from anesthesia was complicated by hypoxemia and repeated obstruction of the endotracheal tube with blood. The cat was discharged the following day.

Over the next 9 months, hemoptysis recurred with increasing frequency and severity, although the cat was clinically normal between episodes. Empiric treatment trials had no apparent effect on clinical signs (Table 1).

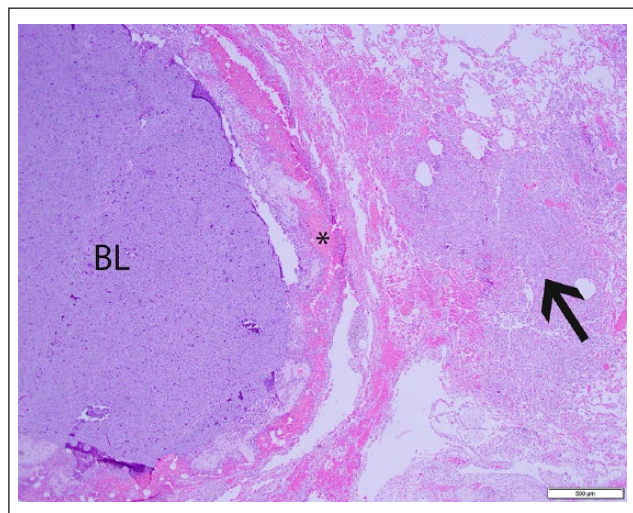


**Figure 1** Multifocal shifting infiltrates and nodular change on thoracic radiographs taken at 8.5 months ([a] right lateral view, [b] left lateral view, [c] ventral/dorsal view) and 18 months ([d] right lateral view, [e] ventral/dorsal view) in a cat with episodic spontaneous hemoptysis.

Re-evaluation at the hospital resulted in epistaxis, respiratory distress and temporary oxygen dependency. Ten days later, the cat was presented for acute hemoptysis with severe respiratory distress and died 5 h after placement in an oxygen cage.

At necropsy, there was hemorrhagic discharge from the nares and free blood within the nasal passages. Lung lobes had multifocal-to-extensive reddening with palpable firmness, particularly in the hilar region. The bronchi were filled with yellow-to-green mucoid material. Unfortunately, only grossly abnormal organs (respiratory system, retropharyngeal lymph nodes, liver and adrenal glands) were evaluated microscopically.

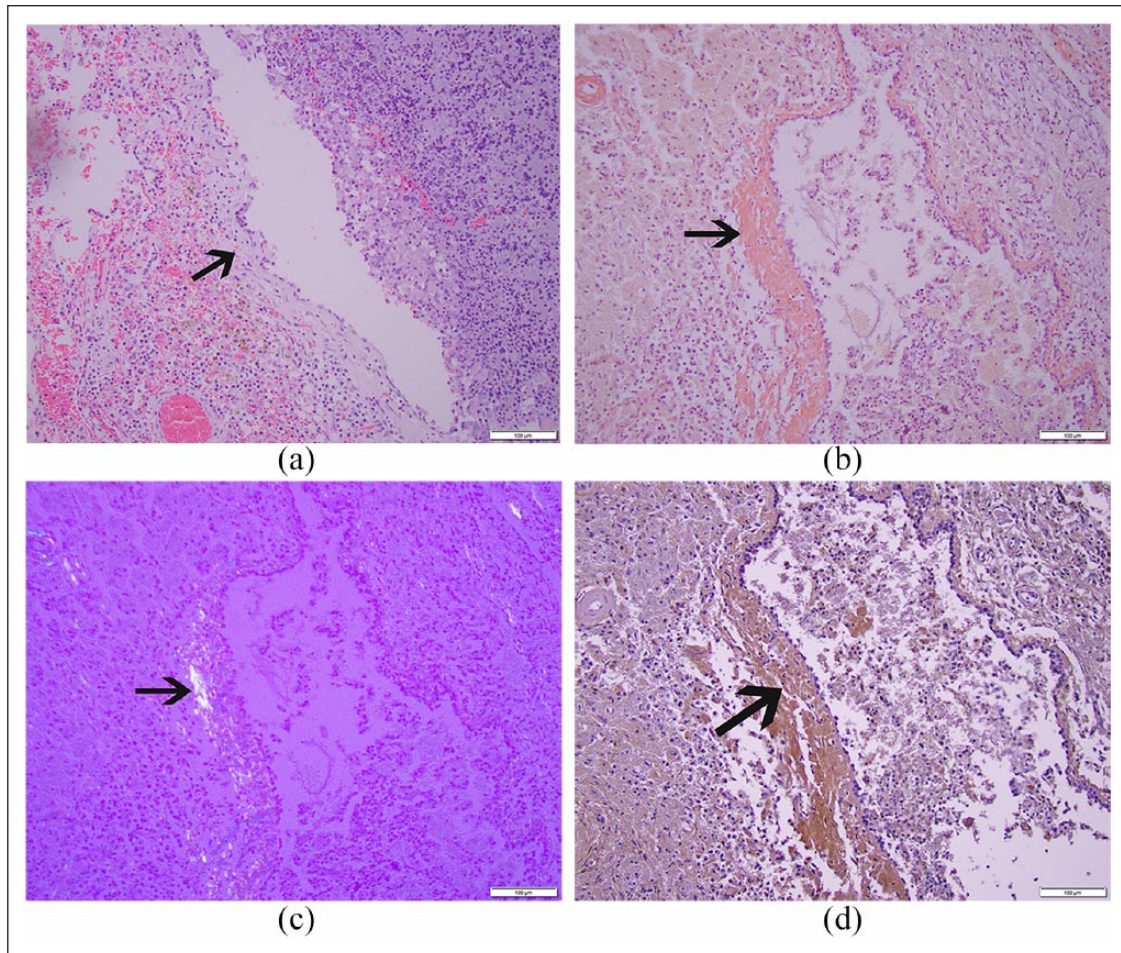
On histologic examination, bronchioles were variably ectatic and filled with epithelial and neutrophilic cellular debris, red blood cells and mucus. This inflammatory infiltrate extended into the immediately adjacent alveolar lumens and septae. In addition, hemorrhage comprised 25–95% of the lung sections, blending with the inflammation and occasionally obliterating the surrounding parenchyma (Figure 2). The walls of pulmonary vessels, bronchi and bronchioles in these areas were segmentally variably distorted and expanded by scant-to-abundant amorphous, eosinophilic, hyaline material. This material was congophilic, potassium permanganate sensitive, displayed apple green birefringence when polarized and positive for anti-AA antibody reactivity on



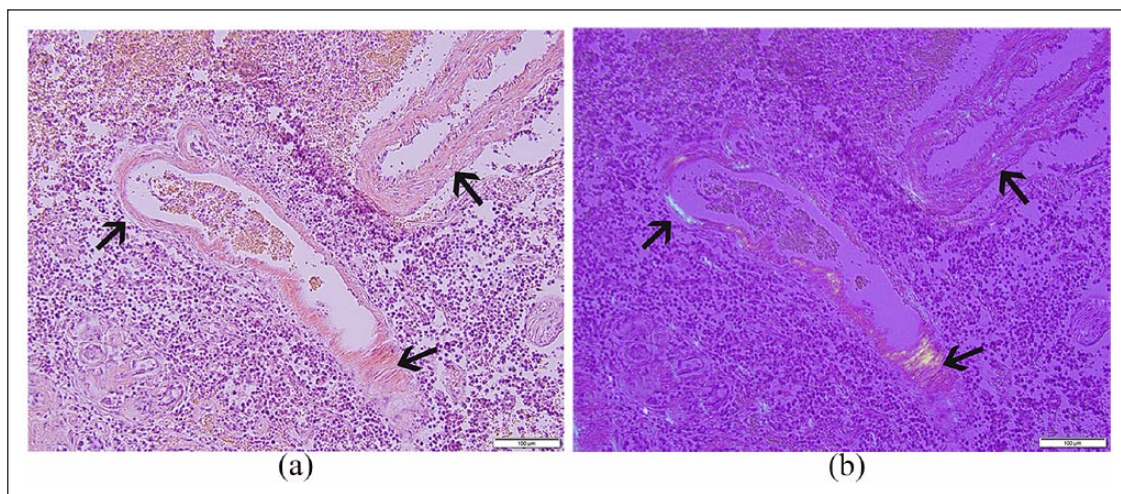
**Figure 2** Debris-filled bronchiectatic airway lumen (BL) with bronchial wall disruption, peribronchial-to-alveolar hemorrhage (\*) and adjacent localized pneumonia (black arrow). Hematoxylin and eosin stain. Bar = 500 μm

immunohistochemistry performed using Marmoset AA 408-89 monoclonal antibody (Immunology and Cancer Program, University of Tennessee Graduate School of Medicine, Knoxville, TN, USA) as per previously described techniques (Figures 3 and 4).<sup>1</sup> Submucosal and





**Figure 3** Bronchial wall tissue section with mural amyloid deposition (arrow): (a) hematoxylin and eosin stain, (b) Congo red stain without and (c) with polarization, and (d) positive immunohistochemical staining for AA antibody. Bar = 100 µm



**Figure 4** Pulmonary vessels with mural amyloid deposition (arrows). Congo red stain (a) without and (b) with polarization. Bar = 100 µm

arteriolar amyloid also was identified in the retropharyngeal lymph node and archived biopsies from the nasopharyngeal polyps and tympanic bullae.

On gross examination, the liver was small (1.78% of body weight vs 3–3.5% normal). On hematoxylin and eosin-stained sections, the tunica media of large hepatic



arteries was segmentally mildly expanded by smudgy pale eosinophilic material. However, periarteriolar birefringence, not anomalous color birefringence, was identified on special stains of these tissues. Thus, this infiltration was consistent with collagen deposition. Final diagnoses for the cat were pulmonary amyloidosis type AA, bronchiectasis and pneumonia with fibrosis and extensive pulmonary hemorrhage.

## Discussion

This report describes a novel presentation of amyloidosis type AA in a cat. Amyloidosis is a non-specific term referring to a group of disorders caused by extracellular in vivo deposition of insoluble fibrillar proteins, such as serum A-amyloid protein (type AA), in a beta-sheet conformation.<sup>2,3</sup> Many types of amyloidosis originating from different proteins have been described in people – some of which are inherited. Amyloid deposition in the extracellular space disrupts the normal tissue architecture. Although organ function can be significantly affected by the site and distribution of amyloid deposition, the mechanisms are incompletely understood.<sup>4,5</sup> Simple physical, mechanical replacement of parenchyma by amyloid deposits might not be sufficient to cause dysfunction. Once formed, the amyloid is relatively insoluble and is resistant to proteolysis. Treatment is aimed at stopping the underlying disease process if possible.

Amyloidosis in the cat most commonly involves the kidney and pancreatic islets.<sup>6,7</sup> Familial amyloidosis (type AA) has been recognized in Abyssinian cats, resulting primarily in renal deposition and disease.<sup>7,8</sup> No biochemical, urinalysis or gross necropsy findings consistent with renal disease or diabetes mellitus were identified in this case. Unfortunately, owing to their normal gross appearance, renal and pancreatic tissues were not retained for histologic examination. As such, subclinical renal and pancreatic amyloidosis cannot be ruled out. Siamese and other breeds can develop type AA systemic amyloidosis, primarily depositing in the sinusoids of the liver with potential resultant spontaneous liver rupture.<sup>9–13</sup> Most cases with hepatic amyloidosis and rupture have increased serum alanine aminotransferase activity, anemia and grossly abnormal livers on necropsy.<sup>10,13</sup> Although the cat of this report was a Siamese-cross, plasma liver enzyme activities and coagulation tests were normal, the liver was grossly small in size and there was no evidence of hepatic sinusoidal amyloid deposition on special staining. Because amyloid sequencing was not performed, a genetic component cannot be ruled out.

Clinically significant pulmonary amyloidosis has not been previously reported in the cat. In 4/11 Abyssinian cats with renal amyloidosis in one report, amyloidosis was found in limited areas of the peribronchial and peribronchiolar connective tissue.<sup>14</sup> Pulmonary amyloid was not identified in other feline reports of amyloidosis.<sup>9–12,14</sup> Amyloidosis has been associated with bronchiectasis in

humans, but amyloid deposition and disease is primarily renal in those cases.<sup>15</sup> In comparison, examination of histologic samples from the lungs of six cats diagnosed with bronchiectasis at the time of necropsy did not identify amyloid in the bronchiolar or pulmonary vessel walls (RL Donnell, unpublished data).

The cat of this report had histopathological evidence of bronchopneumonia and bronchiectasis, possibly secondary to recurrent airway hemorrhage and/or disruption of the mucociliary apparatus due to amyloid deposition. The lack of clinical signs between hemorrhagic episodes and the slow clinical progressive nature of the condition could reflect chronic inflammation leading to bronchiectasis and amyloidosis. Alternatively, the deposition of amyloid in bronchial walls and pulmonary vasculature caused the inflammation, bronchiectasis and hemorrhage. In humans, severe-to-fatal hemorrhage due to amyloidosis has been described with amyloid deposits in intestines, urinary bladder, mediastinum, trachea, bronchi and larynx, as well as cerebral arterioles.<sup>16–21</sup> Individuals with tracheobronchial, laryngeal and mediastinal amyloidosis typically present with respiratory signs due to mechanical obstruction from localized amyloidosis and resultant hemorrhage.

Vascular mural amyloid deposition with pulmonary hemorrhage has been reported in people.<sup>16,22–24</sup> Idiopathic pulmonary vascular amyloidosis, occasionally resulting in respiratory distress due to diffusion impairment, has been described in older dogs secondary to apolipoprotein AI deposition.<sup>25–27</sup> In contrast, clinical signs in this cat were due to acute recurrent hemorrhage with apparently normal pulmonary function between episodes. Alterations in vascular compliance due to the severity of amyloid type AA deposition in the walls, potentially exacerbated by increased pulmonary artery pressures during times of stress, likely resulted in intermittent pulmonary hemorrhage. Chronic topical steroid exposure is reported to contribute to the occurrence of telangiectasia in humans and experimental rats.<sup>28,29</sup> As such, it is possible that administration of steroids contributed to the final fatal hemorrhagic event.

## Conclusions

This case report describes a novel presentation of systemic amyloidosis type AA in a cat. Amyloid deposition was primarily concentrated in the walls of the pulmonary vasculature and bronchioles with lesser involvement of the nasopharyngeal tissues and local lymph nodes. Clinical signs were limited to spontaneous, progressive hemorrhage of the otic and airway tracts, and hemorrhage was ultimately fatal. Final diagnosis of amyloidosis was achieved after using microscopic examination and Congo red staining with green birefringence under polarized light on necropsy tissues. Amyloid deposition was subsequently confirmed in archived biopsy specimens from early in the disease course.

Based on the findings in this case, systemic amyloidosis should be considered as a differential diagnosis in cats with spontaneous hemorrhage of the respiratory or otic tracts after other causes have been eliminated. Evaluation of special stains on biopsy specimens is required to achieve a diagnosis during the early phase of the disease. This case shows that, although long-term prognosis for systemic amyloidosis is grave, good quality of life is possible in some cats with pulmonary amyloidosis due to the slowly progressive nature of clinical signs.

**Acknowledgements** Special thanks to Sallie Macy, BS, MLT, ASCP, Preclinical and Diagnostic Molecular Imaging Laboratory, Amyloidosis and Cancer Theranostics Program, University of Tennessee, Graduate School of Medicine, for her generous donation of time and resources in performing immunohistochemical analysis.

**Conflict of interest** The authors declared no potential conflicts of interest with respect to the research, authorship, and/or publication of this article.

**Funding** The authors received no financial support for the research, authorship, and/or publication of this article.

**ORCID iD** Dianne I Mawby  <https://orcid.org/0000-0001-5563-4674>

## References

- Ludage E, Murphy CL, Davern SM, et al. **Systemic AA amyloidosis in the common marmoset.** *Vet Pathol* 2005; 42: 117–124.
- Woldemeskel M. **A concise review of amyloidosis in animals.** *Vet Med Int* 2012; 2012: 427296. DOI: 10.1155/2012/427296.
- Westermarck GT, Fandrich M and Westermarck P. **AA amyloidosis: pathogenesis and targeted therapy.** *Annu Rev Pathol Mech Dis* 2015; 10: 321–344.
- Gillmore JD, Lovat BL, Persey MR, et al. **Amyloid load and clinical outcome in AA amyloidosis in relation to circulating concentration of serum amyloid A protein.** *Lancet* 2001; 358: 24–29.
- Merlini G, Seldin DC and Gertz MA. **Amyloidosis: pathogenesis and new therapeutic options.** *J Clin Oncol* 2011; 29: 1924–1933.
- O'Brien TD. **Pathogenesis of feline diabetes mellitus.** *Mol Cell Endocrinol* 2002; 197: 213–219.
- Dibartola SP, Tarr MJ and Benson MD. **Tissue distribution of amyloid deposits in Abyssinian cats with familial amyloidosis.** *J Comp Path* 1986; 96: 387–398.
- Chew DJ, Dibartola SP, Boyce JT, et al. **Renal amyloidosis in related Abyssinian cats.** *J Am Vet Med Assoc* 1982; 181: 139–142.
- Godfrey DR and Day MJ. **Generalized amyloidosis in two Siamese cats: spontaneous liver haemorrhage and chronic renal failure.** *J Small Anim Pract* 1998; 39: 442–447.
- Beatty JA, Barrs VR, Martin PA, et al. **Spontaneous hepatic rupture in six cats with systemic amyloidosis.** *J Small Anim Pract* 2002; 43: 355–363.
- van der Linde-Sipman JS, Niewold TA, Tooten PC, et al. **Generalized AA-amyloidosis in Siamese and Oriental cats.** *Vet Immunol Immunopathol* 1997; 56: 1–10.
- Blunden AS and Smith KC. **Generalised amyloidosis and acute liver haemorrhage in four cats.** *J Small Anim Pract* 1992; 33: 566–750.
- Zini E, Hauser B, Meli ML, et al. **Transient laboratory changes in a cat with repeated hepatic haemorrhages due to amyloidosis.** *Vet Rec* 2008; 162: 24–26.
- Crowel WA, Goldston RT, Schall WD, et al. **Generalized amyloidosis in a cat.** *J Am Vet Med Assoc* 1972; 161: 1127–1133.
- Akçay S, Akman B, Ozdemir H, et al. **Bronchiectasis-related amyloidosis as a cause of chronic renal failure.** *Ren Fail* 2002; 24: 815–23.
- Yood RA, Skinner M, Rubinow A, et al. **Bleeding manifestations in 100 patients with amyloidosis.** *J Am Med Assoc* 1983; 249: 1322–1324.
- Tariq SM, Morrison D and McConnochie K. **Solitary bronchial amyloid presenting with haemoptysis.** *Eur Respir J* 1990; 3: 1230–1231.
- Alwitry A, Brackenbur ET, Beggs FA, et al. **Vascular amyloidosis causing spontaneous mediastinal haemorrhage with haemothorax.** *Eur J Cardiothorac Surg* 2001; 20: 871–873.
- Shaheen NA, Salman SD and Nassar VH. **Fatal bronchopulmonary hemorrhage due to unrecognized amyloidosis.** *Arch Otolaryngol* 1975; 101: 259–261.
- Birkeland AC, McHugh JB and Spector ME. **Tracheo-bronchial amyloidosis: a case report and review of the literature.** *J Case Rep Med* 2014; 3: 235859. DOI: 10.4303/jcrm/235859.
- Thanvi B and Robinson T. **Sporadic cerebral amyloid angiopathy—an important cause of cerebral haemorrhage in older people.** *Age Ageing* 2006; 35: 565–571.
- Sterlacci W, Veits L, Moser P, et al. **Idiopathic systemic amyloidosis primarily affecting the lungs with fatal pulmonary haemorrhage due to vascular involvement.** *Pathol Oncol Res* 2009; 15: 133–136.
- Road JD, Jacques J and Sparling J. **Diffuse alveolar septal amyloidosis presenting with recurrent hemoptysis and medial dissection of pulmonary arteris.** *Am Rev Respir Dis* 1985; 132: 1366–1370.
- Shenin M, Xiong W, Naik M, et al. **Primary amyloidosis causing diffuse alveolar hemorrhage.** *J Clin Rheumatol* 2010; 16: 175–177.
- Roertgen KE, Lund EM, O'Brien TD, et al. **Apolipoprotein AI-derived pulmonary vascular amyloid in aged dogs.** *Am J Pathol* 1995; 147: 1311–1317.
- Johnson KH, Sletten K, Hayden DW, et al. **Pulmonary vascular amyloidosis in aged dogs. A new form of spontaneously occurring amyloidosis derived from apolipoprotein AI.** *Am J Pathol* 1992; 141: 1013–1019.
- Faunt KK, Turk JR, Cohn LA, et al. **Isolated right-ventricular hypertrophy associated with severe pulmonary vascular apolipoprotein AI-derived amyloidosis in a dog.** *J Am Anim Hosp Assoc* 1998; 34: 35–37.
- Furue M, Terao H, Rikihisa W, et al. **Clinical dose and adverse effects of topical steroids in daily management of atopic dermatitis.** *Br J Dermatol* 2003; 148: 128–133.
- Smith JG, Wehr RF and Chalker DK. **Corticosteroid-induced cutaneous atrophy and telangiectasia. Experimental production associated with weight loss in rats.** *Arch Dermatol* 1976; 112: 1115–1117.