



Long-term management of high-grade atrioventricular block using cilostazol in a cat

Authors: Iwasa, Naoki, Nishii, Naohito, Takashima, Satoshi, Kobatake, Yui, Nomura, Saki, et al.

Source: Journal of Feline Medicine and Surgery Open Reports, 5(2)

Published By: SAGE Publishing

URL: <https://doi.org/10.1177/2055116919878913>

BioOne Complete (complete.BioOne.org) is a full-text database of 200 subscribed and open-access titles in the biological, ecological, and environmental sciences published by nonprofit societies, associations, museums, institutions, and presses.

Your use of this PDF, the BioOne Complete website, and all posted and associated content indicates your acceptance of BioOne's Terms of Use, available at www.bioone.org/terms-of-use.

Usage of BioOne Complete content is strictly limited to personal, educational, and non - commercial use. Commercial inquiries or rights and permissions requests should be directed to the individual publisher as copyright holder.

BioOne sees sustainable scholarly publishing as an inherently collaborative enterprise connecting authors, nonprofit publishers, academic institutions, research libraries, and research funders in the common goal of maximizing access to critical research.



Long-term management of high-grade atrioventricular block using cilostazol in a cat

Naoki Iwasa^{1,2}, Naohito Nishii² , Satoshi Takashima², Yui Kobatake², Saki Nomura², Kazuko Iwasa¹, Tatsuo Iwasa¹, Tomomi Suzuki¹, Noboru Machida³ and Hitoshi Kitagawa⁴

Journal of Feline Medicine and Surgery Open Reports
1–7

© The Author(s) 2019

Article reuse guidelines:

sagepub.com/journals-permissions

DOI: 10.1177/2055116919878913

journals.sagepub.com/home/jfmsopenreports

This paper was handled and processed by the European Editorial Office (ISFM) for publication in *JFMS Open Reports*



Abstract

Case summary A 12-year-old neutered female domestic shorthair cat was admitted for syncope. Clinical signs and electrocardiography revealed high-grade atrioventricular (AV) block. Treatment with cilostazol ameliorated the clinical signs and arrhythmia. However, the high-grade AV block recurred on several occasions. After 640 days, the cat presented again with clinical deterioration owing to reoccurrence of the arrhythmia and it died 11 days later. Histopathological examination revealed a loss of conduction cells within the His bundle.

Relevance and novel information To our knowledge, this is the first report of high-grade AV block treated with cilostazol in a cat. Treatment with cilostazol prolonged survival for 650 days without pacemaker implantation. Histological findings suggested that the AV block was related to fibrosis of the impulse conduction system.

Keywords: His bundle; cilostazol; electrocardiography; atrioventricular block

Accepted: 4 September 2019

Introduction

Atrioventricular (AV) block is a condition wherein conduction from the atria to the ventricles is delayed or blocked.¹ Using electrocardiography (ECG), AV blocks can be classified into first-, second- and third-degree blocks according to the degree of conduction disturbance. In second-degree AV block, an intermittent conduction disturbance develops between the atrium and ventricle, and low ventricular rates are observed vs atrial rates. Second-degree AV block with one QRS complex conduction for every ≥ 3 P waves is defined as high-grade AV block.² Patients with second-degree AV block usually show no clinical signs; however, many patients with high-grade or third-degree AV block show clinical signs, such as collapse, lethargy and syncope.^{2–4} In cats, relatively few cases of high-grade AV blocks have been reported.^{5,6}

Cardiac pacemaker implantation is the preferred treatment in cats with symptomatic third-degree or

high-grade AV block.^{4,5,7} However, it requires a highly invasive procedure⁷ and has been rarely reported in the literature.^{8,9} Although a study has reported the use of terbutaline, a beta-adrenergic agonist, in a cat with high-grade AV block,⁵ no drug therapy has been established for AV block.

¹Hashima Animal Hospital, Gifu, Japan

²Laboratory of Veterinary Internal Medicine, Faculty of Applied Biological Sciences, Gifu University, Gifu, Japan

³Department of Veterinary Clinical Oncology, Faculty of Agriculture, Tokyo University of Agriculture and Technology, Tokyo, Japan

⁴Department of Veterinary Medicine, Faculty of Veterinary Medicine, Okayama University of Science, Ehime, Japan

Corresponding author:

Naohito Nishii DVM, PhD, Laboratory of Veterinary Internal Medicine, Faculty of Applied Biological Sciences, Gifu University, 1-1 Yanagido, Gifu 501-1193, Japan
Email: nishii@gifu-u.ac.jp



Creative Commons Non Commercial CC BY-NC: This article is distributed under the terms of the Creative Commons

Attribution-NonCommercial 4.0 License (<http://www.creativecommons.org/licenses/by-nc/4.0/>) which permits non-commercial use, reproduction and distribution of the work without further permission provided the original work is attributed as specified on the SAGE and Open Access pages (<https://us.sagepub.com/en-us/nam/open-access-at-sage>).

In human patients with advanced AV block, cilostazol has been administered before pacemaker implantation or in cases wherein pacemaker implantation is not possible.^{10,11} Cilostazol is an antiplatelet aggregation agent with phosphodiesterase type-3 inhibitory effects.¹¹ It causes an increase in heart rate in human patients with bradycardic atrial fibrillation, sick sinus syndrome and second-degree AV block.^{12,13} The mechanism for the increase in heart rate has not been fully elucidated to date; however, an increase in blood flow or intracellular cyclic adenosine monophosphate in the AV node tissue are speculated as the causes of this increase.¹³ In human patients with third-degree AV block, cilostazol does not eliminate the AV conduction abnormality; however, it accelerates the rate of escape rhythm.¹¹ In addition, recovery of the AV conduction using cilostazol in a human patient with advanced AV block has been reported.¹⁴

The abovementioned evidence indicates that cilostazol can be used to treat bradyarrhythmia. Although, cilostazol has been reported to increase the heart rate in healthy dogs,¹⁵ and successfully treat sick sinus syndrome in a dog, the use of cilostazol has not been reported in cats.¹⁶ The present study describes the clinical course and histological findings in a cat with high-grade AV block treated with cilostazol.

Case description

A 12-year-old neutered female domestic shorthair cat with no previous significant clinical concerns was presented to our hospital with acute-onset intermittent syncope (day 1 of illness). The cat had been vaccinated against feline herpesvirus-1, feline calicivirus and feline panleukopenia virus. During the physical examination, auscultation did not reveal any abnormalities; however, the mucous membranes were pale. Blood biochemical analyses revealed decreased potassium (2.6mEq/l; reference interval [RI] 3.1–5.0mEq/l) and albumin (2.3g/dl; RI 2.4–3.8g/dl) concentrations and increased alanine aminotransferase (111U/l; RI 18–108U/l), blood glucose (302mg/dl; RI 63–132mg/dl) and troponin I (0.102ng/ml; RI <0.02ng/ml) concentrations. White blood cell count (13,300/ μ l; RI 5500–19,500/ μ l), urea nitrogen (30.3 mg/dl; RI 17.6–32.8mg/dl), creatinine (1.0mg/dl; RI 0.8–1.8mg/dl) and thyroxine (1.8 μ g/dl; RI 0.6–3.9 μ g/dl) were within the RIs. Radiographs revealed mild cardiomegaly (vertebral heart scale, 8.4; normal cats: 7.5 \pm 0.3),¹⁷ with no abnormalities identified in the lung field.

ECG at the first visit showed P waves without QRS complexes for approximately 20s, followed by a normal sinus rhythm (Figure 1a). Syncope developed and was consistent with the absence of the QRS complex. This syncope occurred repeatedly approximately every 5mins along with a spontaneous recovery cycle. Echo cardiography revealed diastolic regurgitation originating from the mitral valve to the left atrium when the QRS

complex disappeared on the ECG. However, diastolic regurgitation was not observed in any valve in the systolic and diastolic phases when normal AV conduction was maintained. There was no hypertrophy or thinning of the myocardium or morphological abnormalities in the cardiac chambers, valves, aorta or pulmonary artery, and the rest of ECG was unremarkable. The left ventricular fractional shortening was 51.5%. Based on these findings, high-grade AV block without underlying structural heart disease was diagnosed.

Table 1 presents a chronological summary of body weight, vital signs, clinical signs and treatment. On day 1, the cat was maintained in a 40% oxygen atmosphere and received dobutamine (8 μ g/kg/min, dobutamine hydrochloride injection; Koa Isei) and atropine (0.05mg/kg, atropine sulfate injection; Mitsubishi Tanabe Pharma) intravenously and cilostazol (8mg/kg q12h; Pletal, Otsuka Pharmaceutical) orally. On day 2, the cat was eupnoeic in room air and there was no syncope. Each of the P waves was associated with QRS complexes; however, ECG revealed wide QRS complexes (QRS interval: 60ms) (Figure 1b). The cat regained activity and appetite, and was discharged thereafter. Blood glucose (128mg/dl) was within the RI. The owner declined pacemaker implantation. The cat continued to receive cilostazol (8mg/kg q12h, increased to 10mg/kg q12h later) orally. On day 147, ECG revealed a normal sinus rhythm (Figure 1c), and the cat showed no clinical signs that were potentially referable to a bradyarrhythmia.

On day 403, the cat became lethargic and anorexic, and intermittent syncope developed. Over a long period of time during ECG examination, P waves were observed, whereas QRS complexes were absent, which were suggestive of a high-grade AV block (Figure 1d). ECG revealed normal sinus rhythm followed by a period without any ventricular escape activity (approximately 20s). The cat received aminophylline (7mg/kg q12h neophyllin; Eisai Co.) orally in addition to cilostazol. After this treatment, the cat's activity and appetite returned to normal and no syncope occurred. A normal sinus rhythm was observed during ECG on day 428 (Figure 1e).

On day 538, the cat revisited the hospital because of occasional collapse, but its activity and appetite remained normal. ECG revealed normal sinus rhythm followed by uncondensed P waves, which were suggestive of high-grade AV block. A maximum of nine P waves were blocked for approximately 3s. Ventricular escape rhythm with wide QRS complexes (QRS interval 73ms) was observed during the loss of AV conduction (Figure 1f). ECG revealed mild mitral and tricuspid regurgitations during systole. The left ventricular fractional shortening was 51.5%.

On day 640, the cat became lethargic and anorexic again, and showed increased frequency of syncope. ECG revealed tachycardia (230bpm) with low-amplitude QRS complexes and inverted T waves, followed by

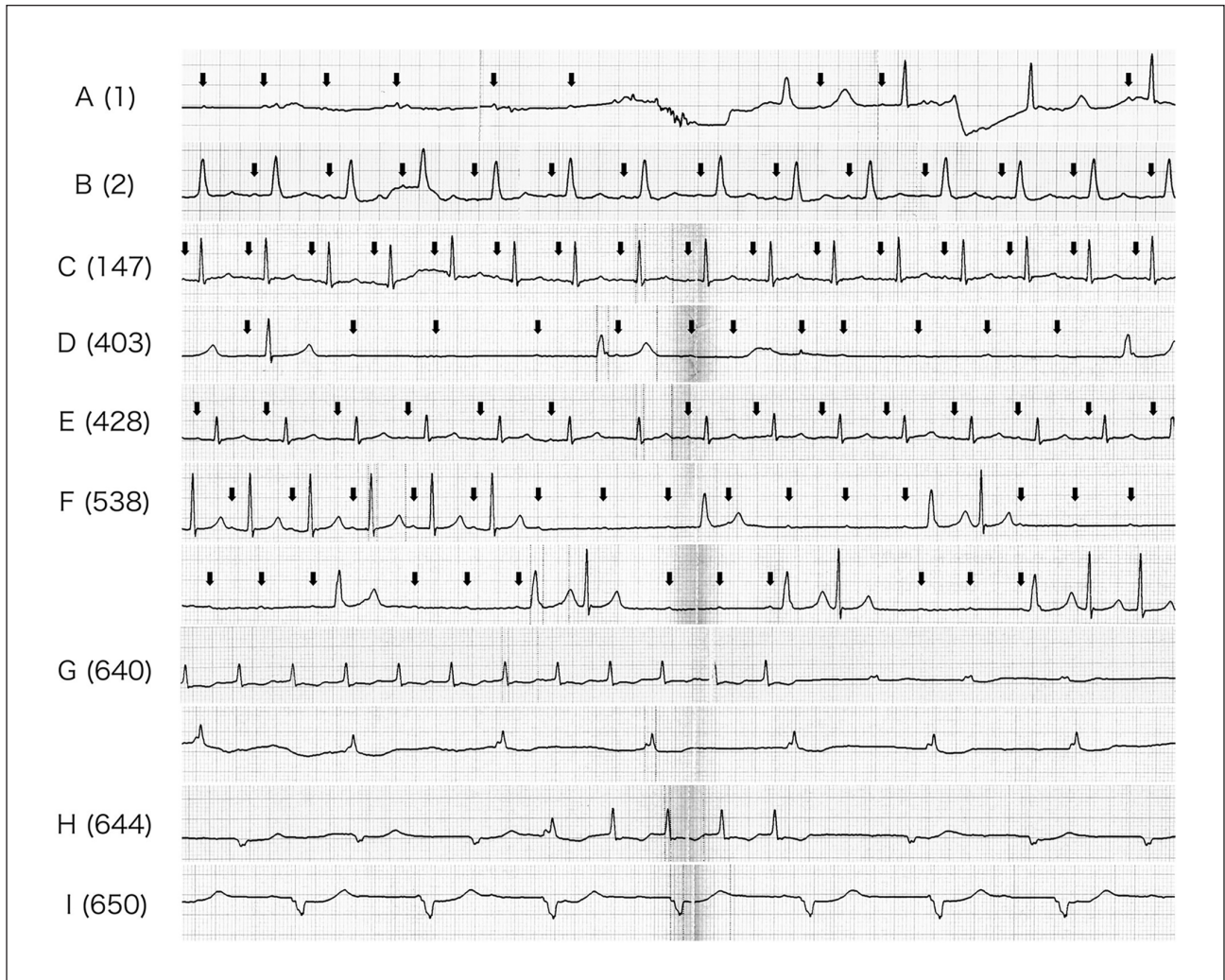


Figure 1 Lead II electrocardiogram. Days of illness are indicated in parentheses (10 mm/mV, 50 mm/s). Arrows indicate P waves

regular biphasic wide R waves at a slow rate (75bpm; Figure 1g). The ECG waves observed later suggested ventricular escape rhythms. For treatment, in addition to the administration of cilostazol and aminophylline, isoproterenol (0.8mg/kg q12h Proteranol S; Kowa Co.) and isosorbide dinitrate (1mg/kg q12h Frandol; Astellas Pharma) were orally administered. However, this treatment failed to improve the clinical signs, and the patient presented with dyspnoea on day 644. Ultrasonography revealed pleural effusion and ascites. Auscultation revealed a grade 2/6 systolic left apical murmur. ECG revealed positive or negative biphasic wide R waves, and normal sinus rhythm intermittently appeared (Figure 1h). ECG also revealed slight mitral and tricuspid regurgitations, enlargement of the left and right atria, and flattening of the interventricular septum. The left ventricular fractional shortening was 37.7%. The cat was maintained in a 40% oxygen atmosphere and received intravenous furosemide (1 mg/kg/6h Lasix injection; Sanofi), followed by thoracocentesis.

On day 650, the cat became unconscious. Ventricular rhythms without clear P waves were observed during ECG (Figure 1i). The cat arrested on day 651.

Necropsy revealed enlarged right and left atria, but normal valves and myocardium. The liver was congested but the macroscopic examinations revealed no abnormality otherwise. Histopathological examinations of the heart revealed no abnormality of conducting cells in the AV node (Figure 2a) and the proximal part of the penetrating His bundle (Figure 2b). However, a remarkable decrease was observed in the number of conducting cells between the middle part of the penetrating His bundle (Figure 2c) and the proximal part of the bifurcating His bundle (Figure 2d). The lesion was partly or completely devoid of conducting cells and was replaced by immature fibrous tissues. Severe fibrosis was also observed in the basal part of the central fibrous body and crest of the ventricular septum. There was no abnormality in the sinus node, sinoatrial conduction path, distal part of the bifurcation of the His bundle, or left and right bundle branches.

Table 1 Chronological summary of body weight, vital signs, clinical signs and treatments in a cat with high-grade atrioventricular block

Day	Body weight (kg)	Body temperature (°C)	Respiratory rate (breaths/min)	Heart rate (beats/min)	Clinical signs	Treatment
1	2.95	36.7	78	45	Syncope and collapse	Atropine (0.05 mg/kg IV), dobutamine (8 µg/kg/min IV), oxygen therapy, cilostazol (8 mg/kg PO)
2	2.95	36.7	42	183	No syncope	Cilostazol (8 mg/kg PO)
100	2.75	38.3	48	160	No syncope	Cilostazol (10 mg/kg PO)
147	2.95	38.6	42	191	No syncope	Cilostazol (10 mg/kg PO)
165	2.9	38.0	42	184	No syncope	Cilostazol (10 mg/kg PO)
189	2.96	38.1	48	195	No syncope	Cilostazol (10 mg/kg PO)
238	3.05	38.4	48	210	No syncope	Cilostazol (10 mg/kg PO)
403	2.9	37.8	60	28	Occasional syncope	Cilostazol (10 mg/kg PO), aminophylline (7 mg/kg PO)
428	2.85	38.0	48	178	No syncope	Cilostazol (10 mg/kg PO), aminophylline (7 mg/kg PO)
452	2.8	38.4	42	181	No syncope	Cilostazol (10 mg/kg PO), aminophylline (7 mg/kg PO)
538	2.9	38.1	42	105	Occasional collapse	Cilostazol (10 mg/kg PO), aminophylline (7 mg/kg PO)
640	2.9	38.0	50	83	Syncope and collapse	Cilostazol (10 mg/kg PO), aminophylline (7 mg/kg PO), isoproterenol (0.8 mg/kg PO), isosorbide dinitrate (1 mg/kg PO)
644	2.85	38.5	54	30	Syncope, dyspnoea, pleural effusion and ascites	Cilostazol (10 mg/kg PO), aminophylline (7 mg/kg PO), furosemide (1 mg/kg/6 h IV), oxygen therapy
646	2.85	37.9	58	144	Syncope, dyspnoea, pleural effusion and ascites	Cilostazol (10 mg/kg PO), aminophylline (7 mg/kg PO), furosemide (1 mg/kg/6 h IV), oxygen therapy
650	1.9	35.0	54	83	Unconscious, dyspnoea, pleural effusion and ascites	Furosemide (1 mg/kg/6 h IV), oxygen therapy, removal of effusion

All oral administrations were given twice a day

Discussion

In veterinary medicine, syncope can be caused by structural cardiac diseases, arrhythmias and non-cardiac causes (eg, drug-induced, neurological diseases and metabolic disturbances).³ High-grade and third-degree AV blocks are bradyarrhythmias that can cause syncope in cats.^{4,5} In the present study, the cat was diagnosed with high-grade AV block at the first visit on the basis of the uncondensed P waves followed by a normal sinus rhythm. The loss of AV conduction and syncope synchronously developed, thus confirming that the clinical signs had been caused by bradycardia and cerebral hypoperfusion due to the high-grade AV block.

Medical treatment for AV block has not been established in cats. In the present paper, the cat was treated using cilostazol and other drugs upon the owner's

request. As shown in our report, cilostazol was effective during the initial cardiac treatment, as demonstrated by a significant increase in heart rate and amelioration of the syncope. Kellum and Stepien⁴ reported the successful treatment of 14 cats with AV block using drug therapy, with a median survival period of 386 days. In the present report, the cat remained stable until approximately day 540, suggesting the efficacy of cilostazol as a choice of treatment for high-grade AV block in cats. However, the cat in our paper received aminophylline in addition to cilostazol from day 403 because it has been shown to improve AV conduction in human patients with AV block.¹⁸ Therefore, the effect of drug therapy after day 403 should be evaluated considering the dual use of cilostazol and aminophylline. In our report, only a ventricular rhythm was observed during ECG after day

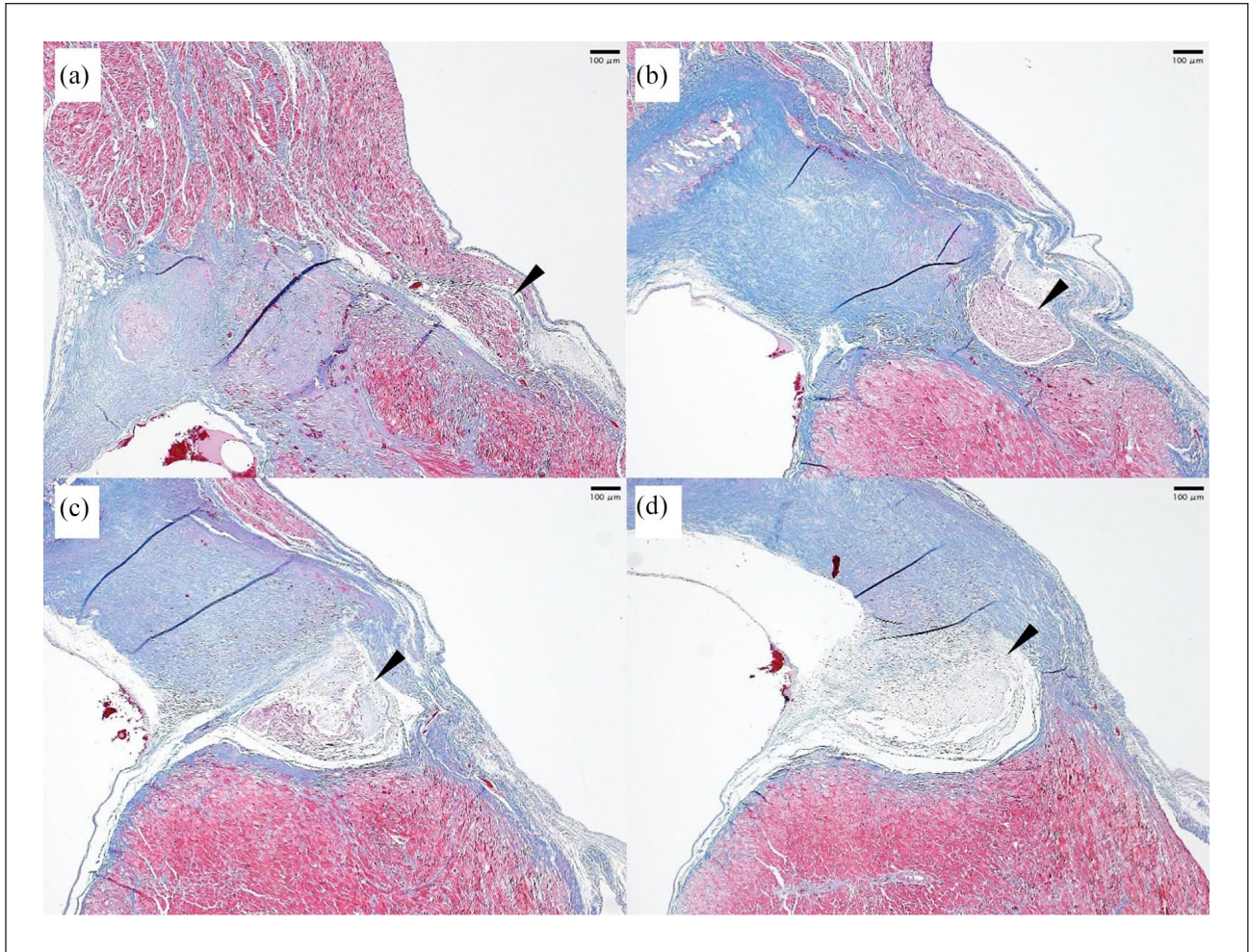


Figure 2 Histology of the horizontal section between the atrioventricular node and the His bundle (haematoxylin and eosin stain): (a) the AV node (arrowhead); (b) the proximal part of the penetrating His bundle (arrowhead); (c) the middle part of the penetrating His bundle (arrowhead); and (d) the proximal part of the bifurcating His bundle (arrowhead). Scale bar=100µm

650, which suggests that the condition progressed from partial to complete AV block. Although the cat's life could have been prolonged by implanting a heart pacemaker, the owner declined a pacemaker implantation.

In cats, abnormality in the impulse conduction system has been associated with cardiac diseases, such as hypertrophic cardiomyopathy, and systemic illness, such as hyperthyroidism.^{19–22} The histological examination of 63 cats with cardiomyopathy revealed fibrosis in both the myocardium and the impulse conduction system.²² In the present report, the lesion was found to be restricted to the impulse conduction system, and no abnormalities were identified in the myocardium. However, the presence of myocardial injury could not be excluded because blood troponin I concentration was increased. Non-cardiac diseases, such as azotaemia²³ or systemic inflammation,²⁴ increase blood troponin I concentrations in dogs; however, the cat in our study neither had azotaemia nor any clinical signs of systemic inflammation, with a white blood cell count within the RI. Dogs with second- or

third-degree AV block may have increased blood troponin I concentration owing to acute or chronic myocarditis.²⁵ In addition, cats with transient trifascicular block with increased troponin I concentrations have been suspected to have myocarditis.²⁶ Moreover, the presence of myocarditis before necropsy was performed could not be excluded in the case reported in our paper; however, the histological examination did not reveal any findings suggestive of myocarditis. In humans, age-related idiopathic fibrosis, which is referred to as sclerosis of the left side of the cardiac skeleton, is considered as a common cause of complete AV block.¹ The advanced fibrosis observed in the present report was similar to the pathological change associated with sclerosis of the left side of the cardiac skeleton in humans.

The degeneration of cells in the His bundle poses a risk of progression to complete AV block.^{1,19} Furthermore, in the present study, progression to complete AV block was suspected on day 650, which was confirmed by the histopathological findings showing a complete discontinuity

in the impulse conduction system. The lack of a clear P wave after day 640 possibly suggests sinus arrest; however, this seems unlikely because no abnormalities were observed in the sinus node or sinoatrial conduction path in the histopathological examinations.

A limitation of the present study is the lack of an ambulatory ECG monitoring system. Because transient abnormality can be undocumented by a conventional ECG, an ambulatory ECG could have evaluated the conduction abnormality more precisely, particularly when the cat showed no clinical signs.

Conclusions

To the best of our knowledge, this is the first report of the treatment of high-grade AV block using cilostazol in a cat. The use of cilostazol provided 650 days of survival without a pacemaker implantation. The histological findings suggested that the AV block was related to the fibrosis of the impulse conduction system in the cat.

Acknowledgements The authors would like to thank Enago (www.enago.jp) for the English language review.

Conflict of interest The authors declared no potential conflicts of interest with respect to the research, authorship, and/or publication of this article.

Funding The authors received no financial support for the research, authorship, and/or publication of this article.

Ethical approval This work involved the use of non-experimental animal(s) only (owned or unowned), and followed established internationally recognised high standards ('best practice') of individual veterinary clinical patient care. Ethical approval from a committee was not necessarily required.

Informed consent Informed consent (either verbal or written) was obtained from the owner or legal custodian of all animal(s) described in this work for the procedure(s) undertaken. No animals or humans are identifiable within this publication, and therefore additional informed consent for publication was not required.

ORCID iD Naohito Nishii  <https://orcid.org/0000-0003-2173-5420>

References

- 1 Lev M. **Anatomic basis for atrioventricular block.** *Am J Med* 1964; 37: 742–748.
- 2 Schrope DP and Kelch WJ. **Signalment, clinical signs, and prognostic indicators associated with high-grade second- or third-degree atrioventricular block in dogs: 124 cases (January 1, 1997–December 31, 1997).** *J Am Vet Med Assoc* 2006; 228: 1710–1717.
- 3 Miller RH, Lehmkuhl LB and Bonagura JD. **Retrospective analysis of the clinical utility of ambulatory electrocar-**

- diographic (Holter) recordings in syncopal dogs: 44 cases (1991–1995).** *J Vet Intern Med* 1999; 13: 111–122.
- 4 Kellum HB and Stepien RL. **Third-degree atrioventricular block in 21 cats (1997–2004).** *J Vet Intern Med* 2006; 20: 97–103.
- 5 Penning VA, Connolly DJ, Gajanayake I, et al. **Seizure-like episodes in 3 cats with intermittent high-grade atrioventricular dysfunction.** *J Vet Intern Med* 2009; 23: 200–205.
- 6 Rishniw M, Tobias AH, Marks SL, et al. **ECG of the month. High-grade second-degree AV block and right bundle-branch block in a cat.** *J Am Vet Med Assoc* 1994; 205: 425–427.
- 7 Santilli RA, Giacomazzi F, Porteiro Vázquez DM, et al. **Indications for permanent pacing in dogs and cats.** *J Vet Cardiol* 2019; 22: 20–39.
- 8 Hirakawa A, Fujiki M, Miura N, et al. **Pacemaker implantation in a cat with paroxysmal third-degree atrioventricular block.** *J Jpn Vet Med Assoc* 2000; 53: 75–79.
- 9 Fox PR, Moise NS, Woodfield JA, et al. **Techniques and complications of pacemaker implantation in four cats.** *J Am Vet Med Assoc* 1991; 199: 1742–1753.
- 10 Atarashi H, Endoh Y, Saitoh H, et al. **Chronotropic effects of cilostazol, a new antithrombotic agent, in patients with bradyarrhythmias.** *J Cardiovasc Pharmacol* 1998; 31: 534–539.
- 11 Kodama-Takahashi K, Kurata A, Ohshima K, et al. **Effect of cilostazol on the ventricular escape rate and neuro-humoral factors in patients with third-degree atrioventricular block.** *Chest* 2003; 123: 1161–1169.
- 12 Toyonaga S, Nakatsu T, Murakami T, et al. **Effects of cilostazol on heart rate and its variation in patients with atrial fibrillation associated with bradycardia.** *J Cardiovasc Pharmacol Ther* 2000; 5: 183–191.
- 13 Kishida M, Watanabe K and Tsuruoka T. **Effects of cilostazol in patients with bradycardiac atrial fibrillation.** *J Cardiol* 2001; 37: 27–33.
- 14 Nimura A, Sato N, Sakuragi H, et al. **Recovery of advanced atrioventricular block by cilostazol.** *Intern Med* 2011; 50: 1957–1961.
- 15 Fukushima R, Kawaguchi T, Yamada S, et al. **Effects of cilostazol on the heart rate in healthy dogs.** *J Vet Med Sci* 2018; 80: 1707–1715.
- 16 Kanno N and Suzuki T. **Long term effects of cilostazol in a dog with sick sinus syndrome.** *J Vet Med Sci* 2017; 79: 1031–1034.
- 17 Lister AL and Buchanan JW. **Vertebral scale system to measure heart size in radiographs of cats.** *J Am Vet Med Assoc* 2000; 216: 210–214.
- 18 Altun A, Kirdar C and Ozbay G. **Effect of aminophylline in patients with atropine-resistant late advanced atrioventricular block during acute inferior myocardial infarction.** *Clin Cardiol* 1998; 21: 759–762.
- 19 Kaneshige T, Machida N, Itoh H, et al. **The anatomical basis of complete atrioventricular block in cats with hypertrophic cardiomyopathy.** *J Comp Pathol* 2006; 135: 25–31.
- 20 Harvey AM, Battersby IA, Faena M, et al. **Arrhythmogenic right ventricular cardiomyopathy in two cats.** *J Small Anim Pract* 2005; 46: 151–156.

- 21 Martinelli E, Spalla I, Quintavalla P, et al. **ECG of the month. Arrhythmia due to hyperthyroidism in a cat.** *J Vet Med Assoc* 2013; 243: 787–789.
- 22 Liu SK, Tilley LP and Tashjian RJ. **Lesions of the conduction system in the cat with cardiomyopathy.** *Recent Adv Stud Cardiac Struct Metab* 1975; 10: 681–693.
- 23 Porciello F, Rishniw M, Herndon WE, et al. **Cardiac troponin I is elevated in dogs and cats with azotaemia renal failure and in dogs with non-cardiac systemic disease.** *Aust Vet J* 2008; 86: 390–394.
- 24 Hamacher L, Dörfelt R, Müller M, et al. **Serum cardiac troponin I concentrations in dogs with systemic inflammatory response syndrome.** *J Vet Intern Med* 2015; 29: 164–170.
- 25 Wiedemann N, Hildebrandt N, Wurtinger G, et al. **Follow-up of troponin I concentration in dogs with atrioventricular block and dual-chamber pacing in a case-matched study.** *J Vet Cardiol* 2017; 19: 247–255.
- 26 Oxford EM, Giacomazzi FB, Moise NS, et al. **Clinical and electrocardiographic presentations of transient trifascicular block in three cats.** *J Vet Cardiol* 2018; 20: 204–212.