



Intranasal proliferative fibro-osseous dysplasia in a domestic longhair cat

Authors: D'Aout, Clarisse, Renfrew, Helen, Dobromylskyj, Melanie, Bacon, Nicholas, Herrmann, Annika, et al.

Source: Journal of Feline Medicine and Surgery Open Reports, 6(1)

Published By: SAGE Publishing

URL: <https://doi.org/10.1177/2055116920917839>

BioOne Complete (complete.BioOne.org) is a full-text database of 200 subscribed and open-access titles in the biological, ecological, and environmental sciences published by nonprofit societies, associations, museums, institutions, and presses.

Your use of this PDF, the BioOne Complete website, and all posted and associated content indicates your acceptance of BioOne's Terms of Use, available at www.bioone.org/terms-of-use.

Usage of BioOne Complete content is strictly limited to personal, educational, and non - commercial use. Commercial inquiries or rights and permissions requests should be directed to the individual publisher as copyright holder.

BioOne sees sustainable scholarly publishing as an inherently collaborative enterprise connecting authors, nonprofit publishers, academic institutions, research libraries, and research funders in the common goal of maximizing access to critical research.



Intranasal proliferative fibro-osseous dysplasia in a domestic longhair cat

Clarisse D'Aout¹, Helen Renfrew¹,
Melanie Dobromylskyj² , Nicholas Bacon³,
Annika Herrmann⁴ and Samantha S Taylor¹

Journal of Feline Medicine and Surgery Open Reports
1–6

© The Author(s) 2020

Article reuse guidelines:

sagepub.com/journals-permissions

DOI: 10.1177/2055116920917839

journals.sagepub.com/home/jfmsopenreports

This paper was handled and processed by the European Editorial Office (ISFM) for publication in *JFMS Open Reports*



Abstract

Case summary A 13-year-old female domestic longhair cat was presented for further investigation of chronic sneezing combined with a right-sided nasal discharge. A CT scan of the head revealed a locally invasive, aggressive right nasal mass radiographically consistent with a malignant neoplastic process. Histopathology on rhinoscopically guided biopsies revealed an unusual pathology consistent with fibro-osseous hyperplasia/dysplasia. Surgical treatment via a ventral rhinotomy and curettage was performed, and the diagnosis confirmed by repeat histopathology. The cat's clinical signs significantly improved postoperatively.

Relevance and novel information This case report describes an unusual feline nasal pathology. To our knowledge, there are no previous reports of a non-neoplastic, non-inflammatory expansile feline nasal tumour. Also described are the CT and histological appearance of the mass, and the difficulties encountered obtaining the definitive diagnosis. Information regarding the prognosis following surgical removal of proliferative fibro-osseous lesions in cats is poor, especially from the nasal cavity where clean margins may well be impossible to obtain. In this case, surgical resection improved clinical signs and the cat remains well at 15 months post-procedure.

Keywords: Nasal tumour; ossifying fibroma; fibrous dysplasia; fibrous hyperplasia; osteoma

Accepted: 6 March 2020

Introduction

Chronic nasal discharge is frequently encountered in feline veterinary medicine. A variety of causes are involved in the complex and sometimes unclear aetiology of chronic nasal disease and a specific diagnosis is needed to provide appropriate management. Common causes of nasal disease include infectious (commonly viral) disease potentially leading to chronic rhinitis, neoplasia, trauma, foreign bodies, anatomical defects such as stenotic nares or cleft palate, oronasal fistula and dental disease.^{1,2} Nasopharyngeal conditions such as polyps or nasopharyngeal stenosis may cause similar clinical signs, in particular stertor, and should be included in the differential diagnosis.³ Diagnosis of specific nasal diseases relies on a combination of techniques, including radiography, CT, rhinoscopy, cytology, bacterial and fungal culture, and histopathology of biopsy samples.^{4,5}

Chronic rhinitis and neoplasia have been reported to be the most common causes of feline nasal disease.² However, dysplastic lesions of the nose, rather than neoplastic fibro-osseous lesions, are poorly described in veterinary medicine. Benign, intra-osseous, proliferative fibro-osseous lesions (PFOLs) are a group of lesions characterised by replacement of normal bone by a proliferative fibrous matrix with various degrees of mineralisation and ossification.⁶ In human medicine, benign PFOLs

¹Lumbry Park Veterinary Specialists, Alton, UK

²Finn Pathologists Histopathology Department, Diss, Norfolk, UK

³Fitzpatrick Referrals Oncology and Soft Tissue, Guildford, UK

⁴SYNLAB VPG Histology, Bristol, UK

Corresponding author:

Clarisse D'Aout DVM, MRCVS, Lumbry Park Veterinary Specialists, Selborne Road, Alton GU34 3HL, UK
Email: clarisse.daout@cvs vets.com



Creative Commons Non Commercial CC BY-NC: This article is distributed under the terms of the Creative Commons

Attribution-NonCommercial 4.0 License (<https://creativecommons.org/licenses/by-nc/4.0/>) which permits non-commercial use, reproduction and distribution of the work without further permission provided the original work is attributed as specified on the SAGE and Open Access pages (<https://us.sagepub.com/en-us/nam/open-access-at-sage>).

include ossifying fibroma (OF), fibrous dysplasia (FD) and cemento-osseous dysplasia (COD), among others.^{7,8} Low-grade osteosarcomas (LG-OSAs) should also be included in the differential diagnosis of mandibular PFOLs as they share histological resemblances with these benign lesions.⁹ Reports in small animals are uncommon,¹⁰⁻¹⁶ and some of the forms described in people have not been reported in veterinary medicine. Reaching a definitive diagnosis of a fibro-osseous lesion poses a challenge for human and veterinary pathologists owing to the similarity of the different subtypes (OF, FD, COD, LG-OSA) in their microscopic appearance.⁹

This report describes the diagnosis and surgical treatment of a large, expansile, non-neoplastic, non-inflammatory hyperplastic/dysplastic fibrous lesion originating from the nasal cavity of a cat.

Case description

A 13-year-old female neutered domestic longhair cat weighing 3.9 kg was presented to a referral centre for investigation of chronic sneezing with a persistent right-sided mucopurulent nasal discharge. The owners

reported some response to a 3-week course of doxycycline, but the signs recurred once treatment was stopped. A subsequent 4-week course of doxycycline and a 10-day course of marbofloxacin did not result in any improvement. At the referring clinic an intra-oral radiograph showed a unilateral soft tissue opacity within the nasal chamber. A nasal flush revealed a marked neutrophilic inflammation with >90% of the cells being deteriorated/degenerated; it appeared to be septic on both cytology and culture (*Pseudomonas aeruginosa*, *Pasteurella* species and *Enterococcus* species isolated, along with oropharyngeal contamination). Bacterial rhinitis was suspected but considered unlikely to be the primary process. Fine-needle aspiration of the submandibular area revealed reactive lymphoid tissue with mild eosinophilic lymphadenitis. A pharyngeal impression smear was also performed and showed some mild neutrophilic inflammation and possibly some mild hyperplasia or dysplasia (Greendale Veterinary Diagnostics).

On examination, the cat was quiet and alert, and in thin body condition (body condition score 3/9). There was reduced airflow in the left nostril and absent airflow in the right nostril; this was assessed using a wisp of cotton while closing the mouth and occluding the alternate nostril. There was a serous discharge from the right nostril and stertor on inspiration. There was no facial deformation.

A complete blood count and biochemistry revealed a mild-to-moderate non-regenerative anaemia (packed cell volume 23.1%) without any other associated abnormality. CT of the head and thorax under general anaesthesia (followed by normograde and retrograde rhinoscopy) revealed an irregularly marginated contrast-enhancing expansile mixed bone and soft tissue mass filling the right nasal cavity centred at the level of the last left upper premolar, with a honeycomb-like appearance (Figure 1). The mass extended rostrally to the rostral margin of the maxilla, and caudally to the choana. The presence of the mass may have obstructed mucous flow from the frontal and sphenoidal sinuses on the right, resulting in the filling of both with fluid (Figure 2).

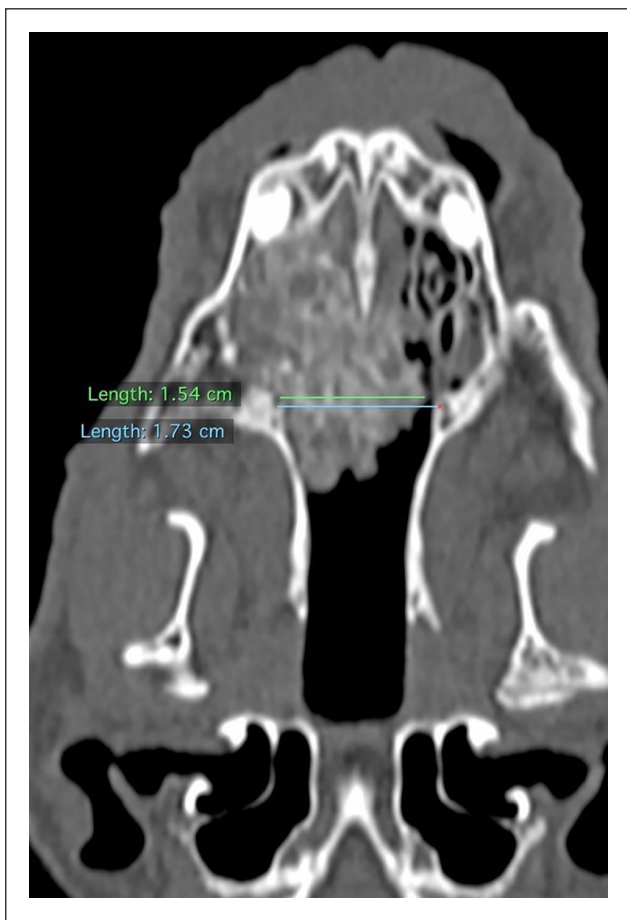


Figure 1 Dorsal reconstruction at the level of the nasopharynx showing the mass filling the choanae and partially occluding the entire rostral nasopharynx but for the narrow gas-filled channel on the left

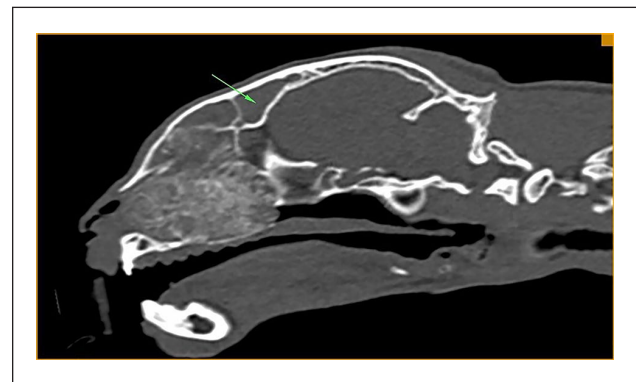


Figure 2 Sagittal reconstruction showing the mass filling the right nasal cavity from rostral maxilla to choanae. The arrow indicates the fluid-filled frontal sinus

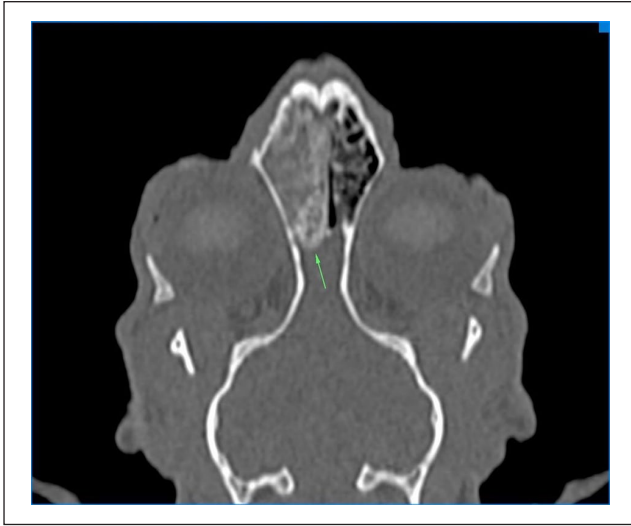


Figure 3 Dorsal reconstruction at the level of the orbit, showing invasion through the right cribriform plate (arrow)

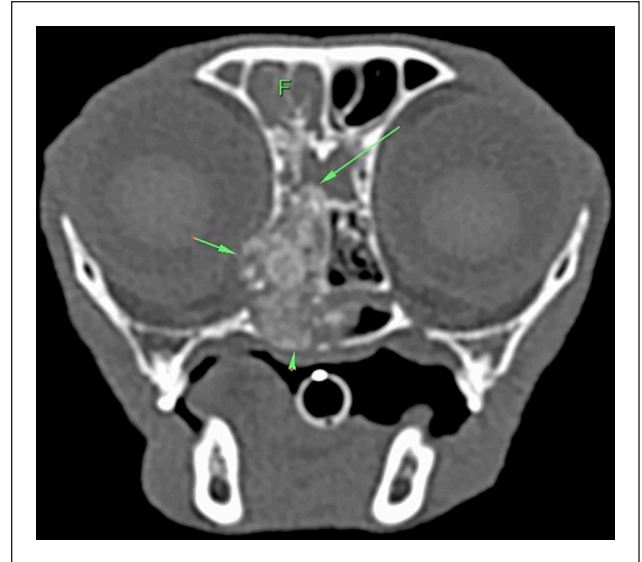


Figure 5 Transverse reconstruction at the level of the cribriform plate showing the fluid-filled left frontal sinus (F), and expansion of the mass through the left cribriform plate (long arrow), the frontal bone on the medial aspect of the left orbit (short arrow), and the palatal bone (arrowhead).

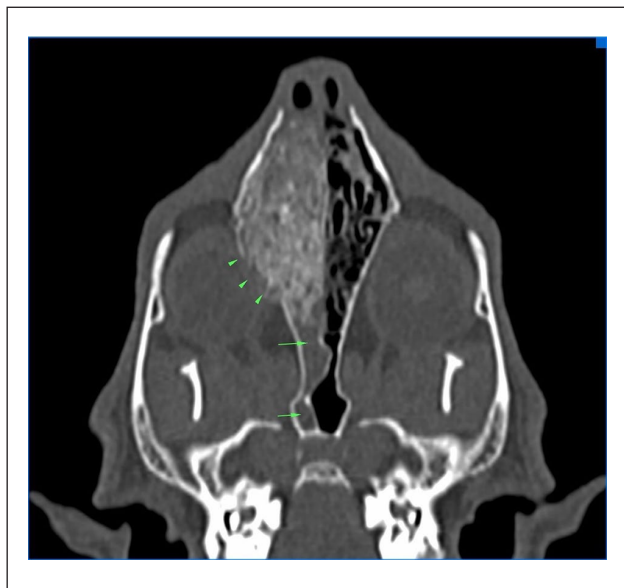


Figure 4 Dorsal reconstruction at the level of the sphenoidal sinus, showing the mass destroying the right frontal bone and invading the right orbit (arrowheads), and fluid filling of the right sphenoidal sinus (arrow) due to obstruction of drainage by the mass

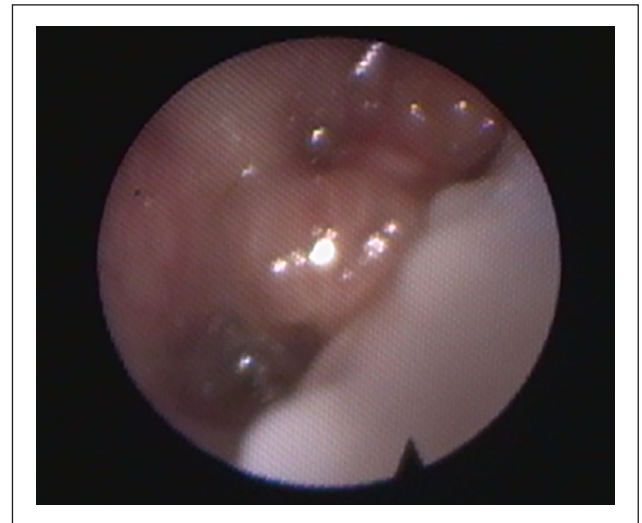

Figure 6 Retrograde rhinoscopic image showing the mass obstructing the right choana and spreading to the left

Thinning and destruction of the cribriform plate was seen (Figure 3), along with similar changes in the frontal and palatal bones, basal lamina of the sphenoid and caudal vomer where the mass had expanded to invade the left nasal chamber, the calvarium, the left orbit and the nasopharynx (Figures 4 and 5). At the level of the choanae the mass nearly filled the air passage, leaving a narrow channel on the left. There was mild right exophthalmos.

Rhinoscopy showed a large mass lesion within the caudal nasopharynx obstructing the choana on the right

and extending over to the left (Figure 6). Multiple biopsies were taken and submitted for histopathology and bacterial and fungal culture.

Microscopic examination revealed parts of an expansile lesion compressing adjacent normal tissues, composed of moderately cellular fibrous stroma containing multifocal areas of trabecular woven bone and partially mineralised osteoid matrix (Figure 7). These trabeculae were not obviously lined by osteoblasts, and osteoclasts appeared to be rare. The lesion also contained rare foci of chondroid matrix (not shown). Mitotic figures were

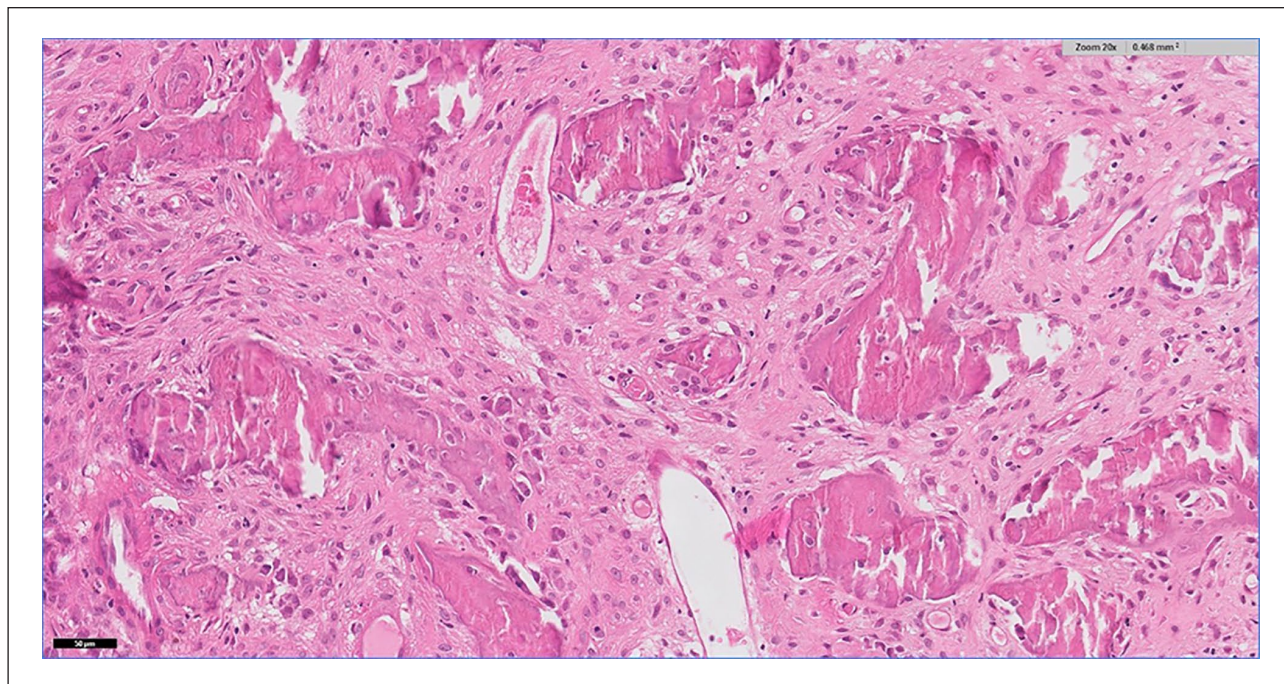


Figure 7 Photomicrograph of a biopsy sample showing soft tissues expanded by areas of moderately cellular fibrous stroma containing multifocal areas of trabecular bone, and partially mineralised osteoid matrix. Haematoxylin and eosin $\times 20$

not noted. The provisional differential diagnosis based on histopathology of the biopsy was fibro-osseous hyperplasia or dysplasia, but the possibility of OF, or an LG-OSA with osteoid and chondroid formation, could not be entirely excluded. Given the presence of the inflammation, this could have represented a chronic, reactive change.

Mass removal was carried out via a ventral rhinotomy. The mucoperiosteum was sharply incised and subsequently undermined and retracted laterally to expose the hard palate. A large bone window was created with a pneumatic burr, which allowed access to the ventral nasal cavity. The relatively soft consistency of the mass meant that adequate curettage and removal could be performed. The majority of the pathological tissue was removed via the ventral approach; however, residual tissue was also removed via the nares. Incomplete resection was expected with this procedure. The patient ate within 24h after surgery. Serosanguinous nasal discharge was noted for several days; however, airflow and preoperative stertor had resolved.

Histopathological assessment of the samples obtained during surgery was performed at a second histopathology laboratory (SYNLAB VPG Histology), and revealed that the turbinate submucosa was variably expanded by multiple, often-small anastomosing trabeculae of reactive woven bone. These trabeculae were mostly not lined by osteoblasts and osteoclasts appeared to be rare. The intertrabecular space was filled with fibrous connective

tissue, which contained moderate numbers of spindle cells within an abundant collagenous matrix. These cells had indistinct cell borders and contained small amounts of eosinophilic cytoplasm. Nuclei were oval with stippled chromatin and inconspicuous nucleoli. Mitoses were fewer than 1 in 10 high-power fields. In the periphery of the examined biopsy sections, frequently a rim of more mature bone was present. These observations, in addition to the CT findings, confirmed the suspicion of fibrous dysplasia. There was not a clean margin of excision, as expected at the time of surgery.

The patient was re-examined 2 weeks after surgery. The owners reported a short period of pseudoptialism that spontaneously resolved. A mild nasal discharge could also be observed. The patient remains alive 15 months post-procedure, with intermittent nasal discharge that responds to broad spectrum antibiotic treatment.

Discussion

This case describes an unusual nasal pathology in a cat. To our knowledge, there are no previous reports involving a non-neoplastic, non-inflammatory expansile feline nasal tumour. A similar case was described in a 3-year-old Welsh Terrier treated with a dorsal rhinotomy and mass removal leading to a complete resolution of the clinical signs without any recurrence 18 months later.¹⁷ However, the histopathological findings in that case were more consistent with osseous hyperplasia than fibrous dysplasia.

Differentiating benign PFOLs by histopathology alone is extremely difficult given the significant overlap in histological features; therefore, a diagnosis of PFOL should also take into consideration radiographic and clinical features.^{7,8,18} Soltero-Rivera et al⁹ reviewed 15 cases of canine oral masses initially diagnosed as OF, probable OF, FD or osteoma, and reported that the histological appearance of the PFOL in this case series (OF and FD) was similar among many specimens and often did not lead to a definitive diagnosis. Ultimately, final classification of a lesion as OF or FD is reported to rely on imaging demonstrating a well-circumscribed mass for OF vs ill-defined margins for FD, as described in the human literature.^{7,8,18} Sixty percent of the PFOLs evaluated by Soltero-Rivera et al⁹ needed reclassification after initial histological diagnosis following re-evaluation of biopsy samples in the light of the imaging results. This illustrates the importance of radiographic and clinical features when investigating PFOLs.

In humans, PFOLs share not only several clinical, radiological and histological similarities, but also have different behaviours, which are not reported in animals. OF, in particular the 'juvenile' histological subtype, may have a locally aggressive behaviour resulting in destruction of the adjacent structures, and a high risk for recurrence with incomplete removal.⁶

The gold standard of treatment for PFOLs, osteomas and LG-OSAs involving the jaw in dogs is removal with up to 2cm bone margins to maximise the likelihood of clean surgical margins and so minimise recurrence.^{10,12,13,18} In cases where complete excision is not possible, radiation therapy may be considered, but development of secondary malignancies has been reported in previously irradiated cases of human FD. Wide surgical resection was not considered in the present case owing to the lysis of the cribiform plate and the lower morbidity associated with an incomplete resection.

Conclusions

This case highlights the importance of collaboration between the pathologist, radiologist and clinician in evaluating benign PFOLs owing to their microscopic resemblance and differences to each other, as well as their variable appearance on imaging. Despite previous retrospective studies and re-examination of the histological samples, accurate classification remains a challenge.^{6,9} Fibrous dysplasia and ossifying fibroma should be considered as differential diagnoses for expansile nasal masses in cats, and surgical resection can be considered as a treatment option. Longer-term follow-up is required to predict prognosis.

Acknowledgements The authors would like to thank Dr Maya Esmans DMV, MRCVS, ECVDI for her contribution in the interpretation of the CT scan. They also thank Louise Best

DVM, primary care veterinarian, for keeping them updated about the cat's progress.

Conflict of interest The authors declared no potential conflicts of interest with respect to the research, authorship, and/or publication of this article.

Funding The authors received no financial support for the research, authorship, and/or publication of this article.

Ethical approval This work involved the use of non-experimental animals only (owned or unowned), and followed internationally recognised high standards ('best practice') of individual veterinary clinical patient care. Ethical approval from a committee was not necessarily required.

Informed consent Informed consent (either verbal or written) was obtained from the owner or legal custodian of all animal(s) described in this work for the procedure(s) undertaken. No animals or humans are individually identifiable within this publication, and therefore additional informed consent for publication was not required.

ORCID iD Melanie Dobromylskyj  <https://orcid.org/0000-0002-0781-5726>

References

- Levy JK and Ford RB. **Diseases of the upper respiratory tract.** In: Sherding RG (ed). *The cat: diseases and clinical management.* 2nd ed. Philadelphia, PA: WB Saunders Co, 1994, pp 947–978.
- Henderson SM, Bradley K, Day MJ, et al. **Investigation of nasal disease in the cat, retrospective study of 77 cases.** *J Feline Med Surg* 2004; 6: 245–257.
- Allen HS, Broussard J and Noone K. **Nasopharyngeal diseases in cats: a retrospective study of 53 cases (1991–1998).** *J Am Anim Hosp Assoc* 1999; 35: 457–461.
- Hunt GB, Perkins MC, Foster SF, et al. **Nasopharyngeal disorders of dogs and cats: a review and retrospective study.** *Compen Contin Educ Vet* 2002; 24: 184–199.
- Schoenborn WC, Wisner ER, Kass PP, et al. **Retrospective assessment of computed tomographic imaging of feline sinonasal disease in 62 cats.** *Vet Radiol Ultrasound* 2003; 44: 185–195.
- Ciniglio Appiani M, Verillaud B, Bresson D, et al. **Ossifying fibromas of the paranasal sinuses: diagnosis and management.** *Acta Otorhinolaryngol Ital* 2015; 35: 355–361.
- Alawi F. **Benign fibro-osseous diseases of the maxillofacial bones: a review and differential diagnosis.** *Am J Clin Pathol* 2002; 118 Suppl: S50–S70.
- Eversole R, Su L and ElMofty S. **Benign fibro-osseous lesions of the craniofacial complex: a review.** *Head Neck Pathol* 2008; 2: 177–202.
- Soltero-Rivera M, Engiles JB, Reiter AM, et al. **Benign and malignant proliferative fibro-osseous and osseous lesions of the oral cavity of dogs.** *Vet Pathol* 2015; 52: 894–902.
- Bordelon JT and Rochat MC. **Use of a titanium mesh for cranioplasty following radical rostral tentorial craniectomy to remove an ossifying fibroma in a dog.** *J Am Vet Med Assoc* 2007; 231: 1692–1695.

- 11 Carrig CB and Seawright AA. **A familial canine polyostotic fibrous dysplasia with subperiosteal cortical defects.** *J Small Anim Pract* 1969; 10: 397–405.
- 12 Fitzgerald W, Slocombe R and Caiafa A. **Fibrous dysplasia of mandibular bone in a dog.** *J Vet Dent* 2002; 19: 77–81.
- 13 Miller MA, Towle HAM, Heng HG, et al. **Mandibular ossifying fibroma in a dog.** *Vet Pathol* 2008; 45: 203–206.
- 14 Speltz MC, Pool RR and Hayden DW. **Pathology in practice.** *J Am Vet Med Assoc* 2009; 235: 1283–1285.
- 15 Whitten KA, Popielarczyk MM, Belote DA, et al. **Ossifying fibroma in a miniature rex rabbit (*Oryctolagus cuniculus*).** *Vet Pathol* 2006; 43: 62–64.
- 16 Wilson RB. **Monostotic fibrous dysplasia in a dog.** *Vet Pathol* 1989; 26: 449–450.
- 17 Rutherford S, Whitbread T and Ness M. **Idiopathic osseous hyperplasia of the nasal turbinates in a Welsh terrier.** *J Small Anim Pract* 2011; 52: 492–496.
- 18 Speight PM and Carlos R. **Maxillofacial fibro-osseous lesions.** *Curr Diagn Pathol* 2006; 12: 1–10.