



Primary duodenal plasmacytoma with associated primary (amyloid light-chain) amyloidosis in a cat

Authors: Tamura, Yu, Chambers, James K, Neo, Sakurako, Goto-Koshino, Yuko, Takagi, Satoshi, et al.

Source: Journal of Feline Medicine and Surgery Open Reports, 6(2)

Published By: SAGE Publishing

URL: <https://doi.org/10.1177/2055116920957194>

BioOne Complete (complete.BioOne.org) is a full-text database of 200 subscribed and open-access titles in the biological, ecological, and environmental sciences published by nonprofit societies, associations, museums, institutions, and presses.

Your use of this PDF, the BioOne Complete website, and all posted and associated content indicates your acceptance of BioOne's Terms of Use, available at www.bioone.org/terms-of-use.

Usage of BioOne Complete content is strictly limited to personal, educational, and non - commercial use. Commercial inquiries or rights and permissions requests should be directed to the individual publisher as copyright holder.

BioOne sees sustainable scholarly publishing as an inherently collaborative enterprise connecting authors, nonprofit publishers, academic institutions, research libraries, and research funders in the common goal of maximizing access to critical research.



Primary duodenal plasmacytoma with associated primary (amyloid light-chain) amyloidosis in a cat

Journal of Feline Medicine and Surgery Open Reports
1–7

© The Author(s) 2020

Article reuse guidelines:

sagepub.com/journals-permissions

DOI: 10.1177/2055116920957194

journals.sagepub.com/home/jfmsopenreports

This paper was handled and processed by the European Editorial Office (ISFM) for publication in *JFMS*



Yu Tamura^{1,2} , James K Chambers³, Sakurako Neo⁴, Yuko Goto-Koshino⁵, Satoshi Takagi⁶, Mizuho Uneyama³, Kazuyuki Uchida³ and Masaharu Hisasue²

Abstract

Case summary A 14-year-old spayed female American Shorthair cat was presented with weight loss and a palpable abdominal mass. Abdominal ultrasound and CT revealed a duodenal mass with suspected perforation and an enlarged jejunal lymph node. Cytological evaluation from a fine-needle aspiration of the abdominal mass displayed many atypical round cells, some with a small amount of light pink material at the cellular edge. The duodenal mass was surgically removed, and was diagnosed as a plasma cell tumour immunohistochemically positive for CD79 alpha, IgA and lambda immunoglobulin light chains. In addition, amyloidosis was detected. PCR to assess the antigen receptor rearrangement of the tumour cells showed a monoclonal rearrangement of the immunoglobulin heavy chain gene. Postoperatively, the cat received chemotherapy with cyclophosphamide and prednisolone. Owing to progressive enlargement of the jejunal lymph node, different chemotherapy protocols were used sequentially, namely chlorambucil, lomustine and L-asparaginase. However, the cat died 96 days after the initial diagnosis. Post-mortem examination confirmed systemic dissemination of tumour cells. The cause of death was considered to be a result of a complication of the tumour itself and associated amyloidosis.

Relevance and novel information This patient was diagnosed with a primary duodenal plasmacytoma, and primary (amyloid light-chain) amyloidosis. In cats, intestinal plasmacytoma is rarely reported and associated amyloidosis is an uncommon feature, when compared with humans. To our knowledge, this is the first clinical report of duodenal plasmacytoma in a cat. The present report shows that feline plasmacytomas should be included in the differential diagnosis of a duodenal mass.

Keywords: Chemotherapy; myeloma-related disorder; small intestine; amyloid deposition

Accepted: 22 July 2020

¹Veterinary Teaching Hospital, Azabu University, Kanagawa, Japan

²Laboratory of Small Animal Internal Medicine, School of Veterinary Medicine, Azabu University, Kanagawa, Japan

³Department of Veterinary Pathology, Graduate School of Agricultural and Life Science, Tokyo University, Tokyo, Japan

⁴Laboratory of Clinical Diagnosis, School of Veterinary Medicine, Azabu University, Kanagawa, Japan

⁵Laboratory of Molecular Diagnostics, Veterinary Medical Center, Tokyo University, Tokyo, Japan

⁶Laboratory of Small Animal Surgery, School of Veterinary Medicine, Azabu University, Kanagawa, Japan

Corresponding author:

Masaharu Hisasue DVM, PhD, Laboratory of Small Animal Internal Medicine, School of Veterinary Medicine, Azabu University, 1-17-71, Fuchinobe, Chuo-ku, Sagami-hara, Kanagawa 252-5201, Japan
Email: hisasue@azabu-u.ac.jp



Creative Commons Non Commercial CC BY-NC: This article is distributed under the terms of the Creative Commons

Attribution-NonCommercial 4.0 License (<https://creativecommons.org/licenses/by-nc/4.0/>) which permits non-commercial use, reproduction and distribution of the work without further permission provided the original work is attributed as specified on the SAGE and Open Access pages (<https://us.sagepub.com/en-us/nam/open-access-at-sage>).

Introduction

Myeloma-related disorders (MRDs) are infrequent diseases in cats,^{1–4} and are classified as multiple myeloma (MM), cutaneous extramedullary plasmacytoma (CEMP), non-CEMP (NCEMP), solitary plasmacytoma of the bone, IgM macroglobulinaemia (Waldenström macroglobulinaemia), immunoglobulin-secreting lymphoma and myeloma cell leukaemia.^{2,3} Feline NCEMP is generally reported to originate from the spleen,^{2,5} liver,² intracerebral tissue,⁶ intraocular tissue,⁷ orbital tissue,^{2,8} respiratory tract,^{9–11} subcutaneous tissue,⁴ oral cavity,^{5,12} mesentery tissue¹³ or stomach.¹⁴ There are few cases reporting pathological involvement of the intestine in feline MRD.³ However, to our knowledge, there have been no reports of clinical cases presenting with duodenal involvement.

Primary amyloid light-chain (AL) amyloidosis is a common feature in human plasma cell tumours.¹⁵ Similarly, tumour cells may produce large quantities of monoclonal cells in animals, typically lambda (λ) immunoglobulin light chain.¹¹ However, AL amyloidosis has only been published in six previous reports of feline plasmacytoma.^{7,9,11–13,16}

Here, we report a case of cat that developed primary duodenal plasmacytoma with AL amyloidosis. This is an uncommon location for feline plasmacytoma and the amyloid deposition associated with the tumour is rarely reported in cats, compared with humans.

Case description

A 14-year-old spayed female American Shorthair cat, weighing 2.8 kg, was presented at Azabu University Veterinary Teaching Hospital with a 6-month history of weight loss, vomiting, decreased activity and a palpable abdominal mass (day 0). Prior to the referral, the cat was treated with an elimination diet, metronidazole (15 mg/kg PO q12h [Flagyl; Shionogi]) and prednisolone (1–2 mg/kg SC [Prednisolone Injection KS; Kyoritsu Seiyaku]); however, the cat's clinical signs did not improve. Physical examination showed a body condition score of 3/9, with dehydration, pale mucous membranes and a mid-cranial abdominal firm and irregular mass (4 cm in size). Informed consent for all procedures was provided by the owner.

Haematological examination (XT-2000iv; Sysmex) showed neutrophilia (24,370 cells/ μ l; reference interval [RI] 2500–12,500 cells/ μ l) and mild regenerative anaemia (red blood cells $4.7 \times 10^6/\mu$ l [RI 5.5–10.0 $\times 10^6/\mu$ l]; haematocrit [Hct] 20% [RI 24–25%]; reticulocytes $122 \times 10^3/\mu$ l [RI $<50 \times 10^3/\mu$ l]). Feline leukaemia virus antigen and feline immunodeficiency virus antibody tests were both negative (SNAP FIV/FelV Combo Kit; IDEXX). The serum biochemistry panel (cobas 6000; Roche) revealed mild hypoproteinaemia (5.3 g/dl; RI 5.4–7.8 g/dl), hypoalbuminaemia (2.1 g/dl; RI 2.5–3.9 g/

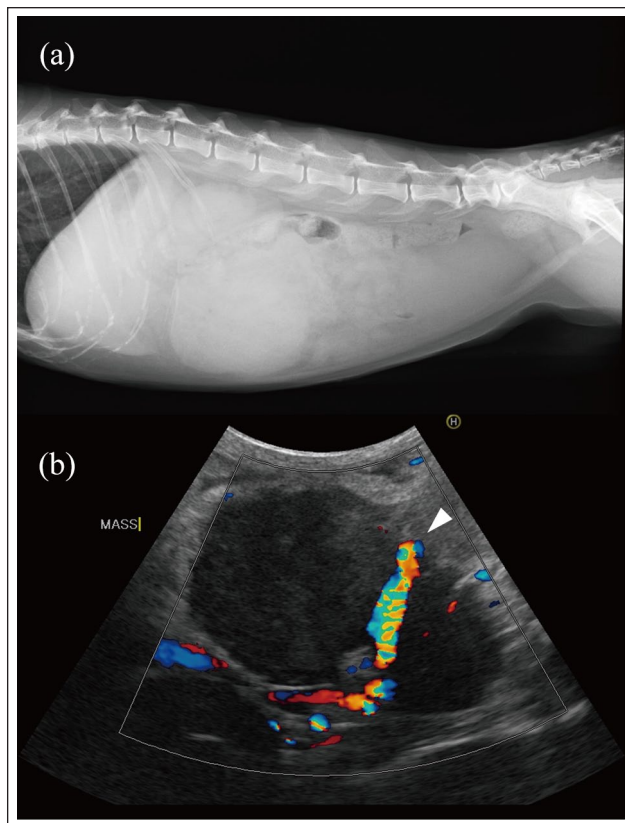


Figure 1 Right lateral abdominal radiograph and abdominal ultrasound image of a 14-year-old spayed female American Shorthair cat. (a) There is a large irregularly rounded soft tissue opaque mass in the right mid-ventral abdomen causing caudal and left caudolateral displacement of the small intestine. (b) A large irregularly rounded hypoechoic small intestinal mass with complete loss of wall layering and several gas foci within. The enlarged jejunal lymph node is contiguous to the mass and the portal vein (arrowhead) with no visible differentiation between the mass and the lymph node

dl) and increased serum amyloid A (SAA) (190.5 μ g/ml [RI 0–2.5 μ g/ml]; FUJIFILM VET Systems). No abnormalities were seen upon urine and faecal examination. Thoracic radiographs were unremarkable; however, abdominal radiographs revealed an irregularly rounded large soft tissue opaque mass (up to 6 cm in diameter) in the mid-ventral abdomen, slightly to the right of the midline, causing caudal and left caudolateral displacement of the small intestine (Figure 1a). The mass had a well-defined cranial margin and ill-defined caudal margin owing to decreased serosal margination. Abdominal ultrasonography (HI VISION Preirus; Hitachi) revealed a large irregularly rounded heterogeneously hypoechoic mass, measuring up to 4 cm in length, in the mid-ventral abdomen. The mass was connected to the intestinal loop with complete loss of layering and several hyperechoic foci with distal reverberation artefact within the centre of the mass. This mass was adjacent to the irregularly

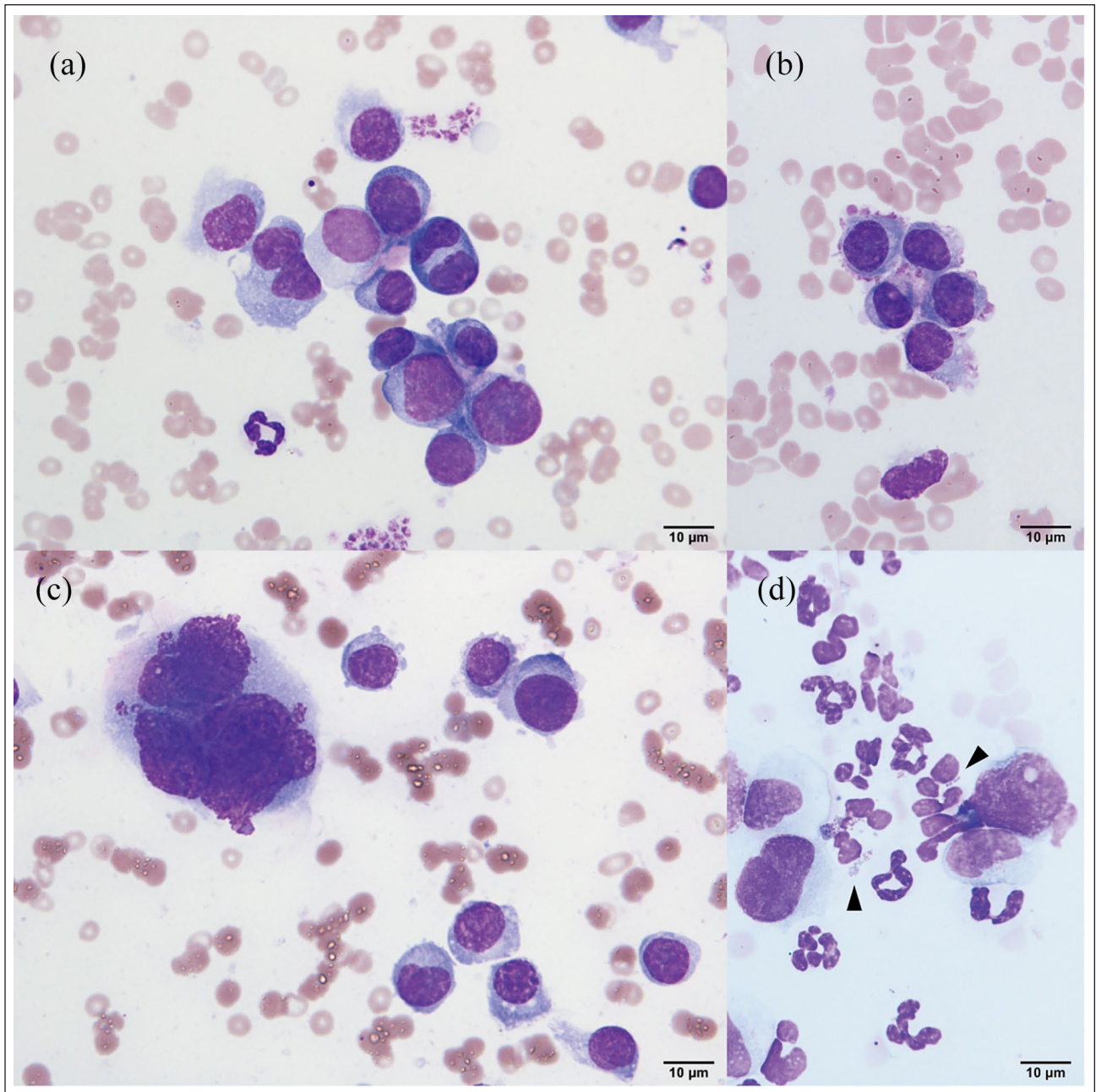


Figure 2 Cytological smear from the abdominal mass in the cat: Wright–Giemsa-stained slides. (a) There are many atypical round cells with eccentrically located round nuclei with eccentrically located round macronuclei, or binucleation with paranuclear clearing within the cytoplasm. (b) There are some atypical round cells with a small amount of extracellular pinkish material. (c) A few gigantic multinucleated cells are seen. (d) There are some neutrophils containing bacteria (arrowheads), which indicates the presence of gastrointestinal rupture

enlarged and hypoechoic jejunal lymph node and the portal vein without recognisable differentiation between the intestinal mass and the enlarged jejunal lymph nodes (Figure 1b). Peritoneal fat around the aforementioned mass was moderately hyperechoic.

On cytology, Wright–Giemsa-stained slides of the mass were highly cellular and contained many atypical round cells, as well as some degenerative neutrophils,

minimal macrophages, rare epithelioid macrophages and rare multinucleated giant cells (Figure 2). Atypical round cells were round-to-oval in shape, 10–30 µm in diameter and contained an eccentrically located round-to-oval nucleus, reticular-to-coarse chromatin and sometimes a prominent nucleoli. The cytoplasm was moderate in amount, basophilic in colour, with perinuclear halos and sometimes with a small amount of light pink

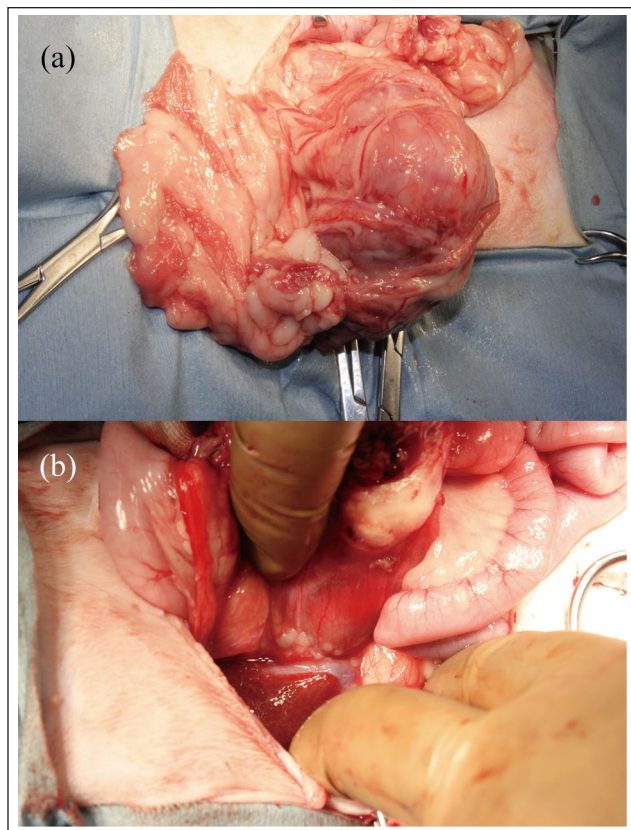


Figure 3 Surgical findings. (a) Duodenal mass and the enlarged lymph node are entangled with the greater omentum. (b) Intra-abdominal suspected metastatic lesions are seen

material at the cellular edge (Figure 2a,b). A moderate number of atypical cells were multinucleated with prominent nucleoli, and large and small nuclei. A few neutrophils contained a moderate number of mixed bacteria in their cytoplasm (Figure 2d).

CT (BrightSpeed Elite Pro; GE Healthcare) was performed the day after initial presentation (day 1) under general anaesthesia, and showed a duodenal mass with suspected intestinal perforation, in addition to an enlarged jejunal lymph node. There were no other abnormalities or other masses found during the CT examination. A transfusion of 38ml whole blood was performed because the patient was expected to experience further progression of hypoproteinaemia and anaemia after correction of dehydration and surgical blood loss. The duodenal mass was surgically removed under general anaesthesia (day 2). The mass had adhered to the greater omentum and to a small portion of the right limb of the pancreas, and although the mass was perforated there was no free abdominal fluid because the site of perforation was covered by the omentum (Figure 3a). After resection of the mass and a small portion of pancreas, a duodenal–jejunal anastomosis was created. It was found, however, that the jejunal lymph node was markedly enlarged, adhering to the portal vein and causing an

involution of the anterior mesenteric vessels. Therefore, resection of the jejunal lymph node was impossible. Moreover, there were already some suspected metastases on the serous surface of jejunum and on mesentery (Figure 3b). Six days after surgery, the enlarged jejunal lymph node was measured by abdominal ultrasonography as the baseline for future monitoring (measurements 3.5×2.9 cm).

Histopathological examination of the surgical specimen revealed infiltration of round neoplastic cells with abundant extracellular acidophilic material that was positive for Congo red. The tumour cells were immunohistochemically positive for CD79 alpha (α), IgA and λ immunoglobulin light chain, and were negative for CD20, IgG, IgM and kappa (κ) immunoglobulin light chain. Amyloid deposits were immunohistochemically positive for λ immunoglobulin light chain. Based on these findings, a duodenal plasmacytoma with AL amyloidosis was diagnosed. Moreover, PCR for antigen receptor rearrangement of the tumour cells was performed as previously described,¹⁷ and showed a monoclonal rearrangement of the immunoglobulin heavy chain gene. Three days after surgery, SAA ($2.9 \mu\text{g/ml}$; RI $0\text{--}2.5 \mu\text{g/ml}$) was almost normal. Upon suture removal on day 16, serum protein electrophoresis (FUJIFILM VET Systems) revealed a normal shape. Moreover, the albumin:globulin ratio (0.62; RI $0.6\text{--}1.32$), cobalamin ($>1000 \text{ ng/l}$ [RI $290\text{--}1000 \text{ ng/l}$]; IDEXX) and folate ($16.1 \mu\text{g/l}$ [RI $9.7\text{--}21.6 \mu\text{g/l}$]; IDEXX) were all within normal ranges.

Abdominal ultrasonography of the enlarged jejunal lymph node showed an increased size of 3.6×5.1 cm on day 16. Based on this finding, a chemotherapy regimen of cyclophosphamide (CPA [Endoxan; Shionogi]) at a dosage of 258 mg/m^2 (50 mg tablet/cat) PO q3 weeks ($86 \text{ mg/m}^2/\text{week}$) with prednisolone (1 mg/kg PO q24h [Predonine; Shionogi]) was started. After 3 weeks, however, the lymph node further enlarged to 4.3×5.7 cm, at which point the dosage of CPA was increased to 300 mg/m^2 IV q2 weeks ($150 \text{ mg/m}^2/\text{week}$). After 4 weeks of treatment with CPA (day 62), the lymph node had further enlarged (5.1×6.2 cm). CPA was then discontinued and a regimen of chlorambucil (CLB; [Leukeran; GlaxoSmithKline]) at a dosage of 20 mg/m^2 PO q2 weeks and spironolactone (2 mg/kg PO q12h [Aldactone; Pfizer]) because of malignant ascites (3.3 g/dl protein, 5000 nucleated cells/ μl with tumour cells, Hct 1.8%), was started. By day 72 the lymph node had further enlarged (5.5×6.7 cm) and 800 ml of free abdominal fluid was removed. CLB was discontinued and lomustine (CCNU; [CeeNU; Bristol Myers Squibb]) at a dosage of 50 mg/m^2 PO q3 weeks was instituted with furosemide (0.5 mg/kg PO q12h [Lasix; Nichi-Iko]) added as a diuretic. As the CCNU was ineffective (jejunal lymph node 7.0×7.5 cm), L-asparaginase (400 U/kg SC [Leunase; Kyowa Kirin])

was used with continuous intravenous infusion at a rate of 3–5 ml/kg/h of saline (Terumo) because the cat was dehydrated owing to the diuretics. At that time, SAA (<0.1 µg/ml; RI 0–2.5 µg/ml) was within the expected range. Three days after the L-asparaginase injection, the cat was discharged from the hospital with a once-daily subcutaneous injection of saline at home by a visiting veterinarian, owing to concerns about the cat's stress levels in the hospital. However, 3 days after discharge, on day 96, the cat died at home.

A post-mortem examination was performed. Upon necropsy, ascites, an enlarged jejunal lymph node (6.0 × 7.0 cm) and some whitish nodules of 2–3 mm on the serous surfaces of the liver, and numerous whitish miliary nodules on serous surfaces of the small intestine and large intestine were grossly observed. On histopathological examination, it was found that the tumour cells had infiltrated the stomach, small intestine, large intestine, liver, spleen, bladder, abdominal wall, diaphragm, mesentery, retroperitoneum, lymph nodes (cervical, thoracic, jejunal) and bone marrow. The tumour cells were large, round-shaped and with marked anisocytosis. The nuclei of the tumour cells showed marked anisokaryosis with dense and irregular nuclear membranes. Abundant extracellular acidophilic material, positive for Congo red, was also found in the all tumour tissues. The tumour cells were immunohistochemically positive for CD79α, IgA and λ immunoglobulin light chain, and negative for CD20, IgG, IgM and κ immunoglobulin light chain. Amyloid deposits were immunohistochemically positive for λ immunoglobulin light chain (Figure 4). Based on these findings, systemic dissemination of plasmacytoma with AL amyloidosis was diagnosed.

Discussion

The current report details a case of feline duodenal plasmacytoma with systemic metastasis and associated AL amyloidosis, which is an extremely rare disease in cats. The current case is considered to be NCEMP derived from the duodenum. Of the reported cases of feline NCEMP, the cats were usually of an older age and mainly American Shorthair and European Shorthair, as in this case.^{4–14}

Other differential diagnoses were lymphoplasmacytic lymphoma (LPL) and MM. Previously, a case of feline cutaneous LPL with systemic metastasis has been reported in Japan.¹⁸ Histopathologically, LPL is a neoplasm composed of small B lymphocytes mixed with plasmacytoid lymphocytes and plasma cells, whereas a plasma cell tumour is a neoplasm of plasma cells. In the current case, most of the tumour cells showed a plasmacytic phenotype and produced AL amyloid; thus, the tumour was diagnosed as a plasmacytoma. MM is also possible as plasma cells had invaded into bone marrow as found on the

post-mortem examination, even though the ante-mortem diagnostic criteria of MM, including monoclonal gammopathy, osteolysis and proteinuria, were not seen.¹⁹ The limitation of this case is that MM cannot be completely ruled out because protein electrophoresis and bone marrow evaluation were not performed prior to surgery.

The prognosis for feline NCEMP is described as poor to guarded (0.5–13 months), which is similar to what was seen in this case; the cat died 96 days after diagnosis, despite treatment.^{4,6–8,11,14} A combination of CPA and corticosteroids is recommended as the first-line therapy for cats with MRD.¹ We started with a lower dose of CPA than in a previous study owing to safety concerns regarding the side effects, although the median dose intensity was reported to be 168 mg/m²/week.¹ Then, we changed chemotherapy from CPA first to CLB and then to CCNU. However, CPA was considered the most effective of these chemotherapies. Recently, the recommended dosage for single agent CPA in combination with prednisolone in cats with cancer was reported to be 460 mg/m² q3 weeks (153 mg/m²/week).²⁰ Therefore, we should have used a higher initial dose of CPA. Although melphalan is one of the treatments used in plasma cell tumours, it was decided not to use this medication owing to reported increased side effects than CPA in cats with MRD.¹ Mass size was slightly decreased after administration of L-asparaginase; however, the response was stable disease (<30% reduction in tumour maximum diameter). Further studies will be required to improve the prescribed therapeutic regimen in feline NCEMP.

In humans and animals, amyloidosis is categorised as primary (AL) or secondary (amyloid A [AA]), depending on the pathogenesis.^{11,15} AA amyloidosis is more common in animals, especially in cats, and is caused by the deposition of fragments of the circulating SAA due to chronic inflammation or infection.^{11,12,15} However, the amyloidosis in this case was categorised as AL as there was deposition of λ immunoglobulin light chain and normal SAA levels after surgery. AL amyloidosis has rarely been reported in cats. In these reports, amyloid deposits of the intraocular, respiratory organs, skin, oral cavity, mesentery, lymph nodes, liver and spleen were all immunohistochemically positive for λ immunoglobulin light chain, which is seen in intra-tumour cells, whereas an atypical case was reported with intra-histiocytic amyloid deposits.^{7,9,11–13,16}

Conclusions

This case was diagnosed as primary duodenal plasmacytoma with systemic metastasis and associated amyloidosis. This is the first reported atypical clinical case, and the clinical behaviour was aggressive. Chemotherapies, including CPA, CLB, CCNU and L-asparaginase, did not

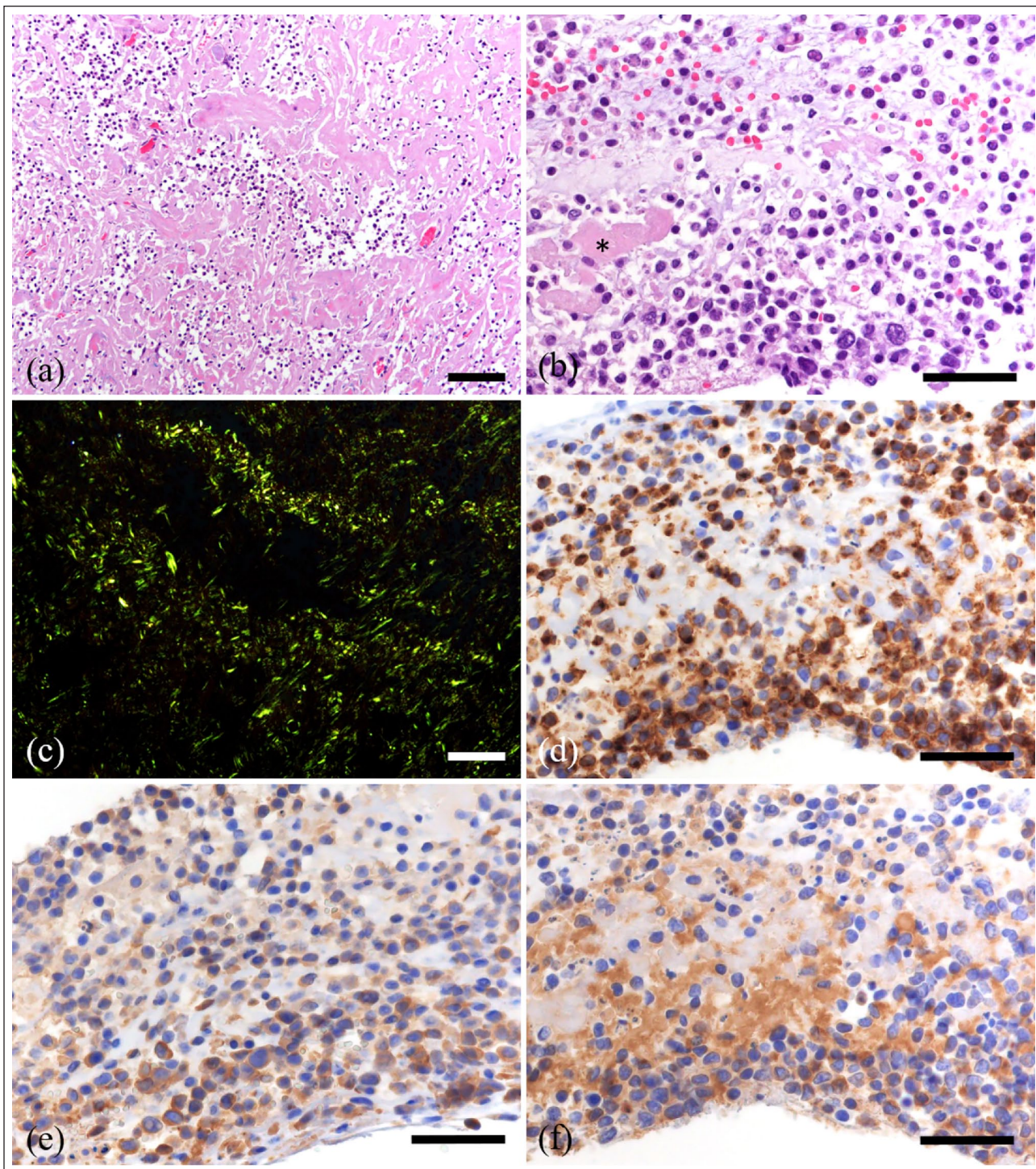


Figure 4 Histopathological findings of the tumour. (a) Tumour cells infiltrating the diaphragm with abundant extracellular eosinophilic material. Haematoxylin and eosin staining, bar = 100µm. (b) Higher magnification of tumour cells. Atypical round cells with anisocytosis and anisokaryosis infiltrate the liver. Extracellular eosinophilic material (asterisk). Haematoxylin and eosin staining, bar = 50µm. (c) Extracellular eosinophilic material showed green birefringence under polarised light microscopy. Diaphragm, Congo red staining, bar = 100µm. (d) Tumour cells were positive for CD79 alpha. Liver, immunohistochemistry for CD79 alpha, bar = 50µm. (e) Tumour cells were positive for IgA. Liver, immunohistochemistry for IgA, bar = 50µm. (f) Tumour cells and extracellular amyloid deposits were positive for lambda light chain. Liver, immunohistochemistry for lambda light chain, bar = 50µm

contribute to remission and the prognosis was poor. Although feline duodenal plasmacytoma and associated amyloidosis are thought to be rare, they should be included in the differential diagnosis for a duodenal mass in cats.

Acknowledgements The authors would like to thank Dr Taiki Yokoyama (Azabu University) for performing the CT scans; Drs Eiichi Kanai and Asaka Sato (Azabu University) for performing the surgery; Drs Ayumi Sumi and Tetsuo Omachi (Patho Labo) for performing the surgical pathology; Dr Hiro-taka Igarashi (Azabu University) for the technical support with PCR for antigen receptor rearrangement; and members of the Department of Veterinary Pathology (Tokyo University) for performing the post-mortem examination of this cat. We would like to thank Editage (www.editage.com) for the English-language editing.

Conflict of interest The authors declared no potential conflicts of interest with respect to the research, authorship, and/or publication of this article.

Funding The authors received no financial support for the research, authorship, and/or publication of this article.

Ethical approval This work involved the use of non-experimental animals only (including owned or unowned animals and data from prospective or retrospective studies). Established internationally recognised high standards ('best practice') of individual veterinary clinical patient care were followed. Ethical approval from a committee was therefore not necessarily required.

Informed consent Informed consent (either verbal or written) was obtained from the owner or legal custodian of all animal(s) described in this work (either experimental or non-experimental animals) for the procedure(s) undertaken (either prospective or retrospective studies). For any animals or humans individually identifiable within this publication, informed consent for their use in the publication was obtained from the people involved.

ORCID iD Yu Tamura  <https://orcid.org/0000-0003-0624-9037>

References

- Cannon CM, Knudson C and Borgatti A. **Clinical signs, treatment, and outcome in cats with myeloma-related disorder receiving systemic therapy.** *J Am Anim Hosp Assoc* 2015; 51: 239–248.
- Mellor PJ, Haugland S, Murphy S, et al. **Myeloma-related disorders in cats commonly present as extramedullary neoplasms in contrast to myeloma in human patients: 24 cases with clinical follow-up.** *J Vet Intern Med* 2006; 20: 1376–1383.
- Mellor PJ, Haugland S, Smith KC, et al. **Histopathologic, immunohistochemical, and cytologic analysis of feline myeloma-related disorders: further evidence for primary extramedullary development in the cat.** *Vet Pathol* 2008; 45: 159–173.
- Igase M, Shimokawa Miyama T, Kambayashi S, et al. **Bimodal immunoglobulin A gammopathy in a cat with feline myeloma-related disorders.** *J Vet Med Sci* 2016; 78: 691–695.
- Mikiewicz M, Otrocka-Domagala I, Paździor-Czapula K, et al. **Morphology and immunoreactivity of canine and feline extramedullary plasmacytomas.** *Pol J Vet Sci* 2016; 19: 345–352.
- Greenberg MJ, Schatzberg SJ, deLahunta A, et al. **Intracerebral plasma cell tumor in a cat: a case report and literature review.** *J Vet Intern Med* 2004; 18: 581–585.
- Kershaw O, Linek J, Linke RP, et al. **Intraocular ALA amyloidoma with plasma cell neoplasia in a cat.** *Vet Ophthalmol* 2011; 14: 88–92.
- Ward DA, McEntee MF and Weddle DL. **Orbital plasmacytoma in a cat.** *J Small Anim Pract* 1997; 38: 576–578.
- Platz SJ, Breuer W, Geisel O, et al. **Identification of lambda light chain amyloid in eight canine and two feline extramedullary plasmacytomas.** *J Comp Pathol* 1997; 116: 45–54.
- Schöniger S, Bridger N, Allenspach K, et al. **Sinonasal plasmacytoma in a cat.** *J Vet Diagn Invest* 2007; 19: 573–577.
- Sykes SE, Byfield V, Sullivan L, et al. **Feline respiratory extramedullary plasmacytoma with lymph node metastasis and intrahistiocytic amyloid.** *J Comp Pathol* 2017; 156: 173–177.
- Majzoub M, Breuer W, Platz SJ, et al. **Histopathologic and immunophenotypic characterization of extramedullary plasmacytomas in nine cats.** *Vet Pathol* 2003; 40: 249–253.
- Rowland PH and Linke RP. **Immunohistochemical characterization of lambda light-chain-derived amyloid in one feline and five canine plasma cell tumors.** *Vet Pathol* 1994; 31: 390–393.
- Zikes CD, Spielman B, Shapiro W, et al. **Gastric extramedullary plasmacytoma in a cat.** *J Vet Intern Med* 1998; 12: 381–383.
- Hokama A, Kishimoto K, Nakamoto M, et al. **Endoscopic and histopathological features of gastrointestinal amyloidosis.** *World J Gastrointest Endosc* 2011; 3: 157–161.
- Carothers MA, Johnson GC, DiBartola SP, et al. **Extramedullary plasmacytoma and immunoglobulin-associated amyloidosis in a cat.** *J Am Vet Med Assoc* 1989; 195: 1593–1597.
- Mochizuki H, Nakamura K, Sato H, et al. **Multiplex PCR and Genescan analysis to detect immunoglobulin heavy chain gene rearrangement in feline B-cell neoplasms.** *Vet Immunol Immunopathol* 2011; 143: 38–45.
- Kagawa Y, Yamashita T, Maetani S, et al. **Cutaneous lymphoplasmacytic lymphoma with systemic metastasis in a cat.** *J Vet Med Sci* 2011; 73: 1221–1224.
- Patel RT, Caceres A, French AF, et al. **Multiple myeloma in 16 cats: a retrospective study.** *Vet Clin Pathol* 2005; 34: 341–352.
- Moore AS, Frimberger AE and Chan CM. **Dosage escalation of intravenous cyclophosphamide in cats with cancer.** *Vet J* 2018; 242: 39–43.