



Acquired left-to-right shunting through a valve-incompetent foramen ovale in a cat with hypertrophic cardiomyopathy and congestive heart failure

Authors: Winter, Randolph L, Jennings, Ryan N, Cronin, James P, Rhinehart, Jaylyn D, and Schober, Karsten E

Source: Journal of Feline Medicine and Surgery Open Reports, 6(2)

Published By: SAGE Publishing

URL: <https://doi.org/10.1177/2055116920959607>

BioOne Complete (complete.BioOne.org) is a full-text database of 200 subscribed and open-access titles in the biological, ecological, and environmental sciences published by nonprofit societies, associations, museums, institutions, and presses.

Your use of this PDF, the BioOne Complete website, and all posted and associated content indicates your acceptance of BioOne's Terms of Use, available at www.bioone.org/terms-of-use.

Usage of BioOne Complete content is strictly limited to personal, educational, and non - commercial use. Commercial inquiries or rights and permissions requests should be directed to the individual publisher as copyright holder.

BioOne sees sustainable scholarly publishing as an inherently collaborative enterprise connecting authors, nonprofit publishers, academic institutions, research libraries, and research funders in the common goal of maximizing access to critical research.



Acquired left-to-right shunting through a valve-incompetent foramen ovale in a cat with hypertrophic cardiomyopathy and congestive heart failure

Journal of Feline Medicine and Surgery Open Reports
1–5

© The Author(s) 2020

Article reuse guidelines:

sagepub.com/journals-permissions

DOI: 10.1177/2055116920959607

journals.sagepub.com/home/jfmsopenreports

This paper was handled and processed by the American Editorial Office (AAFP) for publication in *JFMS*



Randolph L Winter¹, Ryan N Jennings², James P Cronin², Jaylyn D Rhinehart¹ and Karsten E Schober¹

Abstract

Case summary An 8-year-old spayed female domestic shorthair cat was presented for a recheck evaluation of hypertrophic cardiomyopathy and chronic kidney disease. Three years prior to presentation, the patient was diagnosed with obstructive hypertrophic cardiomyopathy and started on atenolol. The left ventricular outflow tract obstruction subsequently resolved. Biochemical analysis a week prior to presentation demonstrated severe azotemia. Transthoracic echocardiograph revealed pericardial effusion, pleural effusion, severe left ventricular concentric hypertrophy, severe left atrial enlargement and continuous left-to-right flow through the interatrial septum near the fossa ovalis. The patient was euthanized owing to poor prognosis, and gross examination at necropsy revealed a valve-incompetent patent foramen ovale secondary to severe left atrial dilation.

Relevance and novel information To our knowledge, this is the first report of an acquired left-to-right shunt through a valve-incompetent foramen ovale in a cat with hypertrophic cardiomyopathy. Severe left atrial dilation was suspected to cause interatrial shunting through the valve-incompetent foramen ovale, and this finding may be relevant to echocardiographic evaluations in other cats.

Keywords: Hypertrophic cardiomyopathy; left atrium; shunt; patent foramen ovale

Accepted: 22 August 2020

Introduction

The valve of the foramen ovale is the derivative of the embryonic septum primum and overlaps the muscular rim of the atrial septum, the derivative of the embryonic septum secundum.¹ When this muscular rim is formed correctly and the valve of the foramen ovale is large enough, there is overlap of these tissues which prevents blood from moving from the left to the right atrium.^{1,2} Hemodynamic changes that occur immediately after birth include decreased pulmonary vascular resistance and increased pulmonary venous return to the left atrium (LA), ultimately establishing the LA as the atrial chamber with higher pressure.³ This provides a functional closing of the patent foramen ovale (PFO) as this valve is pushed against the muscular rim of the foramen

ovale located on the right atrial aspect of the interatrial septum (IAS). These tissues may form an adhesion and thus permanently close. If these tissues do not fuse, then a free margin of this valve may exist through which there

¹Department of Veterinary Clinical Sciences, College of Veterinary Medicine, The Ohio State University, Columbus, OH, USA

²Department of Veterinary Biosciences, College of Veterinary Medicine, The Ohio State University, Columbus, OH, USA

Corresponding author:

Randolph L Winter DVM, PhD, DACVIM (Cardiology), Department of Veterinary Clinical Sciences, College of Veterinary Medicine, The Ohio State University, 601 Vernon L Tharp Street, Columbus, OH 43220, USA

Email: winter.159@osu.edu



Creative Commons Non Commercial CC BY-NC: This article is distributed under the terms of the Creative Commons

Attribution-NonCommercial 4.0 License (<https://creativecommons.org/licenses/by-nc/4.0/>) which permits non-commercial use, reproduction and distribution of the work without further permission provided the original work is attributed as specified on the SAGE and Open Access pages (<https://us.sagepub.com/en-us/nam/open-access-at-sage>).

is probe patency, sometimes referred to as a valve-competent foramen ovale.²⁻⁴

With atrial enlargement and stretching of the atrial walls, the valve of the foramen ovale is pulled such that a patent communication is established, called a valve-incompetent PFO.²⁻⁴ In veterinary medicine, a commonly observed example of this occurs in dogs with pulmonary valve stenosis and secondary right atrial pressure elevation and chamber enlargement.^{5,6} This has also been reported in human infants with a left-to-right shunting patent ductus arteriosus, with the presence of a valve-incompetent foramen ovale being associated with a relatively larger ductal shunt.⁴ To our knowledge, this is the first report of an acquired interatrial shunt in a cat with a histologically normal IAS.

Case description

An 8-year-old spayed female domestic shorthair cat weighing 3.8 kg was presented to The Ohio State University Veterinary Medical Center for a recheck evaluation of previously diagnosed cardiomyopathy and chronic kidney disease (CKD). The patient was first evaluated 3 years prior for a newly auscultated heart murmur, and transthoracic echocardiography at that time identified obstructive hypertrophic cardiomyopathy (HCM) characterized by moderate left ventricular (LV) concentric hypertrophy, moderate dynamic LV outflow tract obstruction owing to systolic anterior motion of the mitral valve and a normal LA size. At that time atenolol (1.2 mg/kg PO q12h) was prescribed, and shortly after this was initiated, the patient was reported as having an improved energy level. Subsequent annual recheck evaluations revealed a resolution of the dynamic outflow tract obstruction, static LV concentric hypertrophy and mild LA enlargement. The previously diagnosed CKD had been monitored by the referring veterinarian and treated with aluminum hydroxide (100 mg/kg PO q8h).

A week prior to presentation at Ohio State, the cat developed anorexia and was evaluated by the referring veterinarian. At that time, a serum biochemical analysis revealed stage 4 CKD based on the International Renal Interest Society staging guidelines: severe elevation of serum blood urea nitrogen (111 mg/dl; reference interval [RI] 10–27 mg/dl); severe elevation of serum creatinine (7.4 mg/dl; RI 0.4–1.3 mg/dl); and moderate hyperphosphatemia (8.5 mg/dl; RI 2.2–6.3 mg/dl). Mildly decreased red blood cell count ($6.43 \times 10^{12}/l$; RI 7.12 – $11.46 \times 10^{12}/l$) and hemoglobin concentration (9.5 g/dl; RI 10.3–16.2 g/dl) were observed on a complete blood count.

Upon physical examination, the heart rate was 140 beats per min and a grade II/VI left parasternal systolic heart murmur was auscultated. The respiratory rate was 40 breaths per min and thoracic auscultation revealed normal bronchial sounds bilaterally. Muscle wasting was appreciated and the patient had a body condition score of 3/9. The cat's weight had decreased by roughly 25%, compared with the previous examination. The remainder of the physical examination was unremarkable. Systemic systolic blood pressure measured with Doppler was 95 mmHg.

Transthoracic echocardiography revealed severe LV concentric hypertrophy (Figure 1a), with a LV posterior wall thickness at end diastole of 9.7 mm measured from two-dimensional images.⁷ Severe LA enlargement was evident in both long- and short-axis views. LA diameter measured as maximum septal-to-free wall dimension from the right parasternal long-axis view was 26 mm (normal <16 mm).⁸ The ratio of LA to aortic diameter from the right parasternal short axis view was 3.1 (normal <1.4).⁹ Spontaneous echocardiographic contrast was observed in the left auricle. There was a moderate amount of eccentric mitral regurgitation directed toward the IAS (see Video 1 in the supplementary material). Transaortic velocities were considered normal (average

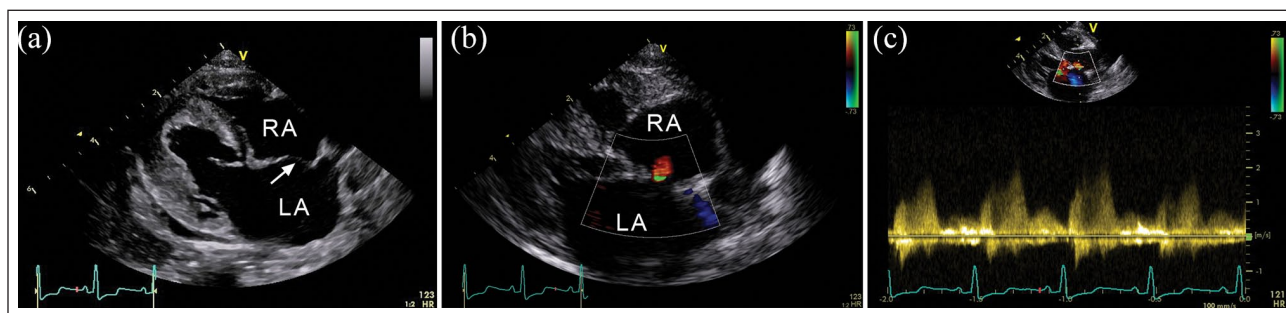


Figure 1 (a) Two-dimensional echocardiographic image from the right parasternal long-axis view demonstrating severe left ventricular concentric hypertrophy, moderate right atrial (RA) enlargement, severe left atrial (LA) enlargement and bowing (arrow) of the interatrial septum (IAS) toward the RA. Pericardial and pleural effusion are also observed. (b) Two-dimensional and color Doppler echocardiographic image from the right parasternal long-axis view demonstrating diastolic, left-to-right flow across the atrial septum. (c) Continuous wave Doppler recording of the left-to-right flow across the IAS demonstrating systolic and diastolic shunt flow

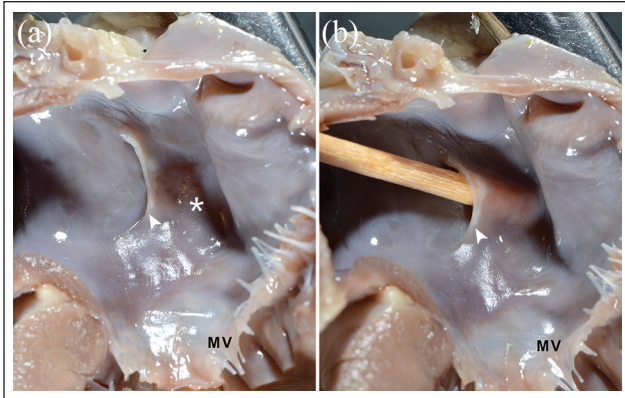


Figure 2 Gross anatomical images of the cut left atrium. (a) The focal, dark-red, roughened surface of the jet lesion (*) is observed. Note the prominent valve of the foramen ovale (▲). (b) The valve of the foramen ovale (▲) is identified, and a wooden applicator probe is observed entering the right atrium through the foramen ovale opening in the left atrium. MV = mitral valve

0.84 m/s),¹⁰ and there was no evidence of dynamic LV outflow tract obstruction. Subjectively, the right ventricle had mild concentric hypertrophy and there was moderate right atrial and ventricular enlargement. Transpulmonary velocities were normal (average of 0.65 m/s).¹⁰ The pulmonary trunk was mildly enlarged, and there was subjectively mild-to-moderate pulmonary insufficiency with velocities that suggested the presence of at least moderate pulmonary hypertension (3.3 m/s, estimated mean pulmonary artery pressure 44 mmHg). Mild pericardial and pleural effusion were identified, indicating the presence of congestive heart failure (CHF). The IAS persistently bowed toward the right atrium throughout the cardiac cycle (Figure 1a), indicating LA pressure overload. Based on two-dimensional images, the IAS appeared intact. However, there was blood continuously shunting from the left to right atrium at the apical aspect of the fossa ovalis as identified by color Doppler signals (Figure 1b; see Video 2 in the supplementary material) and spectral Doppler (Figure 1c). This shunt flow was not present on previous echocardiographic examinations.

Based on the concurrent severe CKD and HCM with CHF, the owner elected humane euthanasia with a subsequent necropsy examination. The presence of CHF warranted the addition of furosemide and an angiotensin-converting enzyme inhibitor, but these medications were considered likely to induce further kidney damage. Gross necropsy examination revealed serosanguineous effusion in the pericardial, pleural and peritoneal cavities (2 ml, 30 ml and 10 ml, respectively). The lungs were rubbery, expanded and oozed a red-tinged watery fluid on cut section. These findings indicated the presence of

pulmonary edema in the lungs, and the liver had marked congestion. Both kidneys were shrunken, nodular and firm, with many uroliths in each renal pelvis. The LV had marked concentric hypertrophy and the wet heart weighed 29 g (normal <19 g).¹¹ The LA was severely dilated, and a slit-like flap of tissue was observed in the mid IAS consistent with the valve of the foramen ovale (Figure 2a). A focal area of reddened, roughened endothelium was observed at the left atrial aspect of the IAS caudal to the valve of the foramen ovale consistent with a jet lesion. A defect in the IAS was not observed, but direct interatrial communication through the foramen ovale was confirmed with a probe (Figure 2b). This was consistent with a foramen ovale, which had been functionally closed until the LA dilation and stretch caused an opening in the IAS, known as valve-incompetent or probe-patent PFO. Histopathologic analysis of lungs revealed subacute, moderate alveolar histiocytosis and protein-rich edema, consistent with left-sided CHF. Within the left ventricle, there was moderate-to-marked interstitial fibrosis. The kidneys exhibited moderate-to-marked chronic interstitial nephritis and glomerulosclerosis, supportive of CKD.

Discussion

This report describes a left-to-right shunting, valve-incompetent PFO in a cat, an acquired interatrial communication not yet reported in this species. This cat was born with a valve-competent PFO but did not have interatrial shunting of blood prior to LA enlargement. Although the anatomic structures of the IAS did not change over time, their ability to allow interatrial communication was acquired with severe LA enlargement. Acquired interatrial communications are relatively rare but have been reported in dogs with myxomatous mitral valve disease.^{12–14} These reports describe damage to the IAS secondary to atrioventricular valve regurgitation. In one report, left-to-right shunting occurred in dogs with severe LA enlargement and a mitral regurgitant jet directed toward the IAS.¹³ These dogs subsequently developed clinically relevant pulmonary hypertension (PH) and right-sided CHF, in part due to shunt-induced right-sided volume overload.¹³ Another report described a right-to-left shunting acquired interatrial communication in a dog with severe tricuspid regurgitation and concurrent PH.¹⁴ That report also described damage to the IAS caused by the impact of the regurgitant jet. The fossa ovalis is typically thinner than other portions of the IAS and thus at risk for tearing when the tissue is damaged. Another report describes an atrial septal aneurysm with bidirectional shunting in a cat with severe right atrial enlargement and restrictive cardiomyopathy.¹⁵ The authors of that report described an atrial septal aneurysm where the entire IAS was abnormal, likely indicating underlying congenital pathology of the IAS.¹⁵ The cat

described in this report was born with a structurally normal IAS with a valve-competent PFO; however, interatrial shunting was not present prior to severe LA enlargement. The cat developed a valve-incompetent PFO and interatrial shunting only after severe LA enlargement, with serial echocardiographic examinations confirming the acquired etiology of this lesion.

The diagnosis of a valve-incompetent PFO in human infants with concurrent patent ductus arteriosus is followed by a period of clinical observation, rather than immediate intervention.^{4,16} In part, this recommendation is based on the finding that the foramen ovale may become valve-competent and therefore cease to be patent as left heart size reduction occurs post ductal closure.⁴ There is also evidence that small PFOs may spontaneously close over time.¹⁶ Acquired interatrial communications have been associated with important clinical sequelae such as PH, hypoxemia and respiratory distress.^{13–15,17,18} The patient in this report had HCM and progressive, severe LA enlargement, as well as PH. Dogs with severe LA enlargement and acquired interatrial communication have been reported to develop PH.¹³ However, PH occurs in dogs with severe LA enlargement even in the absence of an acquired interatrial communication.^{19,20} The velocity of blood flow through the interatrial shunt in the cat in this report suggested a pressure of around 20mmHg greater in the LA than in the right atrium. Whether this contributed to the volume overload of the right atrium and ventricle of this cat is unknown.

The cat of this report was diagnosed with PH, HCM and active left-sided CHF. A recent retrospective study described the presence of PH in 17% of cats with left-sided CHF, most of which had CHF secondary to cardiomyopathy.²¹ It is unknown if the acquired left-to-right shunting contributed to the PH in the cat in this report. A recent multicenter, longitudinal study of 1730 cats that were apparently healthy (n = 722) or had preclinical HCM with or without obstruction (n = 1008) reported on long-term outcomes and risk for CHF, arterial thromboembolism and cardiovascular death.²² The occurrence of CHF or arterial thromboembolism or both was 30.5% in cats diagnosed with preclinical HCM with or without obstruction.²² The cats that developed cardiovascular morbidity had a survival of just 1.3 ± 1.7 years.²² In that report, there was no mention of assessment for acquired interatrial shunts in cats with HCM, so the incidence of this finding and its possible contribution to cardiovascular morbidity cannot be determined at this time. However, a valve-incompetent PFO is likely a rare finding in the cat.

Conclusions

The cat in this report was diagnosed with a valve-incompetent PFO by color and spectral Doppler echocardiography. Although born with an anatomically

normal, valve-competent foramen ovale, the severe LA enlargement secondary to HCM induced the valve-incompetent state and subsequently an acquired left-to-right interatrial communication. Detailed evaluation of the IAS may be warranted in cats with similar atrial enlargement, as the diagnosis of an acquired interatrial communication is likely clinically important.

Acknowledgements The authors thank Marc Hardman for his assistance with the generation of figures for this manuscript.

Conflict of interest The authors declared no potential conflicts of interest with respect to the research, authorship, and/or publication of this article.

Funding The authors received no financial support with respect to the research, authorship, and/or publication of this article.

Ethical approval This work involved the use of non-experimental animals only (including owned or unowned animals and data from prospective or retrospective studies). Established internationally recognized high standards ('best practice') of individual veterinary clinical patient care were followed. Ethical approval from a committee was therefore not necessarily required.

Informed consent Informed consent (either verbal or written) was obtained from the owner or legal custodian of all animal(s) described in this work (either experimental or non-experimental animals) for the procedure(s) undertaken (either prospective or retrospective studies). No animals or humans are identifiable within this publication, and therefore additional informed consent for publication was not required.

Supplemental material The following files are available online:

Video 1: Two-dimensional and color Doppler echocardiographic video of the mitral regurgitant jet directed toward the interatrial septum.

Video 2: Two-dimensional and color Doppler echocardiographic video of blood flow through the acquired interatrial shunt.

References

- 1 Edwards WD. **Cardiac anatomy and examination of cardiac specimens.** In: Allen HD, Driscoll DJ, Shaddy RE, et al (eds). *Moss and Adams' heart disease in infants, children, and adolescents.* 7th ed. Philadelphia: PA: Lippincott Williams & Wilkins, 2008, pp 2–33.
- 2 Ho SY, McCarthy KP and Rigby ML. **Morphological features pertinent to interventional closure of patent oval foramen.** *J Intervent Cardiol* 2003; 16: 33–38.
- 3 Patten BM. **Developmental defects at the foramen ovale.** *Am J Pathol* 1938; 14: 162–169.
- 4 Zhou TF and Guntheroth WG. **Valve-incompetent foramen ovale in premature infants with ductus arteriosus: a Doppler echocardiographic study.** *J Am Coll Cardiol* 1987; 10: 193–199.

- 5 Fujii Y, Nishimoto Y, Sunahara H, et al. **Prevalence of patent foramen ovale with right-to-left shunting in dogs with pulmonic stenosis.** *J Vet Intern Med* 2012; 26: 183–185.
- 6 Hokanson CM, Rhinehart JD and Scansen BA. **Bidirectional flow across a perforate cor triatriatum dexter in a dog with concurrent pulmonary, tricuspid, and mitral valve dysplasia.** *J Vet Cardiol* 2019; 21: 93–97.
- 7 Häggström J, Luis Fuentes V and Wess G. **Screening for hypertrophic cardiomyopathy in cats.** *J Vet Cardiol* 2015; 17: S134–S149.
- 8 Schober KE and Chetboul V. **Echocardiographic evaluation of left ventricular diastolic function in cats: hemodynamic determinants and pattern recognition.** *J Vet Cardiol* 2015; 17: S102–S133.
- 9 Abbott JA and MacLean HN. **Two-dimensional echocardiographic assessment of the feline left atrium.** *J Vet Intern Med* 2006; 20: 111–119.
- 10 Petric AD, Rishniw M and Thomas WP. **Two-dimensionally-guided M-mode and pulsed wave Doppler echocardiographic evaluation of the ventricles of apparently healthy cats.** *J Vet Cardiol* 2012; 14: 423–430.
- 11 Kershaw O, Heblinski N, Lotz F, et al. **Diagnostic value of morphometry in feline hypertrophic cardiomyopathy.** *J Comp Path* 2012; 147: 73–83.
- 12 Buchanan JW and Kelly AM. **Endocardial splitting of the left atrium in the dog with hemorrhage and hemopericardium.** *J Am Vet Radiol Soc* 1964; 5: 29–39.
- 13 Peddle GD and Buchanan JW. **Acquired atrial septal defects secondary to rupture of the atrial septum in dogs with degenerative mitral valve disease.** *J Vet Cardiol* 2010; 12: 129–134.
- 14 Lake-Bakaar GA, Mok MY and Kittleson MD. **Fossa ovalis tear causing right to left shunting in a Cavalier King Charles Spaniel.** *J Vet Cardiol* 2010; 14: 541–545.
- 15 Nicolle AP, Chetboul V, Namba H, et al. **Echocardiographic and Doppler diagnosis: first case of atrial septal aneurysm in a cat.** *Vet Radiol Ultrasound* 2005; 46: 230–233.
- 16 Cantinotti M, Assanta N, Murzi B, et al. **Controversies in the definition and management of insignificant left-to-right shunts.** *Heart* 2014; 100: 200–205.
- 17 Baker JE, Stratmann G, Hoopes C, et al. **Profound hypoxemia resulting from shunting across an inadvertent atrial septal tear after left ventricular assist device placement.** *Anesth Analg* 2004; 98: 937–940.
- 18 Pagtakhan RD, Hartmann AF Jr, Goldring D, et al. **The valve-incompetent foramen ovale: a report on seven infants with left-to-right atrial shunt.** *J Pediatr* 1967; 71: 848–854.
- 19 Kelliham HB and Stepien RL. **Pulmonary hypertension in canine degenerative mitral valve disease.** *J Vet Cardiol* 2012; 14: 149–164.
- 20 Borgarelli M, Abbott J, Braz-Ruivo L, et al. **Prevalence and prognostic importance of pulmonary hypertension in dogs with myxomatous mitral valve disease.** *J Vet Intern Med* 2015; 29: 569–574.
- 21 Vezzosi T and Schober KE. **Doppler-derived echocardiographic evidence of pulmonary hypertension in cats with left-sided congestive heart failure.** *J Vet Cardiol* 2019; 23: 58–68.
- 22 Fox PR, Keene BW, Lamb K, et al. **International collaborative study to assess cardiovascular risk and evaluate long-term health in cats with preclinical hypertrophic cardiomyopathy and apparently healthy cats: the REVEAL study.** *J Vet Intern Med* 2018; 32: 930–943.