



## **Digoxin-specific antibody fragments for the treatment of suspected Nerium oleander toxicosis in a cat**

Authors: Galton, Aaron F, Granfone, Marcella C, and Caldwell, Dana J

Source: Journal of Feline Medicine and Surgery Open Reports, 6(2)

Published By: SAGE Publishing

URL: <https://doi.org/10.1177/2055116920969599>

---

BioOne Complete ([complete.BioOne.org](https://complete.BioOne.org)) is a full-text database of 200 subscribed and open-access titles in the biological, ecological, and environmental sciences published by nonprofit societies, associations, museums, institutions, and presses.

Your use of this PDF, the BioOne Complete website, and all posted and associated content indicates your acceptance of BioOne's Terms of Use, available at [www.bioone.org/terms-of-use](https://www.bioone.org/terms-of-use).

Usage of BioOne Complete content is strictly limited to personal, educational, and non - commercial use. Commercial inquiries or rights and permissions requests should be directed to the individual publisher as copyright holder.

---

BioOne sees sustainable scholarly publishing as an inherently collaborative enterprise connecting authors, nonprofit publishers, academic institutions, research libraries, and research funders in the common goal of maximizing access to critical research.



# Digoxin-specific antibody fragments for the treatment of suspected *Nerium oleander* toxicosis in a cat

Aaron F Galton , Marcella C Granfone and Dana J Caldwell

*Journal of Feline Medicine and Surgery Open Reports*  
1–5

© The Author(s) 2020

Article reuse guidelines:

sagepub.com/journals-permissions

DOI: 10.1177/2055116920969599

journals.sagepub.com/home/jfmsopenreports

This paper was handled and processed by the American Editorial Office (AAFP) for publication in *JFMS Open Reports*



## Abstract

**Case summary** A 6-year-old castrated male domestic shorthair cat presented for lethargy and gastrointestinal signs after possible exposure to *Nerium oleander* leaves. The cat developed a ventricular arrhythmia that responded positively to the administration of digoxin-specific antibody fragments. Underlying hypertrophic cardiomyopathy was also diagnosed after the development of congestive heart failure. Humane euthanasia was elected owing to a lack of significant response to continued therapy.

**Relevance and novel information** To our knowledge, this is the first report to describe the use of digoxin-specific antibody fragments in a cat. *Nerium oleander* toxicosis is associated with significant morbidity and mortality, and digoxin-specific antibody fragments have been used effectively in humans and animals. The development of cardiac necrosis may have contributed to worsening arrhythmias and highlights the importance of early intervention. The use of digoxin-specific antibody fragments for suspected *N oleander* toxicosis in a cat resulted in a rapid response and appeared to be well tolerated.

**Keywords:** Cardiac glycosides; Digibind; cardiotoxicity; cardiomyopathy

**Accepted:** 27 September 2020

## Introduction

Ingestion of the common oleander (*Nerium oleander*) plant can cause severe toxicosis, with numerous reports of poisoning in humans and veterinary species.<sup>1</sup> Cardiac glycosides, including oleandrin and digitoxigenin, are responsible for the plant's toxic effects.<sup>2</sup> Toxicosis can occur from ingestion of plant material, inhalation of smoke from a burning plant or ingestion of water in which the plant has been soaked.<sup>3</sup> All parts of the plant contain glycosides with the seeds and roots containing the highest percentage.<sup>2</sup> Clinical signs in dogs and cats include vomiting, diarrhea, ptialism, oral ulceration, cardiac arrhythmias, electrolyte abnormalities, hypotension and death (ASPCA Poison Control; AnTox Database). Digoxin-specific antibody fragments (dsFab) have been shown to be effective in humans and dogs for alleviating *N oleander*'s cardiotoxicity.<sup>4,5</sup> However, owing to the cost and availability of this product, reports of its use in veterinary medicine are limited. To our knowledge, this is the first report of the use of dsFab for presumed *N oleander* intoxication in a cat.

## Case description

A 6-year-old castrated male domestic shorthair cat was presented to an emergency hospital after a 24 h history of vomiting, diarrhea and lethargy. Thirty-six hours prior to presentation, the cat was outdoors while the owners were trimming *N oleander* bushes. While no ingestion of the plant was witnessed, the cat had a prior history of ingesting string as a kitten. Twelve hours later, vomiting and lethargy were observed. Diarrhea and mild facial swelling developed later that day. The cat was presented to the referring veterinarian the following day owing to persistent clinical signs. A heart rate of 156 beats per minute (bpm), a rectal temperature of 98.1°F (36.7°C)

Critical Care Department, Arizona Veterinary Emergency and Critical Care Center, Phoenix, AZ, USA

### Corresponding author:

Aaron F Galton BS, DVM, Arizona Veterinary Emergency and Critical Care Center, 86 West Juniper Ave Gilbert, AZ 85233, USA  
Email: aaron.galton@azervets.com



Creative Commons Non Commercial CC BY-NC: This article is distributed under the terms of the Creative Commons

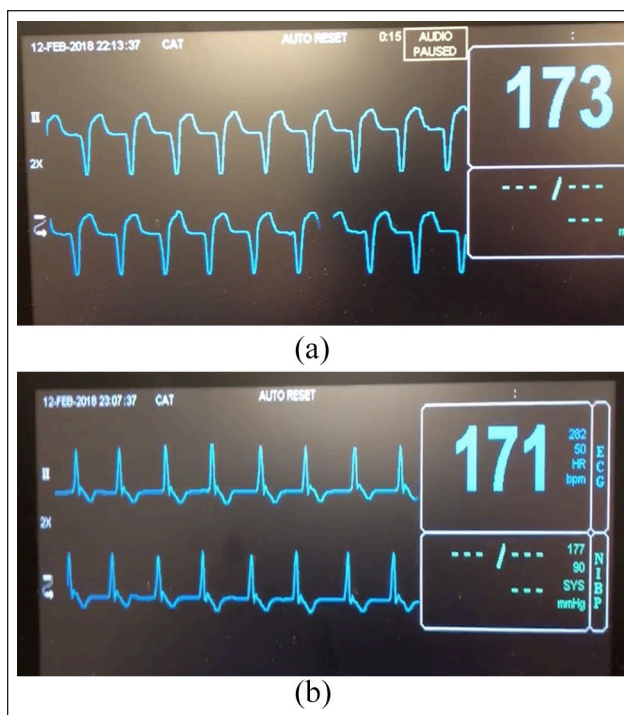
Attribution-NonCommercial 4.0 License (<https://creativecommons.org/licenses/by-nc/4.0/>) which permits non-commercial use, reproduction and distribution of the work without further permission provided the original work is attributed as specified on the SAGE and Open Access pages (<https://us.sagepub.com/en-us/nam/open-access-at-sage>).

and decreased skin turgor were noted, as well as an obtunded mentation and edema of the lips. Bloodwork revealed mild lymphopenia ( $0.69\text{ k}/\mu\text{l}$ ; reference interval [RI]  $0.92\text{--}6.88\text{ k}/\mu\text{l}$ ) and mild elevations in blood urea nitrogen (BUN;  $39\text{ mg}/\text{dl}$  [RI  $16\text{--}36\text{ mg}/\text{dl}$ ]) and alanine transaminase ( $247\text{ }\mu\text{l}$ ; RI  $12\text{--}130\text{ }\mu\text{l}$ ). Three-view abdominal radiographs evaluated by a board-certified radiologist showed mild splenomegaly but were otherwise unremarkable. Intravenous fluid therapy was initiated with 200ml of an isotonic, balanced crystalloid solution (Normosol-R; Abbott) over 6h and an injection of maropitant (Cerenia; Zoetis) was administered ( $1\text{ mg}/\text{kg}$  SC). No general improvement was noted; therefore, transfer to an intensive care hospital was advised.

On presentation, the cat was obtunded, hypothermic at  $98.8^{\circ}\text{F}$  ( $37.1^{\circ}\text{C}$ ) and laterally recumbent with an irregular cardiac rhythm and weak femoral pulses. Blood pressure via Doppler ultrasound was  $86\text{ mmHg}$ . Electrocardiography showed an arrhythmia with wide QRS complexes, no discernable P waves and a variable heart rate of  $140\text{--}175\text{ bpm}$ , suspected to be accelerated idioventricular rhythm (AIVR). The cat was tachypneic at 100 breaths per min with normal effort and lung sounds. Marked ptyalism, buccal ulceration and swelling of the lower lips was present. Evaluation of electrolytes revealed mild hyponatremia ( $144.7\text{ mmol}/\text{l}$ ; RI  $149\text{--}156\text{ mmol}/\text{l}$ ) and mild ionized hypermagnesemia ( $1.03\text{ mmol}/\text{l}$ ; RI  $0.43\text{--}0.7\text{ mmol}/\text{l}$ ); packed cell volume was 38% with total solids of  $6.0\text{ g}/\text{dl}$ .

The patient initially received two IV boluses of  $8\text{ ml}/\text{kg}$  each of a balanced, isotonic crystalloid (Plasma-Lyte A; Baxter) but remained hypotensive at  $72\text{ mmHg}$  via Doppler. A bolus of 2% lidocaine ( $0.34\text{ mg}/\text{kg}$  IV) was administered, followed by second bolus 10 mins later, and finally a continuous rate infusion (CRI) at  $20\text{ }\mu\text{g}/\text{kg}/\text{min}$  IV, but resulted in no change in the arrhythmia. Owing to continued hypotension, a synthetic colloid bolus (VetStarch; Zoetis) was administered ( $2.5\text{ ml}/\text{kg}$  IV), after which the Doppler blood pressure increased to  $94\text{ mmHg}$ . American Society for the Prevention of Cruelty to Animals (ASPCA) Poison Control was contacted, and treatment for *N oleander* toxicosis was recommended, based on history and clinical signs. An enema was performed with the goal of removing plant material from the colon; however, no obvious plant material was retrieved.

A blood sample submitted for analysis within 4h of admission showed a digoxin level of  $0.0\text{ ng}/\text{ml}$ . Despite this, dsFab (Digibind; GlaxoSmithKline) was administered owing to strong concern for *N oleander* poisoning and lack of response to anti-arrhythmic therapy. One vial of Digibind ( $38\text{ mg}$ ) was reconstituted with 4ml of sterile water and administered intravenously over 30mins. Prior to and during administration, the arrhythmia and hypotension persisted, with Doppler blood pressure measurements ranging from  $60\text{ mmHg}$  to  $78\text{ mmHg}$



**Figure 1** (a) ECG tracings prior to digoxin-specific antibody fragment (dsFab) infusion showing ventricular arrhythmia. (b) ECG tracings 15 mins after completion of dsFab infusion showing resolution of ventricular arrhythmia and possible conversion to sinus rhythm

(Figure 1a). Approximately 15 mins after completion of the dsFab infusion, resolution of the ventricular arrhythmia was observed with narrow QRS complexes and a heart rate of  $170\text{ bpm}$ ; however, P waves still could not be clearly identified on lead II electrocardiogram (ECG; Figure 1b). Repeat Doppler blood pressure was  $120\text{ mmHg}$  and the cat remained normotensive throughout hospitalization thereafter. Lidocaine was discontinued at this time. Re-evaluation of renal values 2h later demonstrated resolution of azotemia (BUN  $29\text{ mg}/\text{dl}$ ; RI  $18\text{--}34\text{ mg}/\text{dl}$ ). Despite normokalemia ( $3.58\text{ mmol}/\text{l}$ ; RI  $3.2\text{--}4.7\text{ mmol}/\text{l}$ ), potassium chloride was delivered as a CRI ( $0.3\text{ mEq}/\text{kg}/\text{h}$  IV) in order to avoid hypokalemia associated with dsFab administration.

Overnight, the patient continued to have a normal sinus rhythm on continuous ECG with heart rates between  $130$  and  $175\text{ bpm}$  but developed intermittent ventricular premature complexes. Despite normal thoracic auscultation, the respiratory rate increased from 40 to 70 breaths per min and the patient had gained 5% in body weight from admission. Although three-view thoracic radiographs at that time showed no abnormalities, the intravenous (IV) fluid rate was decreased from  $25\text{ ml}/\text{h}$  to  $15\text{ ml}/\text{h}$  owing to concern for early fluid overload. Over the next 6h, pulmonary crackles developed bilaterally. Repeat thoracic radiographs reviewed by a

board-certified radiologist showed patchy, interstitial pulmonary infiltrates and pulmonary venous congestion. Supplemental oxygen was provided and fluid therapy was discontinued. Furosemide (Lasix; Pfizer) was initiated with a 1 mg/kg IV bolus followed by a CRI of 0.5 mg/kg/h and was continued for 28 h (total of 15 mg/kg administered).

Echocardiography performed by a board-certified cardiologist the following morning revealed moderate, diffuse concentric hypertrophy of the left ventricle and moderate left atrial enlargement. No spontaneous echogenic contrast or left ventricular outflow obstruction were appreciated. Mild pleural and pericardial effusion were present. ECG during the echocardiogram displayed AIVR with multiform ventricular complexes and intermittent sinus rhythm. Based on these findings, the patient was diagnosed with congestive heart failure secondary to hypertrophic cardiomyopathy (HCM). Concurrent cardiac toxicity and arrhythmias from *N oleander* could not be excluded.

Throughout the day, the cat continued to have AIVR with periods of ventricular tachycardia. Lidocaine therapy was resumed but no improvement in arrhythmia was noted. Based on the worsening arrhythmia and continued signs of heart failure, additional dsFab (38 mg IV) was administered 20 h after the initial vial. Following completion, the patient converted to a normal sinus rhythm with heart rates ranging from 160 bpm to 180 bpm; however, the conversion only lasted 4–6 h, after which AIVR returned. Over the following 24 h, the patient remained dependent on supplemental oxygen. Periods of normal sinus rhythm were observed with heart rates of 190–210 bpm. Potassium chloride supplementation was discontinued after 24 h when the cat became hyperkalemic (5.69 mmol/l; RI 3.2–4.7 mmol/l). Progressive elevations in BUN (29–63 mg/dl; RI 18–34 mg/dl) and creatinine (1.0–2.0 mg/dl; RI 1.0–2.1 mg/dl) occurred, despite attempts at providing enteral water. Continued medical management was recommended; however, the owners ultimately elected humane euthanasia.

Necropsy performed by a board-certified pathologist revealed severe, acute, multifocal cardiac necrosis and mild-to-moderate HCM. The lungs contained severe, acute pulmonary edema and congestion. Hemorrhage was noted throughout the gastrointestinal tract and suspected plant material was present in the colon. Based on these findings, underlying HCM with superimposed cardiac necrosis was diagnosed. As analysis of the colon contents was not performed, definitive diagnosis of *N oleander* as the cause for cardiac necrosis could not be determined.

## Discussion

Glycosides exert their cardiotoxic effects via inhibition of the sodium–potassium (Na–K) ATPase pumps of cardiac

myocytes. This results in alterations in membrane potential and increased intracellular calcium concentrations, ultimately leading to arrhythmias and hemodynamic compromise. Hyperkalemia is frequently observed and can exacerbate the arrhythmias. Glycosides are also toxic to cardiac myocytes both directly, as the result of calcium overload, and indirectly via enhanced release of inflammatory mediators and free radical production.<sup>6,7</sup> As such, patients with pre-existing cardiac disease may be at even greater risk of cardiotoxicity.

Medical management for cardiac glycoside toxicosis focuses on decontamination, hemodynamic support, electrolyte correction and anti-arrhythmic therapies. Decontamination via emesis was not attempted based on the time frame since ingestion, and because the cat had already vomited multiple times and presented with obtunded mentation. Activated charcoal has been shown to bind cardiac glycosides and facilitate excretion; however, the risk of aspiration was considered to be too great for oral administration, although administration via orogastric tube could have been considered.<sup>8</sup>

IV fluids were administered for hypotension and suspected hypovolemia secondary to prolonged vomiting and diarrhea. Despite fluid resuscitation, the patient remained hypotensive, likely due to poor cardiac output from the ventricular arrhythmia and concurrent diastolic dysfunction. Focused cardiac ultrasound for evaluation of left atrial enlargement may have been helpful for determining if cardiogenic, rather than hypovolemic, shock was the cause of this patient's hypotension. Catecholamine therapy could have been implemented to address ongoing shock; however, the increase in afterload, myocardial oxygen consumption and pro-arrhythmic effects associated with adrenergic agonists may have been detrimental to this patient. Hypotension and hypothermia resolved only after administration of dsFab and correction of the arrhythmia. The use of crystalloids and synthetic colloids in the face of cardiac dysfunction likely contributed to the development of cardiogenic pulmonary edema, supported by echocardiography and thoracic radiographs. Differential diagnoses included non-cardiogenic pulmonary edema, acute respiratory distress syndrome and anaphylaxis associated with dsFab administration. Anaphylaxis can occur after exposure to a foreign protein, such as the ovine-derived antibody fragments present in dsFab, although the risk of anaphylaxis with dsFab is reduced owing to the removal of the more immunogenic Fc portion of the antibody.<sup>9</sup>

Hyperkalemia is common with glycoside toxicosis and can exacerbate arrhythmias and cardiac dysfunction.<sup>9</sup> This occurs as the result of inactivation of Na–K ATPase pumps, leading to increased extracellular potassium concentrations and alterations in membrane potential. The lack of initial hyperkalemia in this case could potentially be explained by potassium depletion from

prolonged vomiting and diarrhea prior to presentation. Hypokalemia may develop after dsFab administration as a result of the rapid reactivation of Na–K ATPase pumps, and has been associated with worsening arrhythmias due to decreased conduction and increased automaticity.<sup>9</sup> For this reason, potassium supplementation was provided, despite normokalemia. Eventually, the patient became hyperkalemic, with primary consideration given to over-supplementation or acute kidney injury secondary to glycoside toxicity, diuretic use or decreased cardiac output from congestive heart failure.

Lidocaine has been used in people to attempt to correct glycoside-induced arrhythmias.<sup>7,9</sup> The initial ECG was suspected to be AIVR; however, a transient right bundle branch block was also possible. Differentials for the converted rhythm include a sinus rhythm with lack of discernable P waves on the selected lead, atrial fibrillation or a junctional tachycardia with P waves superimposed over the ST segment. A six-lead ECG would have helped elucidate the cardiac rhythm. The lack of response to lidocaine may reflect the presence of bound toxin, which would explain the rapid improvement observed with dsFab. If the arrhythmia were secondary to HCM alone, then no response to dsFab would be expected. Cats are more sensitive than dogs to lidocaine toxicity, which can result in seizures and methemoglobinemia, and should only be used after careful consideration of the risks.<sup>10</sup> As such, a lower dose was used, which may have decreased its effectiveness.

In humans, dsFab is routinely used for severe glycoside toxicosis and may result in resolution of arrhythmias and hyperkalemia.<sup>4</sup> Digibind binds free glycoside molecules, as well as those bound to the Na–K ATPase pumps, owing to a higher affinity of the glycoside molecules for the antibody fragments. Inactivation of the glycoside molecules results in reversal of the toxic effects within 20–60 mins, with an elimination half-life of 15–20 h.<sup>9</sup> Adverse effects reported include rare allergic reactions and hypokalemia secondary to rapid reactivation of the Na–K ATPase pumps (DEA; Digibind package insert). Ideally, the dsFab dose would be determined based on serum digoxin levels, although it is unclear how well digoxin levels correlate with other glycosides. Since the ingested quantity was unknown, one vial was delivered initially. Both vials were obtained from a human hospital for US\$3200 each, but additional vials were ultimately cost-prohibitive for this patient.

While no studies have been performed using dsFab in cats, the use of dsFab as a first-line therapy in humans has been shown to result in improved survival over anti-arrhythmic therapy and cardiac pacing.<sup>5</sup> Case reports have also described the successful use of dsFab in dogs for treatment of severe digoxin and *N oleander* toxicoses.<sup>11,12</sup> A canine model of experimentally induced *N oleander* poisoning demonstrated rapid conversion to sinus rhythm and improved survival in the dsFab-treated group.<sup>13</sup> This

patient's rapid and consistent rhythm conversion after Digibind may suggest that the arrhythmia responded positively to its use. The cat's relative bradycardia following the initial vial is likely a consequence of ongoing negative chronotropic effects of the glycoside, which may suggest that additional Digibind was indicated sooner. The shorter duration of response to the second vial likely reflects the extent of cardiac necrosis present at that point, which may also explain the challenge in resolving this cat's congestive heart failure. Ongoing hypoxemia may also have contributed to cardiac dysfunction, rendering the second vial less effective.

Definitive diagnosis can be challenging due to variable cross-reactivity between digoxin assays and other glycosides. Oleandrin can be identified in blood via liquid chromatography–mass spectrometry, but this assay was not readily available at the time.<sup>14</sup> The chemiluminescent immunoassay used for this patient (iDigoxin; Abbott Laboratories) has 0.3% cross reactivity for digitoxigenin, which may explain the lack of detectable digoxin-equivalent levels. Information is lacking regarding the sensitivity of these assays for dogs and cats, and it is possible that the cat's serum levels were below the limit of detection. Additionally, serum levels may be highly variable owing to redistribution, and clinical signs are often delayed compared with peak blood levels.<sup>9</sup> Measurement of cardiac troponin I may have been helpful in identifying ischemic injury to the cardiomyocytes but is non-specific, and distinction between ischemia from cardiac toxicity, prolonged arrhythmia and underlying cardiomyopathy could not be made.<sup>15</sup>

Necropsy findings in experimentally induced cases of *N oleander* poisoning include petechiation of the heart, congestion of the lungs, liver and kidneys, and gastrointestinal hemorrhage. Acute, multifocal, cardiac necrosis was observed in this patient, and is consistent with previously reported histopathology changes due to *N oleander*.<sup>16,17</sup> Cardiac necrosis could also be attributed to cardiomyopathy-induced hypoxia; however, fibrosis supportive of chronicity would be expected.<sup>15,18</sup> Congestion of multiple organs is also observed with congestive heart failure, but the presence of gastrointestinal hemorrhage may be more suggestive of toxicity. Oral ulceration from irritating saponin compounds have been observed and may explain the patient's facial edema.<sup>1,19</sup> The friable material in the colon was suspected to be plant material, but additional confirmatory testing was not performed. Based on the history, clinical signs, response to Digibind and necropsy findings, *N oleander* toxicosis was strongly suspected, in addition to pre-existing HCM.

## Conclusions

While dsFab is used widely in people with glycoside intoxication, there are limited reports of its use in veterinary medicine, and studies of its pharmacokinetics and tolerability in cats are lacking. Despite this, dsFab should

be considered for severe cases of glycoside toxicosis, as it may be effective in counteracting cardiac toxicity. The benefit may be greater in the early stages, before severe cardiac necrosis has occurred, although additional studies are needed to support this recommendation.

**Conflict of interest** The authors declared no potential conflicts of interest with respect to the research, authorship, and/or publication of this article.

**Funding** The authors received no financial support for the research, authorship, and/or publication of this article.

**Ethical approval** This work involved the use of non-experimental animals only (including owned or unowned animals and data from prospective or retrospective studies). Established internationally recognized high standards ('best practice') of individual veterinary clinical patient care were followed. Ethical approval from a committee was therefore not specifically required for publication in *JFMS Open Reports*.

**Informed consent** Informed consent (either verbal or written) was obtained from the owner or legal custodian of all animal(s) described in this work (either experimental or non-experimental animals) for the procedure(s) undertaken (either prospective or retrospective studies). No animals or humans are identifiable within this publication, and therefore additional informed consent for publication was not required.

**ORCID iD** Aaron F Galton  <https://orcid.org/0000-0002-2409-3585>

## References

- Langford SD and Boor PJ. **Oleander toxicity: an examination of human and animal toxic exposures.** *Toxicology* 1996; 109: 1–13.
- Bandara V, Weinstein SA, White J, et al. **A review of the natural history, toxinology, diagnosis and clinical management of *Nerium oleander* (common oleander) and *Thevetia peruviana* (yellow oleander) poisoning.** *Toxicon* 2010; 56: 273–281.
- Aslani MR, Movassaghi AR, Mohri M, et al. **Clinical and pathological aspects of experimental oleander (*Nerium oleander*) toxicosis in sheep.** *Vet Res Commun* 2004; 28: 609–616.
- Eddleston M, Rajapakse S, Rajakanthan, et al. **Anti-digoxin Fab fragments in cardiotoxicity induced by ingestion of yellow oleander: a randomised controlled trial.** *Lancet* 2000; 355: 967–972.
- Lapostolle F, Borron SW, Verdier C, et al. **Digoxin-specific Fab fragments as single first-line therapy in digitalis poisoning.** *Crit Care Med* 2008; 36: 3014–3018.
- Demiryurek AT and Demiryurek S. **Cardiotoxicity of digitalis glycosides: roles of autonomic pathways, autacoids and ion channels.** *Auton Autacoid Pharmacol* 2005; 25: 35–52.
- Rajapakse S. **Management of yellow oleander poisoning.** *Clin Toxicol (Phila)* 2009; 47: 206–212.
- Ibanez C, Carcas AJ, Frias J, et al. **Activated charcoal increases digoxin elimination in patients.** *Int J Cardiol* 1995; 48: 27–30.
- Kanji S and MacLean RD. **Cardiac glycoside toxicity: more than 200 years and counting.** *Crit Care Clin* 2012; 28: 527–535.
- O'Brien T, Clark-Price S, Evans E, et al. **Infusion of a lipid emulsion to treat lidocaine intoxication in a cat.** *J Am Vet Med Assoc* 2010; 237: 1455–1458.
- Senior DF, Feist EH, Stuart LB, et al. **Treatment of acute digoxin toxicosis with digoxin immune Fab (ovine).** *J Vet Intern Med* 1991; 5: 302–303.
- Pao-Franco A, Hammond TN, Weatherston LK, et al. **Successful use of digoxin-specific immune Fab in the treatment of severe *Nerium oleander* toxicosis in a dog.** *J Vet Emerg Crit Care (San Antonio)* 2017; 27: 596–604.
- Clark RF, Selden BS and Curry SC. **Digoxin-specific Fab fragments in the treatment of oleander toxicity in a canine model.** *Ann Emerg Med* 1991; 20: 1073–1077.
- Dasgupta A, Klein K, Risin SA, et al. **Rapid detection of oleander poisoning by Dimension Vista digoxin assay (Flex Reagent Cartridge).** *J Clin Lab Anal* 2011; 25: 105–109.
- Kittleson MD, Meurs KM, Munro MJ, et al. **Familial hypertrophic cardiomyopathy in Maine Coon cats: an animal model of human disease.** *Circulation* 1999; 99: 3172–3180.
- Barbosa RR, Fontenele-Neto JD and Soto-Blanco B. **Toxicity in goats caused by oleander (*Nerium oleander*).** *Res Vet Sci* 2008; 85: 279–281.
- Omidi A, Razavizadeh AT, Movassaghi AR, et al. **Experimental oleander (*Nerium oleander*) intoxication in broiler chickens (*Gallus gallus*).** *Hum Exp Toxicol* 2012; 31: 853–858.
- Kitz S, Fonfara S, Hahn S, et al. **Feline hypertrophic cardiomyopathy: the consequence of cardiomyocyte-initiated and macrophage-driven remodeling processes?** *Vet Pathol* 2019; 56: 565–575.
- Taskin O, Belli F, Acikalin A, et al. **Add oleander to your list of corrosives.** *Turk J Emerg Med* 2019; 19: 115–116.