



Laparoscopic portosystemic shunt attenuation in two cats

Authors: Izzo, Francesca, Poggi, Edoardo, Pérez Duarte, Francisco J, and Cinti, Filippo

Source: Journal of Feline Medicine and Surgery Open Reports, 8(1)

Published By: SAGE Publishing

URL: <https://doi.org/10.1177/20551169221081416>

BioOne Complete (complete.BioOne.org) is a full-text database of 200 subscribed and open-access titles in the biological, ecological, and environmental sciences published by nonprofit societies, associations, museums, institutions, and presses.

Your use of this PDF, the BioOne Complete website, and all posted and associated content indicates your acceptance of BioOne's Terms of Use, available at www.bioone.org/terms-of-use.

Usage of BioOne Complete content is strictly limited to personal, educational, and non - commercial use. Commercial inquiries or rights and permissions requests should be directed to the individual publisher as copyright holder.

BioOne sees sustainable scholarly publishing as an inherently collaborative enterprise connecting authors, nonprofit publishers, academic institutions, research libraries, and research funders in the common goal of maximizing access to critical research.



Laparoscopic portosystemic shunt attenuation in two cats

Francesca Izzo¹, Edoardo Poggi¹,
 Francisco J Pérez Duarte² and Filippo Cinti^{1,3} 

Journal of Feline Medicine and Surgery Open Reports
 1–7

© The Author(s) 2022
 Article reuse guidelines:
sagepub.com/journals-permissions
 DOI: 10.1177/20551169221081416
journals.sagepub.com/home/jfmsopenreports

This paper was handled and processed
 by the European Editorial Office (ISFM)
 for publication in *JFMS Open Reports*



Abstract

Case series summary Gradual attenuation of an extrahepatic portosystemic shunt using cellophane banding was achieved with a laparoscopic technique in two cats. The portosystemic shunts were treated via a right or left lateral laparoscopic approach. Ultrasonography or CT angiography were used to verify the results of surgery. The success of the procedure was confirmed by normalisation of serum bile acid concentrations and clinical signs at the final re-evaluation.

Relevance and novel information The aim of this case series was to determine the feasibility and outcome of laparoscopy for portosystemic shunt attenuation in two cats. Laparoscopic portosystemic shunt attenuation appeared to be a feasible, safe and effective procedure in cats.

Keywords: Laparoscopy; portosystemic shunt; mini-invasive approach; cellophane banding

Accepted: 2 February 2022

Case series description

Case 1

A 1-year-old intact female domestic shorthair cat weighing 2 kg was referred due of ataxia, lethargy and delayed growth. Biochemical abnormalities at the initial examination included a high baseline concentration of bile acids (109.9 µmol/l; reference interval [RI] 0–10) and hyperammonaemia (150.00 µmol/l; RI 0–90). Abdominal ultrasonography showed the presence of an abnormal vessel and microhepatica, leading to a tentative diagnosis of portosystemic shunt (PSS). CT angiography (CTA) showed hepatic atrophy and a large vascular anomaly (4.2 mm in diameter) diagnosed as a left gastrophrenic extrahepatic portosystemic shunt (EHPSS) close to the diaphragm (Figure 1). Preoperative medical management was initiated 1 day after referral and consisted of amoxicillin and clavulanic acid (12.5 mg/kg PO q12h [Synulox; Zoetis Italia]), lactulose (0.5 ml PO q12h [Laevolac; Chiesi Italia]) and a restricted protein prescription diet for 4 weeks (L/D; Hill's Pet Nutrition).

Laparoscopic surgery was carried out 4 weeks after referral. The cat was premedicated with dexmedetomidine (2.5 mg/kg IM [Dexdomitor; Zoetis Italia]) and methadone (0.15 mg/kg IM [Semfortan; Dechra Veterinary Products]). General anaesthesia was induced

with propofol (5 mg/kg IV [Propofur; Boehringer Ingelheim Animal Health Italia]) and maintained with sevoflurane in oxygen (Sevoflo; Eucuphar Italia). An epidural injection of 0.2% bupivacaine and morphine 0.1 mg/kg (Bupivacaina [Angelini Pharma Italia] and Morfina Cloridato; Molteni Farmaceutica) was used for local anaesthesia. Under general anaesthesia the cat was aseptically prepared for surgery and placed in right lateral recumbency for a left lateral flank approach using a modified Hasson technique (Figure 2).¹ The surgical table was in a neutral position. Three trocar-cannula systems (Kii Sleeve with Advanced Fixation; Applied Medical) were used for laparoscopy and introduced through scalpel blade stab incision. The first 5 mm

¹Apuana Veterinary Clinic – AniCura, Marina di Carrara (MS), Italy

²VETMI, Minimally Invasive Veterinary Surgery Service, Cáceres, Spain

³Portoni Rossi-AniCura Veterinary Hospital, Zola Predosa (BO), Italy

Corresponding author:

Francesca Izzo DVM, MSc, GPCert(SAS), Apuana Veterinary Clinic – AniCura, Viale XX settembre 298, Marina di Carrara (MS) 54033, Italy

Email: franc.izzo@tiscali.it; francesca.izzo@anicura.it



Creative Commons Non Commercial CC BY-NC: This article is distributed under the terms of the Creative Commons

Attribution-NonCommercial 4.0 License (<https://creativecommons.org/licenses/by-nc/4.0/>) which permits non-commercial use, reproduction and distribution of the work without further permission provided the original work is attributed as specified on the SAGE and Open Access pages (<https://us.sagepub.com/en-us/nam/open-access-at-sage>).

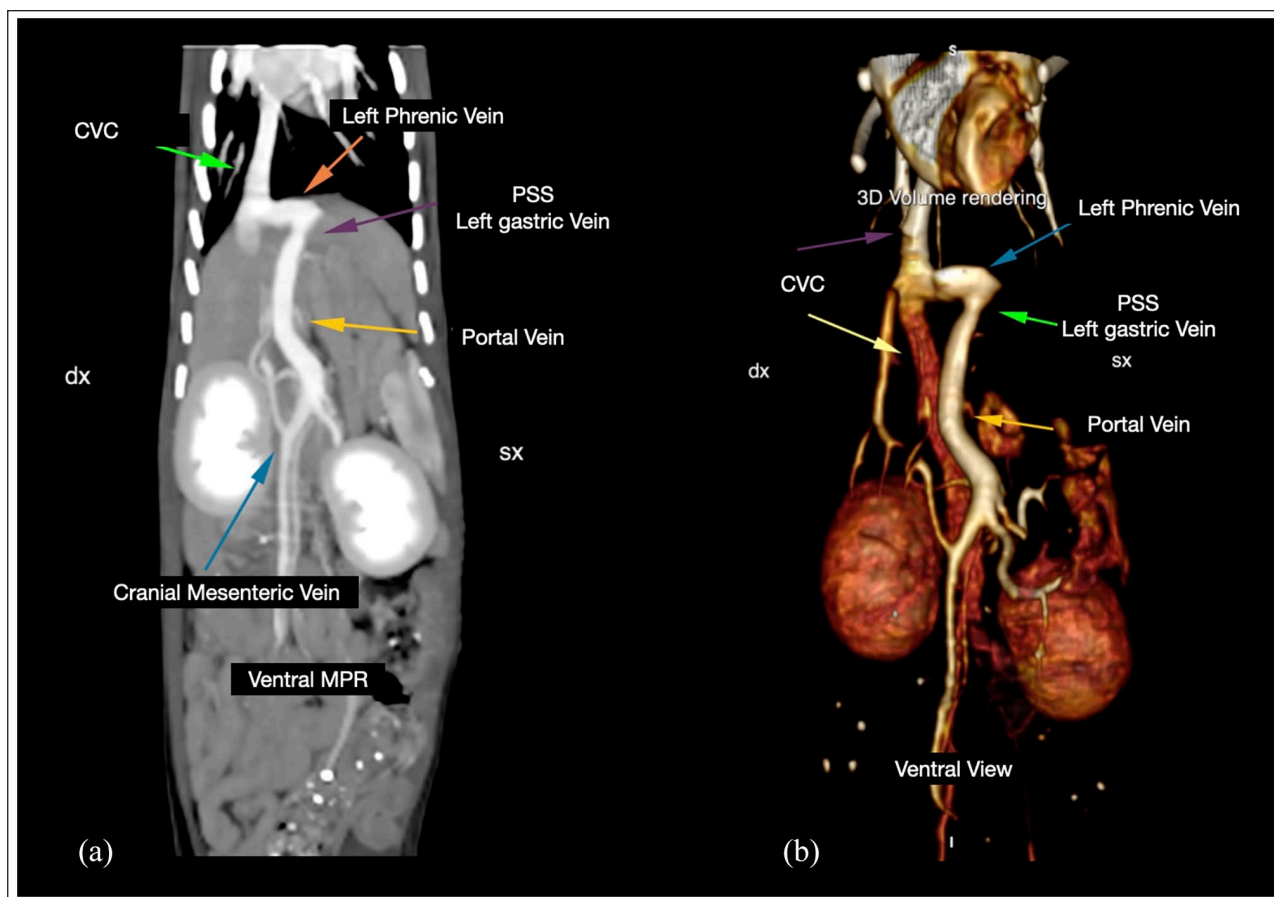


Figure 1 CT angiography with (a) multiplanar reconstruction and (b) three-dimensional volume rendering examinations, showing a ventral view of the abdomen in case 1 with a left gastrophrenic extrahepatic portosystemic shunt. The shunt (left gastric vein) runs in a straight line from the porta hepatis following the lesser curvature of the stomach and ending in the left phrenic vein before joining the left hepatic vein. PSS = portosystemic shunt; CVC = caudal vena cava

cannula was introduced 2 cm lateral to the umbilicus. The abdomen was insufflated with carbon dioxide to maintain a pressure of 5 mmHg. A 5 mm 30° telescope (Hopkins Forward-Oblique Telescope; Karl-Storz) was introduced through the 5 mm cannula to explore the abdomen and monitor placement of the next two cannulae. The second 5 mm cannula was positioned dorsal to the first cannula and just caudal to the last rib. An 11 mm cannula was positioned 6 cm caudodorsal to the first cannula. After laparoscopic exploration of the abdomen, the ligament between the left hepatic lobe and diaphragm was dissected using monopolar scissors (Metzenbaum curved scissors; Karl-Storz). The course of the shunt was seen to the point where it joined the left phrenic vein.

The shunt was dissected from the surrounding tissue using laparoscopic right-angled forceps (right-angled dissecting forceps; Karl-Storz) and Maryland forceps (atraumatic forceps; Karl-Storz). A 10 × 10 mm piece of cellophane (Clear Cello; Hallmark Cards), which had been folded three times to create a width of approximately

3 mm, was placed around the shunt and secured with three haemostatic clips (Epix Universal Clip Applicators 5 mm; Applied Medical) and a surgical knot made with 3-0 non-absorbable suture material (Ethilon; Ethicon), as additional securing of the cellophane band ends (Figure 3). The goal was to reduce the diameter of the shunt to <50%. The abdomen was monitored for signs of portal hypertension such as congestion or change in colour of the pancreas or jejunum, or change in jejunal motility for 5 mins after cellophane band application. Signs of portal hypertension were not seen, and the cannulae were removed, which resulted in deflation of the abdomen. Each port was closed using 3-0 glyconate monofilament suture material (Monosyn; B Braun) in the abdominal wall and subcutaneous tissues and 4-0 glyconate monofilament suture material (Monosyn; B Braun) in the skin. The total surgical time from creation of the first port to closure of the last port was 81 mins.

The postoperative CTA confirmed the position of the cellophane band and partial attenuation of the shunt (Figure 4). The cat recovered without postoperative

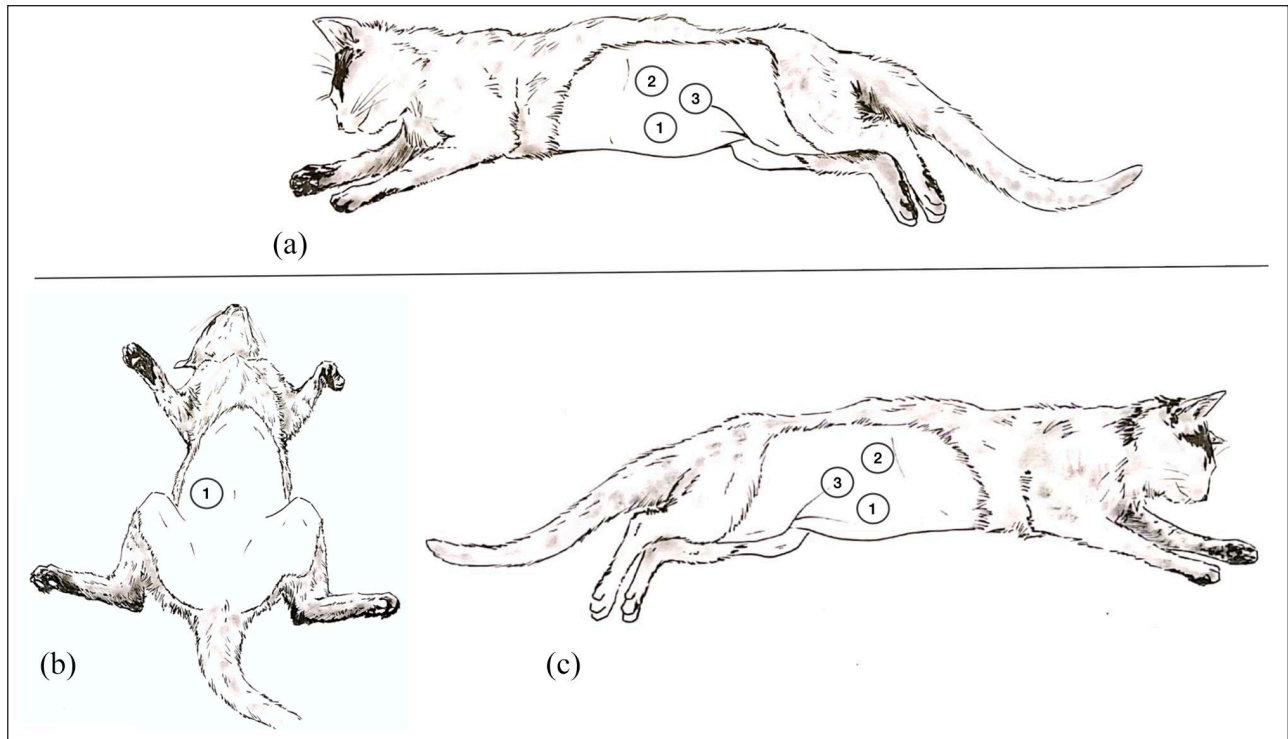


Figure 2 Illustration showing the position of (a) case 1 and (b,c) case 2 during laparoscopic portosystemic shunt attenuation. (a) Case 1 is shown in right lateral recumbency for a left lateral flank approach. The first cannula (5 mm) was placed 2 cm lateral to the umbilicus, the second cannula (5 mm) was placed dorsal to the first cannula just caudal to the last rib and the third cannula (11 mm) was positioned 6 cm caudodorsal to the first cannula. Case 2 was positioned in dorsal recumbency for (b) placement of the first cannula and then repositioned in left recumbency for (c) a right lateral flank approach. The first cannula (5 mm) was placed 1 cm lateral to the right of the umbilical scar, the second cannula was dorsal to the first cannula and just caudal to the last rib, while the third cannula (3 mm) was placed 6 cm caudodorsal to the first cannula to achieve triangulation

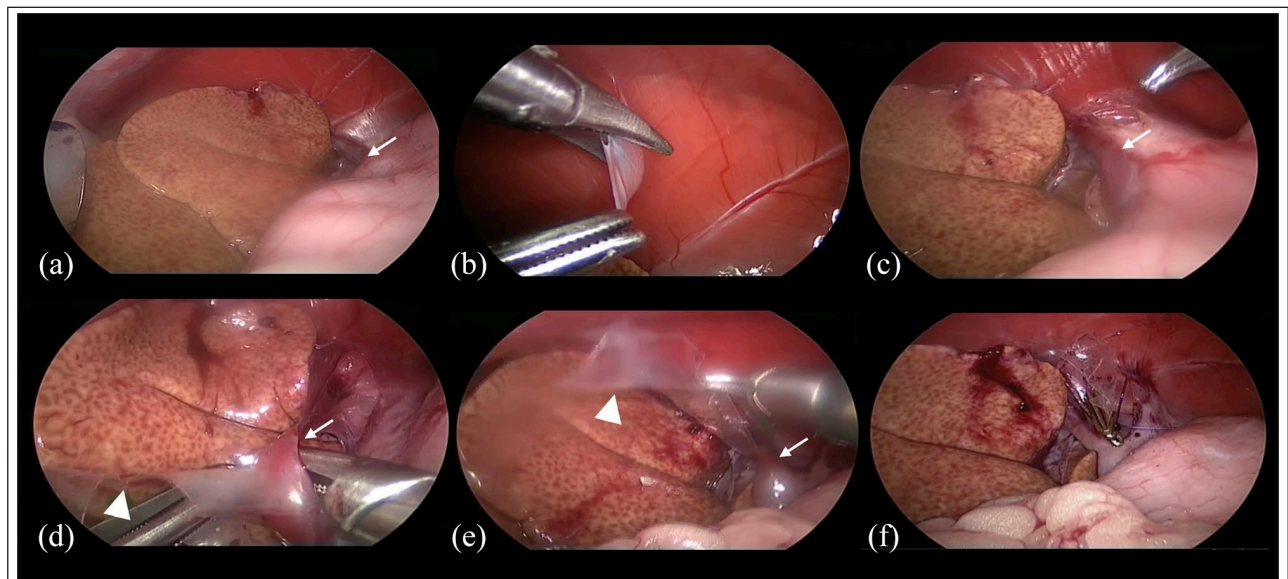


Figure 3 Intraoperative laparoscopic view in case 1. (a) An extrahepatic portosystemic shunt (EHPSS) is seen to the right of the liver lobe, which has yellow discoloration. (b) Dissection of the ligament between the left hepatic lobe and diaphragm. (c–e) Identification and isolation of the shunt and application of the cellophane band. (f) The shunt was dissected and encircled with the cellophane band, secured with three haemostatic clips and a surgical knot. In all images the white arrow indicates the EHPSS and the white arrowhead indicates the cellophane

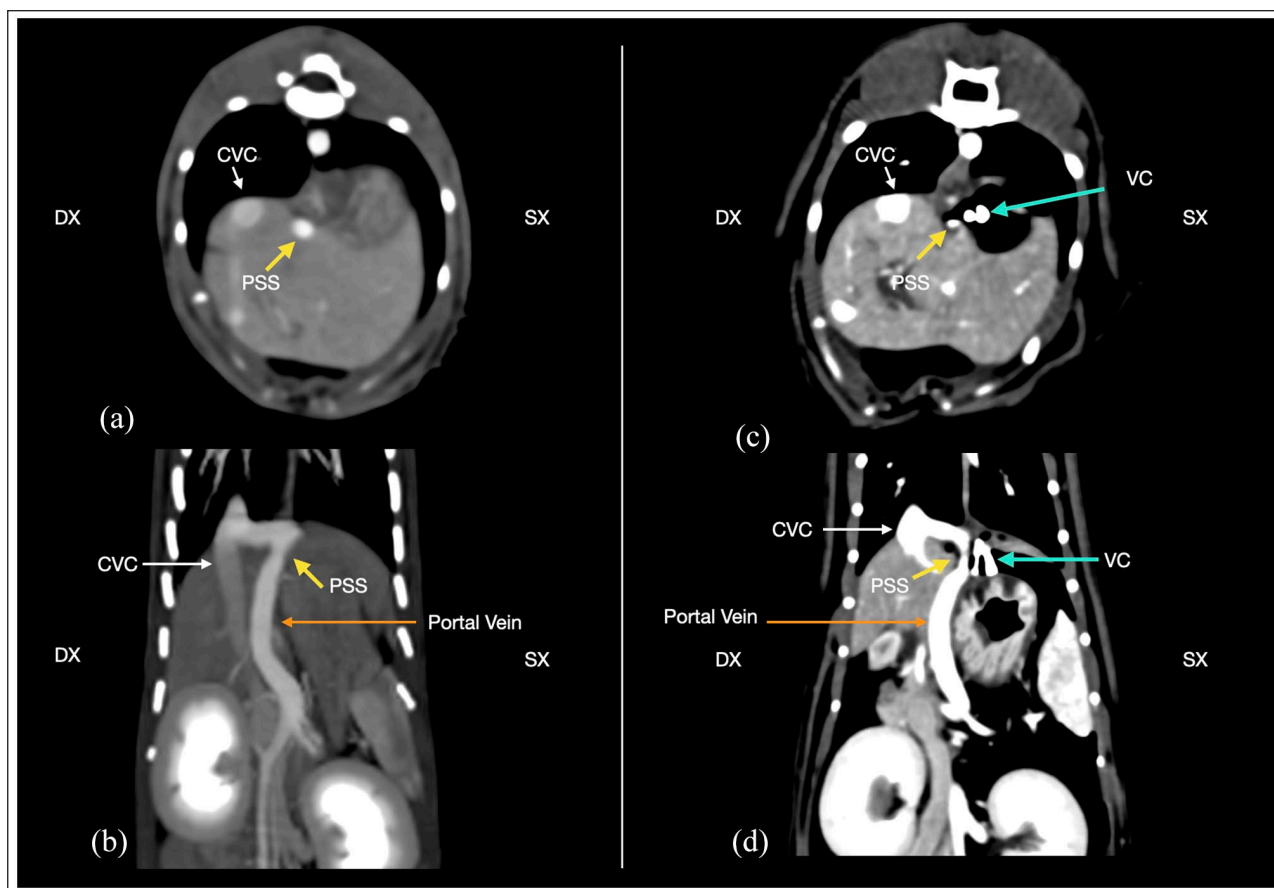


Figure 4 (a,b) Preoperative and (c,d) postoperative CT angiography (CTA) scan of case 1. The postoperative CTA scan showed the attenuation of the portosystemic shunt (PSS) after surgery. Caudal vena cava (CVC) (white arrow), PSS (yellow arrow), portal vein (orange arrow) and vascular/haemostatic clip (VC) (turquoise arrow)

complications. Ultrasonographic examination carried out 8 h after surgery showed no signs of portal hypertension. The cat was eating and drinking normally 9 h postoperatively.

Postoperative analgesia consisted of meloxicam (0.1 ml/kg PO on the first day and 0.05 ml/kg PO for 4 more days [Meloxoral; ATI]). The cat was discharged 24 h postoperatively. Postoperative treatment consisted of lactulose, amoxicillin and clavulanic acid, and a low-protein diet, as prescribed for preoperative medical management, until the concentration of serum bile acids had normalised.

The cat was in good clinical condition 1 month after surgery, had no neurological signs and weighed 2.9 kg, and the baseline concentration of bile acids had decreased to 35 $\mu\text{mol/l}$ (RI 0–10). Three months after surgery, the preprandial (0.1 $\mu\text{mol/l}$) and postprandial (0.4 $\mu\text{mol/l}$) serum concentrations of bile acids were normal (RI 0–20). One year postoperatively, the cat was in excellent health, weighed 4 kg and had no abnormal clinical signs. The results of haematological analysis showed no abnormalities, and the concentration of bile acids was within the RI

(4 $\mu\text{mol/l}$; RI 0–10). Ovariectomy was elected at this time, and preoperative CTA showed complete attenuation of the shunt.

Case 2

A 4-year-old spayed female Persian cat weighing 2.3 kg was referred because of poor clinical condition, low activity level, decreased appetite, vomiting and restlessness. The results of blood analysis showed mild anaemia (haematocrit 26.7% [RI 30.3–52.3]), hyperammonaemia (163.8 $\mu\text{mol/l}$ [RI 0–90]), high baseline concentration of bile acids (115 $\mu\text{mol/l}$ [RI 0–10]) and low urea nitrogen concentration (5.9 mg/dl [RI 16–36]). Ultrasonographic examination of the abdomen showed an abnormal 4 mm vessel, close to the liver, which was diagnosed as a standard extrahepatic portocaval shunt located in the epiploic foramen. Medical stabilisation was initiated with metronidazole (7.5 mg/kg PO q12h; [Metrobactin; Dechra Veterinary Products]), lactulose (0.5 ml/kg PO q12h [Laevolac; Chiesi Italia]) and a restricted protein prescription diet (L/D; Hill's Pet Nutrition). Unfortunately, after 24 days, the response to medical treatment was

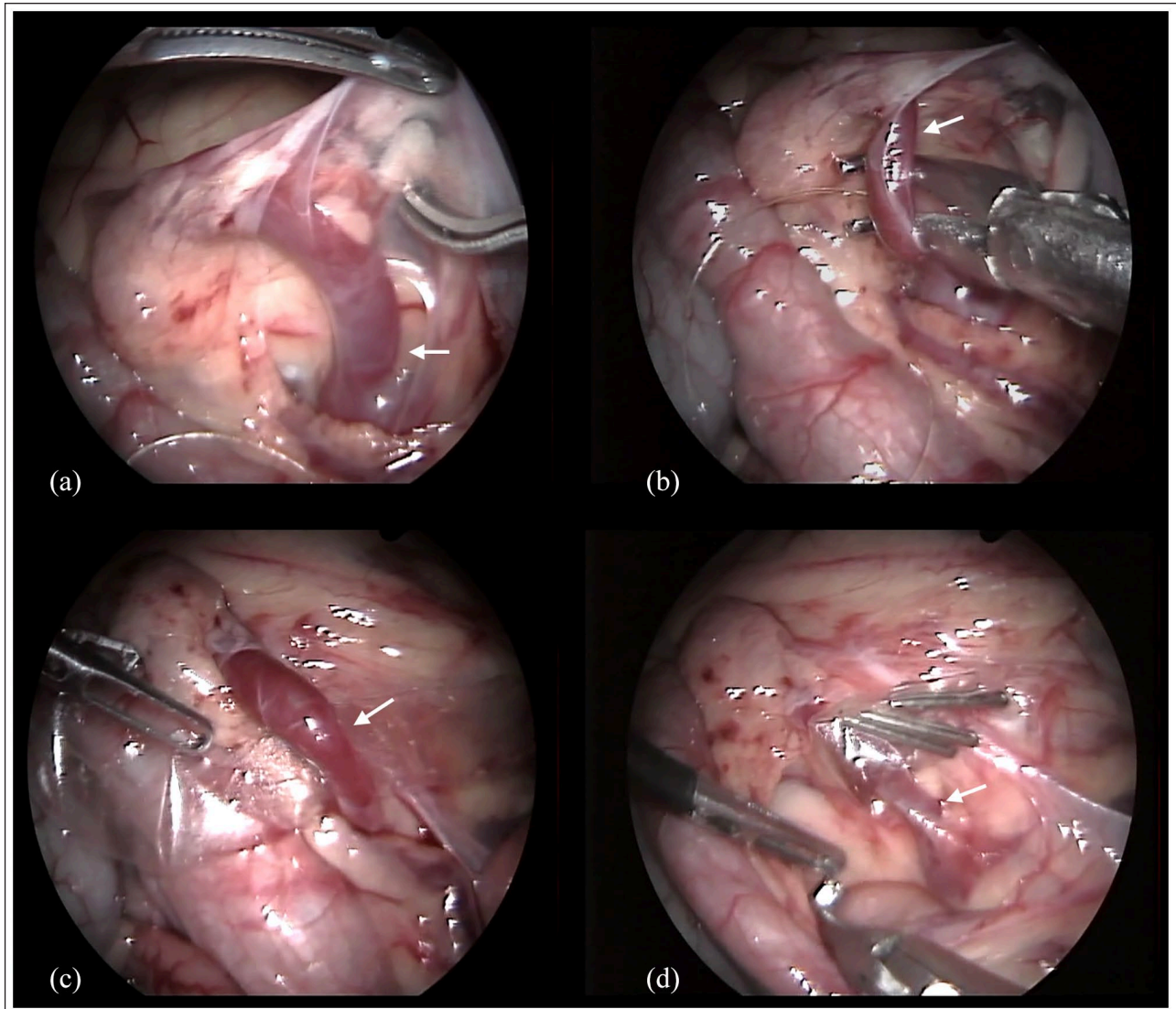


Figure 5 Intraoperative laparoscopic view in case 2. (a) The epiploic foramen and extrahepatic portosystemic shunt (EHPSS) are shown. (b) Dissection of the shunt from the surrounding tissue. (c) Placement of the cellophane band around the shunt. (d) The cellophane band is secured with three haemostatic clips. The white arrow indicates the EHPSS

considered poor and thus surgical treatment with laparoscopic PSS attenuation using cellophane banding was carried out.

Patient preparation followed the steps described for case 1, except that the cat was first placed in dorsal recumbency and then repositioned in left lateral recumbency for a right flank approach after placement of the first cannula. Under general anaesthesia, the procedure used for creation of the pneumoperitoneum was the same as described for case 1. With the cat in dorsal recumbency, the first 5 mm cannula (Kii Sleeve with Advanced Fixation; Applied Medical) was placed 1 cm lateral and to the right of the umbilical scar, and the abdomen was insufflated with carbon dioxide to maintain a pressure of 5 mmHg. The cat was then placed in

left lateral recumbency for a right lateral approach. Under direct view, with a 5 mm 30° telescope, a second 5 mm cannula was placed in right flank, dorsal to the first cannula and just caudal to the last rib. A 3 mm mini-laparoscopy cannula (trocar blunt tip; Karl-Storz) was placed 6 cm caudodorsal to the first cannula to achieve triangulation. The shunt was located in the epiploic foramen. Dissection of the shunt from the surrounding tissue started close to the caudal vena cava using laparoscopic right-angled forceps and Maryland forceps. As described for case 1, a cellophane band was placed around the shunt and secured with three haemostatic clips (Figure 5). Postoperative monitoring of the abdomen for signs of portal hypertension, deflation of the abdomen and closure of the ports followed the steps

described for case 1. The total surgical time was 82 mins. No intra- or postoperative complications occurred, and the cat was eating and drinking normally 8 h after surgery. Postoperative analgesia, discharge time and postoperative medical treatments were the same as described for the case 1.

Ultrasonographic examination of the abdomen 10 days postoperatively confirmed that attenuation of the shunt to a diameter of 3.2 mm had been achieved. Complete attenuation of the shunt was confirmed 2 months after surgery using ultrasonography. At that time, the pre- and postprandial concentrations of bile acids were within the RI (0.7 and 0.9 $\mu\text{mol/l}$ [RI 0–20], respectively) and the results of a physical examination were normal. Re-evaluation 23 months postoperatively revealed no abnormal findings.

Discussion

Laparoscopic EHPSS attenuation was found to be a feasible, complication-free procedure in these cats and was associated with low morbidity. The same technique has been reported in dogs with PSS,^{2,4} but, to our knowledge, this is the first description of PSS attenuation using laparoscopy in cats. An important step was identifying the shunts preoperatively using CTA or ultrasonography, in agreement with the recommendations of others.^{5–7}

PSS may have different locations and courses, and these could influence surgical planning and approach.^{7,8} EHPSS are more common than those located within the liver parenchyma in cats.^{9,10} Case 1 had a congenital EHPSS involving the left gastric vein/left phrenic vein. Despite the position of the PSS, close to lesser gastric curvature and diaphragm, CTA supported the authors' decision for a left flank laparoscopic approach. In case 2 the ultrasonography clearly identified an EHPSS and allowed a planned right lateral approach for better visualisation of the shunt, which was located in the epiploic foramen.

The initial positioning of the animal for the insertion of the first cannula was at the surgeon's preference; no intraoperative complication or shunt identification differences were noted in the two initial recumbency positions. Our preference was to place the second and third cannulae under direct visual control, to obtain optimal triangulation. Three cannulae were sufficient in both cases and using a left or right lateral approach improved visualisation and made the procedure easier than a ventral approach, which was used in dogs.²

Various methods have been described for the gradual attenuation of PSS. Cellophane banding is a relatively simple procedure with a safety and efficacy profile similar to other techniques.^{9,11,12} The physical nature of the cellophane band allowed easy introduction through the cannula. Cellophane banding has been shown to provide gradual occlusion of the shunt with resolution

of clinical signs and normalisation of serum bile acid levels 2 or 3 months postoperatively.^{9,13,14} Recanalisation of shunts post cellophane banding has been reported, but was not seen in these cases.⁶ The bile acid stimulation test is a good indicator of shunt attenuation and the results correlate well with the clinical outcome.¹⁴ This was in agreement with our findings, in which serum bile acid concentration returned to normal after 3 months in case 1 and after 2 months in case 2; clinical signs rapidly returned to normal in both cases.

Intraoperative clinical parameters such as changes in the colour of the pancreas and small intestine, and intestinal motility can be used to monitor for portal hypertension.^{9,15–18} We chose a 5 min period of intraoperative monitoring after the application of the cellophane band and saw no signs of portal hypertension.

Cats present unique challenges for laparoscopy mostly because of their small size. However, the creation of capnoperitoneum provides a good working space in this species and together with magnification of anatomical structures such as blood vessels makes laparoscopy an advantageous technique. In addition, laparoscopy results in smaller incisions, less postoperative pain and allows for a faster return to normal activity vs laparotomy.^{19–21} Nevertheless, an experienced surgical team and expensive equipment are required. Prolonged surgical time is one of the most important limitations of this procedure, but with experience the time required decreases. Our operative time was not associated with morbidity in either cat.

Conclusions

Gradual attenuation of PSS with cellophane banding via laparoscopy appeared to be a feasible, safe and effective technique in cats with EHPSS. Further studies are required to substantiate our findings and to determine whether laparoscopy can be used for treatment of shunts in other locations.

Acknowledgements The authors thank Dr Andrea Arcangeli and Dr Swan Specchi for the CTA images and their scientific support. The authors thank Dr Fabio Esposito for the illustration in Figure 2.

Conflict of interest The authors declared no potential conflicts of interest with respect to the research, authorship, and/or publication of this article.

Funding The authors received no financial support for the research, authorship, and/or publication of this article.

Ethical approval The work described in this manuscript involved the use of non-experimental (owned or unowned) animals. Established internationally recognised high standards ('best practice') of veterinary clinical care for the individual patient were always followed and/or this work involved

the use of cadavers. Ethical approval from a committee was therefore not specifically required for publication in *JFMS Open Reports*. Although not required, where ethical approval was still obtained, it is stated in the manuscript.

Informed consent Informed consent (verbal or written) was obtained from the owner or legal custodian of all animal(s) described in this work (experimental or non-experimental animals, including cadavers) for all procedure(s) undertaken (prospective or retrospective studies). No animals or people are identifiable within this publication, and therefore additional informed consent for publication was not required.

ORCID iD Filippo Cinti  <https://orcid.org/0000-0003-1680-0523>

References

- 1 Mayhew PD and Brown DC. **Comparison of three techniques for ovarian pedicle hemostasis during laparoscopic-assisted ovariohysterectomy.** *Vet Surg* 2007; 36: 541–547.
- 2 Miller MJ and Fowler JD. **Laparoscopic portosystemic shunt attenuation in two dogs.** *J Am Ani Hosp Assoc* 2006; 42: 160–164.
- 3 Miller NA. **Laparoscopic extrahepatic portosystemic shunt attenuation.** In: Tams TR and Rawlings CA (eds). *Small animal endoscopy*. 3rd ed. St Louis, MO: Elsevier, 2011, pp 446–449.
- 4 Poggi E, Rubio DG, Perez Duarte FJ, et al. **Laparoscopic portosystemic shunt attenuation in 20 dogs (2018–2021).** *Vet Surg* 2022. DOI: 10.1111/vsu.13785.
- 5 Lamb CR, Forster-van Hijfte MA, White RN, et al. **Ultrasonographic diagnosis of congenital portosystemic shunt in 14 cats.** *J Small Anim Pract* 1996; 37: 205–209.
- 6 Crowley J, Foo T, Boland L, et al. **Recanalization of a congenital extrahepatic portosystemic shunt previously attenuated with cellophane banding in a cat.** *JFMS Open Rep* 2018; 4. DOI: 10.1177/2055116918795717.
- 7 White RN, Parry AT and Shales C. **Implications of shunt morphology for the surgical management of extrahepatic portosystemic shunts.** *Aust Vet J* 2018; 11: 433–441.
- 8 Culp WTN, Griffin MA, Case JB, et al. **Use of percutaneous transvenous coil embolization in the treatment of intrahepatic portosystemic shunts in four cats.** *J Am Vet Med Assoc* 2020; 257: 70–79.
- 9 Hunt GB, Kummeling A, Tisdall P, et al. **Outcomes of cellophane banding for congenital portosystemic shunts in 106 dogs and 5 cats.** *Vet Surg* 2004; 31: 25–31.
- 10 Lipscomb VJ, Jones HJ, Brockman D, et al. **Complications and long-term outcomes of the ligation of congenital portosystemic shunts in 49 cats.** *Vet Rec* 2007; 160: 465–470.
- 11 Bright SR, Williams JM and Niles JD. **Outcomes of intrahepatic portosystemic shunts occluded with ameroid constrictors in nine dogs and one cat.** *Vet Surg* 2006; 35: 300–309.
- 12 Weisse C, Schwartz K, Stronger R, et al. **Transjugular coil embolization of an intrahepatic portosystemic shunt in a cat.** *J Am Vet Med Assoc* 2002; 221: 1287–1291.
- 13 Cabassu J, Seim 3rd HB, MacPhail CM, et al. **Outcomes of cats undergoing surgical attenuation of congenital extrahepatic portosystemic shunts through cellophane banding: 9 cases (2000–2007).** *J Am Vet Med Assoc*; 2011; 238: 89–93.
- 14 Valiente P, Trehy M, White, et al. **Complications and outcome of cats with congenital extrahepatic portosystemic shunts treated with tin film: thirty four cases (2008–2017).** *J Vet Int Ern Med* 2019; 34: 117–124.
- 15 Kummeling A, Van Sluijjs FJ and Routhuizen J. **Prognostic implications of the degree of shunt narrowing and of the portal vein diameter in dogs with congenital portosystemic shunts.** *Vet Surg* 2004; 33: 17–24.
- 16 White RN, Foster-van Hijfte MA, Petrie G, et al. **Surgical treatment of intrahepatic portosystemic shunts in six cats.** *Vet Rec* 1996; 139: 314–317.
- 17 Schunk CM. **Feline portosystemic shunts.** *Semin Vet Med Surg Small Anim* 1997; 12: 45–50.
- 18 Tillson DM and Winkler JT. **Diagnosis and treatment of portosystemic shunts in the cat.** *Vet Clin North Am Small Anim Pract* 2002; 32: 881–899.
- 19 Culp WTN, Mayhew PD and Brown DC. **The effect of laparoscopy versus open ovariectomy on postsurgical activity in small dogs.** *Vet Surg* 2009; 38: 811–817.
- 20 Gauthier O, Holophern-Doran J, Gendarme T, et al. **Assessment of postoperative pain in cats after ovariectomy by laparoscopy, median celiotomy, or flank laparotomy.** *Vet Surg* 2015; 1: 23–30.
- 21 Devitt CM, Cox RE and Hailey JJ. **Duration, complications, stress, and pain of open ovariohysterectomy versus a simple method of laparoscopic-assisted ovariohysterectomy in dogs.** *J Am Vet Med Assoc* 2005; 6: 921–927.