



## **Diagnosis and management of a laryngeal cyst in a domestic shorthair cat**

Authors: Manson, Katrina C, Graham, Julia L, and Rozanski, Elizabeth A

Source: Journal of Feline Medicine and Surgery Open Reports, 8(1)

Published By: SAGE Publishing

URL: <https://doi.org/10.1177/20551169221104545>

---

BioOne Complete ([complete.BioOne.org](https://complete.BioOne.org)) is a full-text database of 200 subscribed and open-access titles in the biological, ecological, and environmental sciences published by nonprofit societies, associations, museums, institutions, and presses.

Your use of this PDF, the BioOne Complete website, and all posted and associated content indicates your acceptance of BioOne's Terms of Use, available at [www.bioone.org/terms-of-use](https://www.bioone.org/terms-of-use).

Usage of BioOne Complete content is strictly limited to personal, educational, and non - commercial use. Commercial inquiries or rights and permissions requests should be directed to the individual publisher as copyright holder.

---

BioOne sees sustainable scholarly publishing as an inherently collaborative enterprise connecting authors, nonprofit publishers, academic institutions, research libraries, and research funders in the common goal of maximizing access to critical research.



# Diagnosis and management of a laryngeal cyst in a domestic shorthair cat

Katrina C Manson , Julia L Graham and Elizabeth A Rozanski 

*Journal of Feline Medicine and Surgery Open Reports*  
1–5

© The Author(s) 2022

Article reuse guidelines:

sagepub.com/journals-permissions

DOI: 10.1177/20551169221104545

journals.sagepub.com/home/jfmsopenreports

This paper was handled and processed by the American Editorial Office (AAFP) for publication in *JFMS Open Reports*



## Abstract

**Case summary** A 7-year-old male neutered domestic shorthair cat was presented with a 3-month history of dyspnea when exercising and increased respiratory noise when purring. Initial radiographs identified a suspected laryngeal mass. Point-of-care ultrasound found a fluid-filled structure on the larynx, which was drained percutaneously. The cat initially recovered well but, due to recurrence of clinical signs, a CT scan was performed, which confirmed the presence of a laryngeal cyst that was subsequently surgically resected. Histopathological analysis was consistent with a suspected thyroglossal cyst.

**Relevance and novel information** This is only the second report of a laryngeal cyst in the cat. While malignant laryngeal disease may be more prevalent in the cat, benign differentials should be considered as treatment could be curative, as was observed in this case.

**Keywords:** Respiratory; larynx; cyst; dyspnea

**Accepted:** 10 May 2022

## Introduction

Laryngeal cysts are rarely reported in both the veterinary and human literature but are an important consideration in the dyspneic cat. Only one prior case report of a laryngeal cyst in a cat was encountered during a literature search.<sup>1</sup> Thyroglossal cysts are the most common congenital neck mass in humans, although laryngeal involvement remains rare.<sup>2</sup> Overall occurrences of laryngeal disease in the cat are uncommon and previous studies report mainly neoplastic disease associated with laryngeal masses in cats.<sup>3</sup> This report characterizes the clinical signs, imaging, surgical and histopathological findings of a cat with a suspected thyroglossal cyst.

## Case description

A 7-year-old male neutered domestic shorthair cat was referred to the Foster Hospital for Small Animals at Tufts University for further investigation of a suspected laryngeal mass. The cat had been noted to be breathing more heavily and to have mild dyspnea at home for 3 months prior to referral. The cat appeared to improve initially but more acutely worsened 1 week prior to

referral and was presented to the referring veterinarian. The owner of the cat had noticed increased respiratory noise while purring and dyspnea when using the stairs. The cat had been otherwise clinically well, with a normal appetite and no noted dysphagia. Hematology performed by the referring veterinary practice was within normal limits other than mild thrombocytopenia ( $192 \times 10^9/\mu\text{l}$ ; reference interval [RI] 200–500) and mild lymphopenia ( $0.9 \times 10^9/\text{l}$ ; RI 1.2–8.0). Serum biochemistry and total thyroxine (TT4) were also within normal limits, other than a mildly elevated cholesterol (6.9 mmol/l; RI 1.9–5.7). Radiographs of the thorax and neck were performed and reviewed by a board-certified veterinary

Cummings Veterinary Medical Center at Tufts University, Henry & Lois Foster Hospital for Small Animals, North Grafton, MA, USA

### Corresponding author:

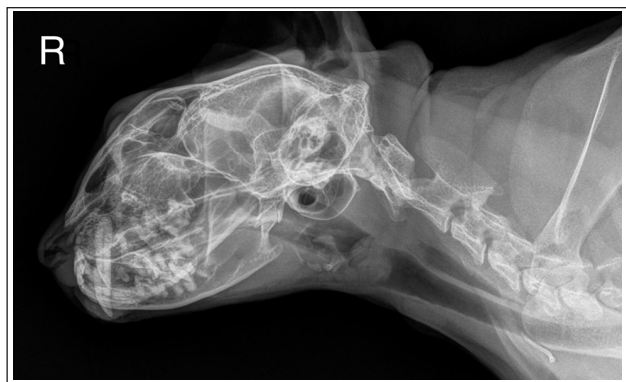Katrina C Manson BVM&S, MRCVS, Cummings Veterinary Medical Center at Tufts University, Henry & Lois Foster Hospital for Small Animals, 55 Willard Street, North Grafton, MA 01536, USA

Email: katrina.manson@tufts.edu



Creative Commons Non Commercial CC BY-NC: This article is distributed under the terms of the Creative Commons

Attribution-NonCommercial 4.0 License (<https://creativecommons.org/licenses/by-nc/4.0/>) which permits non-commercial use, reproduction and distribution of the work without further permission provided the original work is attributed as specified on the SAGE and Open Access pages (<https://us.sagepub.com/en-us/nam/open-access-at-sage>).

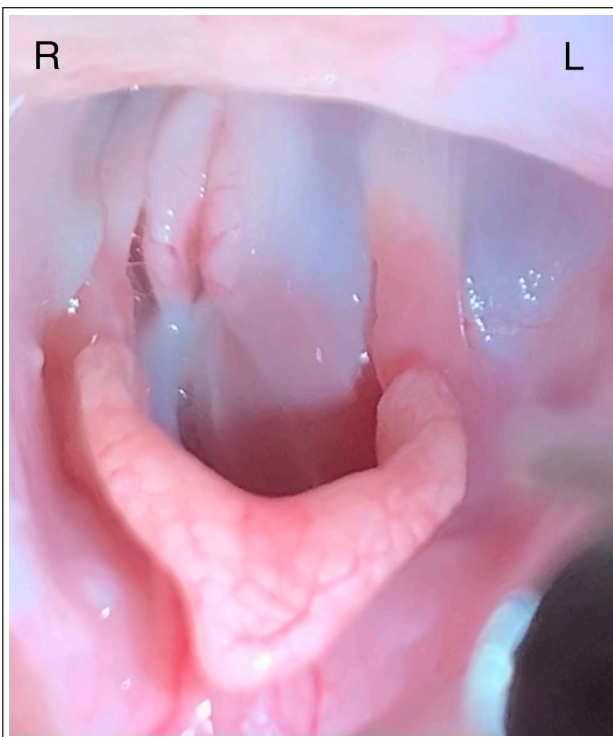


**Figure 1** A round, homogeneously soft tissue opaque structure (ie, laryngeal cyst) was appreciated within the larynx on a right lateral radiograph of the head and neck region of the patient. Image courtesy of the referring veterinarian

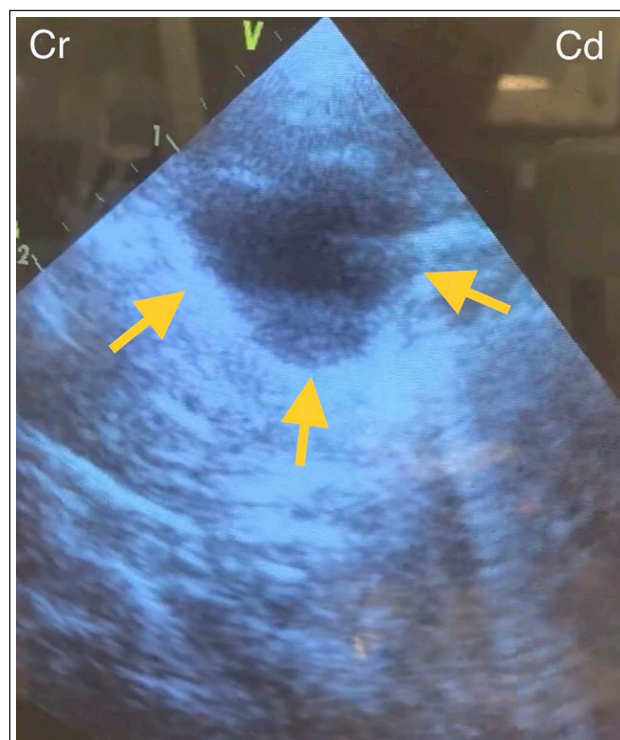
radiologist, with the pertinent finding of a homogeneously soft tissue opaque structure within the larynx, caudal to the epiglottis, which exhibited rounded cranial and caudal margins (Figure 1). The cat was referred for additional diagnostics and treatment.

On presentation 5 days later, the cat was bright, alert and responsive. Physical examination revealed tachypnea with mild stridor on auscultation (respiratory rate 60beats/min). There was no audible heart murmur. The patient was overconditioned, weighing 6.76 kg, with a body condition score of 6/9. There were no other pertinent findings. A venous blood gas analysis revealed no significant abnormalities, packed cell volume was 33% (RI 28–48%) and total solids were 76 g/l (RI 65–79 g/l).

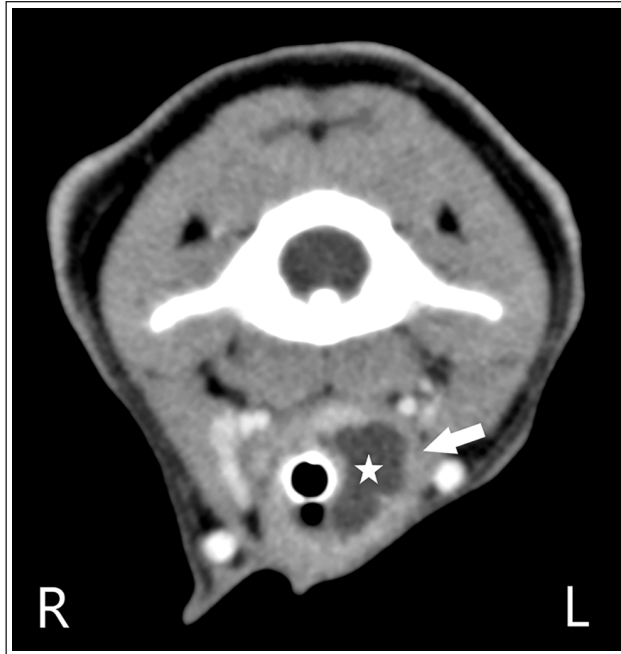Airway examination was performed the following day. Anesthesia was induced with propofol (Propofol; Zoetis) intravenously (IV) to effect. On oral examination, on the left side lateral to the arytenoids, an apparently fluid-filled structure was noted, causing complete deviation of the arytenoids to the right and almost total occlusion of the larynx (Figure 2). A 2.0 mm endotracheal tube was passed initially, a rigid urinary catheter was used as a guidewire through this and a 3.5 mm endotracheal tube was then successfully placed and gaseous anesthesia commenced with isoflurane (Isoflurane, USP; Akorn). The neck was clipped in preparation for tracheostomy if needed. The neck was assessed using point-of-care ultrasound and a thin-walled, round, hypoechoic-to-anechoic structure was found within the region of the larynx (Figure 3). This was percutaneously aspirated under ultrasound guidance using a 20G hypodermic needle and syringe, with approximately 3 ml clear, slightly viscous liquid obtained. The oral examination was repeated and the appearance was much improved. The previously noted mass-like structure was gone and the arytenoids were more centrally and appropriately located. There was some viscous, saliva-like material in the proximal trachea, which was removed with a



**Figure 2** Photograph of the oral cavity and laryngeal area of the sedated cat demonstrating a large mass (ie, laryngeal cyst) protruding from the left side of the larynx, displacing the arytenoids laterally to the right



**Figure 3** Echolaryngography of the anesthetized cat demonstrating a laryngeal cyst, as outlined by the yellow arrows



**Figure 4** Post-contrast transverse CT image displayed on a soft tissue window width/window level at the level of the first cervical vertebra. A thin-walled, centrally fluid-attenuating structure (marked with a white star) is seen within the left aspect of the larynx. The structure has a thin, contrast-enhancing peripheral rim (white arrow) and occupies more than 50% of the laryngeal lumen

sterile cotton bud. The oral cavity and laryngeal region then appeared normal. The cat was given 0.2mg/kg butorphanol (Torbugesic; Zoetis) and 0.15mg/kg dexamethasone sodium phosphate (Dexamethasone Sodium Phosphate Injection; Vedco) IV to aid recovery and extubated without issue. The patient recovered uneventfully and was discharged the following day. The fluid was submitted for cytological examination, which revealed basophilic mucinous material (consistent with inspissated saliva), mild granulomatous inflammation with evidence of chronic hemorrhage and mild squamous epithelial atypia, which was suspected to be associated with inflammation.

The cat was re-presented 7 weeks later owing to recurrence of the stridorous breathing. Repeat hematology, serum biochemistry, TT4 and urinalysis were within normal limits. A CT scan was performed under general anesthesia, using a Canon Aquilion 16-slice CT Scanner before and after administration of IV contrast medium (Iohexol [Omnipaque; GE Healthcare]) at a dose of 600mgI/kg. The CT examination revealed an irregularly ovoid, fluid-attenuating (average Hounsfield units [HU] 13), poorly marginated structure occupying the left aspect of the laryngeal lumen (Figure 4), with a thin, soft tissue-attenuating (average HU 40) peripheral rim. The center of this structure was non-contrast enhancing,

while the peripheral rim was moderately contrast enhancing (average HU 114). The endotracheal tube deformed the medial aspect of this structure. The right medial retropharyngeal lymph node was moderately enlarged, measuring up to 0.8cm in width and 2.7cm in height, with smooth margination and heterogeneously soft tissue-attenuating parenchyma. There was also a subcutaneous, ovoid, soft tissue-attenuating, non-contrast-enhancing nodule over the right ventral neck that measured 1.3cm in width and 1.1cm in height. The remaining structures were within normal limits.

The cat was moved to the operating room and administered 0.1mg/kg hydromorphone (Hydromorphone Hydrochloride Injection) and 0.65mg/kg ketamine (Ketamine Hydrochloride Injection; Dechra) IV, and a ketamine continuous rate infusion was started at 0.6mg/kg/h. The cat subsequently underwent a ventral laryngotomy and the laryngeal cyst was removed. The right cervical subcutaneous nodule was removed and the right medial retropharyngeal lymph node was biopsied. All samples were submitted for histopathological evaluation. The cat was administered 5.3mg/kg bupivacaine liposome injectable suspension (Nocita; Elanco) via infiltration injection at the surgical site for postoperative analgesia, in addition to a prescription of IV buprenorphine and oral gabapentin.

The cat was given a dose of 0.1mg/kg dexamethasone sodium phosphate preoperatively. The cat was extubated but was unable to oxygenate appropriately on room air and minimal airflow was appreciated through the larynx due to upper airway swelling. The cat was reintubated and gaseous anesthesia was resumed. The surgical site was reopened and a temporary transverse tracheostomy was performed. A 4mm sterile tracheostomy tube was placed and the cat recovered successfully from anesthesia. The tracheostomy tube was removed that evening due to worsening respiratory effort; upon decannulation, the effort improved and it was elected not to replace the tube. There was no obstruction to the tube lumen and it was hypothesized that the tube itself had potentially been positionally obstructing the lumen of the trachea. The tracheostomy site was subsequently partially closed and the cat was discharged 2 days postoperatively with 10mg/kg gabapentin PO q8h as needed for additional analgesia. Histopathology revealed a suspected thyroglossal cyst with minimal lymphoplasmacytic and neutrophilic laryngitis. The submitted tissue consisted of a collapsed cyst lined by low cuboidal epithelium and, being on the midline, was consistent with a thyroglossal duct remnant cyst. The presence of colloid-containing thyroid follicles around the cyst would have been a confirmatory finding; however, they were not seen in the examined sections. There was mild reactive lymphoid hyperplasia in the right medial retropharyngeal lymph node and the subcutaneous nodule was consistent with



a ruptured infundibular cyst. At the last follow-up 7 days postoperatively, the cat had recovered well and had no recurrence of clinical signs.

## Discussion

There is relatively scarce literature on laryngeal disease in cats and current published data are largely suggestive of an underlying neoplastic disease process. This case report highlights that benign etiologies of laryngeal disease in cats should be considered as treatment could be curative.

In human medicine, thyroglossal cysts are the most common congenital neck mass, although laryngeal involvement remains relatively rare, with 19 cases reported over 30 years. The most common clinical signs are hoarseness, dyspnea, dysphagia and stridor. Thyroglossal cysts are thought to originate due to failure of involution of the thyroglossal duct during embryonic development and may be located at the level of the hyoid, suprahyoid or infrahyoid. Surgical excision is recommended, with the approach named the Sistrunk procedure for the surgeon who first described the technique. Risk of recurrence after the procedure is low.<sup>2</sup> The Sistrunk procedure, which includes removal of part of the hyoid bone, was not performed on the cat in this case report.

Another option explored in human medicine is ethanol sclerosis for thyroglossal cyst ablation.<sup>4</sup> A recent meta-analysis concluded that this procedure had acceptable success rates, a low risk of complications and can be considered as a first-line treatment for thyroglossal duct cysts in people, although the overall sample size analyzed was small.<sup>5</sup> This technique could therefore also be considered in cats with this condition, although the authors did not find any reports of attempts thus far in a literature search. However, percutaneous ethanol injection has been attempted in cats with bilateral hyperplastic thyroid nodules and resulted in bilateral fatal laryngeal paralysis in one cat and transient laryngeal paralysis in five cats.<sup>6</sup> Given the relative similarity in the anatomic location of the thyroglossal cyst, this is a complication that would have to be considered should ethanol sclerosis be attempted for thyroglossal cysts in cats.

A retrospective case series of laryngeal, laryngotracheal and tracheal masses in cats reported a diagnosis of neoplasia in 81% of cats, with lymphoma and squamous cell carcinoma the most prevalent tumor type. In this study, a median survival time based on Kaplan–Meier analysis was recorded as 5 days, with the authors reporting that many cats were euthanized at the time of diagnosis.<sup>6</sup> Another retrospective case series of laryngeal disease in cats found that those cats with a diagnosis of neoplasia were most likely to have lymphoma or squamous cell carcinoma. The cats that went on to undergo treatment lived between 60 and

1440 days. The aforementioned case series also highlighted laryngeal paralysis as an important differential for the stridorous cat, citing this as the most frequent underlying cause of clinical signs in the study.<sup>7</sup>

There are contrasting reports of the prognosis with tracheostomy in the cat. Tracheostomy has been previously described as a poor prognostic indicator in cats with laryngeal masses, with those cats requiring the procedure less likely to survive to discharge, although those that required the procedure may have been more severely affected.<sup>3</sup> A retrospective study examining tracheostomy in cats reported a high overall complication rate, with 87% of cats undergoing a potentially life-threatening complication while in hospital; however, 43% of the cats in the study were discharged from the hospital and healed uneventfully after decannulation.<sup>8</sup> As with the cat in the current report, those cats with a benign underlying reason for the tracheostomy were most likely to survive to discharge. The cat in this case required a tracheostomy only briefly postoperatively for recovery from anesthesia, but this case highlights that temporary tracheostomy in benign laryngeal disease can be successful in the cat and should not necessarily be thought of as a poor prognostic indicator. Another option, given the potential for complications with tracheostomy in the cat, is to keep cats undergoing laryngeal surgery intubated and anesthetized for a short period of time should extubation fail. This may allow for any potential postoperative swelling to improve before another attempt at extubation is made, thus avoiding the need for tracheostomy. With hindsight, given that the cat ultimately required a tracheostomy for only a very short period postoperatively, this may have been successful in our case. However, with each extubation attempt there is potential for failure to recapture the airway and need for an emergency tracheostomy, as opposed to a controlled procedure such as was carried out in this case.

A CT scan was employed for localization and planning, prior to surgery during the second presentation of the cat in this case report. However, as with previous reports, echolaryngography was initially undertaken and the cyst drained percutaneously. Echolaryngography has the advantage of being performed in the awake patient and in retrospect could have been employed prior to sedated airway examination in this case. However, correlation of laryngoscopy and echolaryngography is useful for diagnosis of laryngeal cyst, although operator experience may limit the findings of the echolaryngography.<sup>9</sup> Owing to the recurrence of this cyst, CT was pursued for diagnosis and surgical planning. Findings were similar to those previously reported in a puppy with a congenital laryngeal cyst, where CT was also undertaken prior to surgery after initial needle centesis of the cyst.<sup>10</sup> Multiple imaging modalities are thus

useful for definitive diagnosis of laryngeal cystic disease in veterinary species.

With hindsight, the risk of recurrence was high given the clinical signs were caused by a cyst and surgical removal was likely needed for cure. However, at the time of initial sampling, it was unknown what the lesion contained and, once drained, the cyst was no longer visible on ultrasound. Therefore, the owner was instructed to watch carefully for the recurrence of clinical signs and be prepared to pursue further diagnostics (in this case CT) and treatment as required.

## Conclusions

This is only the second report of a laryngeal cyst in the cat. While malignant laryngeal disease may be more prevalent in the cat, benign differentials should be considered as treatment could be curative, as was observed in this case.

**Acknowledgements** The authors would like to thank Dr Robert J McCarthy, Dr Catherine N Stecyk and Dr Noa Berlin for their contributions to this case.

**Conflict of interest** The authors declared no potential conflicts of interest with respect to the research, authorship, and/or publication of this article.

**Funding** The authors received no financial support for the research, authorship, and/or publication of this article.

**Ethical approval** The work described in this manuscript involved the use of non-experimental (owned or unowned) animals. Established internationally recognised high standards ('best practice') of veterinary clinical care for the individual patient were always followed and/or this work involved the use of cadavers. Ethical approval from a committee was therefore not specifically required for publication in *JFMS Open Reports*. Although not required, where ethical approval was still obtained it is stated in the manuscript.

**Informed consent** Informed consent (verbal or written) was obtained from the owner or legal custodian of all animal(s)

described in this work (experimental or non-experimental animals, including cadavers) for all procedure(s) undertaken. No animals or people are identifiable within this publication, and therefore additional informed consent for publication was not required.

**ORCID iDs** Katrina C Manson  <https://orcid.org/0000-0002-8229-6110>

Elizabeth A Rozanski  <https://orcid.org/0000-0003-3233-8930>

## References

- 1 Rudorf H, Lane JG, Brown PJ, et al. **Ultrasonographic diagnosis of a laryngeal cyst in a cat.** *J Small Anim Pract* 1999; 40: 275–277.
- 2 Ng A, Yuen HW and Huang XY. **Atypical thyroglossal duct cyst with intra-laryngeal and para-glottic extension.** *Am J Otolaryngol* 2019; 40: 601–604.
- 3 Jakubiak MJ, Siedlecki CT, Zenger E, et al. **Laryngeal, laryngotracheal, and tracheal masses in cats: 27 cases (1998–2003).** *J Am Anim Hosp Assoc* 2005; 41: 310–316.
- 4 Chow T-L, Choi C-Y and Yee-Hing Hui J. **Thyroglossal duct cysts in adults treated by ethanol sclerotherapy: a pilot study of a nonsurgical technique.** *Laryngoscope* 2012; 122: 1262–1264.
- 5 Park SI, Baek JH, Suh CH, et al. **Chemical ablation using ethanol or OK-432 for the treatment of thyroglossal duct cysts: a systematic review and meta-analysis.** *Eur Radiol* 2021; 31: 9048–9056.
- 6 Wells AL, Long CD, Hornof WJ, et al. **Use of percutaneous ethanol injection for treatment of bilateral hyperplastic thyroid nodules in cats.** *J Am Vet Med Assoc* 2001; 218: 1293–1297.
- 7 Taylor SS, Harvey AM, Barr FJ, et al. **Laryngeal disease in cats: a retrospective study of 35 cases.** *J Feline Med Surg* 2009; 11: 954–962.
- 8 Guenther-Yenke CL and Rozanski EA. **Tracheostomy in cats: 23 cases (1998–2006).** *J Feline Med Surg* 2007; 9: 451–457.
- 9 Rudorf H and Barr F. **Echolarngography in cats.** *Vet Radiol Ultrasound* 2002; 43: 353–357.
- 10 Cuddy LC, Bacon NJ, Coomer AR, et al. **Excision of a congenital laryngeal cyst in a five-month-old dog via a lateral extraluminal approach.** *J Am Vet Med Assoc* 2010; 236: 1328–1333.