



Nasopharyngeal sialocoele with underlying auditory tube neoplasia in a cat

Authors: Fritz, Julien, Belmudes, Audrey, Cauvin, Edouard, Girard, Nicolas, and Rault, Delphine N

Source: Journal of Feline Medicine and Surgery Open Reports, 8(2)

Published By: SAGE Publishing

URL: <https://doi.org/10.1177/20551169221109011>

BioOne Complete (complete.BioOne.org) is a full-text database of 200 subscribed and open-access titles in the biological, ecological, and environmental sciences published by nonprofit societies, associations, museums, institutions, and presses.

Your use of this PDF, the BioOne Complete website, and all posted and associated content indicates your acceptance of BioOne's Terms of Use, available at www.bioone.org/terms-of-use.

Usage of BioOne Complete content is strictly limited to personal, educational, and non - commercial use. Commercial inquiries or rights and permissions requests should be directed to the individual publisher as copyright holder.

BioOne sees sustainable scholarly publishing as an inherently collaborative enterprise connecting authors, nonprofit publishers, academic institutions, research libraries, and research funders in the common goal of maximizing access to critical research.



Nasopharyngeal sialocoele with underlying auditory tube neoplasia in a cat

Julien Fritz¹ , Audrey Belmudes², Edouard Cauvin¹, Nicolas Girard³ and Delphine N Rault¹

Journal of Feline Medicine and Surgery Open Reports
1–4

© The Author(s) 2022

Article reuse guidelines:

sagepub.com/journals-permissions

DOI: 10.1177/20551169221109011

journals.sagepub.com/home/jfmsopenreports

This paper was handled and processed by the European Editorial Office (ISFM) for publication in *JFMS Open Reports*



Abstract

Case summary An 8-year-old cat was presented with recent signs related to upper airway obstruction. CT revealed a hypoattenuating mass, with rim enhancement, in the nasopharynx. Paracentesis yielded a viscous fluid, consistent with saliva on cytology. The sialocoele was aspirated, and surgical excision of the ipsilateral mandibular and sublingual salivary glands was performed. The sialocoele recurred 3 months later, associated with a polypoid structure in the auditory tube region. This was surgically extirpated. Histology was consistent with a tubulopapillary adenocarcinoma.

Relevance and novel information To our knowledge, this is the first case report of a nasopharyngeal sialocoele with confirmed underlying neoplasia in a cat, and the first description of CT imaging features of a nasopharyngeal sialocoele in a cat.

Keywords: Nasopharyngeal; sialocoele; CT; auditory tube; neoplasia

Accepted: 6 May 2022

Introduction

A sialocoele is defined as a localised accumulation of saliva resulting from its extravasation through a tear in a salivary duct. Clinical signs are related to the anatomical location of the sialocoele and its dimensions. The position of the cavity depends on where the tear occurs in the salivary duct. While this condition is common in dogs,^{1,2} sialocoeles have only been reported in 19 cats in the literature.^{3–12} Cats have five major salivary glands (parotid, mandibular, sublingual, molar and zygomatic), and minor salivary glands which cannot be seen on direct examination of the oral cavity (labial, lingual and palatal mucosal salivary glands).^{3,13} Sialocoeles may be associated with any salivary glands in cats,^{4–11} except for the molar gland, which opens directly into the buccal cavity (without a duct).

The cause of sialocoeles is unclear in most cases in cats, as in dogs.² Some authors have suggested that they may be induced by pre-existing conditions, including trauma (as a complication of oral or neck surgery or secondary to penetrating or blunt trauma),^{1,3} salivary obstruction by sialoliths⁵ or glandular duct stenosis.¹⁰ Although considered possible, an underlying neoplasm has never been reported in cats. This article presents an

original case report of a nasopharyngeal sialocoele in a cat, caused by an underlying malignant neoplasm and diagnosed using CT. To our knowledge, neither the CT features nor the neoplastic origin of a nasopharyngeal sialocoele have been previously reported in cats.

Case description

An 8-year-old domestic shorthair neutered male cat was presented with a recent history of dysphagia and upper airway dysfunction, including stridor and orthopnoea. Oral examination revealed ventral protrusion of the

¹Department of Diagnostic Imaging, Azurvet Center of Veterinary Specialists, Saint-Laurent-du-Var, France

²Department of Diagnostic Imaging, Dick White Referrals, Six Mile Bottom, UK

³Department of Dentistry and Maxillofacial Surgery, Azurvet Center of Veterinary Specialists, Saint-Laurent-du-Var, France

Corresponding author:

Delphine N Rault DVM Dip ECVDI, Department of Diagnostic Imaging, Azurvet Center of Veterinary Specialists, 769 Av Pierre et Marie Curie, 06700 Saint-Laurent-du-Var, France
Email: d.rault@azurvet.fr



Creative Commons Non Commercial CC BY-NC: This article is distributed under the terms of the Creative Commons

Attribution-NonCommercial 4.0 License (<https://creativecommons.org/licenses/by-nc/4.0/>) which permits non-commercial use, reproduction and distribution of the work without further permission provided the original work is attributed as specified on the SAGE and Open Access pages (<https://us.sagepub.com/en-us/nam/open-access-at-sage>).

rostral portion of the soft palate (Figure 1), causing decreased pharyngeal lumen.

After premedication using midazolam (Hypnovel; Roche), anaesthesia was induced using intravenous (IV) injection of propofol (Propovet; Zoetis) and continued using inhalation of isoflurane (Vetfluran; Virbac) in oxygen via an endotracheal tube. CT of the head was performed using a 64-slice helical CT scanner (Aquilion 64 system; Toshiba Medical Systems), prior to and 2 mins after IV injection of 2ml/kg iodinated contrast agent (iohexol [Omnipaque; GE Healthcare]). Helical acquisitions were obtained with exposure parameters of 120kV and 100mA, 1 mm slice thickness and a reconstruction interval of 0.3mm. Images were reconstructed using a 512 × 512 matrix, a slice thickness of 1 mm, and both bone and soft tissue kernels.

A round-shaped, well-delineated 15mm diameter lesion was observed at the right dorsal aspect of the nasopharynx (Figure 2). The nodular lesion was hypoattenuating (20 Hounsfield units [HU]) with thin rim

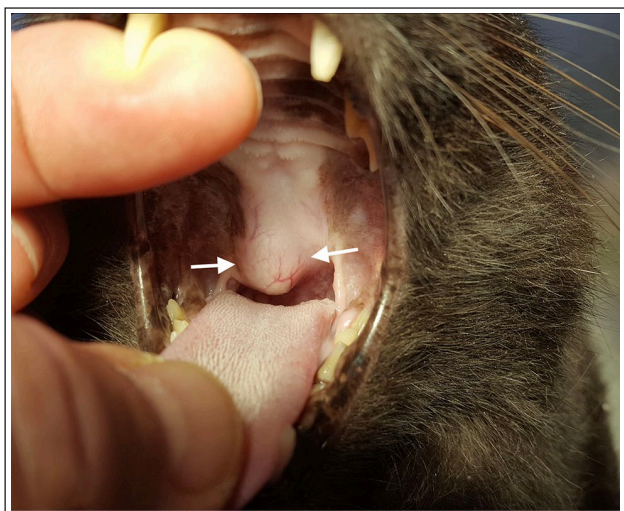


Figure 1 Photograph of the cat at initial presentation with an open mouth, showing the ventral protrusion of the rostral portion of the soft palate (arrows)

enhancement (<1 mm). It was closely associated with, or infiltrated, both the right dorsolateral part of the nasopharynx and the nasal mucosa of the soft palate. The latter was ventrally deviated, the mass filling almost half of the nasopharyngeal lumen. It was also continuous, or in close contact, with another lesion, localised in the vicinity of the right auditory tube. This latter lesion was heterogeneous, moderately enhancing (65–82 HU), with a thick and irregular wall (Figure 3). The right auditory tube was enlarged.

There was bilateral filling of the tympanic bullae with hypoattenuating, fluid density material, although there was mild focal enhancement in the rostralateral compartment of the right tympanic bulla. The osseous wall of the right tympanic bulla was mildly thickened and irregular. There was no other bony deformity in the vicinity of the lesion. Mandibular, lingual and sublingual salivary glands, and sublingual connective soft tissue spaces, were unremarkable. Regional (parotid, mandibular and medial retropharyngeal) lymph nodes had a normal appearance.

Chronic osteitis of the right tympanic bulla was observed and bilateral otitis media was present, possibly secondary to local obstruction of the auditory tubes. Fine-needle aspiration of the cavitory lesion was performed via the oral cavity while the cat was under anaesthesia. Pale-orange viscous fluid (4ml) was aspirated from the lesion. This was consistent with saliva on cytological examination. A diagnosis of pharyngeal sialocoele was thus established.

The pharyngeal sialocoele was freely aspirated, and the mandibular, sublingual monostomatic and sublingual polystomatic glands were surgically removed 1 week after CT. An amoxicillin and clavulanic acid combination was administered orally at a dosage of 15mg/kg q12h (Kesium; CEVA) and meloxicam was administered orally at a dosage of 1 mg/kg q24h (Metacam; Boehringer, Germany) for 5 days postoperatively.

There was spontaneous resolution of the sialocoele in the immediate postoperative period. Fifteen days postoperatively, a fluctuant swelling appeared at the original

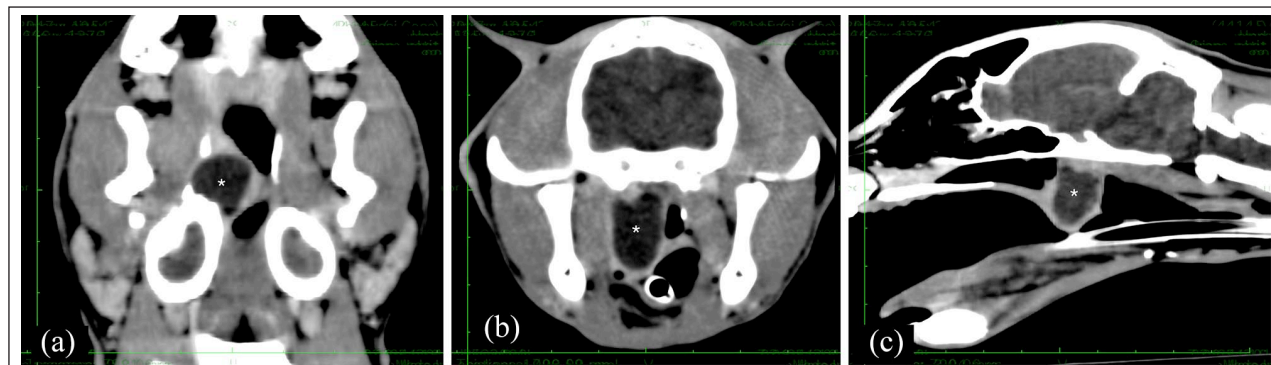


Figure 2 (a) Dorsal, (b) transverse and (c) sagittal plane multiplanar reconstructions of the head using a soft tissue algorithm, post-contrast acquisition, performed at presentation and showing the right lateral pharyngeal sialocoele (asterisk)

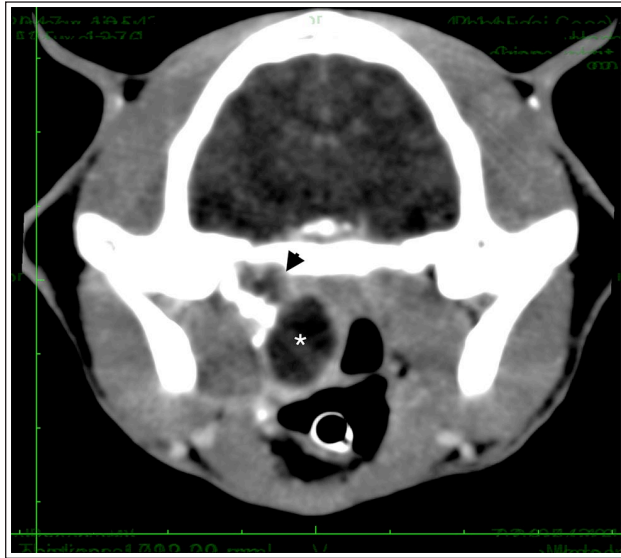


Figure 3 Transverse plane images of the skull using a soft tissue kernel reconstruction, post-contrast acquisition, at the level of the temporomandibular joints, showing the sialocoele (asterisk) and the second lesion, extending into the right auditory tube (arrowhead)

location of the sialocoele, followed by progressive recurrence of the clinical signs over a duration of 4 months. At a 4.5-month follow-up consultation, examination of the oral cavity revealed bulging of the soft palate, in the region of the right auditory tube. Visual oral examination and radiological evaluation using cone beam CT (New Tom 5G; QR) confirmed that the previously described heterogeneous enlargement of the right auditory tube had grown as a tubular mass at the right dorsal aspect of the nasopharynx. This lesion extended towards the right tympanic auditory tube. A neoplastic process of the right auditory tube was suspected.

A week later, partial surgical excision of the nasopharyngeal tubular mass and bulla curettage were performed via a combination of right ventral bulla osteotomy and a transpalatine approach. Postoperative care was unremarkable.

The histopathological findings were consistent with a tubulopapillary adenocarcinoma of the auditory tube, which was consistent with the initial visual examination. The owner declined proposed adjuvant treatments, including chemotherapy and radiation therapy.

Follow-up CT examination was performed 6 months later, owing to recurrence of the clinical signs. A voluminous nasopharyngeal sialocoele, causing partial obstruction of the nasopharynx, was observed. The sialocoele was continuous with a heterogeneous, strongly enhancing tissue-attenuating structure at the right dorsal aspect of the nasopharynx, protruding into the right auditory tube. It was consistent with recurrence/local spread of the tubulopapillary adenocarcinoma. Needle aspiration of the pharyngeal sialocoele was performed to improve the cat's comfort.

Discussion

The differential diagnosis of pharyngeal nodular lesions in cats includes nasopharyngeal polyps, granulomas, cryptococcosis, lymphoma, cysts, abscesses (associated with bacterial inoculation through oral trauma or foreign body penetration) and sialocoeles.^{14,15} In our case, the CT appearance of the lesion, featuring hypoattenuating and unenhanced content with a thin, well-defined rim, was highly suggestive of a sialocoele. This was confirmed cytologically.

Salivary mucocoeles or sialocoeles are a common cause of cervical or intraoral swelling in dogs and less commonly reported in cats.^{3-12,16-18} In one study, the authors reported that the occurrence of mucocoeles in dogs was three times greater than in cats.² Nasopharyngeal sialocoeles appear to be more commonly encountered in brachycephalic dogs, especially in Pugs.¹⁸ There has been one reported case of a cat with a nasopharyngeal sialocoele causing acute respiratory distress.⁴ No diagnostic imaging technique was documented in this report and no underlying cause could be identified. Unlike in previous reports, the clinical signs of dysphagia, stridor and orthopnoea developed gradually in our case. This chronic evolution is, however, described in brachycephalic dogs with nasopharyngeal sialocoeles,¹⁸ with presenting signs of chronic upper airway obstruction, such as snoring, discomfort while sleeping and exercise intolerance.

The tomodensitometric features of this condition have been described in dogs,¹⁷⁻¹⁹ with the lesion presenting as a well-defined, hypoattenuating and non-enhancing mass, surrounded by a thin, contrast-enhancing wall, located at the caudal aspect of the soft palate. Similar features were noted in our case, although the lesion further extended into the enlarged right auditory tube. This was supposedly related to the underlying presence of a neoplastic process within the auditory tube, which could have been suspected since the initial CT examination. In another study,¹⁷ mineralisations were observed in 54% of sialocoeles, although none of them in the nasopharyngeal region. However, this was not the case in this cat.

In previously reported feline sialocoeles, the origins of the lesions were unknown,^{3-7,11,12} except in one animal for whom the lesion was secondary to duct stenosis.¹⁰ In dogs, salivary mucocoeles are more frequently encountered. In our case, the presence of another soft tissue lesion in the enlarged auditory tube was visualised on the first CT examination and further diagnosed as a tubulopapillary adenocarcinoma. We suspected that the neoplastic process may have caused obstruction to the salivary flow because of infiltration of the duct or glandular tissue, or through mechanical obstruction of the duct. In either case, salivary outflow impairment would have led to tearing of the duct or gland, with subsequent leakage and focal accumulation of saliva. The underlying neoplastic process probably accounted for the recurrence, despite surgical treatment as well.

The main salivary glands in cats include the mandibular and sublingual glands, which are closely related, and the zygomatic glands. There are additional minor salivary glands, which cannot be seen on direct examination of the oral cavity, including labial, lingual and palatal mucosal salivary glands.³ A sialocoele related to the minor palatal mucosal salivary gland was considered most likely, although a relationship with the major salivary gland could not be ruled out considering the relatively large volume of the lesion. The elected surgical strategy was therefore believed to be most likely to succeed in this case. Aspiration of the sialocoele and surgical excision of the ipsilateral mandibular and sublingual salivary glands were performed in order to prevent further accumulation of saliva. Recurrence implied that these glands were not implicated in the formation of the sialocoele, and therefore, considering the location, it is likely that the lesion originated from a minor palatal mucosal salivary gland.

It is likely that focal compression or infiltration of the soft palate by the neoplastic process induced the development of the sialocoele in our patient. The owners then declined further surgical treatment and radiotherapy.

Conclusions

This article presents the first description of the tomographic (CT) features of a nasopharyngeal sialocoele in a cat. In our case, it was associated with a neoplastic process in the ipsilateral auditory tube in a cat. The authors suggest considering a sialocoele in the differential diagnosis of hypoattenuating well-defined lesions in the nasopharyngeal region in cats, and that a potential local neoplastic process as an underlying condition should be scrutinised.

Conflict of interest The authors declared no potential conflicts of interest with respect to the research, authorship, and/or publication of this article.

Funding The authors received no financial support for the research, authorship, and/or publication of this article.

Ethical approval The work described in this manuscript involved the use of non-experimental (owned or unowned) animals. Established internationally recognised high standards ('best practice') of veterinary clinical care for the individual patient were always followed and/or this work involved the use of cadavers. Ethical approval from a committee was therefore not specifically required for publication in *JFMS Open Reports*. Although not required, where ethical approval was still obtained it is stated in the manuscript.

Informed consent Informed consent (verbal or written) was obtained from the owner or legal custodian of all animal(s) described in this work (experimental or non-experimental

animals, including cadavers) for all procedure(s) undertaken (prospective or retrospective studies). No animals or people are identifiable within this publication, and therefore additional informed consent for publication was not required.

ORCID ID Julien Fritz  <https://orcid.org/0000-0003-2258-5399>

Nicolas Girard  <https://orcid.org/0000-0001-5423-074X>

References

- 1 Benjamino KP. **Pharyngeal mucoceles in dogs: 14 cases.** *J Am Anim Hosp Assoc* 2012; 48: 31–35.
- 2 Verstraete FJM and Lommer MJ. **Oral and maxillofacial surgery in dogs and cats.** Edinburgh: Saunders, 2012.
- 3 Kiefer KM. **Salivary mucocele in cats: a retrospective study of seven cases.** *Vet Med* 2007; 102: 582–585.
- 4 Feinman JM. **Pharyngeal mucocele and respiratory distress in a cat.** *J Am Vet Med Assoc* 1990; 197: 1179–1180.
- 5 Harrison JD and Garrett JR. **An ultrastructural and histochemical study of a naturally occurring salivary mucocele in a cat.** *J Comp Pathol* 1975; 85: 411–416.
- 6 Hawe RS. **Parotid salivary sialocoele in a cat.** *Feline Pract* 1998; 26: 6–8.
- 7 Rahal SC, Nunes AL, Teixeira CR, et al. **Salivary mucocele in a wild cat.** *Can Vet J* 2003; 44: 933–934.
- 8 Speakman AJ, Baines SJ, Williams JM, et al. **Zygomatic salivary cyst with mucocele formation in a cat.** *J Small Anim Pract* 1997; 38: 468–470.
- 9 Tsioli B. **Sialocoele in the cat: a report of 2 cases.** *J Hellen Vet Med Soc* 2018; 66: 141–146.
- 10 Vallefucio R. **Parotid salivary duct sialocoele associated with glandular duct stenosis in a cat.** *J Feline Med Surg* 2011; 13: 781–783.
- 11 Wallace LJ, Guffy MM, Gray AP, et al. **Anterior cervical sialocoele (salivary cyst) in a domestic cat.** *J Am Anim Hosp Assoc* 1972; 8: 74–78.
- 12 Bassanino J, Palierne S, Blondel M, et al. **Sublingual sialocoele in a cat.** *JFMS Open Rep* 2019; 5. DOI: 10.1177/2055116919833249.
- 13 Dyce KM, Sack WO and Wensing CJG. **Textbook of veterinary anatomy.** 5th ed. Philadelphia, PA: Saunders, 2017.
- 14 Reed N and Gunn-Moore D. **Nasopharyngeal disease in cats: diagnostic investigation.** *J Feline Med Surg* 2012; 14: 306–315.
- 15 Hunt GB, Perkins MC, Foster SF, et al. **Nasopharyngeal disorders of dogs and cats: a review and retrospective study.** *Compend Contin Educ Pract Vet* 2002; 24: 184–200.
- 16 Spangler WL and Culbertson MR. **Salivary gland disease in dogs and cats: 245 cases (1985–1988).** *J Am Vet Med Assoc* 1991; 198: 465–469.
- 17 Oetelaar GS, Heng HG, Lim CK, et al. **Computed tomographic appearance of sialocoele in 12 dogs.** *Vet Radiol Ultrasound* 2022; 63: 30–37.
- 18 De Lorenzi D, Bertinello D, Mantovani C, et al. **Nasopharyngeal sialoceles in 11 brachycephalic dogs.** *Vet Surg* 2018; 47: 431–438.
- 19 Ploypetch S. **Diagnosis of pharyngeal sialocoele in a dog by CT-scan: a case report.** *Thai J Vet Med* 2016; 46: 331–336.