



## **Ventral cervical subcutaneous Aspergillus species fungal granuloma in a cat**

Authors: Bartels, Courtney, Alvarez-Sanchez, Alejandro, Ranganathan, Bharadhwaj, O'Neill, T William, and Townsend, Katy L

Source: Journal of Feline Medicine and Surgery Open Reports, 8(2)

Published By: SAGE Publishing

URL: <https://doi.org/10.1177/20551169221121916>

---

BioOne Complete ([complete.BioOne.org](https://complete.BioOne.org)) is a full-text database of 200 subscribed and open-access titles in the biological, ecological, and environmental sciences published by nonprofit societies, associations, museums, institutions, and presses.

Your use of this PDF, the BioOne Complete website, and all posted and associated content indicates your acceptance of BioOne's Terms of Use, available at [www.bioone.org/terms-of-use](https://www.bioone.org/terms-of-use).

Usage of BioOne Complete content is strictly limited to personal, educational, and non - commercial use. Commercial inquiries or rights and permissions requests should be directed to the individual publisher as copyright holder.

---

BioOne sees sustainable scholarly publishing as an inherently collaborative enterprise connecting authors, nonprofit publishers, academic institutions, research libraries, and research funders in the common goal of maximizing access to critical research.



# Ventral cervical subcutaneous *Aspergillus* species fungal granuloma in a cat

Courtney Bartels<sup>1,2</sup> , Alejandro Alvarez-Sanchez<sup>1</sup>,  
Bharadhwaj Ranganathan<sup>1,2</sup>, T William O'Neill<sup>3,4</sup>  
and Katy L Townsend<sup>1</sup>

*Journal of Feline Medicine and Surgery Open Reports*  
1–6

© The Author(s) 2022

Article reuse guidelines:

sagepub.com/journals-permissions

DOI: 10.1177/20551169221121916

journals.sagepub.com/home/jfmsopenreports

This paper was handled and processed by the American Editorial Office (AAFP) for publication in *JFMS Open Reports*



## Abstract

**Case summary** An 8-year-old domestic longhair cat was evaluated for a right ventral subcutaneous cervical mass. Serial bloodwork and contrast-enhanced cranial and thoracic CT initially lacked ethmoturbinate lysis and showed a progressive, vascularized, right ventral cervical mass involving local lymph nodes. The mass was removed surgically on two occasions. Histopathology and fungal culture were diagnostic for a recurring sclerosing fungal granuloma and pyogranulomatous and eosinophilic lymphadenitis, consistent with *Aspergillus* species. The cat was treated with oral itraconazole; however, owing to the owner's non-compliance in administering the medication and disease progression, the cat was humanely euthanized 3 years after diagnosis.

**Relevance and novel information** The development of a cervical subcutaneous fungal granuloma of *Aspergillus* species in a domestic longhair cat before obvious maxillary, orbital or ethmoturbinate lysis on initial diagnostics is rare and suggests an early onset of lymphatic or hematogenous spread from a suspected nidus of infection within the sinonasal cavity.

**Keywords:** *Aspergillus*; granuloma; fungal; subcutaneous

**Accepted:** 8 August 2022

## Introduction

*Aspergillus* species are a ubiquitous opportunistic fungus found in the environment. It is considered to be an emerging infectious disease that affects mammals worldwide.<sup>1,2</sup> Aspergillosis can be classified as invasive, semi-invasive or non-invasive, and is frequently caused by *Aspergillus fumigatus*, followed by *Aspergillus niger*, *Aspergillus felis* and *Aspergillus fischeri*.<sup>1,3,4</sup> Common sites of infection are the sinus cavity, orbit and thorax, with focal infections reported in the ear canal, cornea, gastrointestinal tract and urinary bladder.<sup>4–8</sup> *Aspergillus* species infection typically occurs through inhalation. Rarely, spread can occur via lymphatic or hematogenous routes. This report documents the development of a cervical subcutaneous *Aspergillus* species granuloma in a cat prior to obvious maxillary or ethmoturbinate lysis, suggesting early-onset lymphatic or hematogenous spread.

## Case description

An 8-year-old male neutered domestic longhair cat weighing 6.54 kg with an unknown vaccination status was referred for a 3-week history of a right ventral

<sup>1</sup>Department of Clinical Sciences, Carlson College of Veterinary Medicine, Oregon State University, Corvallis, OR, USA

<sup>2</sup>Department of Small Animal Clinical Sciences, Michigan State University, East Lansing, MI, USA

<sup>3</sup>Oregon Veterinary Diagnostic Laboratory, Carlson College of Veterinary Medicine, Oregon State University, Corvallis, OR, USA

<sup>4</sup>Digital Pathology, Charles River Laboratories, Ashland, OH, USA

### Corresponding author:

Katy L Townsend BVSc (Hons), MS, DACVS, Department of Clinical Sciences, Carlson College of Veterinary Medicine, Oregon State University, Magruder Hall, 700 SW 30th Street, Corvallis, OR 97331, USA

Email: katy.townsend@oregonstate.edu



Creative Commons Non Commercial CC BY-NC: This article is distributed under the terms of the Creative Commons

Attribution-NonCommercial 4.0 License (<https://creativecommons.org/licenses/by-nc/4.0/>) which permits non-commercial use, reproduction and distribution of the work without further permission provided the original work is attributed as specified on the SAGE and Open Access pages (<https://us.sagepub.com/en-us/nam/open-access-at-sage>).

cervical mass. Primary care complete blood count (CBC) and serum biochemistry revealed hyperglobulinemia (8.7 g/dl; reference interval [RI] 2.9–4.7) as the only clinically significant finding.

On presentation, physical examination revealed a large, subcutaneous, mobile mass (30 mm × 25 mm) in the right ventral cervical region. CBC showed no clinically significant findings. Serum biochemistry revealed mild hypoalbuminemia (2.4 g/dl; RI 2.6–4.0) and hyperglobulinemia (7.4 g/dl; RI 2.9–4.7). Feline leukemia virus antigen and feline immunodeficiency antibody SNAP tests (IDEXX Laboratory) were negative. The patient was sedated with dexmedetomidine 0.005 mg/kg (Dexdomitor; Orion Pharma) and butorphanol 0.3 mg/kg intravenously (Torbutrol; Bristol-Myers). Cranial, cervical and thoracic CT scans were acquired (Aquilion 64 slice, 36-5 [Toshiba] and Tsurumichuo 4-chrome [Tsurumi-Ku]) before and after intravenous injection of iodinated contrast medium (1.83 ml/kg iodixanol [Isovue 300; General Electric Healthcare]). Images revealed lymphadenopathy of the right medial retropharyngeal lymph node (RMRLN; 39 mm × 18 mm × 19 mm) and right mandibular lymph node (RMLN; 12 mm × 14 mm × 7 mm), bilateral non-destructive rhinitis with soft tissue attenuating and non-contrast-enhancing material in the frontal sinus and right sphenoid sinus causing ill-defined turbinate margins and no maxillary or ethmoturbinate lysis. Cytology of the mass showed plasma cell proliferation, eosinophilia and mast cells, suggestive of a reactive lymph node. Serum protein electrophoresis (SPE; IDEXX Laboratory) was consistent with a polyclonal gammopathy with severe hypergammaglobulinemia of 5.33 g/dl (RI 0.3–2.5). The owner declined additional diagnostics at this time.

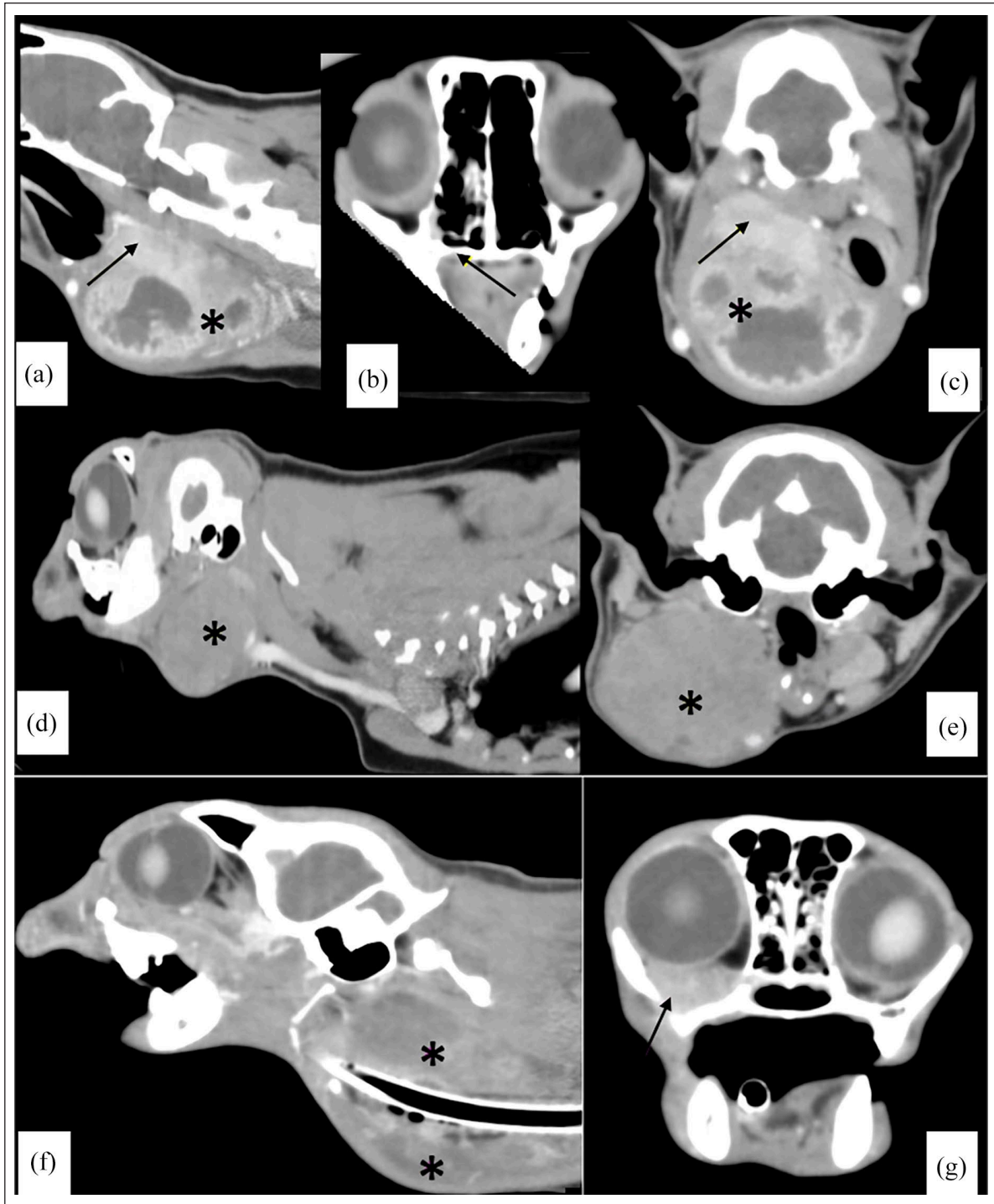
Five months later, the cat re-presented for progression of the mass (45 mm × 45 mm). Chemistry revealed persistent hypoalbuminemia (2.5 g/dl; RI 2.6–4.9) and hyperglobulinemia (8.4 g/dl; RI 2.9–4.7). Cervical and thoracic CT was repeated under sedation as previously described, revealing a large right ventral cervical mass with ill-defined margins causing deviation of the hyoid bones, the base of the tongue, larynx and pharynx to the left. There was also bilateral mandibular lymphadenopathy (right 12 mm × 14 mm × 7 mm; left 5 mm × 5 mm × 6 mm) and severe enlargement of the RMRLN (50 mm × 41 mm × 47 mm; Figure 1). Cytology of the RMLN showed lymphoid reactivity with mixed inflammation and no evidence of neoplasia. Ultrasound-guided fine-needle aspiration of the mass, liver and spleen were performed. Cytology of the mass was inconclusive, whereas the liver and spleen showed marked plasmacytosis. Surgical excision with histopathology of the RMLN and cervical mass was recommended and pursued. Histopathology of the lymph node diagnosed sclerosing pyogranulomatous eosinophilic lymphadenitis with fungal hyphae. The cervical mass was a pyogranuloma with numerous branching hyphae (Figure 2). Fungal

cultures were not performed. The patient was given robenacoxib (1 mg/kg PO [Onsior; Elanco]) once after surgery and discharged with buprenorphine (0.01 mg/kg oral transmucosally [OTM] q8h [Buprenex; Indivior]) and liquid suspension itraconazole (5.05 mg/kg PO q24h [Sporanox; Janssen Pharmaceutica]). However, owing to difficulty administering at home, the patient only received one dose of itraconazole.

The patient re-presented 17 months postoperatively for suspected recurrence of the cervical fungal granuloma. Physical examination revealed a firm, lobulated right subcutaneous ventral cervical mass (50 mm × 30 mm) near the scar of the previous excision site. The right superficial cervical lymph node (RSCLN) was firm and enlarged on palpation (15 mm in length). CBC, serum biochemistry and CT were repeated and compared with previous visits. Anemia (hematocrit 27%; RI 30–45%), lymphopenia (679/μl; RI 1500–7000), hypoalbuminemia (2.5 g/dl; RI 2.6–4.0) and hyperglobulinemia (9.2 g/dl; 2.9–4.7) were identified. Imaging revealed an enlarged right cervical mass, left mandibular lymphadenopathy, decreased lung lobe sizes and tortuosity of the cranial mediastinal blood vessels (Figure 1). Cytology of the mass revealed mixed inflammation with intralesional fungi. Marginal surgical excision of the recurring fungal granuloma and RSCLN were performed and submitted for histopathological analysis and fungal culture.

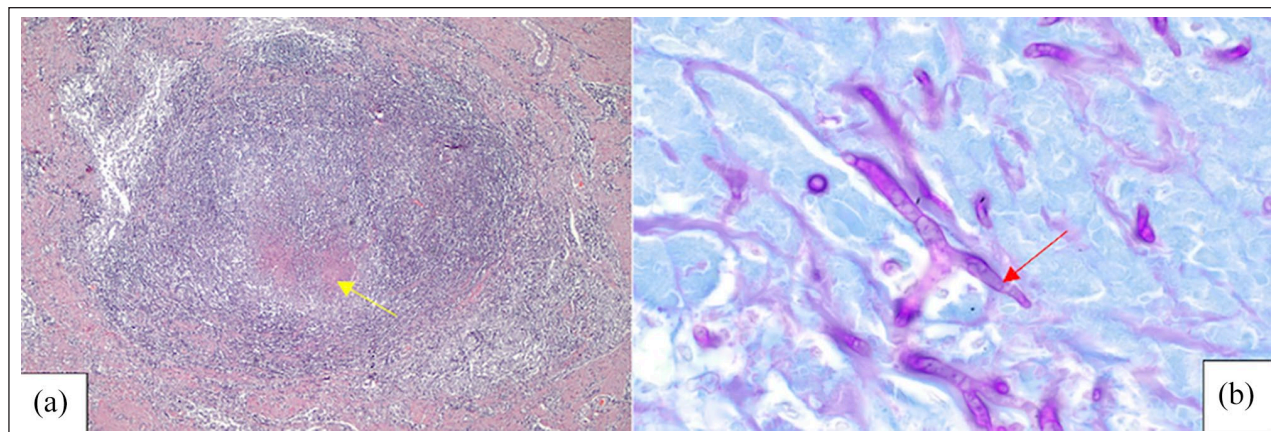
Histopathology yielded similar results: pyogranulomatous lymphadenitis with intralesional fungal hyphae (Figure 3). Fungal culture revealed *Aspergillus* species characterized by branching fungal hyphae with roughly parallel walls and Grocott's methenamine silver (GMS) and periodic acid–Schiff (PAS) confirmed recurrence. Speciation was not performed. The patient was discharged with gabapentin (10 mg/kg PO q8h [Neurontin; Pfizer]), robenacoxib (1 mg/kg PO q24h), liquid suspension itraconazole (5.05 mg/kg PO q24h) and buprenorphine (0.01 mg/kg OTM q8h).

The cat re-presented 11 months after the second surgery for acute respiratory distress. Liquid suspension itraconazole (5.05 mg/kg PO q24h) had not been administered as instructed. Physical examination revealed a firm, lobulated, subcutaneous mass (120 mm × 40 mm) in the left ventral cervical region, immediately caudal to the mandible. A gallop rhythm with a grade 4/6 left parasternal systolic murmur was auscultated. CBC revealed a non-regenerative anemia (hematocrit 15.2% [RI 30–45%]; reticulocytes 6800/μl [RI 0–50,000]). Doppler blood pressure was 112 mmHg. An echocardiogram showed left ventricle thickening with mitral regurgitation and turbulent outflow, consistent with hypertrophic cardiomyopathy without signs of heart failure. Contrast-enhanced cranial and thoracic CT was repeated, showing a large mass (56 mm × 38 mm × 34 mm) extending from the right retrobulbar region to the nasopharynx, caudally to the thoracic inlet, causing rightward deviation of the hyoid apparatus, larynx, trachea, thyroid



**Figure 1** (a) Sagittal, soft tissue window, contrast-enhanced CT of the cervical region 5 months after initial presentation. Note the severely enlarged, progressive, well-vascularized right ventral cervical mass (asterisk) with involvement of the right medial retropharyngeal lymph node (arrow). (b) Transverse, soft tissue window, contrast enhanced CT of nasal cavity. Note the minimal soft tissue opacity in the nasal cavity and no bony lysis (arrow). (c) Transverse, soft tissue window, contrast-enhanced CT of the cranial cervical region. Note the mass (asterisk) and the right medial retropharyngeal lymph node (arrow). (d) Sagittal, soft tissue window CT of the cervical region with iodinated contrast 22 months after initial presentation. Note the mass (asterisk). (e) Transverse, soft tissue window CT of the cervical region with iodinated contrast. Note the enlarged right ventral cervical mass (asterisk). (f) Sagittal, soft tissue window CT of the cervical region with iodinated contrast 33 months after initial presentation. Note the retrobulbar mass effect, as well as the cervical mass dorsal and ventral to the trachea (asterisks). (g) Transverse, soft tissue window CT of the cervical region with iodinated contrast. Noted the mass effect displacing the right globe (arrow)





**Figure 2** (a) Hematoxylin and eosin photomicrograph ( $\times 40$ ) of the granuloma effacing lymph node. Note the central area of necrotic debris containing frequent eosinophils and degenerate neutrophils surrounded by concentric rings of epithelioid macrophages, lymphocytes and a fibrous capsule (yellow arrow). (b) Periodic acid–Schiff stain ( $\times 1000$ ) of the granuloma effacing lymph node. Note the numerous intralesional fungal hyphae (red arrow)

glands and cervical esophagus, as well as displacement of the right globe (Figure 1). The left lateral mandibular lymph node was enlarged ( $12\text{ mm} \times 7\text{ mm}$ ). The left common carotid artery coursed through the mass, and there was sternal and cranial mediastinal lymphadenopathy, in addition to a pulmonary nodule within the left caudal lung lobe. There was marked loss of endoturbinates of the right and left nasal cavity, with soft tissue-attenuating material within the lateroventral aspect of the right nasal cavity. Given the extent of the fungal granuloma and recurring nature, surgical resection was not advised, and the cat was humanely euthanized without necropsy.

## Discussion

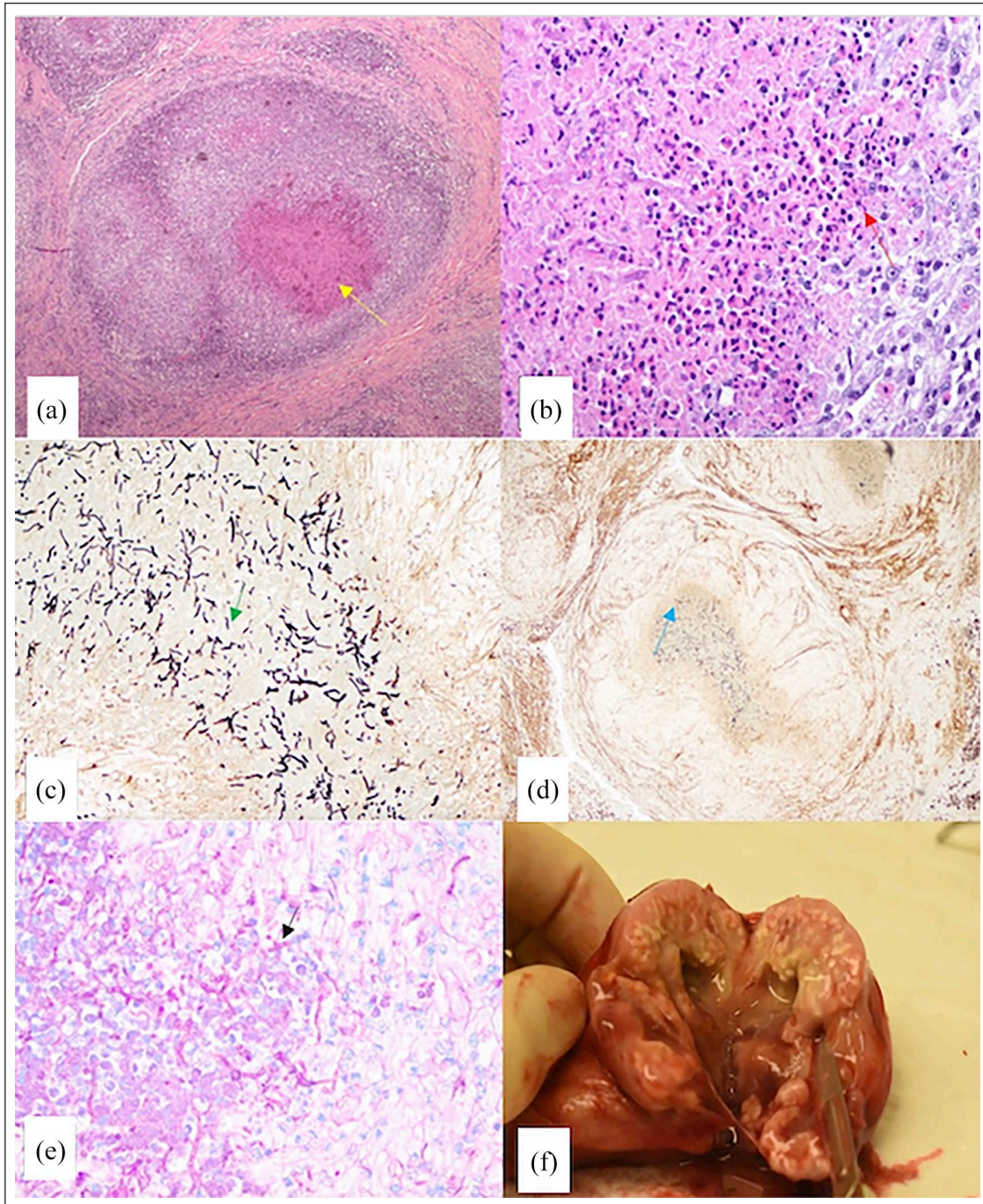
This report is of an *Aspergillus* species granuloma forming in the subcutaneous ventral cervical region of a cat suspected to be secondary to hematogenous or lymphatic dissemination from the nasal cavity. Initial diagnosis of *Aspergillus* species was achieved based on surgical excision and histopathology. Recurrence was diagnosed based on repeat surgical excision, histopathology, histochemical stains (GMS and PAS; Figures 2 and 3) and fungal culture. Histopathology revealed severe pyogranulomatous and eosinophilic lymphadenitis with numerous intralesional, branching and fungal hyphae with parallel walls, findings consistent with previously described aspergillosis cases.<sup>2–4</sup>

Serial chemistries showed persistent hyperglobulinemia, the most frequently reported laboratory abnormality associated with aspergillosis.<sup>9–12</sup> Similar changes can be found with neoplastic processes; therefore, SPE was pursued. These results were consistent with a polyclonal gammopathy, signifying an underlying inflammatory or infectious disease rather than neoplasm. Cytology and histopathology were used to identify the presence of fungal hyphae.<sup>2</sup> These results, in conjunction with results from the SPE, confirmed *Aspergillus* species infection.

Cranial CT showed evidence of nasal disease in this patient at presentation. Given the presence of soft tissue-attenuating material within the nasal cavity without associated bone lysis, it is possible that the cat initially had rhinosinusitis or allergic rhinitis. Similar ventral distribution of fluid and soft tissue material was seen in a series of cats with rhinitis.<sup>13</sup> Sinonasal neoplasia and fungal infections are also frequently associated with paranasal bone lysis at the time of diagnosis, yet there was no evidence of bone lysis in this cat at presentation.<sup>14,15</sup> Additionally, hyperattenuating soft tissues were commonly seen in a study of cats with sinonasal fungal disease yet similar enhancement following contrast injection was not seen in this cat.<sup>15</sup> Had bone and/or nasal turbinate destruction been noticed at the time of the initial CT, rhinoscopy, biopsy and culture sample acquisition would have been recommended for further evaluation.

Without bone lysis, we suspect the fungus metastasized to the cervical integument and lymph nodes via hematogenous or lymphatic routes from the nasal cavity. There are reports of rare focal infections within the urinary bladder and gastrointestinal tract.<sup>4–8</sup> However, these dissemination routes could have resulted from an ascending infection through the urinary system or oral ingestion, respectively. It appears that this route of dissemination in cats may occur more frequently than initially thought in the absence of ethmoturbinate lysis. In addition, the feline report by Cormack and colleagues had primary dissemination to adjacent tissue planes through the naso-orbital structures and respiratory system.<sup>16</sup> These routes account for the most common dissemination paths and are classically associated with upper respiratory signs and/or epistaxis.<sup>2</sup> Orbital bone lysis was not documented in our cat until 22 months after presentation. Albeit rare, we caution readers that dissemination to the integument and locoregional lymph nodes can occur without apparent sinonasal symptomatology.





**Figure 3** (a) Hematoxylin and eosin (HE) stain ( $\times 40$ ) of the granuloma. Note the frequent eosinophils and degenerate neutrophils surrounded by concentric rings of epithelioid macrophages, lymphocytes and a fibrous capsule (yellow arrow). (b) HE stain ( $\times 400$ ) of the edge of granuloma with rare fungal hyphae. Note that eosinophils and necrotic debris dominate this area with rare eosinophilic fungal hyphae. The right side of the image shows the internal edge of the granuloma, with foamy macrophages and scattered small lymphocytes (red arrow). (c) Grocott's methenamine silver stain ( $\times 40$ ) of the same granuloma as (a). Note the abundance of fungal hyphae within the center of the granuloma (green arrow). (d) Grocott's methenamine silver stain ( $\times 400$ ) of the same granuloma as (b). Note the fungal morphology, which consists of fungal hyphae of 3–6  $\mu\text{m}$  width with roughly parallel walls, regular branching and variable angles ranging from approximately  $45^\circ$  to  $90^\circ$  (blue arrow). (e) Periodic acid–Schiff stain ( $\times 400$ ) of the same granuloma as (b) and (d). Note the fungal hyphae, in addition to the previously described features (black arrow). (f) Ventral cervical fungal granuloma. On removal, the granuloma had coalescing pyogranulomas, eosinophilic infiltrates, supported by mature fibrocollagenous tissue, necrotic tissue, hemorrhage and collagen degeneration, as well as numerous branching hyphae with inflammatory infiltrates. A diagnosis of severe sclerosing pyogranulomatous and eosinophilic lymphadenitis associated with intralésional fungi was determined

Although no prospective case-controlled studies exist on the treatment of feline aspergillosis cases, the prognosis for non-invasive aspergillosis is relatively good when appropriately treated, whereas the prognosis of the invasive form is relatively poor, despite treatment.<sup>2,9,17</sup> *Aspergillus* species infections are typically treated with topical or systemic antifungals. Correct identification via molecular testing and antifungal susceptibility is instrumental in guiding therapy and limit azole cross-resistance.<sup>18</sup> Molecular testing and early fungus speciation could have been used to guide antifungal selection; however, neither were performed. Most cryptic species of *Aspergillus* are resistant to itraconazole,<sup>19</sup> yet this antifungal was selected as it is usually effective against *Aspergillus fumigatus*.

## Conclusions

Feline aspergillosis is an emerging disease, with a growing number of cases and novel tissue involvement. Species identification is crucial to tailor treatment protocols. This report documents a case of suspected lymphatic or hematogenous dissemination of sinonasal aspergillosis to cervical lymph nodes and subcutaneous tissues in a cat years before suffering from paranasal bone destruction, warranting consideration as a differential.


**Conflict of interest** The authors declared no potential conflicts of interest with respect to the research, authorship, and/or publication of this article.

**Funding** The authors received no financial support for the research, authorship, and/or publication of this article.

**Ethical approval** The work described in this manuscript involved the use of non-experimental (owned or unowned) animals. Established internationally recognized high standards ('best practice') of veterinary clinical care for the individual patient were always followed and/or this work involved the use of cadavers. Ethical approval from a committee was therefore not specifically required for publication in *JFMS Open Reports*. Although not required, where ethical approval was still obtained, it is stated in the manuscript.

**Informed consent** Informed consent (verbal or written) was obtained from the owner or legal custodian of the animal(s) described in this work (experimental or non-experimental animals, including cadavers) for all procedure(s) undertaken (prospective or retrospective studies). No animals or people are identifiable within this publication, and therefore additional informed consent for publication was not required.

**ORCID iD** Courtney Bartels  <https://orcid.org/0000-0002-3145-3278>

Katy L Townsend  <https://orcid.org/0000-0001-6405-0793>

## References

- 1 Sykes J. Canine and feline infectious diseases. St Louis, MO: Elsevier Saunders, 2014.
- 2 Hartmann K, Lloret A, Pennisi MG, et al. **Aspergillosis in cats: ABCD guidelines on prevention and management.** *J Feline Med Surg* 2013; 15: 605–610.
- 3 Barrs VR and Talbot JJ. **Feline aspergillosis.** *Vet Clin North Am Small Anim Pract* 2014; 44: 51–73.
- 4 Goodale EC, Outerbridge CA and White SD. **Aspergillus otitis in small animals – a retrospective study of 17 cases.** *Vet Dermatol* 2016; 27. DOI: 10.1111/vde.12283.
- 5 Adamama-Moraitou K, Paitaki C, Rallis T, et al. **Aspergillus species cystitis in a cat.** *J Feline Med Surg* 2001; 3: 31–34.
- 6 Hazell K, Swift I and Sullivan N. **Successful treatment of pulmonary aspergillosis in a cat.** *Aust Vet J* 2011; 89: 101–104.
- 7 Labelle AL, Hamor RE, Barger AM, et al. **Aspergillus flavus keratomycosis in a cat treated with topical 1% voriconazole solution.** *Vet Ophthalmol* 2009; 12: 48–52.
- 8 Stokes R. **Intestinal mycosis in a cat.** *Aust Vet J* 1973; 49: 499–500.
- 9 Barrs VR, Halliday C, Martin P, et al. **Sinonasal and sino-orbital aspergillosis in 23 cats: aetiology, clinicopathological features and treatment outcomes.** *Vet J* 2012; 191: 58–64.
- 10 Hamilton H, Whitley R and McLaughlin S. **Exophthalmos secondary to aspergillosis in a cat.** *J Am Anim Hosp Assoc* 2000; 36: 343–347.
- 11 McLellan GJ, Aquino SM, Mason DR, et al. **Use of posaconazole in the management of invasive orbital aspergillosis in a cat.** *J Am Anim Hosp Assoc* 2006; 42: 302–307.
- 12 Smith LN and Hoffman SB. **A case series of unilateral orbital aspergillosis in three cats and treatment with voriconazole.** *Vet Ophthalmol* 2010; 13: 190–203.
- 13 Tromblee T, Jones J, Etue A, et al. **Association between clinical characteristics, computed tomography characteristics, and histologic diagnosis for cats with sinonasal disease.** *Vet Radiol Ultrasound* 2006; 47: 241–248.
- 14 Scheonborn W, Wisner E, Kass P, et al. **Retrospective assessment of computed tomographic imaging of feline sinonasal disease in 62 cats.** *Vet Radiol Ultrasound* 2003; 44: 185–195.
- 15 Karnik K, Reichle J, Fischetti A, et al. **Computed tomographic findings of fungal rhinitis and sinusitis in cats.** *Vet Radiol Ultrasound* 2009; 50: 65–68.
- 16 Cormack C, Donahoe J, Talbot J, et al. **Disseminated invasive aspergillosis caused by *Aspergillus felis* in a cat.** *J Vet Intern Med* 2021; 35: 2395–2400.
- 17 Barrs VR and Talbot JJ. **Fungal rhinosinusitis and disseminated invasive aspergillosis in cats.** *Vet Clin North Am Small Anim Pract* 2020; 50: 331–357.
- 18 Barrs VR. **Feline aspergillosis.** In: Seyedmousavi S, de Hoog GS, Guillot J, et al (eds). *Emerging and epizootic fungal infections in animals.* Cham: Springer, 2018, pp 337–356.
- 19 Ghannoum MA and Rice LB. **Antifungal agents: mode of action, mechanisms of resistance, and correlation of these mechanisms with bacterial resistance.** *Clin Microbiol Rev* 1999; 12: 501–517.