



Zinc toxicosis in a cat associated with ingestion of a metal screw nut

Authors: Yu, Jane, Jenkins, Elizabeth, Podadera, Juan M, Proschogo, Nicholas, Chan, Ringo, et al.

Source: Journal of Feline Medicine and Surgery Open Reports, 8(2)

Published By: SAGE Publishing

URL: <https://doi.org/10.1177/20551169221136464>

BioOne Complete (complete.BioOne.org) is a full-text database of 200 subscribed and open-access titles in the biological, ecological, and environmental sciences published by nonprofit societies, associations, museums, institutions, and presses.

Your use of this PDF, the BioOne Complete website, and all posted and associated content indicates your acceptance of BioOne's Terms of Use, available at www.bioone.org/terms-of-use.

Usage of BioOne Complete content is strictly limited to personal, educational, and non - commercial use. Commercial inquiries or rights and permissions requests should be directed to the individual publisher as copyright holder.

BioOne sees sustainable scholarly publishing as an inherently collaborative enterprise connecting authors, nonprofit publishers, academic institutions, research libraries, and research funders in the common goal of maximizing access to critical research.



Zinc toxicosis in a cat associated with ingestion of a metal screw nut

Jane Yu¹, Elizabeth Jenkins¹, Juan M Podadera¹, Nicholas Proschogo², Ringo Chan¹ and Lara Boland¹

Journal of Feline Medicine and Surgery Open Reports
1–5

© The Author(s) 2022

Article reuse guidelines:

sagepub.com/journals-permissions

DOI: 10.1177/20551169221136464

journals.sagepub.com/home/jfmsopenreports

This paper was handled and processed by the European Editorial Office (ISFM) for publication in *JFMS Open Reports*



Abstract

Case summary A 3-year-old female neutered domestic shorthair cat was presented for vomiting, inappetence and weight loss. The cat developed moderately regenerative anaemia, moderately increased alanine transaminase and alkaline phosphatase activities, hyperbilirubinaemia and prolonged activated partial thromboplastin time. Abdominal ultrasound identified gastric wall thickening and changes suggestive of pancreatitis. Gastroduodenoscopy identified a metal screw nut in the pylorus, which was removed with rat tooth forceps. Metal analysis and serum zinc concentration using leftover serum collected at admission were performed after screw nut removal. Serum zinc concentration was markedly elevated, confirming a diagnosis of zinc toxicosis. Metal analysis of the screw nut showed that the major metal component was zinc. The cat recovered after screw nut removal and supportive care. Clinical signs resolved and the serum zinc concentration reduced significantly after screw nut removal.

Relevance and novel information Reports of zinc toxicosis in cats are scarce, possibly due to the more discriminating eating habits of this species. To our knowledge, this is the first report of zinc toxicosis causing haemolytic anaemia, liver enzyme activity increases, gastrointestinal signs and pancreatitis in a cat associated with ingestion of a zinc-containing metal object.

Keywords: Zinc toxicosis; haemolytic anaemia; liver; pancreatitis

Accepted: 15 October 2022

Case description

A 3-year-old female neutered domestic shorthair cat was presented to the emergency service as a referral for 2 weeks of inappetence and weight loss. One week earlier the cat was presented to the local veterinarian for inappetence, vomiting and 600 g weight loss. Haematology was unremarkable. Biochemistry revealed mildly increased alanine transaminase (ALT) (131 U/l; reference interval [RI] 12–130) and alkaline phosphatase (ALP) (256 U/l; RI 14–111). The cat was treated with intravenous (IV) fluids, amoxicillin–clavulanic acid, gabapentin, maropitant, mirtazapine and buprenorphine, and was discharged after 24 h. Five days later, inappetence continued and the cat was administered diazepam IV and dexamethasone subcutaneously to stimulate appetite. The cat then presented 1 day later for persistent inappetence and was treated with sucralfate before being transferred to the emergency service. The cat had no known history of access to toxins or foreign bodies.

Physical examination at referral revealed that the cat was quiet, alert and responsive, had pale-pink mucous membranes, tachycardia (200 beats/min), tachypnoea (60 breaths/min) and a body condition score (BCS) of 3/9. Packed cell volume (PCV) was 18% with a total protein of 66 g/l. Haematology showed a normocytic normochromic moderately regenerative anaemia with a haematocrit of 0.151/l (RI 0.25–0.48), an absolute reticulocyte count of $102 \times 10^9/l$ (RI 3–50) and moderate

¹Sydney School of Veterinary Science, Faculty of Science, The University of Sydney, NSW, Australia

²School of Chemistry, Faculty of Science, University of Sydney, Sydney, NSW, Australia

Corresponding author:

Jane Yu BVSc, MANZCVS, Small Animal Medicine, Sydney School of Veterinary Science, University of Sydney, 65 Parramatta Road, Sydney, NSW 2006, Australia
Email: jane.yu@sydney.edu.au



Creative Commons Non Commercial CC BY-NC: This article is distributed under the terms of the Creative Commons

Attribution-NonCommercial 4.0 License (<https://creativecommons.org/licenses/by-nc/4.0/>) which permits non-commercial use, reproduction and distribution of the work without further permission provided the original work is attributed as specified on the SAGE and Open Access pages (<https://us.sagepub.com/en-us/nam/open-access-at-sage>).

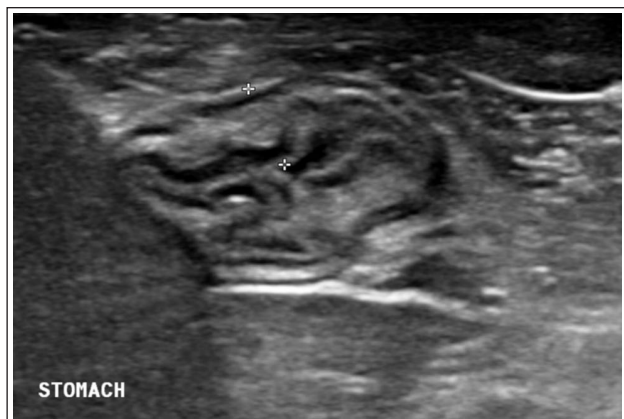

Figure 1 Diffuse concentric submucosal thickening of the gastric wall as shown on abdominal ultrasound

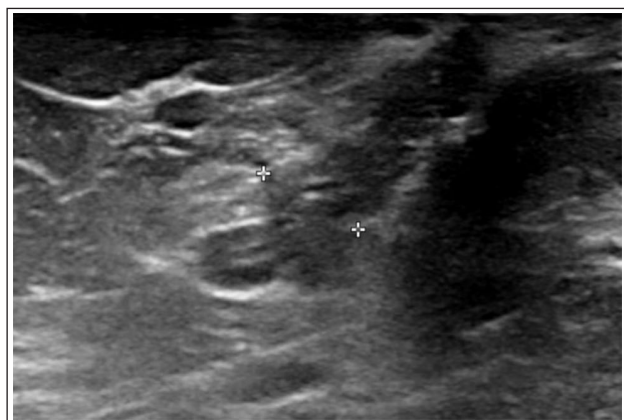

Figure 2 A hypoechoic pancreas with a mild increase in peripancreatic peritoneal echogenicity as shown on abdominal ultrasound

neutrophilia of $20.8 \times 10^9/l$ (RI 2–13). Differential diagnoses for anaemia included haemolysis or haemorrhage. Biochemistry showed moderately increased ALT (249 U/l; RI <60) and ALP activity (277 U/l; RI <50), mild hyperbilirubinemia (10.6 $\mu\text{mol/l}$; RI 2.5–3.5) and mild hypercholesterolaemia (6 mmol/l; RI 1.9–3.9). Point-of-care feline leukaemia virus antigen and feline immunodeficiency virus antibody tests were negative. The activated partial thromboplastin time (APTT) was mildly prolonged at 132.0s (RI 65–119) and prothrombin time (PT) was within the RI at 19.0s (RI 15–22). Abdominal ultrasound identified diffuse concentric submucosal thickening of the gastric wall (wall thickness 0.3 cm; Figure 1) and a hypoechoic pancreas with a mild increase in peripancreatic peritoneal echogenicity (Figure 2). Ultrasonographic findings were suggestive of an intramural gastropathy and pancreatitis. Samples were sent for haemotropic mycoplasma PCR (*Mycoplasma haemofelis*, *Candidatus Mycoplasma haemominutum* and

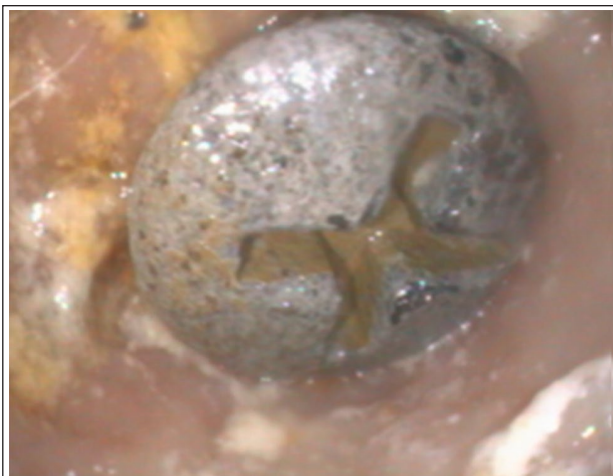


Figure 3 The metal screw nut was identified at the pylorus during endoscopy

Candidatus Mycoplasma turicensis), faecal PCR (feline coronavirus, *Trichostrongylus axei*, *Cryptosporidium* species, panleukopenia virus, *Clostridium perfringens*, *Giardia* species, *Salmonella* species, *Toxoplasma gondii*, *Campylobacter jejuni* and *Campylobacter coli*) and faecal flotation to investigate possible causes of the regenerative anaemia and gastrointestinal signs. The cat was treated with esomeprazole (1 mg/kg IV q12h) and vitamin K1 (3.8 mg/kg PO q12h). PCV decreased to 12% over 8h with a total protein of 68 g/l, and the cat received a 45 ml type A fresh whole-blood transfusion, after blood typing. The next day, PCV was 20% and the cat was eating. The cat was discharged with omeprazole (1.9 mg/kg PO q12h), sucralfate (0.1 g/kg PO q8h), marbofloxacin (4.8 mg/kg PO q24h) and vitamin K1 (3.8 mg/kg PO q12h) while test results were pending. Further diagnostic tests, including abdominal radiographs and endoscopy, were declined due to financial constraints.

Two days later, the cat presented for recurrent inappetence. Haematology revealed a non-regenerative anaemia with a haematocrit of 0.17 l/l and a mild neutrophilia ($15.3 \times 10^9/l$). Gastroduodenoscopy was performed under general anaesthesia to investigate a possible gastrointestinal cause of inappetence, weight loss and anaemia. A non-obstructive metal object (the nut of a cam lock screw used in flat-packed household furniture) was found in the pylorus and was removed with rat tooth forceps (Figures 3 and 4). Re-inspection of the pyloric region identified a minor erosion (Figure 5). The rest of the stomach, oesophagus and duodenum were unremarkable. An oesophageal feeding tube was placed and treatment included IV fluid therapy, omeprazole, vitamin K1, sucralfate, marbofloxacin, mirtazapine (1.4 mg/kg PO q72h) and maropitant (1.5 mg/kg PO q24h).



Figure 4 The metal screw nut was removed with a small amount of gastric material (food)

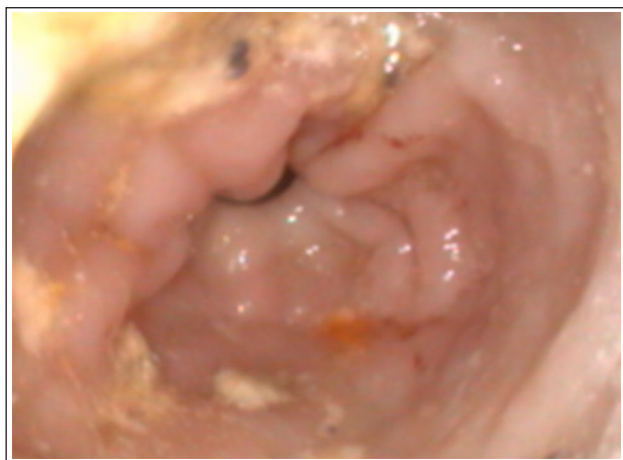

Figure 5 Re-inspection of pyloric region identified a minor erosion

Two days later, PCV was 20% with a total protein of 60 g/l. The cat started eating consistently and the feeding tube was removed after 6 days. Haemotropic mycoplasma PCR, faecal flotation and PCR were negative. The cat was discharged with mirtazapine only and the rest of the medications were discontinued. Body weight at discharge was 2.4 kg. After screw nut removal, metal analysis and serum zinc concentration using leftover serum collected at admission were performed. Serum zinc concentration, available 25 days later, showed a markedly

Table 1 Inductively coupled plasma mass spectrometry metal analysis of the screw nut (weight 1.340 g)

Metal	Concentration (µg/g screw nut)	Composition (%)
Zinc 66	250.835	82.191
Aluminium 27	35.596	11.664
Copper 63	13.313	4.362
Phosphorus 31	3.445	1.129
Iron 57	0.605	0.198
Sodium 23	0.444	0.146
Cadmium 111	0.202	0.066
Nickel 60	0.177	0.058
Lead 206	0.135	0.044
Lead 208	0.135	0.044
Lead 207	0.133	0.044
Potassium 39	0.090	0.030
Selenium 82	0.031	0.010
Cobalt 59	0.012	0.004
Magnesium 24	0.011	0.004
Chromium 52	0.007	0.002
Titanium 47	0.004	0.001
Manganese 55	0.004	0.001
Zirconium 90	0.003	0.001
Gold 197	0.002	0.001
Vanadium 51	0.001	0.0003
Silver 197	0.001	0.0003
Silicon 28	ND	ND
Mercury 202	ND	ND
Sulfur 32	ND	ND
Calcium 43	ND	ND
Arsenic 75	ND	ND
Strontium 88	ND	ND
Barium 138	ND	ND

ND = below the limit of detection

elevated concentration at 448 µmol/l (RI 7.65–16.8), confirming zinc toxicosis. Metal analysis of the screw nut by inductively coupled plasma mass spectrometry (ICPMS) (Table 1) showed it was mainly composed of zinc. High levels of aluminium, copper, iron and nickel and a very low level of lead and cadmium were detected.

Seven weeks later, the cat was clinically well with a normal appetite. Examination revealed a body weight of 3.2 kg (800 g gain) and a BCS of 5/9. Haematology was unremarkable (haematocrit 0.30 l/l). Biochemistry was unremarkable: ALT, ALP and total bilirubin were all within the RIs. APTT (95 s) and PT (18 s) were within the RIs. Abdominal ultrasound was unremarkable. Repeat serum zinc concentration was 42.4 µmol/l.

Discussion

Zinc toxicosis in cats is uncommon.¹ The true toxic dose for metallic zinc in cats has not been established.¹ Normal serum zinc concentrations range between 0.50 and 1.10 ppm (7.65–16.8 µmol/l) in cats.¹ Most cases of confirmed

zinc toxicity have serum zinc levels exceeding 5 ppm (76.5 µmol/l).¹ In the case reported here, the cat had a markedly increased serum zinc concentration of 448 µmol/l, accompanied by clinical signs of inappetence, vomiting and a regenerative anaemia. These findings were compatible with a diagnosis of zinc toxicosis. The serum zinc concentration had reduced to 42.4 µmol/l 7 weeks later with the resolution of clinical signs and anaemia after removal of the zinc-containing foreign object.

While the exact mechanism of zinc toxicosis is unknown,¹ following ingestion, erosion of zinc material caused by gastric acid leads to subsequent toxicosis.² The corrosive properties of zinc cause gastrointestinal signs, including vomiting, inappetence, lethargy and diarrhoea.¹ The cat in this case presented to the referring veterinarian for vomiting prior to referral. We suspect that the zinc-containing metal screw nut was ingested at that time, 12 days prior to removal, causing gastric irritation and acute vomiting.

Following gastrointestinal absorption in the duodenum, zinc is bound to albumin and macroglobulins and is transported to the liver via the portal circulation.³ Approximately 30–40% of zinc is extracted by the liver and is subsequently released into the circulation.¹ The liver, kidney, pancreas and spleen are the organs with the most rapid accumulation and turnover of zinc.¹ In dogs, zinc toxicosis, in addition to gastrointestinal signs and haemolytic anaemia, can also cause pancreatitis, hepatopathy and acute kidney injury.^{1,2,4–14} In dogs with zinc toxicosis, intravascular haemolysis with normocytic or macrocytic, hypochromic anaemia and Heinz bodies is the most consistent abnormality observed.^{1,2,11} While there are no reports of anaemia secondary to zinc toxicosis in cats in the current literature, ferrets have been described to develop anaemia secondarily to gastrointestinal bleeding in an experimental study.¹⁵ In the case reported here, a moderately regenerative anaemia was identified with hyperbilirubinaemia, suggesting haemolysis. Although Heinz bodies were not observed in this case, the finding of Heinz bodies is less specific in cats and can be seen in healthy cats, cats with diabetes mellitus, hyperthyroidism and lymphoma.¹⁶

The APTT was mildly prolonged and returned to within RIs after screw nut removal. Prolonged APTT has been described in dogs with zinc toxicosis.^{2,9,10} It has been speculated that zinc could cause inhibition of coagulation factors VIII, IX, XI and/or XII.^{2,17}

Increased ALT and ALP activity, and hyperbilirubinaemia are typical findings of zinc toxicosis in dogs.^{1,2} These findings were also observed in the cat described here. However, it is unknown if the increase in liver enzymes was directly related to a hepatopathy or pancreatopathy. The liver is the major organ of zinc metabolism and histological lesions with centrilobular or periportal to mid-zonal hepatic necrosis have been reported in dogs with zinc toxicosis.¹ Resolution of the

anaemia and liver enzyme elevations at follow-up suggested that these clinicopathological abnormalities could be related to zinc toxicosis and/or the resolution of pancreatitis.

The ultrasonographic finding of pancreatitis in this cat was interesting. Pancreatitis and pancreatic fibrosis have been described in dogs with zinc toxicosis.^{1,3,4,10,18–20} In humans with zinc toxicosis, a hypoxic mechanism has been suggested as the cause of pancreatitis.²¹ Although the exact mechanism of zinc-induced pancreatitis is unknown in dogs, zinc has been shown to concentrate in the pancreas and eliminate in pancreatic secretions of dogs.²² Various pancreatic lesions on histopathology have been described in dogs with zinc toxicosis, including inflammation, nodular changes, fibrosis and necrosis.^{1,3,10,18} Pancreatic fibrosis and nodular changes were also observed in experimental cats fed with zinc.^{23,24} We suspect that pancreatitis in the cat reported here was associated with zinc toxicosis; however, we acknowledge that definitive diagnosis of feline pancreatitis remains challenging without histopathology,²⁵ and the aetiology of pancreatitis in this case remains elusive.

There are several limitations to our study. Although other metal toxicosis cannot be excluded, the clinical signs in the cat were incompatible with neurological signs expected for aluminium toxicosis.²⁶ Hepatocellular injury caused by copper toxicosis is possible; however, zinc toxicosis is more likely with compatible clinical signs, and the majority of the screw nut was composed of zinc.²⁷ A Coombs test or saline agglutination test was not performed as part of the diagnostic investigation for haemolytic anaemia. The justification of marbofloxacin use was based on the rapid deterioration of the cat, initial suspicion of haemotropic mycoplasmosis and hepatopathy, this was stopped when haemotropic mycoplasma PCR results returned negative. Although the use of vitamin K1 is debatable with a mildly prolonged APTT, considering the risk of coagulopathy in hepatic disease, the severe anaemia and uncommon adverse effects with oral use, vitamin K1 was given. Gastric contents and gas during the initial abdominal ultrasound precluded the identification of the metal screw nut. In the case of unexplained regenerative anaemia and gastrointestinal signs, abdominal radiographs should be performed to look for metal toxicosis. However, abdominal radiographs were declined at that time.

Conclusions

This is the first detailed clinical report of a case of zinc toxicosis in a cat. Gastrointestinal signs, regenerative anaemia, increased liver enzyme activity, prolonged APTT, gastric wall thickening and pancreatitis were observed. The clinical signs and clinicopathological abnormalities resolved after the removal of a gastric foreign object (a zinc-containing metal screw nut) and supportive treatment.

Acknowledgements The authors would like to thank the cat's owner, the staff and students of the Valentine Charlton Cat Centre and the Mass Spectrometry Facility at the School of Chemistry, The University of Sydney, for provision of excellent technical assistance.


Conflict of interest The authors declared no potential conflicts of interest with respect to the research, authorship, and/or publication of this article.

Funding The authors received no financial support for the research, authorship, and/or publication of this article.

Ethical approval The work described in this manuscript involved the use of non-experimental (owned or unowned) animals. Established internationally recognised high standards ('best practice') of veterinary clinical care for the individual patient were always followed and/or this work involved the use of cadavers. Ethical approval from a committee was therefore not specifically required for publication in *JFMS Open Reports*. Although not required, where ethical approval was still obtained, it is stated in the manuscript.

Informed consent Informed consent (verbal or written) was obtained from the owner or legal custodian of all animal(s) described in this work (experimental or non-experimental animals, including cadavers) for all procedure(s) undertaken (prospective or retrospective studies). For any animals or people individually identifiable within this publication, informed consent (verbal or written) for their use in the publication was obtained from the people involved.

ORCID iD Jane Yu  <https://orcid.org/0000-0002-4661-8311>

Nicholas Proschogo  <https://orcid.org/0000-0001-8729-9874>

References

- Talcott P. **Zinc**. In: Peterson ME and Talcott PA (eds). *Small animal toxicology*. 3rd ed. St Louis, MO: Elsevier Saunders, 2013, pp 847–851.
- Gurnee CM and Drobotz KJ. **Zinc intoxication in dogs: 19 cases (1991–2003)**. *J Am Vet Med Assoc* 2007; 230: 1174–1179.
- Blundell R and Adam F. **Haemolytic anaemia and acute pancreatitis associated with zinc toxicosis in a dog**. *Vet Rec* 2013; 172: 17. DOI: 10.1136/vr.100376.
- Foote K, Gilroy C, Burton S, et al. **Zinc toxicosis-associated hemolytic anemia and pancreatic disease in 2 dogs**. *Can Vet J* 2020; 61: 147–152.
- Hammond GM, Loewen ME and Blakley BR. **Diagnosis and treatment of zinc poisoning in a dog**. *Vet Hum Toxicol* 2004; 46: 272–275.
- Volmer PA, Roberts J and Meerdink GL. **Anuric renal failure associated with zinc toxicosis in a dog**. *Vet Hum Toxicol* 2004; 46: 276–278.
- Meurs KM, Breitschwerdt EB, Baty CJ, et al. **Postsurgical mortality secondary to zinc toxicity in dogs**. *Vet Hum Toxicol* 1991; 33: 579–583.
- Latimer KS, Jain AV, Inglesby HB, et al. **Zinc-induced hemolytic anemia caused by ingestion of pennies by a pup**. *J Am Vet Med Assoc* 1989; 195: 77–80.
- Siow JW. **Zinc toxicosis in a dog secondary to prolonged zinc oxide ingestion**. *Open Vet J* 2018; 8. DOI: 10.4314/ovj.v8i4.17.
- Bischoff K, Chiapella A, Weisman J, et al. **Zinc toxicosis in a boxer dog secondary to ingestion of holiday garland**. *J Med Toxicol* 2017; 13: 263–266.
- Bexfield N, Archer J and Herrtage M. **Heinz body haemolytic anaemia in a dog secondary to ingestion of a zinc toy: a case report**. *Vet J* 2007; 174: 414–417.
- Torrance AG and Fulton RB Jr. **Zinc-induced hemolytic anemia in a dog**. *J Am Vet Med Assoc* 1987; 191: 443–444.
- Clancey NP and Murphy MC. **Zinc-induced hemolytic anemia in a dog caused by ingestion of a game-playing die**. *Can Vet J* 2012; 53: 383–386.
- Gandini G, Bettini G, Pietra M, et al. **Clinical and pathological findings of acute zinc intoxication in a puppy**. *J Small Anim Pract* 2002; 43: 539–542.
- Straube EF, Schuster NH and Sinclair AJ. **Zinc toxicity in the ferret**. *J Comp Pathol* 1980; 90: 355–361.
- Christopher MM. **Relation of endogenous Heinz bodies to disease and anemia in cats: 120 cases (1978–1987)**. *J Am Vet Med Assoc* 1989; 194: 1089–1095.
- Breitschwerdt EB, Armstrong PJ, Robinette CL, et al. **Three cases of acute zinc toxicosis in dogs**. *Vet Hum Toxicol* 1986; 28: 109–117.
- Shaw DP, Collins JE and Murphy MJ. **Pancreatic fibrosis associated with zinc toxicosis in a dog**. *J Vet Diagn Invest* 1991; 3: 80–81.
- Mikszewski JS, Saunders HM and Hess RS. **Zinc-associated acute pancreatitis in a dog**. *J Small Anim Pract* 2003; 44: 177–180.
- Abdel-Mageed AB and Oehme FW. **A review on biochemical roles, toxicity and interactions of zinc, copper and iron: IV. Interactions**. *Vet Hum Toxicol* 1990; 32: 456–458.
- Sarma PS and Narula J. **Acute pancreatitis due to zinc phosphide ingestion**. *Postgrad Med J* 1996; 72: 237–238.
- Montgomery ML, Sheline GE and Chaikoff IL. **The elimination of administered zinc in pancreatic juice, duodenal juice and bile of the dog as measured by its radioactive isotope (Zn)**. *J Exp Med* 1943; 78: 151–159.
- Drinker KR, Thompson PK and Marsh M. **An investigation of the effect of long-continued ingestion of zinc, in the form of zinc oxide, by cats and dogs, together with observations upon the excretion and the storage of zinc**. *Am J Physiol* 1927; 80: 31–64.
- Scott DA and Fisher AM. **Studies on the pancreas and liver of normal zinc-fed cats**. *Am J Physiol* 1937; 121: 253–260.
- Forman MA, Steiner JM, Armstrong PJ, et al. **ACVIM consensus statement on pancreatitis in cats**. *J Vet Intern Med* 2021; 35: 703–723.
- Segev G, Bandt C, Francey T, et al. **Aluminium toxicity following administration of aluminium-based phosphate binders in 2 dogs with renal failure**. *J Vet Intern Med* 2008; 22: 1432–1435.
- Talcott P. **Copper**. In: Peterson ME and Talcott PA (eds). *Small animal toxicology*. 3rd ed. St Louis, MO: Elsevier Saunders, 2013, pp 517–521.