



Multifocal cutaneous phaeohyphomycosis caused by *Exophiala spinifera* with clinical resolution in an immunocompromised cat

Authors: Kondratjeva, Jevgenija, Pressanti, Charline, Reynolds, Brice S, Trumel, Catherine, Delverdier, Maxence, et al.

Source: Journal of Feline Medicine and Surgery Open Reports, 9(1)

Published By: SAGE Publishing

URL: <https://doi.org/10.1177/20551169231164610>

BioOne Complete (complete.BioOne.org) is a full-text database of 200 subscribed and open-access titles in the biological, ecological, and environmental sciences published by nonprofit societies, associations, museums, institutions, and presses.

Your use of this PDF, the BioOne Complete website, and all posted and associated content indicates your acceptance of BioOne's Terms of Use, available at www.bioone.org/terms-of-use.

Usage of BioOne Complete content is strictly limited to personal, educational, and non - commercial use. Commercial inquiries or rights and permissions requests should be directed to the individual publisher as copyright holder.

BioOne sees sustainable scholarly publishing as an inherently collaborative enterprise connecting authors, nonprofit publishers, academic institutions, research libraries, and research funders in the common goal of maximizing access to critical research.



Multifocal cutaneous phaeohyphomycosis caused by *Exophiala spinifera* with clinical resolution in an immunocompromised cat

Journal of Feline Medicine and Surgery Open Reports
1–6

© The Author(s) 2023

Article reuse guidelines:

sagepub.com/journals-permissions

DOI: 10.1177/20551169231164610

journals.sagepub.com/home/jfmsopenreports

This paper was handled and processed by the European Editorial Office (ISFM) for publication in *JFMS Open Reports*



Jevgenija Kondratjeva¹, Charline Pressanti¹,
Brice S Reynolds², Catherine Trumel^{1,3},
Maxence Delverdier^{4,5}, Anne-Cécile Normand⁶,
Nicolas Soetart⁷, Jacques Guillot^{8,9}
and Marie Christine Cadiergues^{1,10}

Abstract

Case summary A 3-year-old neutered domestic shorthair cat with a long history of idiopathic immune-mediated haemolytic anaemia and thrombocytopenia treated with ciclosporin and prednisolone was referred 2 months after the appearance of nodular dermatitis. A single pigmented nodule was present in the lateral carpal region of the right foreleg. The lesion was 7 mm in diameter, non-exudative and cutaneous to subcutaneous. Fine-needle aspiration of the mass revealed the presence of pigmented fungal elements. Excisional surgery was planned; in the meantime, a plaque-like lesion developed in the interorbital region. Histopathological examination confirmed the presumptive diagnosis of phaeohyphomycosis, and *Exophiala spinifera* was identified as the aetiological agent. Itraconazole, given orally at a dose of 10 mg/kg for 8 weeks following surgery, enabled clinical resolution despite continued use of immunosuppressants. The follow-up was carried out over 14 weeks.

Relevance and novel information This case report provides the first evidence of multifocal cutaneous phaeohyphomycosis caused by *E spinifera* with clinical resolution after combined surgical and itraconazole treatment in an immunocompromised cat.

Keywords: Skin; nodule; fungus; *Exophiala spinifera*; phaeohyphomycosis

Accepted: 2 March 2023

¹Department of Clinical Sciences, University of Toulouse, ENVT, Toulouse, France

²InTheRes, University of Toulouse, INRAE, ENVT, Toulouse, France

³CREFRE (The Regional Centre for Functional and Experimental Exploration Resources), University of Toulouse, Inserm, UPS, Toulouse, France

⁴Department of Basic Sciences, University of Toulouse, ENVT, Toulouse, France

⁵IHAP (Interactions Hôtes-Agents Pathogènes), University of Toulouse, ENVT, INRAE, Toulouse, France

⁶AP-HP (Assistance Publique-Hôpitaux de Paris), Department of Parasitology and Mycology, Hôpital La Pitié-Salpêtrière, Paris, France

⁷Laboniris, Oniris, Nantes, France

⁸Department of Dermatology, Parasitology and Mycology, Oniris, Nantes, France

⁹University of Angers, University of Brest, IRF, SFR ICAT, Angers, France

¹⁰INFINITY (Toulouse Institute for Infectious and Inflammatory Diseases), University of Toulouse, Inserm, CNRS, UPS, Toulouse, France

Corresponding author:

Marie Christine Cadiergues DrMedVet, PhD, EBVS Specialist in Veterinary Dermatology, Department of Clinical Sciences, University of Toulouse, ENVT, 23, Chemin des Capelles, Toulouse 31076, France

Email: marie-christine.cadiergues@envt.fr



Creative Commons Non Commercial CC BY-NC: This article is distributed under the terms of the Creative Commons

Attribution-NonCommercial 4.0 License (<https://creativecommons.org/licenses/by-nc/4.0/>) which permits non-commercial use, reproduction and distribution of the work without further permission provided the original work is attributed as specified on the SAGE and Open Access pages (<https://us.sagepub.com/en-us/nam/open-access-at-sage>).

Introduction

Deep mycoses comprise cutaneous and subcutaneous infections, sometimes as manifestations of a systemic disease caused by a diverse group of fungi and pseudofungi.¹ Three major aetiological categories of subcutaneous mycoses are recognised: phaeohyphomycosis, hyalohyphomycosis and eumycotic mycetoma.^{2–4} Phaeohyphomycosis is caused by dematiaceous fungi that produce melanin-pigmented hyphae and yeast-like forms in tissues and in culture.^{2,5} Clinically, phaeohyphomycosis often presents as pigmented, ulcerated, crusting or fistulising nodules, non-ulcerated nodules and/or plaques, which can be focal or multifocal and locally invasive. In cats, the areas typically affected are face, distal limbs and tail.^{2,5}

Dematiaceous fungi are rarely pathogenic in immunocompetent hosts, but have recently emerged as important causes of comorbidity in immunocompromised dogs and cats. The apparent increase in their prevalence is possibly due to improved veterinary diagnostic techniques.^{2,6} Their precise diagnosis, treatment options and data dissemination are important in both human and veterinary medicine.

The development of molecular identification of fungi has facilitated accurate species identification. To date, the genera *Exophiala*, *Fonsecaea*, *Macrophomina*, *Microspheeropsis*, *Moniliella*, *Phialophora*, *Phoma*, *Scolecobasidium* and *Stemphylium* have been reported to cause diseases in cats.^{2,3,5} *Exophiala* species are one of the most frequently recognised agents in human and feline phaeohyphomycoses.^{7–9} *Exophiala spinifera* is one of the most aggressive species of the genus.¹⁰ It is associated with severe infections and has an 80% mortality rate in systemic human cases.¹¹ Virulence has been attributed to extracellular polysaccharides produced by yeast-like elements that prevent phagocytes from acting upon tissue invasion.^{10,12,13} To date, four feline cases caused by *E spinifera* have been reported in the literature, three in Australia^{7,14} and one in France,¹⁵ all four with a poor outcome.

Herein, we report a positive outcome of multifocal cutaneous phaeohyphomycosis caused by *E spinifera* in an immunocompromised cat following combined surgical and medical treatment.

Case description

A 3-year-old neutered domestic shorthair cat was referred for a nodular dermatitis that had appeared 2 months previously. The cat lived in southwest France but had spent several months in the Central African Republic when it was 1 year old. The cat had access to the outdoors, and its owner reported regular fights with other cats. About 18 months previously, the cat had been diagnosed with idiopathic immune-mediated haemolytic anaemia and thrombocytopenia (IMHA/IMT) but had been relatively stable for the past 10 months on oral ciclosporin (Atopica chat 100 mg/ml; Elanco) at a dosage

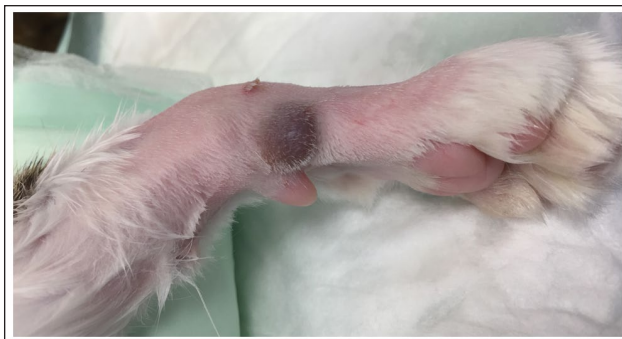

Figure 1 Right forelimb with a nodular lesion, 7 mm in diameter, cutaneous to subcutaneous, pigmented, soft, haired, non-painful and non-productive

of 7.4 mg/kg q24h and oral prednisolone (Prednicortone 20 mg; Dechra) at a dosage of 2.5 mg/kg q48h. The cat had recently developed one nodule on the lateral carpal of the right foreleg. The lesion was 7 mm in diameter, cutaneous to subcutaneous, pigmented, soft, haired, non-painful and non-productive (Figure 1). This lesion was reported to have grown slowly, without disturbing the cat. No other dermatological or clinical abnormalities were observed.

The history (immunocompromised cat with access to the outdoors) and clinical features were most consistent with the hypotheses of a cutaneous/subcutaneous infection (pseudomycetoma, leprosy syndrome, other opportunistic mycobacteria, phaeohyphomycosis, hyalohyphomycosis, eumycotic mycetoma, cryptococcosis, sporotrichosis, poxvirus infection, leishmaniasis), neoplasms (melanoma, haemangioma, feline progressive histiocytosis, mastocytoma) and, less likely, sterile granuloma.

Fine-needle aspirates were taken from the nodule, and smears were May–Grünwald–Giemsa stained. Cytological examination revealed damaged inflammatory cells suggestive of neutrophils and the presence of multiple pigmented fungal elements, leading to a diagnosis of phaeohyphomycosis without precise identification of the fungal species involved (Figure 2).

Surgical excision was proposed as part of the therapeutic regimen, and also to provide material for histological examination and mycological culture, and was accepted by the owner. On the day of the surgery, 1 month after the initial presentation, the nodule was slightly larger (approximately 1 cm in diameter), and a pigmented plaque-like lesion had appeared between the eyes (Figure 3). Complete excision of the limb nodule and a 4 mm punch biopsy of the plaque were performed under general anaesthesia. Oral itraconazole (Itrafungol; Virbac) at a dosage of 10 mg/kg q24h was started on the same day.

Microscopic appearance was similar for both lesions and was characterised by diffuse, superficial and deep dermal (Figure 4a,b) histiocytic, lymphocytic and, to

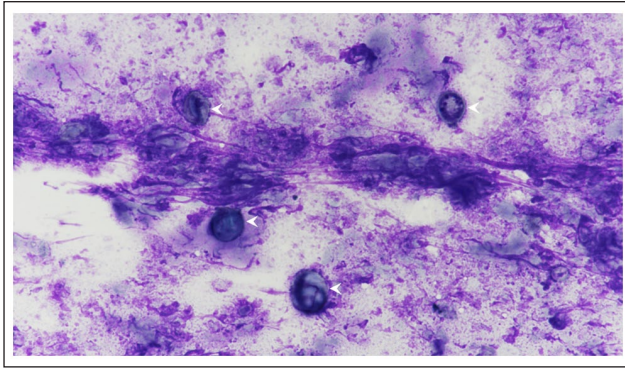


Figure 2 Fine-needle aspirate of the nodule. Damaged inflammatory cells suggestive of neutrophils and multiple pigmented fungal elements (arrows point to May-Grünwald-Giemsa staining, magnification $\times 1000$)




Figure 3 Plaque-like lesion located in the interorbital region

a lesser extent, neutrophilic infiltrate, with numerous spherical elements, measuring 3–20 μm in diameter, often isolated or with narrow-based buds, surrounded by a basophilic capsule (Figure 4c). Periodic acid–Schiff staining revealed that the elements were positive (Figure 4d). The margins of the nodule appeared to be free of fungal elements.

The fungus was cultured on Sabouraud dextrose agar plates complemented with 0.5g/l chloramphenicol for 11 days at 27°C and 37°C and yielded colonies of a black yeast-like fungus (Figure 5). The fungus was identified through macroscopic and microscopic observations, confirmed by mass spectrometry (matrix-assisted laser desorption/ionisation–time of flight mass spectrometry)

and molecular biology. Mass spectra were acquired after complete protein extraction using a Microflex LT/HS (Bruker Daltonik) and matched against the online application MSI-2 (<https://msi.happy-dev.fr>). The species *E spinifera* was identified by mass spectrometry. Confirmation was obtained using Sanger DNA sequencing of internal transcribed spacer regions. The DNA sequence was compared with sequences in the NCBI GenBank database using the Basic Local Alignment Search Tool. The best match (99.8% identity) was with *E spinifera*, strain CNRMA6.306 (GenBank accession number KP132129.1). The sequences have been deposited in Genbank (accession number OQ466703).

To investigate the antifungal susceptibility of the isolate, minimal inhibitory concentrations (MICs) were identified using the concentration gradient band (E-test; Biomérieux). The tests showed sensitivity to voriconazole, posaconazole, itraconazole and amphotericin B (MIC 0.023 $\mu\text{g}/\text{ml}$, 0.008 $\mu\text{g}/\text{ml}$, 0.006 $\mu\text{g}/\text{ml}$ and 0.19 $\mu\text{g}/\text{ml}$, respectively) and resistance to fluconazole (MIC 24 $\mu\text{g}/\text{ml}$). Based on these results, itraconazole was maintained.

At the 8-week follow-up evaluation, the excisional wound had completely healed and no relapse was visible. Clinical resolution of the non-excised facial lesion was observed. Itraconazole was continued for six more weeks and stopped. Immunosuppressive therapy (cyclosporin and prednisolone) was continued to prevent relapse of IMHA/IMT.

Discussion

Immunocompromised individuals are much more prone to developing phaeohyphomycosis than immunocompetent individuals. In humans, cases are frequently associated with glucocorticoid therapy,¹⁶ whereas in companion animals, one of the predisposing factors is medium–long-term cyclosporin therapy, particularly if combined with other immunosuppressants.^{2,5,6} This may be related to the main target of cyclosporin, T-helper cells, thus depriving the host of critical defence against fungal infection.² In the present case, the cat was under immunomodulatory therapy aimed at controlling immune-mediated haemolytic anaemia and thrombocytopenia, with no underlying cause identified, despite extensive work-up. The haematological abnormalities were difficult to control and only partial improvement was obtained by combining cyclosporin and prednisolone, both at a relatively high dosage/frequency over a long period of time. The lifestyle of the cat (access to outdoors, fights with other cats) was also a predisposing factor, increasing the risk of inoculation through traumatic wounds.

The clinical presentation of cutaneous phaeohyphomycosis comprised focal or multifocal pigmented, ulcerated or non-ulcerated nodules and/or plaques, located on the face, the distal limbs and the tail.^{2,5} When first presented, a single typical focal nodular lesion was detected;

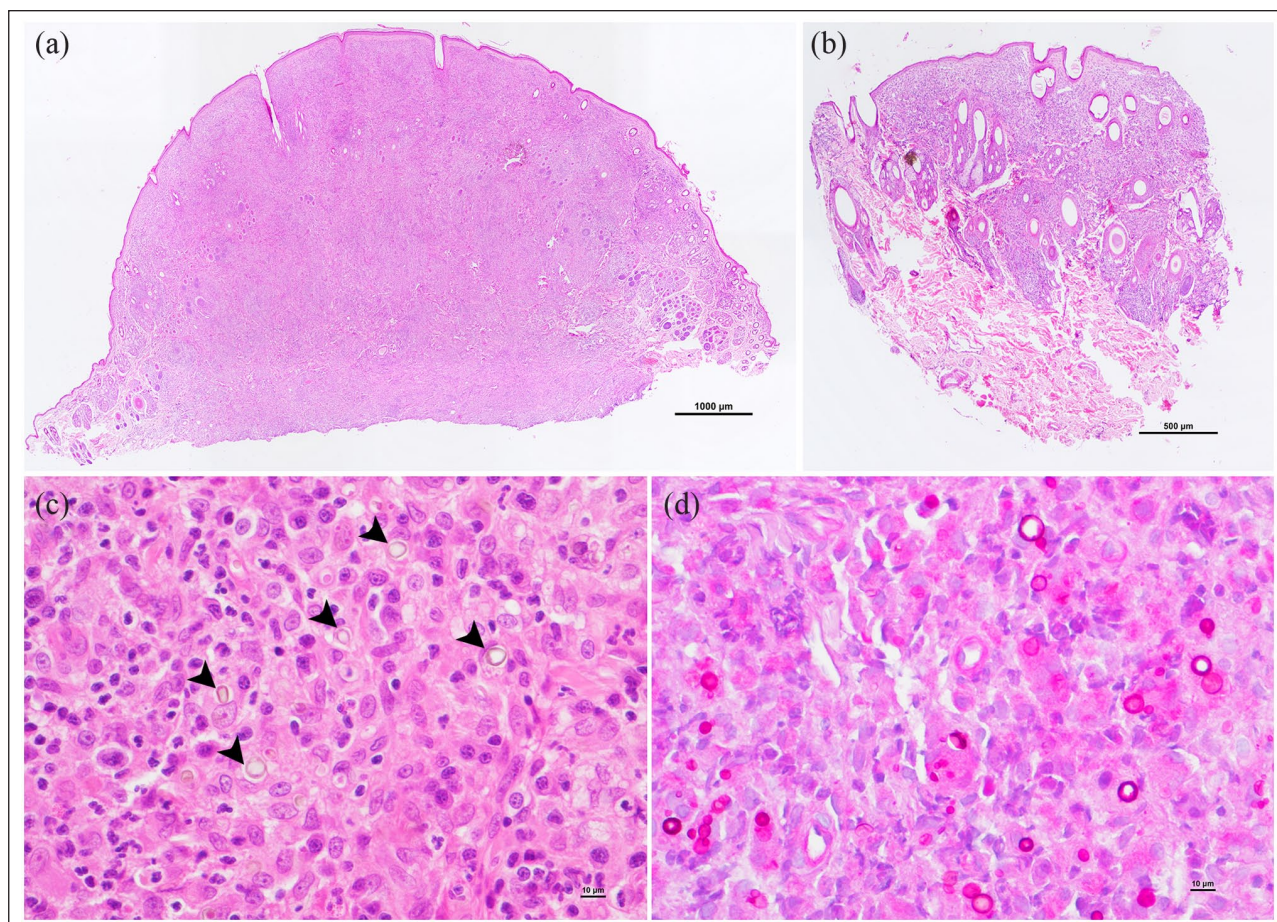


Figure 4 Histopathological examination of the nodule removed from (a) the right forelimb and (b) the biopsy of the plaque-like interorbital lesion, showing a nodular-to-diffuse superficial and deep dermal dermatitis (haematoxylin and eosin staining, magnification $\times 40$, bars = 1000 μm [a] and 500 μm [b]). (c) The infiltrate was histiocytic, lymphocytic and, to a lesser extent, neutrophilic, with numerous spherical elements, 3–20 μm in diameter, often isolated or with narrow-based buds, pigmented, surrounded by a basophilic capsule (black arrows, haematoxylin and eosin staining, magnification $\times 400$, bar = 10 μm). (d) Periodic acid–Schiff staining showed that the elements were positive (magnification $\times 400$, bar = 10 μm)

a second, plaque-like lesion (also pigmented) developed during the following weeks. It is difficult to judge whether the second lesion spread from the initial lesion or was due to contamination from the same environmental source. Multifocal and systemic spreading of the disease has been regularly reported, particularly in untreated hosts, both humans and animals.^{2,5,7,8,17,18} Some of these cases were associated with genetic mutations that affect antifungal defence mechanisms (autosomal recessive CARD9 deficiency).¹⁹

Cytological examination of fine-needle aspirates is an important diagnostic step in subcutaneous fungal infection and is easy to perform. In the present case, it allowed for rapid diagnosis of phaeohyphomycosis and, subsequently, a straightforward therapeutic decision. Indeed, fungal culture and subsequent appropriate techniques are indispensable to identify the exact species and assess its antifungal susceptibility.^{1,2,5}

In cats, current treatment recommendations for *Exophiala* infection are based on a very small number of

cases and derive from recommendations in humans.^{5,11} Whenever possible, surgical excision with wide margins should be performed; in the case of multiple lesions or disseminated infection, itraconazole should be prescribed pending results of the susceptibility test.^{5,7} Based on multiple reports of antifungal resistance in humans, antifungal susceptibility profiling is recommended.^{9,13} All previous reported feline cases had poor outcomes: one was lost after initial improvement on ketoconazole;¹⁴ one relapsed after withdrawal of ketoconazole and 5-fluorocytosine;¹⁴ in the third case, surgery followed by oral administration of ketoconazole and fluconazole was unsuccessful;¹⁵ in the last case, the cat did not tolerate itraconazole combined with terbinafine, posaconazole was refused and the cat was eventually euthanased.⁷ In the present case, improvement was very rapid. Clearly, there is a risk of recurrence, as well as of other opportunistic infections as the cat continues to spend time outdoors and because the immunomodulators cannot be stopped. Indeed, better results would be expected if the immunosuppressive treatment

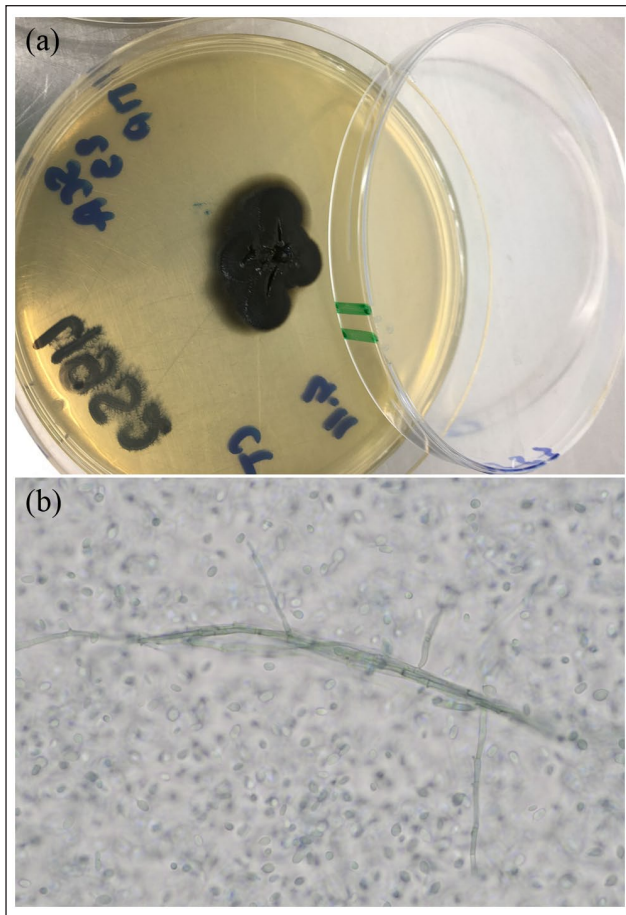


Figure 5 (a) Appearance of the fungal colonies after incubation on Sabouraud dextrose agar for 11 days at 37°C. The colonies were black, slimy at the centre due to yeast-like growth and smooth near the margin. (b) Microscope images ($\times 400$ magnification) of the fungus. Brownish septate hyphae and numerous conidia (some with annellated zones, representing germinating cells) are visible

could be stopped or reduced.¹⁷ As the underlying disease had been difficult to control, even with a combination of immunosuppressant drugs, alleviating the doses was not envisaged. In humans, like in dogs, interactions between ciclosporin and itraconazole, resulting from inhibition of cytochrome P450 (CYP3A), allow the dose of ciclosporin to be reduced when the two molecules are combined.^{6,20–22} Such interaction is not reported in cats; nevertheless, in a previous study, ketoconazole increased the concentration of ciclosporin in the blood about two-fold after ciclosporin was administered,²³ suggesting that the same applies to itraconazole.²²

Conclusions

This case report provides the first evidence of multifocal cutaneous phaeohiphomycosis caused by *E spinifera* with clinical resolution after combining surgical and itraconazole treatments in an immunocompromised cat.

Acknowledgements We are grateful to Floriane Hubert and Cécile Roux (Laboniris, Nantes, France) for their valuable technical help.

Conflict of interest The authors declared no potential conflicts of interest with respect to the research, authorship, and/or publication of this article.

Funding The authors received no financial support for the research, authorship, and/or publication of this article.

Ethical approval The work described in this manuscript involved the use of non-experimental (owned or unowned) animals. Established internationally recognised high standards ('best practice') of veterinary clinical care for the individual patient were always followed and/or this work involved the use of cadavers. Ethical approval from a committee was therefore not specifically required for publication in *JFMS Open Reports*. Although not required, where ethical approval was still obtained, it is stated in the manuscript.

Informed consent Informed consent (verbal or written) was obtained from the owner or legal custodian of all animal(s) described in this work (experimental or non-experimental animals, including cadavers) for all procedure(s) undertaken (prospective or retrospective studies). For any animals or people individually identifiable within this publication, informed consent (verbal or written) for their use in the publication was obtained from the people involved.

ORCID iD Marie Christine Cadiergues  <https://orcid.org/0000-0001-6909-0153>

References

- Dehghanpir SD. **Cytomorphology of deep mycoses in dogs and cats.** *Vet Clin North Am Small Anim Pract* 2023; 53: 155–173.
- Dedeaux A, Grooters A, Wakamatsu-Utsuki N, et al. **Opportunistic fungal infections in small animals.** *J Am Anim Hosp Assoc* 2018; 54: 327–337.
- Miller RI. **Nodular granulomatous fungal skin diseases of cats in the United Kingdom: a retrospective review.** *Vet Dermatol* 2010; 21: 130–135.
- Walsh TJ and Dixon DM. **Spectrum of mycoses.** In: Baron S (ed). *Medical microbiology*. 4th ed. Galveston, TX: University of Texas Medical Branch, 1996, 919–925.
- Lloret A, Hartmann K, Pennisi MG, et al. **Rare opportunistic mycoses in cats: phaeohiphomycosis and hyalohiphomycosis: ABCD guidelines on prevention and management.** *J Feline Med Surg* 2013; 15: 628–630.
- Archer TM, Boothe DM, Langston VC, et al. **Oral cyclosporine treatment in dogs: a review of the literature.** *J Vet Intern Med* 2014; 28: 1–20. DOI: 10.1111/jvim.12265.
- Daly JA, Hubka V, Kubatova A, et al. **Feline disseminated cutaneous phaeohiphomycosis due to *Exophiala spinifera*.** *Med Mycol Case Rep* 2020; 27: 32–35.
- Harris JE, Sutton DA, Rubin A, et al. ***Exophiala spinifera* as a cause of cutaneous phaeohiphomycosis: case study and review of the literature.** *Med Mycol* 2009; 47: 87–93.

- 9 Liu H, Zhang J, Chen Y, et al. **Phaeohyphomycosis due to *Exophiala spinifera* greatly improved by ALA-PDT: a case report.** *Photodiagnosis Photodyn Ther* 2019; 28: 297–299.
- 10 Song Y, da Silva NM, Weiss VA, et al. **Comparative genomic analysis of capsule-producing black yeasts *Exophiala dermatitidis* and *Exophiala spinifera*, potential agents of disseminated mycoses.** *Front Microbiol* 2020; 11: 586.
- 11 Bohelay G, Robert S, Bouges-Michel C, et al. **Subcutaneous phaeohyphomycosis caused by *Exophiala spinifera* in a European patient with lymphoma: a rare occurrence case report and literature review.** *Mycoses* 2016; 59: 691–696.
- 12 Song Y, Laureijssen-van de Sande WWJ, Moreno LF, et al. **Comparative ecology of capsular *Exophiala* species causing disseminated infection in humans.** *Front Microbiol* 2017; 8: 2514.
- 13 Vitale RG and de Hoog GS. **Molecular diversity, new species and antifungal susceptibilities in the *Exophiala spinifera* clade.** *Med Mycol* 2002; 40: 545–556.
- 14 Kettlewell P, McGinnis MR and Wilkinson GT. **Phaeohyphomycosis caused by *Exophiala spinifera* in two cats.** *J Med Vet Mycol* 1989; 27: 257–264.
- 15 Chermette R, Ferreiro L, Bièvre Cd, et al. ***Exophiala spinifera* nasal infection in a cat and a literature review of feline phaeohyphomycoses.** *J Mycol Med* 1997; 7: 149–158.
- 16 Revankar SG, Baddley JW, Chen SC, et al. **A mycoses study group international prospective study of phaeohyphomycosis: an analysis of 99 proven/probable cases.** *Open Forum Infect Dis* 2017; 4. DOI: 10.1093/ofid/ofx200.
- 17 Borrás P, Messina F, Abrantes R, et al. **First report of phaeohyphomycosis caused by *Phialophora americana* in a domestic cat from Argentina.** *JFMS Open Rep* 2022; 8. DOI: 10.1177/20551169221077611.
- 18 Wang L, Wang C, Shen Y, et al. **Phaeohyphomycosis caused by *Exophiala spinifera*: an increasing disease in young females in mainland China? Two case reports and review of five cases reported from mainland China.** *Mycoses* 2015; 58: 193–196.
- 19 Lanternier F, Barbati E, Meinzer U, et al. **Inherited CARD9 deficiency in 2 unrelated patients with invasive *Exophiala* infection.** *J Infect Dis* 2015; 211: 1241–1250.
- 20 Florea NR, Capitano B, Nightingale CH, et al. **Beneficial pharmacokinetic interaction between cyclosporine and itraconazole in renal transplant recipients.** *Transplant Proc* 2003; 35: 2873–2877.
- 21 Matsuda Y, Nakagawa S, Yano I, et al. **Effect of itraconazole and its metabolite hydroxyitraconazole on the blood concentrations of cyclosporine and tacrolimus in lung transplant recipients.** *Biol Pharm Bull* 2022; 45: 397–402.
- 22 Sasaki K and Shimoda M. **Possible drug-drug interaction in dogs and cats resulted from alteration in drug metabolism: a mini review.** *J Adv Res* 2015; 6: 383–392.
- 23 McAnulty JF and Lensmeyer GL. **The effects of ketoconazole on the pharmacokinetics of cyclosporine A in cats.** *Vet Surg* 1999; 28: 448–455.