



## **Repeat histopathology and culture of colonic biopsy specimens after treatment for Escherichia coli-associated granulomatous colitis in a cat**

Authors: Waite, Oliver, Yaffy, Dylan, and Kathrani, Aarti

Source: Journal of Feline Medicine and Surgery Open Reports, 9(1)

Published By: SAGE Publishing

URL: <https://doi.org/10.1177/20551169231178442>

---

BioOne Complete ([complete.BioOne.org](https://complete.BioOne.org)) is a full-text database of 200 subscribed and open-access titles in the biological, ecological, and environmental sciences published by nonprofit societies, associations, museums, institutions, and presses.

Your use of this PDF, the BioOne Complete website, and all posted and associated content indicates your acceptance of BioOne's Terms of Use, available at [www.bioone.org/terms-of-use](https://www.bioone.org/terms-of-use).

Usage of BioOne Complete content is strictly limited to personal, educational, and non-commercial use. Commercial inquiries or rights and permissions requests should be directed to the individual publisher as copyright holder.

---

BioOne sees sustainable scholarly publishing as an inherently collaborative enterprise connecting authors, nonprofit publishers, academic institutions, research libraries, and research funders in the common goal of maximizing access to critical research.



# Repeat histopathology and culture of colonic biopsy specimens after treatment for *Escherichia coli*-associated granulomatous colitis in a cat

*Journal of Feline Medicine and Surgery Open Reports*  
1–6

© The Author(s) 2023

Article reuse guidelines:

sagepub.com/journals-permissions

DOI: 10.1177/20551169231178442

journals.sagepub.com/home/jfmsopenreports

This paper was handled and processed by the European Editorial Office (ISFM) for publication in *JFMS Open Reports*



Oliver Waite<sup>1</sup>, Dylan Yaffy<sup>2</sup> and Aarti Kathrani<sup>1</sup>

## Abstract

**Case summary** A 7.5-year-old neutered male Oriental Shorthair cat presented with an 8-month history of haematochezia, mucoid diarrhoea, tenesmus and vocalisation after a 4-year history of small bowel diarrhoea. Transabdominal ultrasonography confirmed diffuse colonic wall thickening and extensive ulceration and erythema after colonoscopy. Colonic histopathology confirmed periodic acid-Schiff positive macrophages, consistent with granulomatous colitis; *Escherichia coli* was cultured from colonic biopsy specimens. Fluorescent in situ hybridisation (FISH) identified intracellular *E coli*, and an 8-week oral course of marbofloxacin, a hydrolysed protein diet and a 5-day course of fenbendazole yielded a transient partial clinical remission of the colitis signs. A reported resolution in the small bowel signs was also reported. Colonoscopy was repeated 5 months later due to the recurrence of colitis signs. Histopathology was not consistent with granulomatous colitis supporting a complete remission; however, a chronic inflammatory enteropathy was confirmed with moderate lymphoplasmacytic, neutrophilic and eosinophilic colitis without a histiocytic component. *E coli* was again cultured from colonic biopsies with sensitivity to fluoroquinolones; FISH was positive for intracellular *E coli*. Clinical signs persisted despite a 2-week course of oral marbofloxacin.

**Relevance and novel information** *E coli*-associated granulomatous colitis is rare in cats. Colonic biopsy specimen culture is important to guide appropriate antibiotic therapy. Repeat histopathology, culture and FISH have not been previously reported after treatment of a cat with *E coli*-associated granulomatous colitis. Persistent clinical signs after treatment with oral marbofloxacin alongside a confirmed complete histologic remission support the presence of a concurrent chronic inflammatory enteropathy and pathology for the cat's ongoing colitis.

**Keywords:** Chronic enteropathy; *Escherichia coli*; granulomatous colitis; marbofloxacin; remission

**Accepted:** 10 May 2023

## Introduction

Granulomatous colitis (GC) is an inflammatory enteropathy common among Boxers and French bulldogs characterised by large-bowel diarrhoea, haematochezia and tenesmus.<sup>1–6</sup> The histological appearance of GC is well described, with severe mucosal ulceration and periodic acid–Schiff positive (PAS+) macrophages dispersed throughout the colonic lamina propria and submucosa.<sup>2,7–9</sup> Invasive and adherent *Escherichia coli* strains have been identified within PAS+ macrophages using

<sup>1</sup>Department of Clinical Science and Services, Royal Veterinary College, University of London, North Mymms, Hertfordshire, UK

<sup>2</sup>Department of Pathobiology and Population Sciences, Royal Veterinary College, University of London, North Mymms, Hertfordshire, UK

### Corresponding author:

Oliver Waite BVSc, MRCVS, Department of Clinical Science and Services, Royal Veterinary College, University of London, Hawkshead Lane, North Mymms, Hertfordshire AL9 7TA, UK  
Email: owaite21@rvc.ac.uk



Creative Commons Non Commercial CC BY-NC: This article is distributed under the terms of the Creative Commons

Attribution-NonCommercial 4.0 License (<https://creativecommons.org/licenses/by-nc/4.0/>) which permits non-commercial use, reproduction and distribution of the work without further permission provided the original work is attributed as specified on the SAGE and Open Access pages (<https://us.sagepub.com/en-us/nam/open-access-at-sage>).

fluorescent in situ hybridisation (FISH). Clinical remission (CR) is dependent upon eradicating invasive intracellular *E coli*.<sup>2-4</sup>

GC is rare in cats.<sup>10-13</sup> Direct colonic tissue culture is often used to guide antibiotics in dogs, but this has never been reported in a case of feline GC. Similarly, repeat histopathology and FISH performed on colonic biopsy specimens after fluoroquinolone treatment have not been described in cats. Herein, we describe the first use of histopathology, culture and FISH on colonic biopsy specimens, performed as part of initial diagnostic investigations and 3 months after completing an 8-week course of oral marbofloxacin in a cat with confirmed GC. Repeat histopathology was inconsistent with GC, but colonic mixed inflammation supported a chronic inflammatory enteropathy (CIE).

### Case description

A 7.5-year-old, 4.7-kg, indoor, neutered male Oriental Shorthair cat was presented to the Queen Mother Hospital for Animals for the investigation of mixed bowel diarrhoea with a progressive 8-month history of haematochezia, mucoid diarrhoea, tenesmus and vocalisation. Defecation frequency had increased from twice to  $\geq 5$  times daily. Before the onset of colitis, the cat had a 4-year history of small-bowel diarrhoea, with large volumes of liquid faeces.

Prior treatments, including 4 weeks of anti-inflammatory oral glucocorticoids, a single subcutaneous injection of cefovecin, multiple 2-week courses of oral metronidazole and frequent 3-day courses of oral fenbendazole prescribed predominately for the chronic small-bowel diarrhoea, had not improved the clinical signs. Therapeutic limited-ingredient novel protein and hydrolysed protein diets were not trialled and the cat received a commercial over-the-counter complete diet.

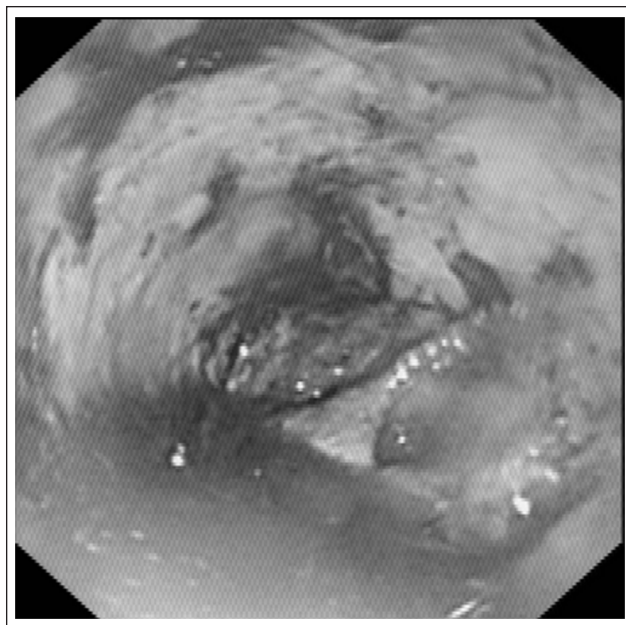
The cat had a WSAVA body condition score of 5/9 with normal musculing. The remainder of the physical examination was unremarkable, and the cat was hospitalised for further investigations.

Haematology and serum biochemistry revealed a mild mature neutrophilia ( $13.04 \times 10^9/l$  [reference interval (RI)  $2.5-12.5 \times 10^9$ ]) and hypercholesterolemia ( $4.39 \text{ mmol/l}$  [RI  $2.2-4$ ]). Serum cobalamin concentrations without prior supplementation were supranormal ( $>1200 \text{ ng/l}$  [RI  $>200$ ]) and T4 concentration was not supportive of hyperthyroidism ( $31.5 \text{ nmol/l}$  [RI  $19-65$ ]). Feline immunodeficiency virus antibody and feline leukaemia virus antigen testing were negative. A McMaster faecal egg count did not detect endoparasites or coccidial oocysts; neither *Giardia* species nor *Cryptosporidium* species were identified. A faecal sample submitted for *Tritrichomonas foetus* polymerase chain reaction (PCR) before referral had returned negative.

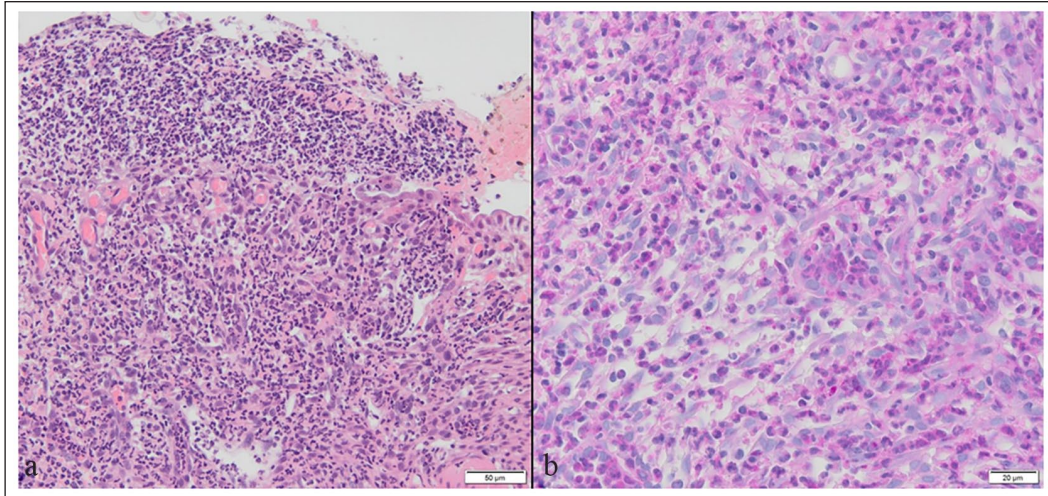
Transabdominal ultrasound identified a diffuse 4.5-mm thickening of the colonic wall and a severe, focal narrowing at the distal aspect of the descending colon. There was no abdominal lymphadenopathy, and the remainder of the gastrointestinal tract was unremarkable.

Gastroduodenal and ileocolic endoscopy (Olympus GIF-XP260N) was performed under general anaesthesia. The stomach, duodenum and ileum were grossly unremarkable. The colon was short in length (20 cm), friable and oedematous with severe, diffuse ulceration and haemorrhage (Figure 1). The focal narrowing identified during transabdominal ultrasonography was not visualised. Gastric, duodenal and ileal biopsies were histologically unremarkable. Ten colonic biopsy specimens were collected using 2.2-mm oval fenestrated biopsy forceps. Nine specimens were placed free-floating in 10% formalin, and embedded in paraffin blocks for histopathology. One colonic biopsy specimen collected in a sterile sample pot and moistened with sterile 0.9% saline was submitted for aerobic and anaerobic culture.

Histopathology was consistent with multifocal, severe pyogranulomatous and ulcerative colitis with numerous PAS+ macrophages and distortion of the lamina propria by florid granulation tissue (Figure 2). Culture recorded by matrix-assisted laser desorption/ionisation revealed a moderate growth of *E coli* that was sensitive to marbofloxacin (minimum inhibitory concentration [MIC]  $\leq 0.5$ ).



**Figure 1** Initial endoscopic visualisation of the colon using an Olympus GIF-XP260N endoscope demonstrated severe, multifocal ulceration to the colonic wall with a markedly erythematous and friable mucosa



**Figure 2** Photomicrographs of histologic sections of colonic endoscopic biopsies: (a) haematoxylin and eosin stain,  $\times 100$ , showing severe pyogranulomatous and ulcerative colitis with loss of the mucosal epithelium and complete distortion of the lamina propria architecture by granulation tissue, and (b) periodic acid-Schiff (PAS),  $\times 400$ , showing PAS + staining of the macrophage cytoplasm

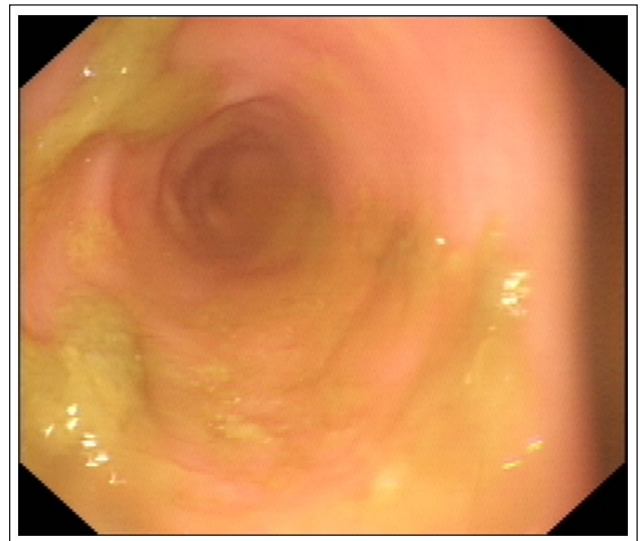
FISH was performed on formalin-fixed, paraffin-embedded colonic biopsy specimens using specific *Campylobacter*, *E coli* and eubacterial probes, revealing abundant, multiplying clusters of *E coli* and fewer clusters of *Campylobacter jejuni* and *Clostridial* species.

An 8-week course of oral marbofloxacin (4 mg/kg q24 h) was prescribed with five consecutive days of oral fenbendazole (50 mg/kg q24h). The cat was also transitioned onto a therapeutic hydrolysed protein diet (Pro Plan Veterinary Diets HA Hypoallergenic Dry Cat Food; Purina) over 5 days. A partial CR ( $\leq 40\%$  improvement as reported by the owner) was described 2 weeks into therapy, characterised by improved faecal consistency and reduced frequency of haematochezia and tenesmus. As multiple therapies were simultaneously implemented, it is not possible to definitively confirm which therapy was most effective.

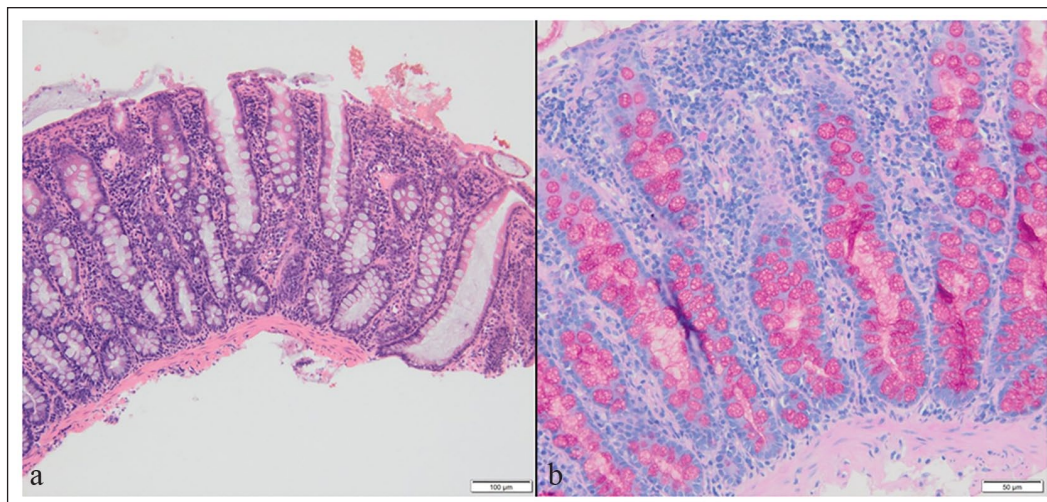
Five months later, the cat was re-referred with a complete clinical relapse typified by haematochezia and tenesmus, without any reported small-bowel diarrhoea. Strict adherence to the advised hydrolysed protein diet was confirmed; however, trials with alternative therapeutic diets were declined by the owner. The primary-care practice had prescribed 10 days of oral metronidazole (26.6 mg/kg q12h) followed by 8 days of oral sulfasalazine (13.3 mg/kg q12h), without improvement. Haematology and serum biochemistry remained unremarkable. Serum cobalamin and TT4 concentrations were 1050.0 ng/l (RI  $>200$ ) and 13.9 nmol/l (RI 19–65), respectively. Feline specific pancreatic lipase immunoreactivity and trypsin-like immunoreactivity concentrations were unremarkable at 1.5  $\mu\text{g/l}$  (RI 0.1–3.5) and 71.0  $\mu\text{g/l}$  (RI 12.1–82), respectively. A repeat faecal McMaster egg count did not detect endoparasites or coccidial oocysts. Sedation was performed to facilitate

colonic washing and the retrieval of faeces for *T foetus*-PCR testing, which returned negative. Transabdominal ultrasonography confirmed persistent and diffuse colonic-wall thickening (3.5 mm).

Repeat gastric and ileal endoscopic biopsies were histologically unremarkable. Duodenal histopathology was consistent with mild, mixed inflammation. Colonoscopy did not identify ulceration or haemorrhage (Figure 3). Ten colonic biopsy specimens were



**Figure 3** Endoscopic visualisation of the colon using an Olympus GIF-XP260N endoscope, 5 months after initial presentation and after an 8-week course of oral marbofloxacin. There was a marked improvement in the endoscopic appearance of the colonic wall. The previous ulceration and haemorrhage were not observed



**Figure 4** Photomicrographs of histologic sections of colonic endoscopic biopsies: (a) haematoxylin and eosin stain,  $\times 100$ , showing moderate, lymphoplasmacytic, neutrophilic and eosinophilic colitis with no histiocytic component and an intact mucosal epithelium, and (b) periodic acid–Schiff (PAS),  $\times 200$ , showing no PAS+ staining of the inflammatory infiltrate

obtained and processed in a manner identical to that described in the initial investigation above.

Histopathology was consistent with a CIE describing a moderate lymphoplasmacytic, neutrophilic and eosinophilic colitis without a histiocytic component (Figure 4). A profuse growth of marbofloxacin-sensitive *E coli* (MIC  $\leq 0.5$ ) was cultured from a colonic biopsy specimen, with a sensitivity pattern identical to that of the initial diagnosis. FISH was repeated in a manner identical to that of the initial investigation, with additional *Salmonella*-species-specific probes. Individual and localised clusters of *E coli*, *Salmonella* and *Clostridial* species were detected within the tissue. *Campylobacter* species were not detected. Oral marbofloxacin (4 mg/kg q24h) was prescribed, but discontinued after 2 weeks due to lack of clinical improvement.

An IDEXX feline microbiota dysbiosis index was performed on a single faecal sample, which was inconsistent with a shift in the overall intestinal microbiota (dysbiosis index  $-2.5 \log \text{DNA [RI]} < 0$ ). Therefore, additional empirical therapy, predominantly with diet, was initially prioritised over faecal microbiota transplant.

## Discussion

We describe a case of feline *E coli*-associated GC with a complete histologic remission after 8 weeks of oral marbofloxacin. Histopathology, culture and FISH of colonic biopsy specimens were performed before marbofloxacin therapy and repeated due to the cat's partial CR and subsequent clinical relapse. Post-treatment investigations have not been reported in cats with GC. Similarly, we report the first description of culture and sensitivity profiling from colonic biopsy specimens alongside the fifth reported case of GC in a cat.<sup>10–13</sup>

CR of GC relies upon eradicating intracellular *E coli* from within PAS+ macrophages in dogs and cats.<sup>2–4,10–13</sup> Antimicrobial resistance is a reported cause for relapsing canine GC with persistent clinical signs, histological changes and culture results.<sup>3,14</sup> In our case, *E coli* cultured after repeat colonic biopsies demonstrated the same susceptibility pattern without resistance, alongside a histological resolution of the GC. Colonic biopsy culture and FISH using selective *E coli* probes are performed in dogs with histologically confirmed GC to identify intracellular bacteria.<sup>1–3,15</sup> Direct colonic biopsy tissue culture has not been reported in a cat with GC, but is considered necessary to guide antimicrobial therapy given the growing fluoroquinolone resistance.<sup>15</sup> We submitted samples for FISH using selective *E coli*, *Campylobacter*, *Salmonella* and eubacterial probes due to the endoscopic appearance of the colon and the histologic presence of PAS+ macrophages. Intracellular clusters of *E coli* were confirmed alongside *Campylobacter* species, but the significance of this latter finding remains unclear. *E coli*-associated GC in dogs is treated with enrofloxacin. The case described was treated with oral marbofloxacin considering the retinotoxic consequences of enrofloxacin in cats and available sensitivity profiling.<sup>16,17</sup>

Colonoscopy was repeated due to a complete clinical relapse and perceived GC treatment failure. Histopathology was inconsistent with GC. However, lymphoplasmacytic, neutrophilic and eosinophilic colitis confirmed a CIE, supporting an alternative pathology for the clinical signs. Food-responsive enteropathy accounts for at least 60% of all cases of CIE.<sup>18</sup> However, the owners were initially reluctant to attempt alternative therapeutic diet trials for the CIE.

In cats, *T foetus* infection and intracellular *Campylobacter coli* confirmed with FISH are described as causes of neutrophilic enteritis.<sup>19,20</sup> Repeated FISH assessments using *Campylobacter*-specific probes and faecal PCR testing for *T foetus* were negative. Intracellular *E coli* remained a consistent finding on FISH, without clear significance; however, a study of canine CIE has described imbalances in the structure and composition of ileal and colonic mucosal microbiota.<sup>21</sup> Comparable feline studies are lacking.

Complete CR is described in dogs with GC as early as 2 weeks into enrofloxacin therapy, despite persistent PAS+ macrophages confirmed in dogs up to 6 months later alongside a complete CR.<sup>3,4</sup> Repeat colonic histopathology has not been described in a cat with GC after fluoroquinolone treatment.

Limited investigations were performed to exclude fungal disease and algae as a cause of GC due to the geographic location, chronicity, indoor-only housing and absent travel history for the cat. PAS staining did not identify any fungal organism and *Prototheca* species was not observed. A second case limitation is the lack of multiple therapeutic diet trials for the CIE, which was initially declined by the owner.

## Conclusions

Neither follow-up histopathology in a cat diagnosed and treated with *E coli*-associated GC nor colonic biopsy specimen culture have previously been described. GC should remain a differential diagnosis for chronic colitis in cats, as an increasing number of isolated case reports suggests the prevalence of the disease may be under-reported. Larger-scale studies are required to further assess the prevalence, breed predispositions, clinical characteristics, treatment response and outcome. A complete histologic remission after oral marbofloxacin therapy confirmed a successful GC treatment. A concurrent CIE likely explained the cat's persistent clinical signs.

**Conflict of interest** The authors declared no potential conflicts of interest with respect to the research, authorship, and/or publication of this article.

**Funding** The authors received no financial support for the research, authorship, and/or publication of this article.

**Ethical approval** The work described in this manuscript involved the use of non-experimental (owned or unowned) animals. Established internationally recognised high standards ('best practice') of veterinary clinical care for the individual patient were always followed and/or this work involved the use of cadavers. Ethical approval from a committee was therefore not specifically required for publication in *JFMS Open*

*Reports*. Although not required, where ethical approval was still obtained, it is stated in the manuscript.

**Informed consent** Informed consent (verbal or written) was obtained from the owner or legal custodian of all animal(s) described in this work (experimental or non-experimental animals, including cadavers) for all procedure(s) undertaken (prospective or retrospective studies). For any animals or people individually identifiable within this publication, informed consent (verbal or written) for their use in the publication was obtained from the people involved.

**ORCID iD** Oliver Waite  <https://orcid.org/0000-0002-4417-2547>

Dylan Yaffy  <https://orcid.org/0000-0002-4388-0672>

## References

- Craven M, Dogan B, Schukken A, et al. **Antimicrobial resistance impacts clinical outcome of granulomatous colitis in boxer dogs.** *J Vet Intern Med* 2010; 24: 819–824.
- Simpson KW, Dogan B, Rishniw M, et al. **Adherent and invasive *Escherichia coli* is associated with granulomatous colitis in boxer dogs.** *Infect Immun* 2006; 74: 4778–4792.
- Mansfield CS, Craven JM, Davies DR, et al. **Remission of histiocytic ulcerative colitis in Boxer dogs correlates with eradication of invasive intramucosal *Escherichia coli*.** *J Vet Intern Med* 2009; 23: 964–969.
- Manchester AC, Hill S, Sabatino B, et al. **Association between granulomatous colitis in French Bulldogs and invasive *Escherichia coli* and response to fluoroquinolone antimicrobials.** *J Vet Intern Med* 2013; 27: 56–61.
- Hostutler RA, Luria BJ, Johnson SE, et al. **Antibiotic-responsive histiocytic ulcerative colitis in 9 dogs.** *J Vet Intern Med* 2004; 18: 499–504.
- Conrado FO, Jones EA, Graham EA, et al. **Cytologic, histopathologic, and clinical features of granulomatous colitis in a French Bulldog.** *Vet Clin Pathol* 2020; 50: 76–82.
- German AJ, Hall EJ, Kelly DF, et al. **An immunohistochemical study of histiocytic ulcerative colitis in boxer dogs.** *J Comp Pathol* 2000; 122: 163–175.
- Craven M, Mansfield CS and Simpson KW. **Granulomatous colitis of boxer dogs.** *Vet Clin North Am Small Anim Pract* 2011; 41: 433–445.
- Van Kruiningen HJ, Montali RJ, Strandberg JD, et al. **A granulomatous colitis of dogs with histologic resemblance to Whipple's disease.** *Vet Pathol* 1965; 2: 521–544.
- Leal RO, Simpson K, Fine M, et al. **Granulomatous colitis: more than a canine disease? A case of *Escherichia coli*-associated granulomatous colitis in an adult cat.** *JFMS Open Rep* 2017; 3. DOI: 10.1177/2055116917731168.
- Van Kruiningen HJ and Dobbins WO. **Feline histiocytic colitis.** *Vet Pathol* 1979; 16: 215–222.
- Safian AM and Bolton T. ***Escherichia coli*-associated granulomatous colitis in a cat.** *Vet Rec Case Rep* 2021; 9: e4. DOI: 10.1002/vrc2.4.
- Matsumoto I, Nakahima K, Morita H, et al. ***Escherichia coli*-induced granulomatous colitis in a cat.** *JFMS Open Rep* 2019; 5. DOI: 10.1177/2055116919836537.

- 14 Cochran L, Hill S, Lotti U, et al. **Clinical characteristics and long- term outcome of *E. coli*-associated granulomatous ileocolitis in dogs: five cases (2010–2014).** *J Small Anim Pract* 2021; 62: 588–598.
- 15 Manchester AC, Dogan B, Guo Y, et al. ***Escherichia coli*-associated granulomatous colitis in dogs treated according to antimicrobial susceptibility profiling.** *J Vet Intern Med* 2021; 35: 150–161.
- 16 Gelatt KN, van der Woerd A, Ketring KL, et al. **Enrofloxacin-associated retinal degeneration in cats.** *Vet Ophthalmol* 2001; 4: 99–106.
- 17 Meekins JM. **Acute blindness.** *Top Companion Anim Med* 2015; 30: 118–125.
- 18 Bandara Y, Priestanll SL, Chang YM, et al. **Outcome of chronic inflammatory enteropathy in cats: 65 cases (2011–2021).** *J Small Anim Pract* 2023; 64: 121–129.
- 19 Maunder CL, Reynolds ZF, Peacock L, et al. ***Campylobacter* species and neutrophilic inflammatory bowel disease in cats.** *J Vet Intern Med* 2016; 30: 996–1001.
- 20 Yaeger MJ and Gookin JL. **Histologic features associated with *tritrichomonas foetus*-induced colitis in domestic cats.** *Vet Pathol* 2005; 42: 797–804.
- 21 Cassmann E, White R, Atherly T, et al. **Alterations of the ileal and colonic mucosal microbiota in canine chronic enteropathies.** *PLoS One* 2016; 11. DOI: 10.1371/journal.pone.0147321.