



Surgical management of a laryngeal rhabdomyosarcoma in a cat

Authors: Alexander, Akash, Hughes, Katherine, Constantino-Casas, Fernando, and Owen, Laura Jane

Source: Journal of Feline Medicine and Surgery Open Reports, 9(2)

Published By: SAGE Publishing

URL: <https://doi.org/10.1177/20551169231194318>

BioOne Complete (complete.BioOne.org) is a full-text database of 200 subscribed and open-access titles in the biological, ecological, and environmental sciences published by nonprofit societies, associations, museums, institutions, and presses.

Your use of this PDF, the BioOne Complete website, and all posted and associated content indicates your acceptance of BioOne's Terms of Use, available at www.bioone.org/terms-of-use.

Usage of BioOne Complete content is strictly limited to personal, educational, and non - commercial use. Commercial inquiries or rights and permissions requests should be directed to the individual publisher as copyright holder.

BioOne sees sustainable scholarly publishing as an inherently collaborative enterprise connecting authors, nonprofit publishers, academic institutions, research libraries, and research funders in the common goal of maximizing access to critical research.



Surgical management of a laryngeal rhabdomyosarcoma in a cat

Akash Alexander^{id}, Katherine Hughes^{id},
Fernando Constantino-Casas and Laura Jane Owen

Journal of Feline Medicine and Surgery Open Reports
1–5

© The Author(s) 2023

Article reuse guidelines:

sagepub.com/journals-permissions

DOI: 10.1177/20551169231194318

journals.sagepub.com/home/jfmsopenreports

This paper was handled and processed by the European Editorial Office (ISFM) for publication in *JFMS Open Reports*



Abstract

Case summary An 11-year-old male castrated British Shorthair was referred for investigations into an upper respiratory tract mass. A partial laryngectomy was performed to excise the mass. Marginal resection of the mass involved excision of parts of the thyroid cartilage and left arytenoid cartilage. A tracheostomy tube was maintained for 48h postoperatively. The cat recovered without complication and was discharged at 72h postoperatively. Histopathology of the mass was deemed most consistent with a rhabdomyosarcoma (RMS).

Relevance and novel information Telephone follow-up 12 months postoperatively confirmed resolution of the clinical signs. To our knowledge, this is the first report of a laryngeal RMS in a cat. RMS should be considered a differential diagnosis for a laryngeal mass in a cat. This case demonstrates that resection via a partial laryngectomy may be a viable therapeutic option.

Keywords: Laryngeal mass; rhabdomyosarcoma; partial laryngectomy; larynx

Accepted: 26 July 2023

Case description

An 11-year-old male castrated British Shorthair was referred for investigations into an upper respiratory tract mass. Three months prior to referral, the cat had presented to its primary care veterinarian for episodes of wheezing and retching. These were symptomatically managed with dexamethasone (0.1 mg/kg SC) (Dexafort; MSD Animal Health), transiently improving the clinical signs. One month later, the cat re-presented with dyspnoea, inspiratory stridor and vomiting. On emergency intubation, a mass was noted within the larynx. Cytorreduction of the mass was performed, in a piecemeal fashion, to alleviate airway obstruction. The fragments of tissue were submitted for histopathology and deemed consistent with an ulcerated and inflamed soft-tissue sarcoma. There was resolution of the clinical signs following cytorreduction and the cat was discharged pending referral. No medication was prescribed postoperatively.

On presentation to the referral hospital, clinical examination of the cat was unremarkable. The owners reported that, in the weeks prior to referral, there had been two

paroxysmal coughing episodes and an intermittent increase in inspiratory noise. The cat was not receiving any medication at the time of admission. A laryngoscopy following induction of general anaesthesia revealed a mass associated with the rostral aspect of the left arytenoid cartilage (Figure 1). During inspiration, under a light plane of anaesthesia, the right arytenoid was observed to move normally, but no abduction of the left arytenoid cartilage was observed. CT (Aquilion 16; Toshiba) revealed a rounded, ill-defined, soft tissue-attenuating mass lesion on the left side of the larynx. The lesion was approximately 1 cm in size and homogeneously enhanced with contrast administration (Iohexol,

Department of Veterinary Medicine, University of Cambridge, Cambridge, UK

Corresponding author:

Akash Alexander BvetMed, AFHEA, MRCVS, Department of Veterinary Medicine, University of Cambridge, Madingley Road, Cambridge, CB3 0ES, UK
Email: akashalexander7@gmail.com



Creative Commons Non Commercial CC BY-NC: This article is distributed under the terms of the Creative Commons

Attribution-NonCommercial 4.0 License (<https://creativecommons.org/licenses/by-nc/4.0/>) which permits non-commercial use, reproduction and distribution of the work without further permission provided the original work is attributed as specified on the SAGE and Open Access pages (<https://us.sagepub.com/en-us/nam/open-access-at-sage>).

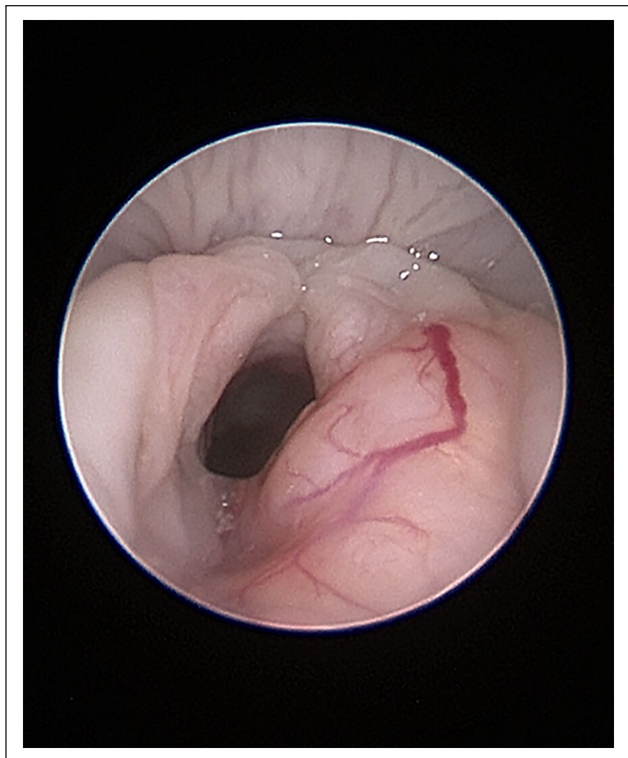


Figure 1 The mass, as seen on laryngoscopy, associated with the rostroventral aspect of the left arytenoid cartilage

Omnipaque; GE Healthcare). There was no evidence of metastatic spread. Repeat excisional biopsy was performed for palliation of the clinical signs while the owners considered the therapeutic options available. The cat received a single dose of buprenorphine (0.02 mg/kg IV) (Buprecare; AnimalCare) postoperatively.

One month later, a partial laryngectomy was performed as previously described.¹ In brief, the cat was positioned in dorsal recumbency with the neck elevated with a sandbag. A ventral midline incision was made over the larynx and cranial trachea. To improve surgical access during the procedure, a temporary tracheostomy was performed with incision of the annular ligament between the third and fourth tracheal rings. The thyroid cartilage was incised on the ventral midline and stay sutures were placed to facilitate retraction. The mass was readily exteriorised through the retraction of the thyroid cartilage (Figures 2 and 3). Marginal resection of the mass, with 1–2 mm margins of mucosa and cartilage, was performed using a combination of a no.15 scalpel blade and iris scissors. The excision included the cranial portion of the thyroid cartilage and the ventral portion of the left arytenoid cartilage. Mucosal apposition was possible at the rostral aspect of the defect. Caudally, mobilisation of the left sternohyoid muscle was required to cover the cartilage defect on the ventral aspect of the larynx. Care was taken to ensure all suture knots

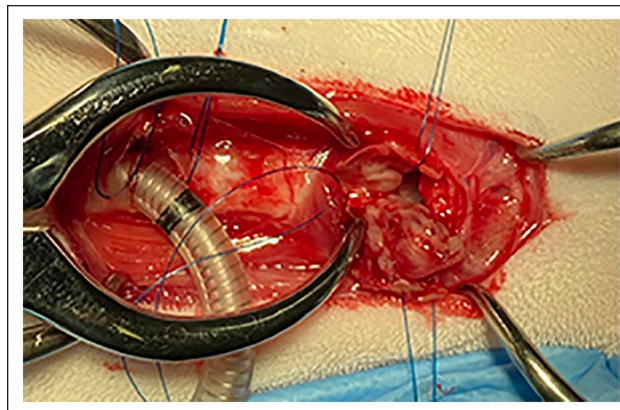


Figure 2 Intraoperative visualisation of the mass through a ventral incision into the thyroid cartilage

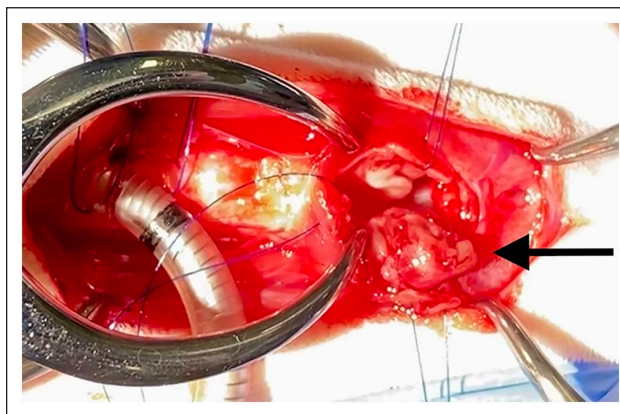


Figure 3 Close-up intraoperative image with illumination of the mass (black arrow)

(1.5 metric polyglecaprone 25; Monocryl; Ethicon) were located outside of the airway lumen. The endotracheal tube was removed from the temporary tracheostomy site and replaced with a 3.5 mm uncuffed tracheostomy tube. Closure of the surgical site was performed in a routine fashion, with a small region remaining open for the tracheostomy tube, which was maintained postoperatively. An oesophageal feeding tube was placed at the time of surgery. Intraoral examination at the end of surgery was satisfactory, with good movement of remaining arytenoid cartilages during recovery.

The cat recovered unremarkably from general anaesthesia and surgery. The cat was eating voluntarily within 12 h and had no complications associated with the tracheostomy tube. The tracheostomy tube and oesophageal feeding tube were removed after 48 h. The cat was discharged at 72 h postoperatively with tramadol (2.5 mg/kg, PO q8h for 5 days) (Summit Veterinary Pharmaceuticals) and a 12-day tapering dosage of prednisolone (1 mg/kg PO q24h down to 0.5 mg/kg PO every other day (Millpledge Veterinary).

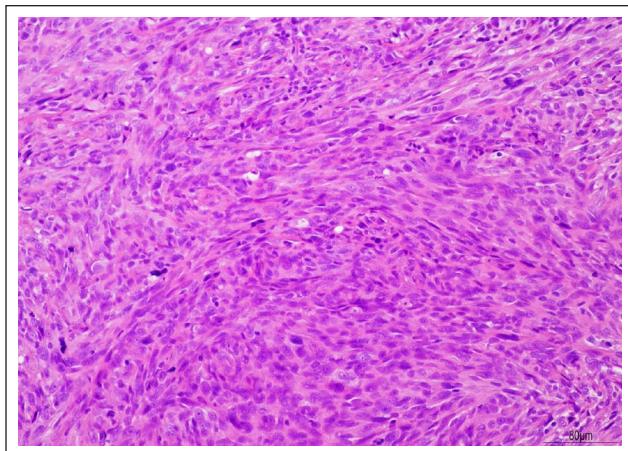


Figure 4 The neoplastic cells are predominantly arranged in wide interlacing bundles and streams supported by a moderately fine collagenous stroma. Haematoxylin and eosin stain. Scale bar = 80 μm

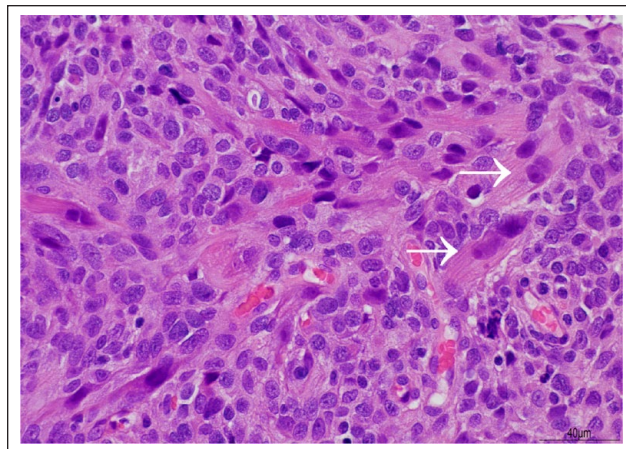


Figure 5 Rare neoplastic cells are elongated spindloid and have multiple nuclei arranged in a row, consistent with strap cells (arrows). Haematoxylin and eosin stain. Scale bar = 40 μm

Histopathology of the mass was deemed most consistent with a rhabdomyosarcoma (RMS). The neoplastic cells were predominantly arranged in wide interlacing bundles and streams supported by a moderately fine collagenous stroma (Figure 4). Rarely, these cells were elongated spindloid and had multiple nuclei arranged in a row, consistent with strap cells (Figure 5). The majority of the neoplastic cells exhibited intense cytoplasmic immunohistochemical staining for desmin 1 (Figure 6). There were 27 mitoses per 10 high power fields (per 2.37 mm²) and a moderate degree of anisocytosis and anisokaryosis throughout the neoplastic population. Neoplastic cells did not extend to the tissue margins but the clear surgical margins were considered 'narrow' (less than 2 mm fixed tissue).

Following histological diagnosis, no further treatment or repeat monitoring was elected for by the owner. At the time of writing (12 months postoperatively), the owner was contacted for telephone follow-up and reported the cat to be free of clinical signs and experiencing an excellent quality of life.

Discussion

To our knowledge, this is the first reported case of a laryngeal RMS in a cat. Laryngeal mass lesions currently reported in the feline literature include squamous cell carcinoma, lymphoma, inflammatory laryngeal disease, adenocarcinoma, peripheral nerve sheath tumour, lymphoid hyperplasia and cysts.²⁻⁷ There is currently one reported case of a laryngeal RMS in a dog, which was diagnosed on necropsy.⁸

This case drew similarities with previously reported cases of laryngeal disease in cats. The presenting clinical signs were consistent with those most commonly reported, namely stridor and dyspnoea.^{1,2,5} Additionally,

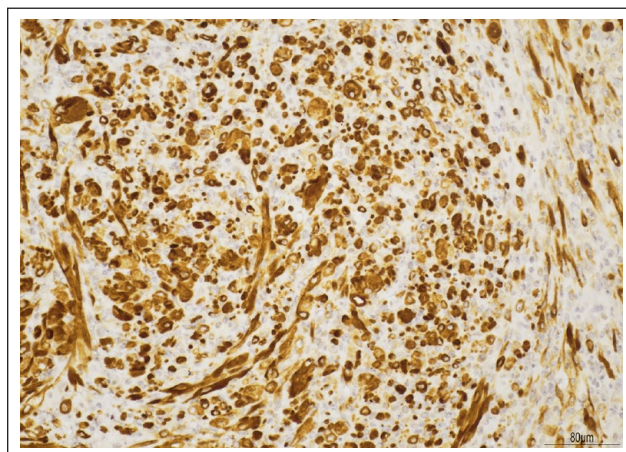


Figure 6 Approximately 60% of the neoplastic cells exhibit intense cytoplasmic immunohistochemical staining for desmin 1. Immunohistochemical staining for desmin 1 with haematoxylin counterstain. Scale bar = 80 μm

the transient improvement seen following corticosteroid administration has been previously reported.⁵ It is possible that this response was related to a reduction in tumoral inflammation, as seen on the initial histology report. It is also possible that a reduction in laryngeal oedema, caused by obstructive airway disease, may have occurred. Non-steroidal anti-inflammatories were avoided at all time points, in case there was a need to administer steroids to manage laryngeal oedema.

On laryngoscopy, no abduction of the left arytenoid cartilage was noted during inspiration. Potential causes for this were 'mass effect' obstruction preventing movement of the cartilage or compression of the recurrent laryngeal nerve resulting in paralysis. Following surgery, there was visible movement of the remaining portion of

arytenoid cartilage. This would indicate that the preoperative findings were likely owing to mass effect. On retrospective review of the preoperative laryngoscopy, mild movement of the dorsal cartilage was evident, supporting the theory of 'paralysis' secondary to mass effect.

With regards to management, three surgical options were discussed with the owners: total laryngectomy with permanent tracheostomy, partial laryngectomy or palliative permanent tracheostomy. Total laryngectomy would afford the best chance at complete surgical excision, with the lowest risk of local recurrence. However, this required balance with the associated perioperative risks and lifestyle changes required. Partial laryngectomy would not entail the same postoperative concerns and, dependent on tumour grade, marginal resection would still afford an agreeably low risk of recurrence. Based on the information presented, the owners elected to proceed with partial laryngectomy. The ability to still perform a total laryngectomy and permanent tracheostomy should local recurrence occur may have additionally influenced this decision.

A recent case series was the first to describe and report partial laryngectomy in cats.¹ The surgical technique in this case was based on that previously described, but with a few modifications. First, to improve visualisation and surgical access, re-intubation was performed intraoperatively through a separate tracheostomy site, rather than the ventral laryngotomy. Second, the temporary tracheostomy was maintained following surgery as a prophylactic measure, rather than placement in response to respiratory distress. The high rate of complications with temporary tracheostomies in cats led the authors of the previous case series to advocate for their use only when necessary, rather than as a preventative measure.⁹ It is noteworthy that this case series recorded a high rate of breathing difficulties seen following partial laryngectomy (4/6). A period of obstructed breathing could lead to further respiratory compromise and oedema formation.^{10,11} Episodes of respiratory obstruction can also result in increased lower airway secretions, which may increase the risk of tube occlusion, a commonly observed complication.^{9,12} Surgeon discretion in this case led to the decision to place and maintain the temporary tracheostomy tube prophylactically, allowing a smooth recovery, with no complications encountered. However, it should be noted that despite 4/6 cases experiencing breathing difficulties in the case series, only two cases required a temporary tracheostomy and 5/6 cases survived to discharge. Increasing evidence and experience may help to better predict cats that would benefit from prophylactic tracheostomy tube placement.

Laryngeal RMS is considered a rare tumour in the human medical literature and there is no definitive consensus on how it is best managed.^{13,14} Based on the current human medical literature and with application of data with respect to RMS in general, the optimal

therapy may be a multimodal approach consisting of surgery (partial or total laryngectomy) followed by chemo- and/or radiotherapy.^{14,15} Histologically, these tumours are categorised into embryonal, alveolar, botryoid and pleomorphic forms, as well as a rare spindle-cell variant,¹⁶ based on the medical pathology literature. Immunohistochemistry can increase the certainty of diagnosis with positive findings for muscle-specific actin, desmin and myoglobin, which are markers of mature muscle cells.¹³ In the single veterinary case report of a laryngeal RMS in a dog, the diagnosis was based on the appearance of a proliferation of neoplastic cells originating from skeletal muscles.⁸ The cells were noted to be atypical with a marked pleomorphism and the cytoplasm was noted to be scarce and irregular. There was no description of immunohistochemistry being performed within the report. A limitation of our report is that only one immunohistochemical marker (desmin) was used to confirm muscle as the cell type of origin. However, in this case, the histological features were highly suggestive of RMS and immunohistochemical staining was employed for confirmation only. In addition to the muscle-specific markers described above, MyoD and myogenin are two regulatory gene products that appear to be expressed specifically by skeletal muscle cells, with a nuclear expression pattern. These markers may be particularly helpful in the identification of poorly differentiated RMS.¹⁶

An interesting finding in this report was the propensity and speed with which the mass was noted to recur following cytoreduction. Following each intervention, there was resolution of clinical signs for 4–8 weeks. Although there was no standardisation of how much mass was removed, the resolution of clinical signs can be used as a proxy for the surgical dose administered. At the 12-month telephone follow-up, there were no reported clinical signs, and the cat continued to experience an excellent quality of life. This was not definitive, given the previous clinical progression, but would suggest no local recurrence. Although prognosticating a disease process based on a single case report should be carried out cautiously, this report does highlight the potential for surgical therapy in managing laryngeal RMSs in cats.

Conclusions

RMS should be considered a differential diagnosis for cats presenting with a laryngeal mass. This case demonstrates that marginal resection via a partial laryngectomy may be a viable therapeutic option. Temporary tracheostomy can aid in visualisation during surgery and in recovery from anaesthesia.

Acknowledgements We thank the staff of the Queen's Veterinary School Hospital for their care and assistance with this case. The authors gratefully acknowledge the technical

expertise of the histology laboratory staff in their preparation of histological sections and in the performance of immunohistochemistry.

Conflict of interest The authors declared no potential conflicts of interest with respect to the research, authorship, and/or publication of this article.

Funding The authors received no financial support for the research, authorship, and/or publication of this article.

Ethical approval The work described in this manuscript involved the use of non-experimental (owned or unowned) animals. Established internationally recognised high standards ('best practice') of veterinary clinical care for the individual patient were always followed and/or this work involved the use of cadavers. Ethical approval from a committee was therefore not specifically required for publication in *JFMS Open Reports*. Although not required, where ethical approval was still obtained, it is stated in the manuscript.

Informed consent Informed consent (verbal or written) was obtained from the owner or legal custodian of all animal(s) described in this work (experimental or non-experimental animals, including cadavers) for all procedure(s) undertaken (prospective or retrospective studies). No animals or people are identifiable within this publication, and therefore additional informed consent for publication was not required.

ORCID iD Akash Alexander  <https://orcid.org/0000-0002-3728-0750>

Katherine Hughes  <https://orcid.org/0000-0002-3331-1249>

References

- Moser J, Haimel G, Tichy A, et al. **Partial laryngectomy for the management of laryngeal masses in six cats.** *J Feline Med Surg* 2022; 24: 373–380.
- Beatty JA, Lam AL, Beatty JA, et al. **Laryngeal disease in 69 cats: a retrospective multicentre study.** [https://www.researchgate.net/publication/236331402\(2012\)](https://www.researchgate.net/publication/236331402(2012)) (accessed 29 November 2022).
- Costello MF, Keith D, Hendrick M, et al. **Acute upper airway obstruction due to inflammatory laryngeal disease in 5 cats.** *J Vet Emerg Crit Care* 2001; 11: 205–210.
- Jakubiak MJ, Cecile Siedlecki DT, Elisabeth Zenger D, et al. **Laryngeal, laryngotracheal, and tracheal masses in cats: 27 cases (1998–2003).** *J Am Anim Hosp Assoc* 2005; 41: 310–316.
- Taylor SS, Harvey AM, Barr FJ, et al. **Laryngeal disease in cats: a retrospective study of 35 cases.** *J Feline Med Surg* 2009; 11: 954–962.
- Carlisle CH, Biery DN and Thrall DE. **Tracheal and laryngeal tumors in the dog and cat: literature review and 13 additional patients.** *Vet Radiol* 1991; 32: 229–235.
- Vincenti S, Betting A, Durand A, et al. **Total laryngectomy in a cat with a laryngeal peripheral nerve sheath tumor.** *Vet Surg* 2021; 50: 1533–1541.
- Dias FGG, Cintra PP, Calazans SG, et al. **Laryngeal rhabdomyosarcoma in a dog: case report.** *Arq Bras Med Vet Zootec* 2018; 70: 1423–1426.
- Guenther-Yenke CL and Rozanski EA. **Tracheostomy in cats: 23 cases (1998–2006).** *J Feline Med Surg* 2007; 9: 451–457.
- Bhattacharya M, Kallet RH, Ware LB, et al. **Negative-pressure pulmonary edema.** *Chest* 2016; 150: 927–933.
- Udeshi A, Cantie SM and Pierre E. **Postobstructive pulmonary edema.** *J Crit Care* 2010; 25. DOI: 10.1016/j.jcrc.2009.12.014.
- Alb M, Tsagogiorgas C and Meinhardt JP. **Negative-pressure pulmonary edema (NPPE)** [in German]. *Anesthesiol Intensivmed Notfallmed Schmerzther* 2006; 41: 64–78.
- Kukwa W, Wojtowicz P, Jagielska B, et al. **Laryngeal embryonal rhabdomyosarcoma in an adult—a case presentation in the eyes of geneticists and clinicians.** *BMC Cancer* 2011; 11: 166. DOI: 10.1186/1471-2407-11-166.
- Dikbas O, Altundag K, Abali H, et al. **Embryonal rhabdomyosarcoma of the larynx.** *Otolaryngol Head Neck Surg* 2005; 133: 160–162.
- Pittore B, Fancello G, Cossu Rocca P, et al. **Rhabdomyosarcoma: a rare laryngeal neoplastic entity** [in Italian]. *Acta Otorhinolaryngol Ital* 2010; 30: 52–57.
- Shi J, Gao R, Zhang J, et al. **Invasive spindle-cell rhabdomyosarcoma with osteolysis in a dog: case report and literature review.** *J Vet Diagn Invest* 2023; 35: 168–172.