



## **Feline herpesvirus-1-related multiple respiratory eosinophilic nodules in an adult cat receiving long-term oral prednisolone**

Authors: Philp, Helen S, Johnson, Lynelle R, Choi, Eunju April, Brosnan, Robert J, and Slater, Robert T

Source: Journal of Feline Medicine and Surgery Open Reports, 10(1)

Published By: SAGE Publishing

URL: <https://doi.org/10.1177/20551169231220291>

---


BioOne Complete ([complete.BioOne.org](https://complete.BioOne.org)) is a full-text database of 200 subscribed and open-access titles in the biological, ecological, and environmental sciences published by nonprofit societies, associations, museums, institutions, and presses.

Your use of this PDF, the BioOne Complete website, and all posted and associated content indicates your acceptance of BioOne's Terms of Use, available at [www.bioone.org/terms-of-use](https://www.bioone.org/terms-of-use).

Usage of BioOne Complete content is strictly limited to personal, educational, and non - commercial use. Commercial inquiries or rights and permissions requests should be directed to the individual publisher as copyright holder.

---

BioOne sees sustainable scholarly publishing as an inherently collaborative enterprise connecting authors, nonprofit publishers, academic institutions, research libraries, and research funders in the common goal of maximizing access to critical research.



# Feline herpesvirus-1-related multiple respiratory eosinophilic nodules in an adult cat receiving long-term oral prednisolone

*Journal of Feline Medicine and Surgery Open Reports*  
1–7

© The Author(s) 2024

Article reuse guidelines:

sagepub.com/journals-permissions

DOI: 10.1177/20551169231220291

journals.sagepub.com/home/jfmsopenreports

This paper was handled and processed by the American Editorial Office (AAFP) for publication in *JFMS Open Reports*



Helen S Philp<sup>1</sup> , Lynelle R Johnson<sup>2</sup> ,  
Eunju April Choi<sup>3</sup>, Robert J Brosnan<sup>4</sup>   
and Robert T Slater<sup>1</sup>

## Abstract

**Case summary** A 10-year-old male castrated domestic shorthair cat was presented for evaluation of a 3-day history of increased inspiratory effort. The cat had received prednisolone 1 mg/kg PO q24h for 1 year due to chronic diarrhea. On physical examination, the patient exhibited severe stridor, intermittent open-mouth breathing and bilateral mucopurulent nasal discharge. Subcutaneous emphysema was palpated over the dorsal cervical region. Mild hypoventilation (PvCO<sub>2</sub> 55.1 mmHg; approximate reference interval 35–45 mmHg) was identified. Cervicothoracic radiographs showed marked gas tracking within cervical soft tissues with concurrent laryngeal thickening, pulmonary nodules, a bronchial pulmonary pattern, pneumomediastinum and aerophagia. The cat was hospitalized and treated overnight with oxygen and intravenous fluid therapy before anesthesia the next day. On laryngoscopy, a large tracheal mass was observed arising from the right subglottic region and was removed using biopsy forceps. CT revealed an additional mass at the level of the tracheal bifurcation causing marked luminal narrowing of the trachea and proximal main bronchi. The cat made a good initial recovery, although moderate stridor persisted. Five days later, the cat was re-examined due to recurrence of respiratory distress and orthopnea, and the owner elected euthanasia. Histopathology revealed severe nodular obstructive eosinophilic plasmacytic laryngotracheitis with intranuclear inclusion bodies positive for feline herpesvirus-1 on immunohistochemistry.

**Relevance and novel information** This report describes the presentation and management of a cat with respiratory distress secondary to intratracheal eosinophilic masses caused by feline herpesvirus-1. Although the outcome was ultimately unsatisfactory, to the authors' knowledge, this clinical presentation has not been previously reported.

**Keywords:** Eosinophilic; herpesvirus-1; respiratory; tracheal

**Accepted:** 25 November 2023

<sup>1</sup>William R. Pritchard Veterinary Medical Teaching Hospital, University of California Davis, Davis, CA, USA

<sup>2</sup>Department of Medicine & Epidemiology, School of Veterinary Medicine, University of California Davis, Davis, CA, USA

<sup>3</sup>Department of Pathology, Microbiology & Immunology, School of Veterinary Medicine, University of California Davis, Davis, CA, USA

<sup>4</sup>Department of Surgical & Radiological Sciences, School of Veterinary Medicine, University of California Davis, Davis, CA, USA

### Corresponding author:

Helen S Philp BVMS, DACVECC, William R. Pritchard Veterinary Medical Teaching Hospital, University of California Davis, 1 Garrod Drive, Davis, CA 95618, USA  
Email: hphilp@ucdavis.edu



Creative Commons Non Commercial CC BY-NC: This article is distributed under the terms of the Creative Commons

Attribution-NonCommercial 4.0 License (<https://creativecommons.org/licenses/by-nc/4.0/>) which permits non-commercial use, reproduction and distribution of the work without further permission provided the original work is attributed as specified on the SAGE and Open Access pages (<https://us.sagepub.com/en-us/nam/open-access-at-sage>).

## Introduction

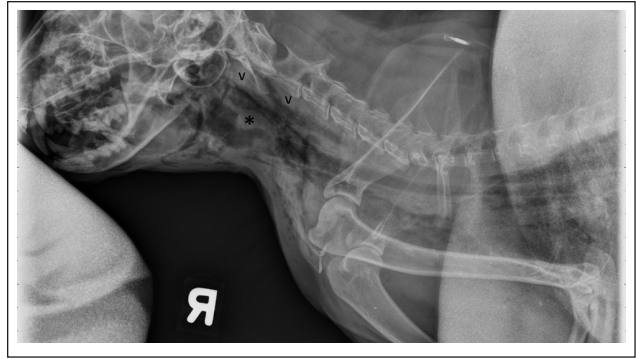
Feline herpesvirus-1 (FHV-1) enters via the oronasal route and replicates in the upper respiratory tract epithelium.<sup>1</sup> Acute infection leads to oculonasal discharge, fever and tracheitis, which are followed by life-long latent infection in approximately 80% of cases.<sup>2,3</sup> Cats with latent infection can remain asymptomatic, develop recrudescence during times of stress or immunosuppression, or may develop chronic signs. Documentation of a direct relationship between the virus and many disease syndromes is hampered by the ubiquity of FHV-1 in the feline population and asymptomatic carriage, as well as widespread vaccination. However, chronic syndromes associated with histopathologic or molecular evidence of FHV-1 include non-healing corneal ulcers,<sup>4</sup> dry eye,<sup>5</sup> facial dermatitis,<sup>6,7</sup> corneal sequestrum, eosinophilic keratitis<sup>8</sup> and chronic rhinosinusitis.<sup>9</sup> Lung involvement is rare in natural FHV-1 infection although fibrinonecrotic pneumonia has been reported.<sup>1,10–13</sup> This report describes the novel presentation of a cat with respiratory distress secondary to intratracheal eosinophilic masses caused by FHV-1.

## Case description

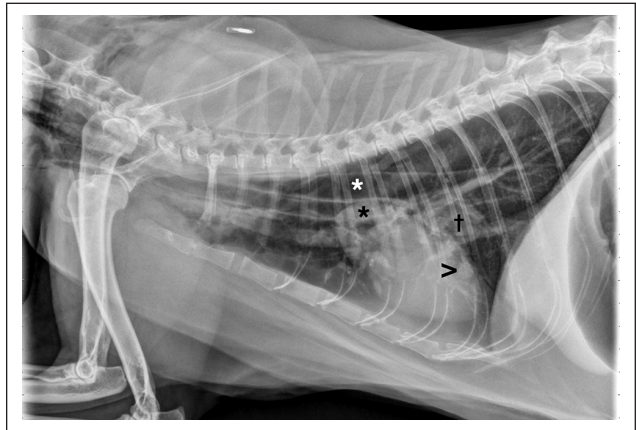
A 10-year-old male castrated domestic shorthair cat was presented to the emergency service at the University of California Davis Veterinary Medical Teaching Hospital for acute respiratory distress. The cat's voice had changed in pitch 2–3 weeks previously and 2–3 episodes of coughing had been observed. The owners reported a 7-year history of intermittent upper respiratory tract signs that were non-responsive to doxycycline (Doxycycline; Cipla) or prednisolone (Prednisolone; Lloyd). Chronic diarrhea had been managed with a prescription diet (Gastrointestinal Biome; Hill's) and prednisolone at a dose of 1 mg/kg PO q24h for the past year.

On physical examination, the cat's rectal temperature was 99.6°F (37.6°C), heart rate was 190 bpm and respiratory rate was 30 bpm. There was moderate, bilateral mucopurulent nasal discharge with preservation of nasal airflow. The cat exhibited markedly increased inspiratory and expiratory effort, severe stridor and intermittent open-mouth breathing. Subcutaneous emphysema was palpated over the dorsal cervical region.

Supplemental oxygen was administered during placement of an intravenous catheter and butorphanol (Torbugesic; Zoetis) was given for sedation (0.2 mg/kg IV). Venous blood gas analysis revealed mild hypoventilation with a PvCO<sub>2</sub> of 55.1 mmHg (approximate reference interval [RI] 35–45 mmHg). Cervicothoracic radiographs revealed marked gas tracking within cervical soft tissues, with concurrent pneumomediastinum and aerophagia (Figure 1). The laryngeal soft tissues were thickened, with convex margination. Multilobar,



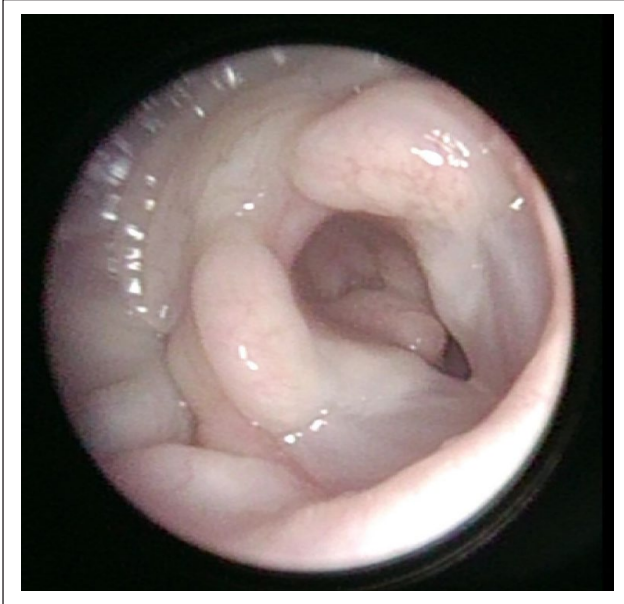**Figure 1** Right lateral radiograph showing marked gas tracking within the cervical soft tissues (black arrowheads), most severe surrounding the pharynx/larynx, with subjective thickening of the laryngeal soft tissues (black asterisk)



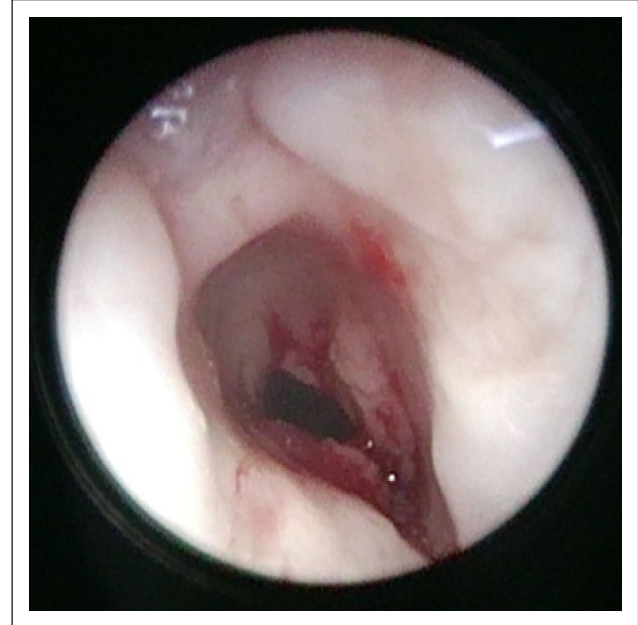**Figure 2** Right lateral radiograph showing pneumomediastinum and multilobar, ventrally distributed bronchocentric soft tissue nodules (black arrowhead) containing dystrophic mineralization. There is a soft tissue opacity at the heart base (black asterisk), correlating to the tracheal mass identified on CT. The white asterisk identifies esophageal dilation suggestive of aerophagia. The black dagger correlates to the axillary/caudal mediastinal mass identified on CT

ventrally distributed bronchocentric soft-tissue nodules containing dystrophic mineralization and a diffuse bronchial pattern were also observed (Figure 2). The cat was hospitalized overnight on oxygen and intravenous fluid therapy.

The next morning, the cat remained stridorous but with improved inspiratory effort and reduced subcutaneous emphysema. A complete blood count and serum biochemistry were unremarkable apart from increased creatine kinase at 4287 IU/l (RI 73–260 IU/l). A feline immunodeficiency virus (FIV)/feline leukemia virus (FeLV) SNAP test (SNAP Combo FeLV Ag/FIV Antibody Test; IDEXX) and *Cryptococcus* antigen titer were negative.



**Figure 3** Endoscopic view of the right-sided subglottic mass obscuring the tracheal lumen



**Figure 4** Endoscopic view of the larynx after biopsy and debulking of the right-sided subglottic mass

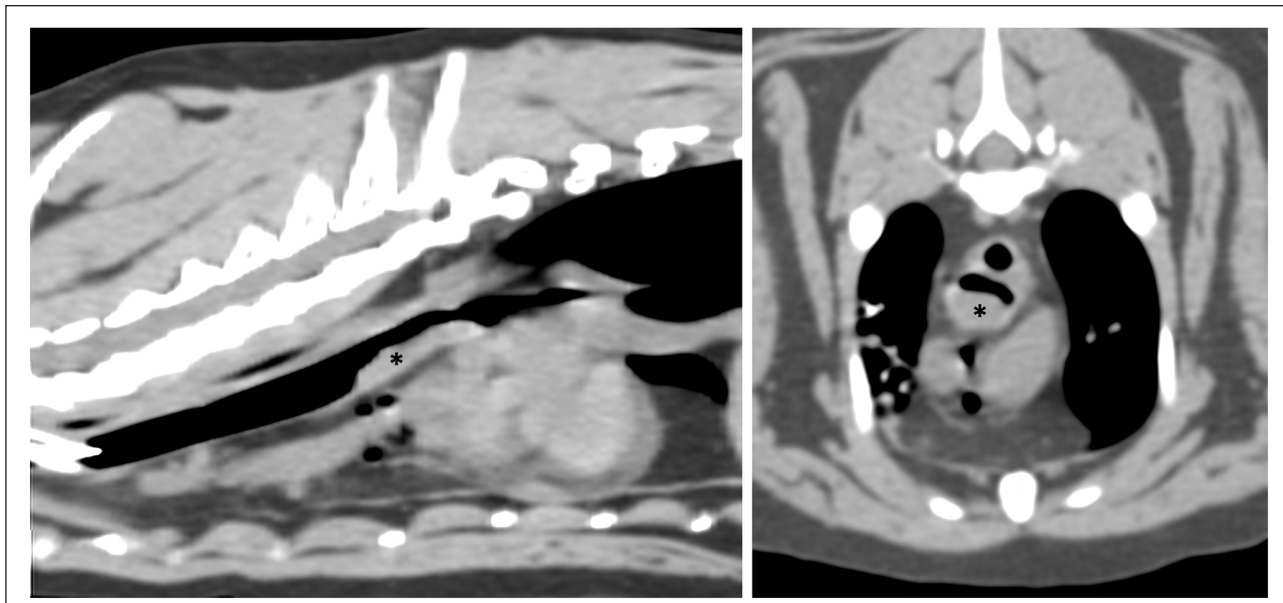
On day 3 of hospitalization, the patient was sedated with butorphanol, and a light plane of anesthesia was induced with propofol (Propoflo; Zoetis) and midazolam (Midazolam; Westward) administered intravenously for laryngeal examination with endoscopy and CT to follow. Laryngoscopy using a rigid 0° telescope with a sheath (Endoscopy Support Services) revealed mild laryngeal swelling. A large pink mass measuring approximately 5 × 4 mm arising from the right subglottic region was visible within the trachea, obstructing virtually the entire lumen and precluding passage of a cuffed endotracheal tube (Figure 3). A companion lesion (measuring approximately 2 × 3 mm) could be seen distally originating from the left subglottic region of the trachea. The right-sided, rostral mass was removed using 4 mm Sontec cup biopsy forceps (Figure 4) and the patient was intubated with a 4.5 mm cuffed endotracheal tube.

Anesthesia was subsequently maintained using isoflurane in oxygen. End-tidal CO<sub>2</sub> measured by side-stream capnography was in the range of 52–61 mmHg, and non-invasive peripheral oxygen saturation was 100%. CT revealed a large volume of fluid-attenuating content within both nasal cavities and the left frontal sinus. There was a rounded soft-tissue mass associated with the ventral margin of the distal trachea at the level of the bifurcation, causing marked luminal narrowing of the trachea and proximal mainstem bronchi (Figure 5). There were multifocal, patchy and nodular soft-tissue opaque regions of lung consolidation (some bronchus-associated), most pronounced within the ventral aspects of the cranial lung lobes, as well as multifocal mineral foci within the pulmonary parenchyma (Figure 6). There

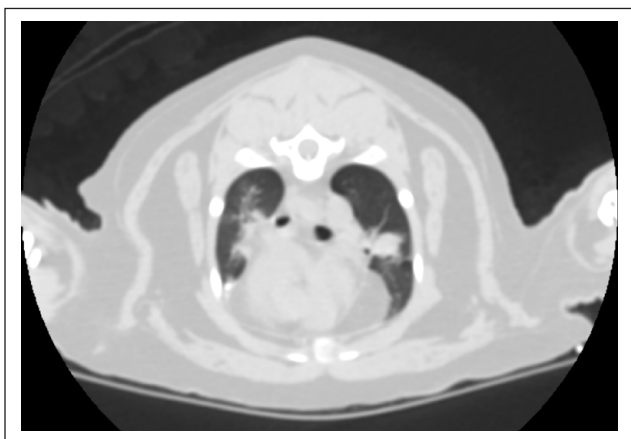
was diffuse bronchial wall thickening with a small volume of fluid-attenuating material within the left mainstem bronchus. The lobar bronchus of the caudal subsegment of the left cranial lung lobe tapered abruptly, and the ventral aspect of this lobe was consolidated with rounded margins. The ventral aspect of the accessory lobe was similarly consolidated, with air bronchogram formation. There was a mixed soft-tissue and fluid-attenuating mass involving the caudal mediastinum and cranial aspect of the accessory lung lobe, with faint peripheral mineralization measuring approximately 1.6 × 1.3 × 1.1 cm. Anesthetic maintenance was changed to a propofol infusion to allow tracheoscopy using a 4.9 mm flexible videoscope (BF-Q190; Olympus). The examination showed multiple pale pink to white masses distally in the trachea to the level of the carina. Biopsy forceps, ratigators, loop snares and three-prong graspers were unable to lift the obstructive masses from the epithelial surface, limiting further airway evaluation. The most proximal mass near the carina was sampled, inducing mild hemorrhage that spontaneously resolved.

Impression smears of all masses revealed mats of eosinophils and fewer mast cells. Histopathology of the subglottic and tracheal carinal mass revealed abundant eosinophils forming the bulk of the mass, with elongated epithelium occasionally covering the surface and a small subset of mast cells. Based on the mass effect and mast cell population, a mast cell neoplasm or underlying lymphoproliferative process was prioritized.

The cat was administered dexamethasone sodium phosphate (Dexamethasone SP; Bimeda) 0.1 mg/kg IV



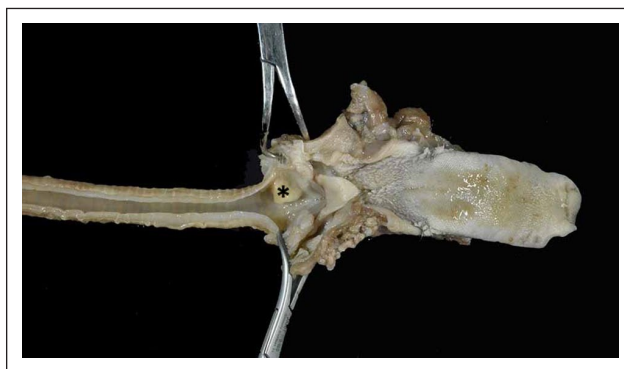
**Figure 5** Sagittal and transverse thoracic CT images showing a rounded soft-tissue mass (asterisk) associated with the ventral margin of the distal trachea at the level of the bifurcation, causing marked luminal narrowing of the trachea



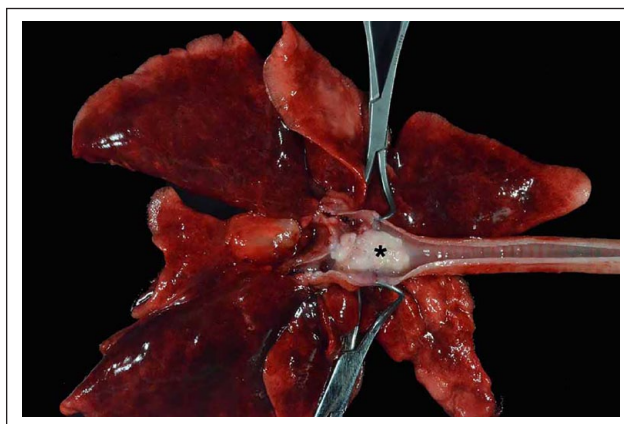
**Figure 6** Transverse thoracic CT image showing multifocal pulmonary abnormalities

and terbutaline (Terbutaline sulfate; APP Pharmaceuticals) 0.01 mg/kg SC before anesthetic recovery in an oxygen cage. There was moderate improvement in respiratory effort but persistent stridor. The cat was discharged the next day on prednisolone (5 mg PO q24h) and inhaled dexamethasone (0.2 ml dexamethasone SP diluted in one vial of Addipak saline (Saline; Teleflex) placed in a nebulizer cup and administered for 10–15 mins q12h).<sup>14</sup> The re-check examination 2 days later was unchanged.

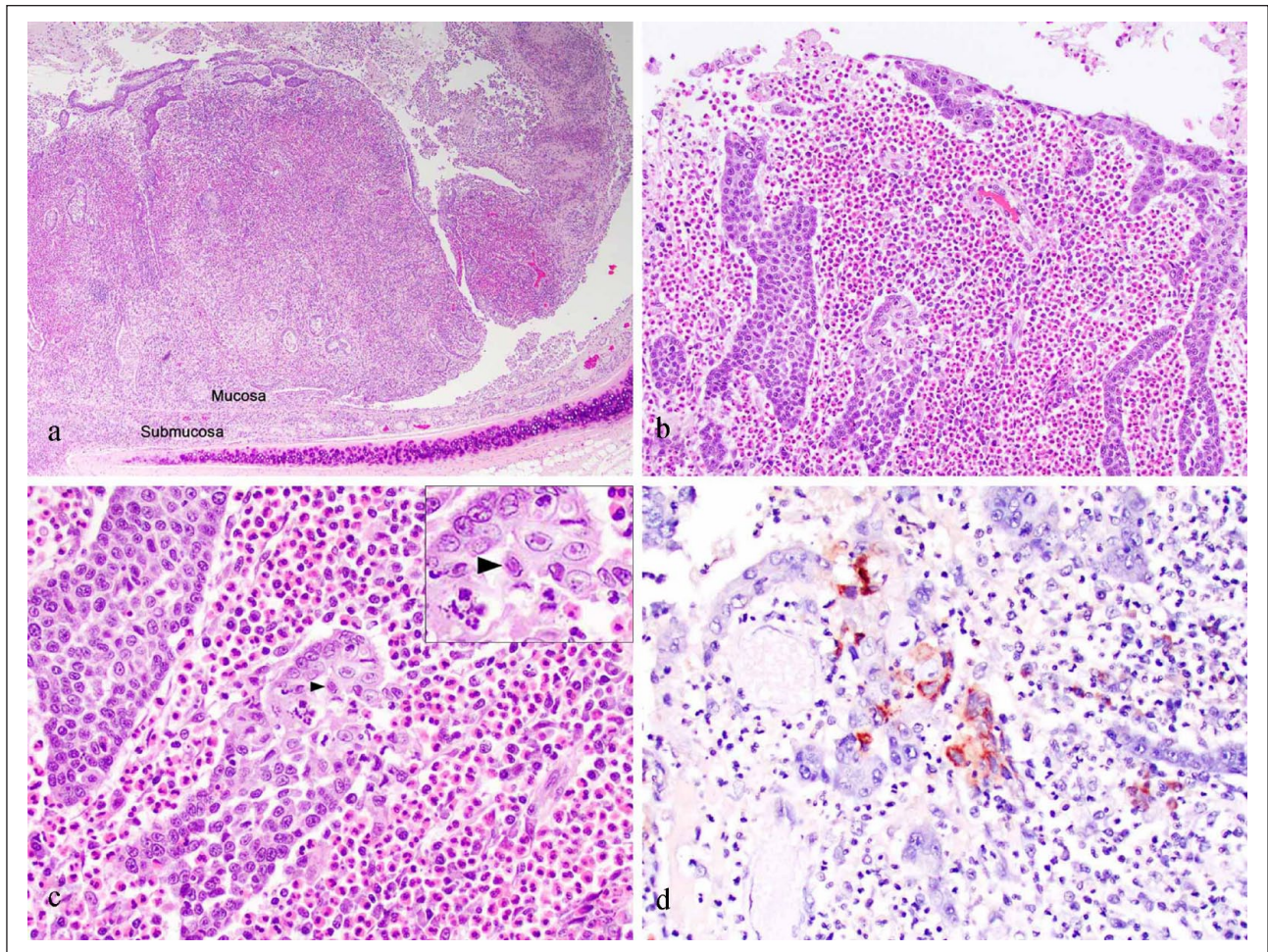
Five days later, the cat was re-examined due to a recurrence of respiratory distress and the owner elected euthanasia. Gross examination identified masses described during ante-mortem examination (Figures 7 and 8). Histopathology was near identical to the biopsy specimen, revealing severe nodular obstructive eosinophilic



**Figure 7** Post-mortem appearance of the remaining subglottic mass after fixation in 10% neutral buffered formalin. A large exophytic mass (asterisk) arising from the mucosa occupies the lumen



**Figure 8** Post-mortem appearance of the tracheal mass. At the carina is an obstructive, soft but firmly attached white mass (asterisk). The lungs are atelectatic and congested



**Figure 9** Representative histology of the carinal mass. (a) The mass effect is appreciated in this low-magnification view confirming the mass arising from and thickening the mucosa. H&E,  $\times 4$ . (b) Higher magnification of a superficial portion of the mass highlighting the massive eosinophilic inflammation with fewer plasma cells and histiocytes. Normal respiratory epithelium is not present and instead the mass is covered by squamous epithelium indicating metaplasia. H&E,  $\times 20$ . (c) Intranuclear eosinophilic inclusion bodies identified occasionally within the epithelial cells (arrowhead). Inclusion bodies are magnified in the inset. H&E,  $\times 40$ . (d) Immunohistochemical staining against FHV-1 highlighting brown cytoplasmic staining in affected cells.  $\times 40$ . FHV-1 = feline herpes virus-1; H&E = hematoxylin and eosin

plasmacytic laryngotracheitis. In addition, there was epithelial squamous metaplasia and dysplasia with infrequent intranuclear inclusion bodies positive for FHV-1 on immunohistochemistry (Figure 9). The left cranial lung lobe had severe bronchiectasis with eosinophilic lymphoplasmacytic bronchitis, intraluminal obstructive fibrosis and necrotic cellular debris, as well as severe, obstructive atelectasis. Additional findings included severe mucoid rhinosinusitis and mild chronic pancreatic inflammation. The intestinal tract was considered normal.

## Discussion

The cause of the eosinophilic nodular masses in the distal larynx, tracheal carina and lungs was FHV-1, evidenced by intranuclear inclusion bodies and positive immunohistochemical staining. While FHV-1 is known

to cause eosinophilic ulcerative facial dermatitis<sup>7</sup> and eosinophilic keratitis,<sup>8</sup> to the authors' knowledge, nodular eosinophilic lesions in the respiratory tract have not been previously described. Constrictive bronchiolitis obliterans presumed secondary to FHV-1 infection has been described but led to neutrophilic inflammation.<sup>15</sup> Disseminated FHV-1 leading to necrotizing laryngotracheitis, bronchopneumonia and gastritis associated with eosinophilic intranuclear inclusion bodies has also been reported.<sup>13</sup> The reason why some FHV-1-associated lesions, such as ulcerative dermatitis, are eosinophil-rich is unknown. Most FHV-1-associated lesions are not eosinophilic, and eosinophilic inflammation is not typical for herpesvirus infection in other species. In humans, herpes simplex virus has rarely been associated with eosinophilic ulcerative esophagitis<sup>16</sup> and eosinophilic cellulitis.<sup>17</sup> It is possible that epithelial cells infected with

FHV-1 in older cats produce eotaxins to induce a florid eosinophilic response. However, research is required to confirm this speculation.

Inflammatory laryngotracheal masses have been reported in cats,<sup>18</sup> but none were described to be eosinophilic. In general, mass-forming upper and lower respiratory eosinophilic lesions are considered unusual in cats. In dogs, two conditions have been reported to present in this manner: intraluminal eosinophilic granulomas<sup>19</sup> and canine eosinophilic pulmonary granulomatosis.<sup>20</sup> Whether these represent a continuum of the same pathophysiological process or separate entities altogether, both are considered unusual hypersensitivity responses.<sup>21</sup>

There are numerous potential causes for pneumomediastinum and subcutaneous emphysema, but two are prioritized in this patient. First, damage to the airways can lead to loss of mural integrity, alveolar rupture and direct leakage of air into the mediastinum. This is the most common cause in people<sup>22</sup> and has been reported in a cat with FHV-1-related necrotizing bronchopneumonia.<sup>23</sup> A less likely possibility is alveolar rupture secondary to respiratory distress. Air may subsequently enter the mediastinum via bronchovascular bundles/sheaths, as described by Macklin.<sup>24</sup> Other reported causes excluded in this patient include trauma, foreign bodies and positive-pressure ventilation.<sup>25–27</sup> In people with pneumomediastinum, conservative management is often pursued with oxygen therapy to promote free air absorption, and this approach was effective in the cat of this report.<sup>28</sup>

The role of long-term prednisolone administration on host immune defenses and the development of tracheal lesions in the cat in this report is unclear. During the latent stage of FHV-1 infection, viral DNA persists in the nuclei of sensory ganglion neurons.<sup>1</sup> It is thought that T lymphocytes prevent reactivation via the production of gamma interferon and lymphocyte-mediated cytotoxicity.<sup>1</sup> Reactivation of latent infection can be induced experimentally by glucocorticoid treatment in approximately 70% of cats,<sup>10</sup> although clinical signs of reactivation in cats administered methylprednisolone appear to be mild.<sup>29</sup> The involvement of prednisolone treatment in the pathogenesis of the lesions described in this report is unknown.

Guidelines for the management of FHV-1-induced disease have been published by the European Advisory Board on Cat Diseases.<sup>2</sup> The guidelines emphasize supportive care, antiviral therapy and treatment of secondary bacterial infections. Ideally, antiviral therapy would have been instituted in the patient in this report and may have hastened resolution of the lesions. One commonly used antiviral drug is famciclovir, which can reduce the duration and severity of clinical signs of FHV-1 infection with minimal side effects.<sup>30</sup> However, the authors were not aware that FHV-1 was the causative agent at the time. Ultimately, the most immediate concern was the airway obstruction resulting from the

tracheal masses. Unfortunately, it proved very difficult to debulk the lesions and airway obstruction persisted after the endoscopy. On histopathology, it was noted that the mass effect was primarily mucosal, but having a broad base, squamous metaplasia and fibrosis may have caused the masses to become firmly adhered to the tracheal wall and resistant to attempts to debulk them. Nebulization with saline and dexamethasone was initiated but only a short temporary improvement was achieved. It is possible that laser resection or surgical intervention would have been successful in debulking the masses and relieving airway obstruction.

## Conclusions

Nodular and mass-forming eosinophilic lesions secondary to FHV-1 infection should be considered as a differential diagnosis in cats presenting with signs of upper airway obstruction. These lesions may prove difficult to debulk via endoscopy.

**Acknowledgements** We thank Dr Kristina Vu for the post-mortem management of this patient and gross photography.


**Conflict of interest** The authors declared no potential conflicts of interest with respect to the research, authorship, and/or publication of this article.


**Funding** The authors received no financial support for the research, authorship, and/or publication of this article.

**Ethical approval** The work described in this manuscript involved the use of non-experimental (owned or unowned) animals. Established internationally recognized high standards ('best practice') of veterinary clinical care for the individual patient were always followed and/or this work involved the use of cadavers. Ethical approval from a committee was therefore not specifically required for publication in *JFMS Open Reports*. Although not required, where ethical approval was still obtained, it is stated in the manuscript.

**Informed consent** Informed consent (verbal or written) was obtained from the owner or legal custodian of all animal(s) described in this work (experimental or non-experimental animals, including cadavers) for all procedure(s) undertaken (prospective or retrospective studies). For any animals or people individually identifiable within this publication, informed consent (verbal or written) for their use in the publication was obtained from the people involved.

**ORCID ID** Helen S Philp  <https://orcid.org/0000-0001-7420-8021>

Lynelle R Johnson  <https://orcid.org/0000-0002-5331-5626>

Robert J Brosnan  <https://orcid.org/0000-0002-0508-6363>

## References

- 1 Maes R. **Felid herpesvirus type 1 infection in cats: a natural host model for alphaherpesvirus pathogenesis.** *ISRN Vet Sci* 2012; 2012. DOI: 10.5402/2012/495830.

- 2 Thiry E, Addie D, Belak S, et al. **Feline herpesvirus infection: ABCD guidelines on prevention and management.** *J Feline Med Surg* 2009; 11: 547–555.
- 3 Gaskell RM and Povey RC. **Experimental induction of feline viral rhinotracheitis virus re-excretion in FVR-recovered cats.** *Vet Rec* 1977; 100: 128–133.
- 4 Ali K, Mostafa A and Soliman S. **Complicated corneal ulceration in cats: diagnosis and treatment outcomes of 80 cases (2014–2018).** *J Hellenic Vet Med Soc* 2021; 72: 3041.
- 5 Lim CC, Reilly CM, Thomasy SM, et al. **Effects of feline herpesvirus type 1 on tear film break-up time, Schirmer tear test results, and conjunctival goblet cell density in experimentally infected cats.** *Am J Vet Res* 2009; 70: 394–403.
- 6 Porcellato I, Luciani L, Marenzoni ML, et al. **Feline herpesvirus ulcerative dermatitis: an atypical case?** *Vet Derm* 2018; 29: 258–296.
- 7 Lee M, Bosward KL and Norris JM. **Immunohistological evaluation of feline herpesvirus-1 infection in feline eosinophilic dermatoses or stomatitis.** *J Feline Med Surg* 2010; 12: 72–79.
- 8 Labelle A and Labelle P. **Eosinophilic keratoconjunctivitis in cats.** *Vet Clin North Am Small Anim Pract* 2023; 53: 353–365.
- 9 Reed N. **Chronic rhinitis in the cat.** *Vet Clin North Am Small Anim Pract* 2014; 44: 33–50.
- 10 Gaskell R, Dawson S, Radford A, et al. **Feline herpesvirus.** *Vet Res* 2007; 38: 337–354.
- 11 Feinstein L, Miller GF and Penney BE. **Diagnostic exercise: lethal pneumonia in neonatal kittens.** *Comp Med* 1998; 48: 190–192.
- 12 Chvala-Mannsberger S, Bagó Z and Weissenböck H. **Occurrence, morphological characterization and antigen localization of felid herpesvirus-induced pneumonia in cats: a retrospective study (2000–2006).** *J Comp Pathol* 2009; 141: 163–169.
- 13 McGregor GF, Sheehan K and Simko E. **Pneumonia and gastritis in a cat caused by feline herpesvirus-1.** *Can Vet J* 2016; 57: 147–150.
- 14 Klassen TP, Watters LK, Feldman ME, et al. **The efficacy of nebulized budesonide in dexamethasone-treated outpatients with croup.** *Pediatrics* 1996; 97: 463–466.
- 15 Hsieh PI, Chen HW, Yeh HN, et al. **Constrictive bronchiolitis obliterans with a presumptive etiology of preceding feline herpesvirus infection in a cat.** *BMC Vet Res* 2022; 18: 258. DOI: 10.1186/s12917-022-03368-4.
- 16 Kim J, Lee K and Lee W. **A case of eosinophilic esophagitis associated with herpes esophagitis in a pediatric patient.** *Clin Endosc* 2019; 52: 606–611.
- 17 Ludwig RJ, Grundmann-Kollmann M, Holtmeier W, et al. **Herpes simplex virus type 2-associated eosinophilic cellulitis (Wells' syndrome).** *J Am Acad Dermatol* 2003; 48: S60–S61.
- 18 Jakubiak MJ, Siedlecki CT, Zenger E, et al. **Laryngeal, laryngotracheal, and tracheal masses in cats: 27 cases (1998–2003).** *J Am Anim Hosp Assoc* 2005; 41: 310–316.
- 19 Johnson LR, Johnson EG, Hulsebosch SE, et al. **Eosinophilic bronchitis, eosinophilic granuloma, and eosinophilic bronchopneumopathy in 75 dogs (2006–2016).** *J Vet Int Med* 2019; 33: 2217–2226.
- 20 Abbott DEE and Allen AL. **Canine eosinophilic pulmonary granulomatosis: case report and literature review.** *J Vet Diagn Invest* 2020; 32: 329–335.
- 21 Clercx C and Peeters D. **Canine eosinophilic bronchopneumopathy.** *Vet Clin North Am Small Anim Pract* 2007; 37: 917–935.
- 22 Sakai M, Murayama S, Gibo M, et al. **Frequent cause of the Macklin effect in spontaneous pneumomediastinum: demonstration by multidetector-row computed tomography.** *J Comput Assist Tomogr* 2006; 30: 92–94.
- 23 Maes S, Van Goethem B, Saunders J, et al. **Pneumomediastinum and subcutaneous emphysema in a cat associated with necrotizing bronchopneumonia caused by feline herpesvirus-1.** *Can Vet J* 2011; 52: 1119–1122.
- 24 Macklin CC. **Transport of air along sheaths of pulmonary blood vessels from alveoli to mediastinum: clinical implications.** *Arch Intern Med (Chic)* 1939; 64: 913–926.
- 25 Thomas EK and Syring RS. **Pneumomediastinum in cats: 45 cases (2000–2010).** *J Vet Emerg Crit Care* 2013; 23: 429–435.
- 26 Zambelli AB. **Pneumomediastinum, pneumothorax and pneumoretroperitoneum following endoscopic retrieval of a tracheal foreign body from a cat.** *J S Afr Vet Assoc* 2006; 77: 45–50.
- 27 Brown DC and Holt D. **Subcutaneous emphysema, pneumothorax, pneumomediastinum, and pneumopericardium associated with positive-pressure ventilation in a cat.** *J Am Vet Med Assoc* 1995; 206: 997–999.
- 28 Song IH, Lee SY, Lee SJ, et al. **Diagnosis and treatment of spontaneous pneumomediastinum: experience at a single institution for 10 years.** *Gen Thorac Cardiovasc Surg* 2017; 65: 280–284.
- 29 Lappin MR and Roycroft LM. **Effect of ciclosporin and methylprednisolone acetate on cats previously infected with feline herpesvirus 1.** *J Feline Med Surg* 2015; 17: 353–358.
- 30 Thomasy SM, Shull O, Outerbridge CA, et al. **Oral administration of famciclovir for treatment of spontaneous ocular, respiratory, or dermatologic disease attributed to feline herpesvirus type 1: 59 cases (2006–2013).** *J Am Vet Med Assoc* 2016; 249: 526–538.