



THE 1971 OUTBREAK OF HEMORRHAGIC DISEASE AMONG WHITE-TAILED DEER OF THE SOUTHEASTERN UNITED STATES 1

Authors: PRESTWOOD, ANNIE K., KISTNER, THEODORE P.,
KELLOGG, FOREST E., and HAYES, FRANK A.

Source: Journal of Wildlife Diseases, 10(3) : 217-224

Published By: Wildlife Disease Association

URL: <https://doi.org/10.7589/0090-3558-10.3.217>

BioOne Complete (complete.BioOne.org) is a full-text database of 200 subscribed and open-access titles in the biological, ecological, and environmental sciences published by nonprofit societies, associations, museums, institutions, and presses.

Your use of this PDF, the BioOne Complete website, and all posted and associated content indicates your acceptance of BioOne's Terms of Use, available at www.bioone.org/terms-of-use.

Usage of BioOne Complete content is strictly limited to personal, educational, and non - commercial use. Commercial inquiries or rights and permissions requests should be directed to the individual publisher as copyright holder.

BioOne sees sustainable scholarly publishing as an inherently collaborative enterprise connecting authors, nonprofit publishers, academic institutions, research libraries, and research funders in the common goal of maximizing access to critical research.

THE 1971 OUTBREAK OF HEMORRHAGIC DISEASE AMONG WHITE-TAILED DEER OF THE SOUTHEASTERN UNITED STATES¹

ANNIE K. PRESTWOOD, THEODORE P. KISTNER,² FOREST E. KELLOGG and FRANK A. HAYES
Southeastern Cooperative Wildlife Disease Study, Department of Parasitology,
College of Veterinary Medicine, University of Georgia, Athens, 30602, U.S.A.

Abstract: Hemorrhagic disease (HD) caused by bluetongue and epizootic hemorrhagic disease viruses occurred in white-tailed deer (*Odocoileus virginianus*) of seven southeastern states during the late summer and early fall, 1971. The disease first appeared in South Carolina and then erupted almost simultaneously in Florida, Georgia, Kentucky, North Carolina, Tennessee, and Virginia. Peracute, acute, and chronic forms of HD were distinguished. Few gross lesions were observed in peracute HD but hemorrhage and edema commonly were seen in acute HD. Stomatitis and laminitis characterized the chronic disease. Mortality rate appeared to be related to the number of deer on the area.

INTRODUCTION

Epizootics among wild animal populations generally are poorly documented, particularly those which occur over a large geographic region. In the southeastern United States, epizootics of unknown cause occurred among widespread white-tailed deer populations during 1949, 1954, and 1955.⁴ During the late summer and early fall of 1971, extensive mortality attributable to a hemorrhagic disease (HD) occurred among widely separated white-tailed deer populations in several southeastern states.

This report documents the appearance of the disease and presents observations on gross pathologic lesions and sequelae.

MATERIALS AND METHODS

White-tailed deer were received for clinical and pathologic studies at the Southeastern Cooperative Wildlife Dis-

ease Study's (SCWDS) regional laboratory and at on-site field laboratories established by the SCWDS. Due to the widespread and nearly simultaneous outbreaks of disease, detailed epizootiologic studies could not be conducted by the SCWDS. Game and Fish Commission personnel throughout the Southeast, however, were advised of the appearance of HD in the region and surveillance was established in each state. The Veterinarian-in-Charge (ANH, USDA) in each state also was advised of the occurrence of HD, and in some instances, USDA personnel collected specimens for laboratory diagnosis.

Moribund or recently dead animals were sought for post-mortem examinations. Whole blood was collected from each deer received alive, and samples were used for serum collection and preservation in OCG solution (5 g potassium oxalate, 5 g phenol, 500 ml distilled water, and 500 ml glycerine). Whole blood was

¹ This study was supported in part by an appropriation from the Congress of the United States. Funds were administered and research coordinated under the Federal Aid in Wildlife Restoration Act (50 Stat. 917) and through Contract No. 14-16-0008-777, Bureau of Sport Fisheries and Wildlife, U.S. Department of the Interior.

² Present address: Department of Veterinary Medicine, Oregon State University, Corvallis.

preserved in OCG solution on a volume per volume basis. Complete post-mortem examinations were performed, and gross lesions recorded. Tissues were preserved in 10% buffered formalin for subsequent histopathologic studies. When feasible, blood clots or spleens were frozen on dry ice or at -70°C or preserved in OCG solution.

For diagnostic purposes, 6 ml of a splenic tissue suspension containing 100,000 units of procaine penicillin G and 125 mg dihydrostreptomycin sulfate were injected intramuscularly into each of two tame white-tailed deer. Experimental deer were obtained as adults in Thomas-ton, Georgia, and were maintained in isolation trailers on the University Farm for 3 months prior to inoculation. Deer were observed daily for clinical signs of illness, and body temperatures were recorded. Animals were held until recovery was apparent or death had ensued. A complete necropsy was conducted on the experimental deer that died.

Serum, spleen, or whole blood samples from natural and artificial infections were forwarded for virus isolation to the Animal Disease Research Laboratory, ARS, USDA, Denver, Colorado, and to the Animal Disease Research Institute, Health of Animals Branch, Canada Department of Agriculture, Hull, Quebec.

RESULTS

White-tailed deer with lesions suggestive of HD were seen between August 7 and December 24, 1971, and deer in 23 counties of seven southeastern states (Fig. 1) were affected. Major outbreaks of HD occurred during late August and September. Acute HD, however, was not uncommon during October. Chronic HD and sequelae occurred in deer during late October, November, and December. A brief description of the disease as it occurred in each state is presented.

Field Observations

Florida.—HD in Florida was observed among deer in an enclosure in Liberty County. An estimated 25 of 400 deer

died during September through December. Morbidity, however, was considerably higher.

Georgia.—HD apparently was widespread throughout much of central and northern Georgia, although extensive mortality was not detected. Most HD occurred from early August throughout September. Surveillance for sick or dead deer was excellent and the opening of the archery season in late September enhanced location of sick or dead animals. Laminitis and secondary bacterial infections were observed infrequently in deer killed during the November hunting season.

Kentucky.—HD in Kentucky apparently was confined to an enclosure in the Mammoth Cave National Park. Mortality commenced in late September and approximately 60% of the 104 deer died.

North Carolina.—HD was widespread among deer herds throughout much of central and western North Carolina and was first detected during mid-September. Mortality was extensive on the Uwharrie Game Management Area in Montgomery County. Occasional cases of HD occurred throughout October.

South Carolina.—HD apparently was confined to deer populations in the coastal plain of South Carolina. Extensive mortality was not observed among deer of this area, however during early August hunters killed numerous animals which had stomatitis and laminitis.

Tennessee.—HD was detected only in deer of the Cades Cove area of the Great Smoky Mountains National Park in Tennessee. Mortality was first observed during the last week in August, and 52 carcasses were located. Mortality was high since observations of deer declined by 84%. Eleven cattle on the area died concomitantly with deer, and gross lesions were similar to those encountered in deer.³

Virginia.—Extensive mortality was observed in deer of James City County during late August and early September. An estimated 160 deer died on this 1000 hectare tract. Lame deer were commonly observed by hunters on the Camp Pickett

area of Nottoway County during the December hunting season. Laminitis and secondary bacterial infections were common in these animals.

Pathology

Peracute, acute, and chronic HD were observed in white-tailed deer during these outbreaks.

Animals with peracute HD frequently had few gross pathologic lesions except massive edema of the respiratory system and the head and neck. Acute pulmonary

edema caused death of these deer. In some instances an apparent compensatory dehydration of the digestive tract occurred, and ingesta in the upper digestive tract was exceedingly dry and nearly lith-like in appearance and texture.

Acute HD constituted the classic syndrome⁶ in which hemorrhages throughout the body characterized the disease. Petechial, ecchymotic, and frank hemorrhages frequently were encountered throughout the digestive tract. Erosions on the dental pad, hard palate, and tongue were not unusual in acute HD. Coronitis also occurred.

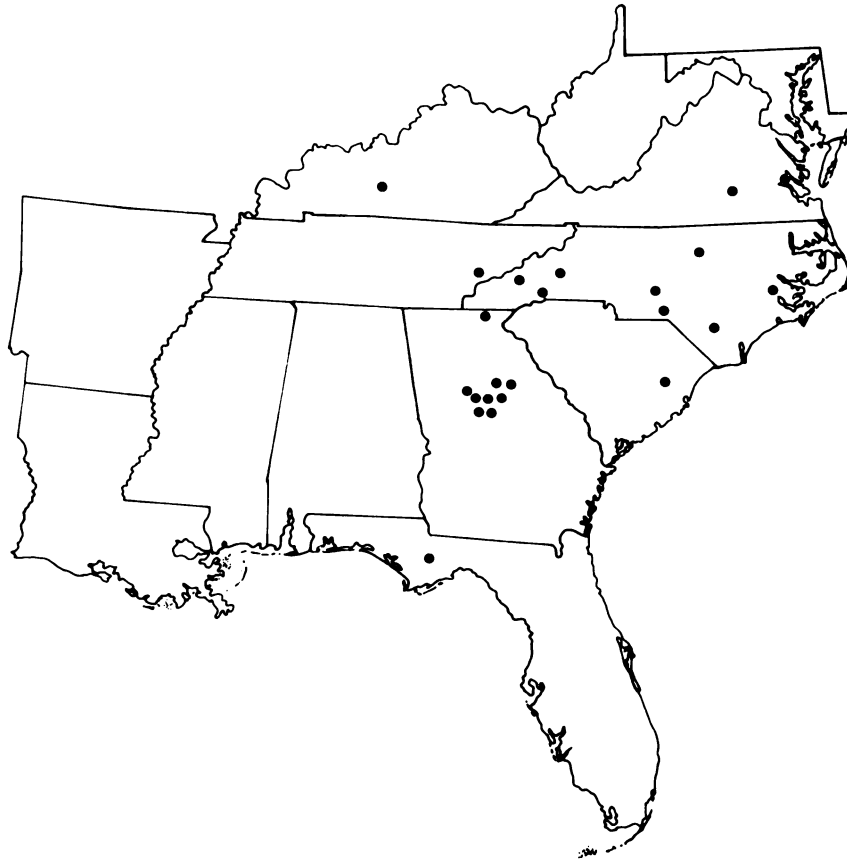

FIGURE 1. Map of southeastern United States showing origin of deer having hemorrhagic disease in 1971.

Chronic HD presented a variety of post-mortem findings. Lesions of the digestive tract and feet were most common. Ulcers on the dental pad, the hard palate, and the tongue occurred frequently (Fig. 2), and severe necrotizing glossitis occasionally was seen (Fig. 3). Ulceration and sloughing of the lining of the fore-stomachs commonly were found. In many fawns, healing of the rumen had commenced, and as much as three-fourths of the rumen wall was covered with scar tissue. These fawns were smaller than normal and malnourished. Gastritis and enteritis commonly were found in chronic HD. Foot lesions ranged from coronitis and laminitis to complete sloughing of the hooves. Secondary infections often were seen, and abscess formation was not unusual (Fig. 4). Some animals with severe foot lesions were emaciated and suffered from severe malnutrition.

Transmission Studies

A pooled splenic tissue suspension from two deer from Blount County,

Tennessee, was injected into a 1-year-old male deer. On days 5-7 post-injection, the buck had signs of illness which consisted of depression, reddening of the muzzle and ears, edema around the eyes, and laminitis. The body temperature reached a maximum of 40.2C on day 6 post-injection. After day 7, the buck began an uneventful recovery.

A splenic tissue suspension from a deer from McDowell County, North Carolina, was injected into a 2-year-old female white-tailed deer. By day 4 post-injection, the doe exhibited clinical signs of weakness and dyspnea, and the body temperature had reached 41C. On day 5 the animal's tongue had swollen and was hanging from the left side of the mouth. There was blood in the feces. On day 6, a white, frothy nasal discharge was present, there was edema of the eyes and muzzle, and all feet were swollen in the region of the fetlocks. On day 9, the deer was unable to rise, had severe dyspnea, and died during blood collection.

Salient necropsy lesions included stomatitis, laminitis, edema, and hemor-

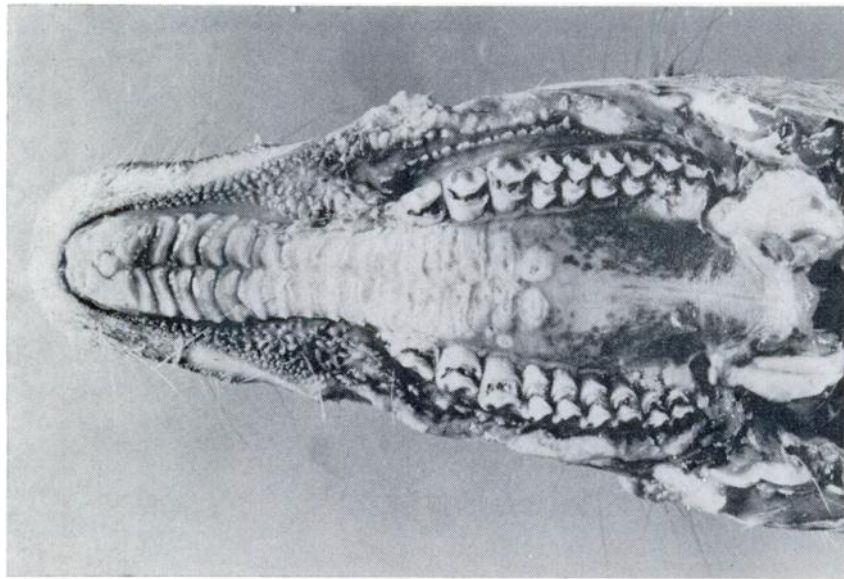


FIGURE 2. Ulcerations on dental pad and hard palate in white-tailed deer naturally affected with hemorrhagic disease. BTV was isolated.

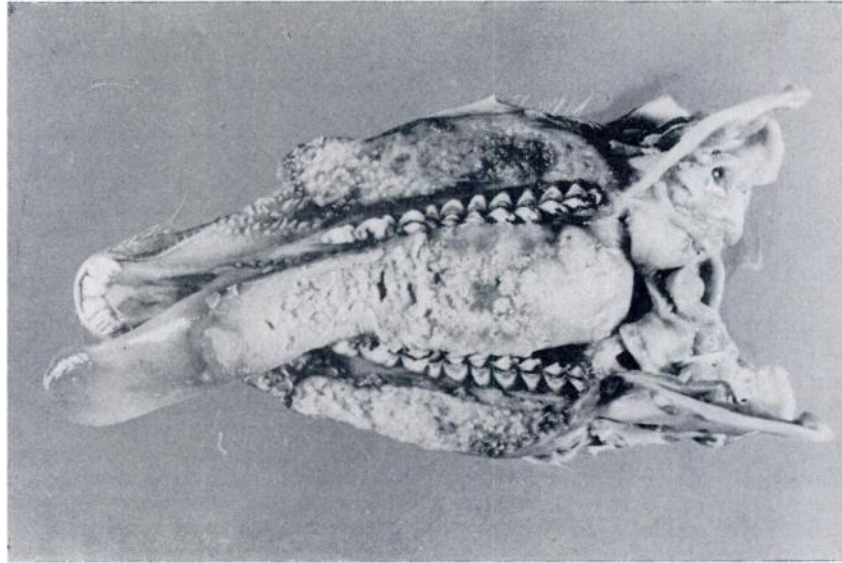


FIGURE 3. Severe necrotizing glossitis in white-tailed deer naturally affected with hemorrhagic disease. BTV was isolated. Same animal as Figure 2.

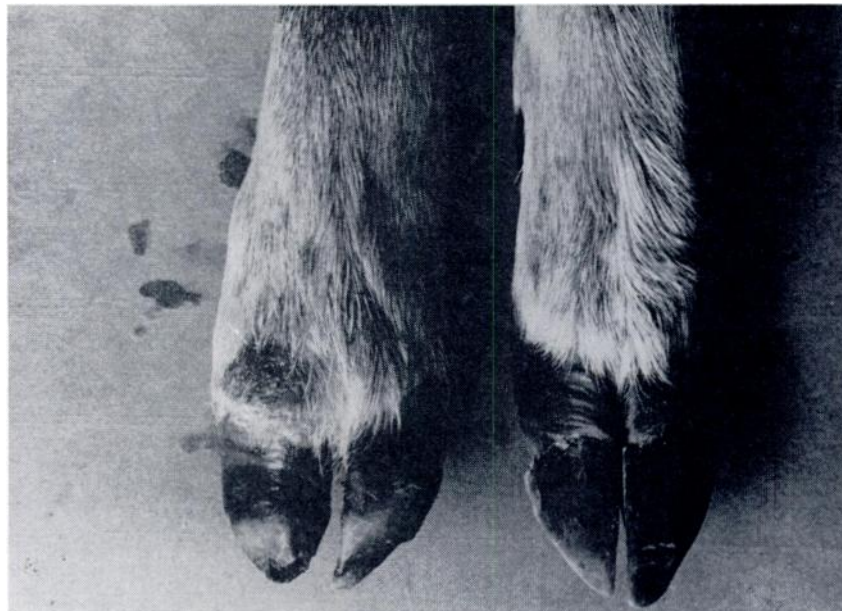

FIGURE 4. Sloughing hooves with secondary infection observed in deer recovering from hemorrhagic disease.

rhages. Hemorrhages were particularly pronounced throughout the entire digestive tract, and approximately 200 ml of free blood was found in the rectum.

Etiology

Neutralizing antibodies for bluetongue virus (BTV) and epizootic hemorrhagic disease virus (EHDV) were detected in deer sera by plaque reduction neutralization or agar gel precipitin tests. Antibodies to BTV were found in serums from deer in Liberty County, Florida, McDowell County, North Carolina, and in Berkeley and Charleston Counties, South Carolina. Antibodies for EHDV were detected in deer from Liberty County, Florida, and Greene County, Georgia. Two viruses subsequently were isolated during this outbreak, viz., BTV and EHDV. BTV was recovered from deer of Towns County, Georgia, Edmonson County, Kentucky, McDowell County, North Carolina, and Blount County, Tennessee. EHDV was isolated from deer from Edmonson County, Kentucky, and Henderson County, North Carolina. Both BTV and EHDV were isolated from a single animal in Kentucky. Florida deer had neutralizing antibodies to both viruses. Details of the serological and virological procedures and the results obtained are being presented elsewhere.¹¹

DISCUSSION

The HD syndrome in white-tailed deer generally is accepted as being caused by either of two viruses, BTV or EHDV. These entities in deer are indistinguishable clinically and pathologically, and virus isolation and identification must be performed to differentiate the infections.^{5,6,10,12,13} Epizootic hemorrhagic disease previously was known from deer only in the northern United States and Canada,¹³ while only one account of naturally occurring BT in white-tailed deer is available.⁹ This report describes the first occasion in which both viruses have been recovered during one epizootic.

Hemorrhagic disease previously was unknown in southeastern white-tailed deer

although the epizootics which occurred during 1949, 1954, and 1955 are thought to have been due to this syndrome.⁴ If HD caused earlier epizootics among southeastern deer, then its nidus during this interim remains obscure. The viruses and suitable means of transmission were present in many areas of the Southeast during the summer and fall of 1971, since epizootics erupted in many different locales almost simultaneously. These data suggest that HD first occurred in coastal South Carolina where chronic lesions of stomatitis and laminitis commonly were found in hunter-killed deer during early August. The disease next flared in piedmont Georgia and almost simultaneously in the mountains of Tennessee and coastal Virginia. Outbreaks quickly followed in the mountains of Georgia and North Carolina, piedmont North Carolina, the limestone regions of Kentucky and northwest Florida, and in southcentral Virginia (Fig. 1). In most instances there were no known connections between these outbreaks, and sites of epizootics were widely separated. Deer usually were present in the surrounding areas so a lack of suitable hosts apparently was not the limiting factor in spread of the disease.

Absence of virus or suitable vectors may have been factors limiting spread of the disease. Cattle serve as inapparent carriers of BTV, and the lesions of chronic HD in deer are markedly similar to those described for BT in cattle.^{1,2,7,8} Bluetongue has been reported in cattle of several southeastern states, and it has been suggested that "the infection and death of wild ruminants may be a result of hidden incidence of BT infection in our cattle populations."¹¹ Indeed, on one of the epizootic areas (Blount County, Tennessee) 11 cattle which shared a common pasture with deer succumbed to an unidentified syndrome which produced lesions similar to those in affected deer.⁸

The availability of suitable vectors may have contributed significantly to the spread of the disease. Bluetongue virus is biologically transmitted by *Culicoides varipennis*,^{1,12} and the closely related EHD virus probably is transmitted by

this or allied species of midges. Climatic or other conditions which affected these vectors undoubtedly would have influenced the spread of these viruses.

Deer mortality rates appeared quite variable in the epizootics and apparently were associated with host density. Among penned deer at Mammoth Cave National Park, approximately 60% of the deer succumbed (Roughton, R. D., pers. comm.). The disease was observed only rarely in wild deer within the park, where deer density was considerably lower, i.e., at or near carrying capacity. In contrast,

the mortality rate apparently was quite high among deer at the Cades Cove area of the Great Smoky Mountains National Park. Population control measures were not practiced on the latter area and a high density population was present.^a Deer herds in Montgomery County, North Carolina, and in James City County, Virginia, were considered to exceed carrying capacity, and although exact figures are not available, losses were considered high. On areas where deer populations apparently were in balance with the environment, losses appeared minimal.

Acknowledgements

The authors would like to thank the many State-Federal Conservation Biologists and Officers who aided in this study. The authors are indebted to Dr. J. G. Bowne of the United States Department of Agriculture and Dr. F. C. Thomas of the Canada Department of Agriculture for virus isolation and identification.

LITERATURE CITED

1. BOWNE, J. G. 1973. Is bluetongue an important disease in cattle? *J. Am. vet. med. Assoc.* 163: 911-914.
2. ———, A. J. LUEDKE, M. M. JOCHIM and H. E. METCALF. 1968. Bluetongue disease in cattle. *J. Am. vet. med. Assoc.* 153: 662-668.
- *3. FOX, J. R. and M. R. PELTON. 1973. Observations of a white-tailed deer die-off in the Great Smoky Mountains National Park. *Proc. 27th Annual Conf. Southeastern Association of Game and Fish Commissioners, Hot Springs, Arkansas. In press.*
- *4. HAYES, F. A. and ANNIE K. PRESTWOOD. 1969. Some considerations for diseases and parasites of white-tailed deer in the southeastern United States. *Proc. Symposium White-Tailed Deer in the Southern Forest Habitat, Nacogdoches, Texas, 25-26 March 1969, p. 32-36.*
5. KARSTAD, L. and D. O. TRAINER. 1967. Histopathology of experimental bluetongue disease of white-tailed deer. *Can. vet. J.* 8: 247-254.
6. ———, A. WINTER and D. O. TRAINER. 1961. Pathology of epizootic hemorrhagic disease of deer. *Am. J. vet. Res.* 22: 227-235.
7. LUEDKE, A. J., M. M. JOCHIM and R. H. JONES. 1969. Bluetongue in cattle: Viremia. *Am. J. vet. Res.* 30: 511-516.
8. ———, ———, J. G. BOWNE and R. H. JONES. 1970. Observations on latent bluetongue virus infection in cattle. *J. Am. vet. med. Assoc.* 156: 1871-1879.
9. STAIR, E. L., R. M. ROBINSON and L. P. JONES. 1968. Spontaneous bluetongue in Texas white-tailed deer. *Path. vet.* 5: 164-173.

* Available from: Library Reference Service, Conservation Library Center, Denver Public Library, 1357 Broadway, Denver, Colorado 80203.

10. THOMAS, F. C. and JANICE MILLER. 1971. A comparison of bluetongue virus and EHD virus: Electron microscopy and serology. *Can. J. comp. Med.* 35: 22-27.
11. ———, N. WILLIS and G. RUCKERBAUER. 1974. Identification of viruses involved in the 1971 outbreak of hemorrhagic disease in southeastern United States white-tailed deer. *J. Wildl. Dis.* 10: 187-189.
12. TRAINER, D. O. 1970. Bluetongue. In: *Infectious Diseases of Wild Mammals*. Davis, J. W., L. H. Karstad and D. O. Trainer, eds. Iowa State Univ. Press, Ames. p. 55-59.
13. ——— and L. H. KARSTAD. 1970. Epizootic hemorrhagic disease. In: *Infectious Diseases of Wild Mammals*. Davis, J. W., L. H. Karstad and D. O. Trainer, eds. Iowa State Univ. Press, Ames. p. 51-54.
14. VOSDINGH, R. A., D. O. TRAINER and B. C. EASTERDAY. 1968. Experimental bluetongue disease in white-tailed deer. *Can. J. comp. Med. vet. Sci.* 32: 382-387.

Received for publication 19 October 1973
